



www.ofthalmoloji.org

E-ISSN: 2149-8709

# TURKISH JOURNAL OF OPHTHALMOLOGY

TURKISH JOURNAL OF OPHTHALMOLOGY

TJO

## Research Articles

*Superiority of Baseline Biomechanical Properties over Corneal Tomography in Predicting Keratoconus Progression*

Mehmet Akif Erol et al.; Eskişehir, Turkey

*Retrospective Evaluation of Corneal Foreign Bodies with Anterior Segment Optical Coherence Tomography*

Elif Akbaş et al.; İzmir, Turkey

*Survey of the Impact of the COVID-19 Pandemic on Ophthalmology Clinical Practice in Turkey*

Melisa Zişan Karşlıoğlu et al.; İstanbul, Gaziantep, Turkey

*The Causes and Frequency of Monocular and Binocular Blindness in Adults Applying to the Health Committee of a University Hospital in Central Anatolia*

Günsu Deniz Mirza et al.; Konya, Turkey

*The Surgeon's Role in Inducing and Controlling Motion Errors During Intraocular Membrane Peeling Procedures*

Mahmut Dođramacı and David Steel; Essex, Newcastle Upon Tyne, United Kingdom

*Experimental Laboratory Modeling of Choroidal Vasculature: A Study of the Dynamics of Intraoperative Choroidal Hemorrhage during Pars Plana Vitrectomy*

Mahmut Dođramacı et al.; Essex, United Kingdom, İstanbul, Turkey

## Review

*Does Ophthalmology Need Philosophy?*

Dođan Ceyhan and Tekin Yaşar; Nicosia, TRNC, İstanbul, Turkey

## Case Reports

*Traumatic Dislocation of the Globe into the Ethmoid Sinus*

Zafer Onaran et al.; Kırkkale, Ankara, Turkey

*Lipemia Retinalis Diagnosed Incidentally After Laser Photocoagulation Treatment for Retinopathy of Prematurity*

Taylan Öztürk et al.; İzmir, Turkey

*Challenges in the Diagnosis of Intraocular Lymphoma*

Mahmut Kaya et al.; İzmir, Turkey

*Serpiginous Choroiditis Complicated with Choroidal Neovascular Membrane Detected using Optical Coherence Tomography Angiography: A Case Series and Literature Review*

Asli Perente et al.; Alexandroupoli, Greece

## Letter to the Editor

*Letter to the Editor re: "The Relationship Between Keratoconus Stage and the Thickness of the Retinal Layers"*

Masoud Khorrami-nejad and Mohsen Heirani; Tehran, Iran

## Reply to Letter to the Editor

*Reply to Letter to the Editor re: "The Relationship Between Keratoconus Stage and the Thickness of the Retinal Layers"*

Cemal Özsaygılı and Yener Yıldırım; Kayseri, Turkey

September  
October 2021  
51 Volume  
Issue 5

# TURKISH JOURNAL OF OPHTHALMOLOGY



www.offtalmoloji.org

TJO

## Editor-in-Chief

### Murat İRKEÇ, MD

Hacettepe University Faculty of Medicine, Department of Ophthalmology, Ankara, Turkey

Areas of Interest: Cornea and Ocular Surface Disease, Glaucoma, Allergy and Immunology

E-mail: mirkec@hacettepe.edu.tr

ORCID ID: orcid.org/0000-0001-8892-4811

## Associate Editors

### Tomris ŞENGÖR, MD

İstanbul Bilim University Faculty of Medicine, Department of Ophthalmology, İstanbul, Turkey

Areas of Interest: Cornea and Ocular Surface Disease, Contact Lens

E-mail: tomris.sengor@gmail.com

ORCID ID: orcid.org/0000-0002-9436-5582

### Sait EĞRİLMEZ, MD

Ege University Faculty of Medicine, Department of Ophthalmology, İzmir, Turkey

Areas of Interest: Cornea and Ocular Surface Disease, Contact Lens, Refraction, Cataract and Refractive Surgery

E-mail: saitegrilmez@gmail.com

ORCID ID: orcid.org/0000-0002-6971-527X

### Özlem YILDIRIM, MD

Mersin University Faculty of Medicine, Department of Ophthalmology, Mersin, Turkey

Areas of Interest: Uveitis, Medical Retina, Glaucoma

E-mail: dryildirimoz@hotmail.com

ORCID ID: orcid.org/0000-0002-3773-2497

### Banu BOZKURT, MD, FEBO

Selçuk University Faculty of Medicine, Department of Ophthalmology, Konya, Turkey

Areas of Interest: Cornea and Ocular Surface Disease, Glaucoma, Allergy and Immunology

E-mail: drbanubozkurt@yahoo.com

ORCID ID: orcid.org/0000-0002-9847-3521

## Statistical Board

### Ahmet DİRİCAN

İstanbul University İstanbul Faculty of Medicine, Department of Biostatistics and Medical Informatics, İstanbul, Turkey

## English Language Editor

Jacqueline Renee GUTENKUNST, Maryland, USA

## Publishing House

Molla Gürani Mah. Kaçamak Sokak No: 21,  
34093 Fındıkzade-İstanbul-Turkey

Publisher Certificate Number: 14521

Phone: +90 212 621 99 25 Fax: +90 212 621 99 27

E-mail: info@galenos.com.tr

Online Publishing Date: October 2021

International scientific journal published bimonthly.

E-ISSN: 2149-8709



## Advisory Board

### Yonca AYDIN AKOVA,

Bayındır Kavaklıdere Hospital, Ophthalmology Clinic, Ankara, Turkey

### Mustafa Kemal ARICI,

Bezmialem Vakıf University Faculty of Medicine, Department of Ophthalmology, İstanbul, Turkey

### Atila BAYER,

Ophthalmology, Dünyagöz Hospital, Ankara, Turkey

### Kamil BİLGİHAN,

Gazi University Faculty of Medicine, Department of Ophthalmology, Ankara, Turkey

### İzzet CAN,

Ophthalmology, Independent Practitioner, Ankara, Turkey

### Jose M. BENİTEZ-del-CASTILLO,

Universidad Complutense de Madrid, Hospital Clinico San Carlos, Department of Ophthalmology, Madrid, Spain

### Murat DOĞRU,

Keio University Faculty of Medicine, Department of Ophthalmology, Tokyo, Japan

### Şansal GEDİK,

Selçuk University Faculty of Medicine, Department of Ophthalmology, Konya, Turkey

### Ömür UÇAKHAN GÜNDÜZ,

Ankara University Faculty of Medicine, Department of Ophthalmology, Ankara, Turkey

### Banu Melek HOŞAL,

Ankara University Faculty of Medicine, Department of Ophthalmology, Ankara, Turkey

### Sibel ÇALIŞKAN KADAYIFÇILAR,

Hacettepe University Faculty of Medicine, Department of Ophthalmology, Ankara, Turkey

### Murat KARAÇORLU,

İstanbul Retina Institute, Ophthalmology Clinic, İstanbul, Turkey

### Sarper KARAKÜÇÜK,

Anadolu Medical Center, Ophthalmology Clinic, Kocaeli, Turkey

### Tero KİVELÄ,

University of Helsinki, Helsinki University Hospital, Department of Ophthalmology, Helsinki, Finland

### Hayyam KIRATLI,

Hacettepe University Faculty of Medicine, Department of Ophthalmology, Ankara, Turkey

### Anastasio G.P. KONSTAS,

Aristotle University of Thessaloniki, Department of Ophthalmology, Thessaloniki, Greece

### Anat LOEWENSTEIN,

Tel Aviv University Sackler Faculty of Medicine, Department of Ophthalmology, Tel Aviv, Israel

### Mehmet Cem MOCAN,

University of Illinois at Chicago, Department of Ophthalmology and Visual Sciences, Chicago

### Pınar AYDIN O'DWYER,

Ophthalmology, Independent Practitioner, Ankara, Turkey

### Şengül ÖZDEK,

Gazi University Faculty of Medicine, Department of Ophthalmology, Ankara, Turkey

### Hakan ÖZDEMİR,

Bezmialem Vakıf University Faculty of Medicine, Department of Ophthalmology, İstanbul, Turkey

### Banu TURGUT ÖZTÜRK,

Selçuk University Faculty of Medicine, Department of Ophthalmology, Konya, Turkey

### Seyhan Bahar ÖZKAN,

Adnan Menderes University Faculty of Medicine, Department of Ophthalmology, Aydın, Turkey

### Afsun ŞAHİN,

Koç University Faculty of Medicine, Department of Ophthalmology, İstanbul, Turkey

### H. Nida ŞEN,

George Washington University, National Eye Institute, Department of Ophthalmology, Washington, USA

### İlknur TUĞAL-TUTKUN,

İstanbul University İstanbul Faculty of Medicine, Department of Ophthalmology, İstanbul, Turkey

### Nilgün YILDIRIM,

Eskişehir Osmangazi University Faculty of Medicine, Department of Ophthalmology, Eskişehir, Turkey

### Nurşen YÜKSEL,

Kocaeli University Faculty of Medicine, Department of Ophthalmology, Kocaeli, Turkey

**The Turkish Journal of Ophthalmology is an official journal of the Turkish Ophthalmological Association.**

On Behalf of Turkish Ophthalmological Association Owner

### İzzet CAN

Private Practice, Ankara, Turkey

# TURKISH JOURNAL OF OPHTHALMOLOGY

TJO



www.ofthalmoloji.org

## ABOUT US

The Turkish Journal of Ophthalmology (TJO) is the only scientific periodical publication of the Turkish Ophthalmological Association and has been published since January 1929. In its early years, the journal was published in Turkish and French. Although there were temporary interruptions in the publication of the journal due to various challenges, the Turkish Journal of Ophthalmology has been published continually from 1971 to the present.

The Turkish Journal of Ophthalmology is currently published in Turkish and English languages. TJO is an independent international periodical journal based on single-blind peer-review principle. TJO is regularly published six times a year and special issues are occasionally released. The aim of TJO is to publish original research papers of the highest scientific and clinical value at an international level. Furthermore, review articles, case reports, editorial comments, letters to the editor, educational contributions and congress/meeting announcements are released.

The target audience includes specialists and physicians in training in ophthalmology in all relevant disciplines.

The editorial policies are based on the "Recommendations for the Conduct, Reporting, Editing, and Publication of Scholarly Work in Medical Journals (ICMJE Recommendations)" by the International Committee of Medical Journal Editors (2013, archived at <http://www.icmje.org/>) rules.

The Turkish Journal of Ophthalmology is indexed in the **PubMed/MEDLINE**, **PubMed Central (PMC)**, **Web of Science-Emerging Sources Citation Index (ESCI)**, **Scopus**, **TUBITAK/ULAKBIM**, **Directory of Open Access Journals (DOAJ)**, **EBSCO Database**, **CINAHL**, **Proquest**, **Embase**, **British Library**, **Index Copernicus**, **J-Gate**, **IdealOnline**, **Turk Medline**, **Hinari**, **GOALI**, **ARDI**, **OARE** and **Turkish Citation Index**.

### Open Access Policy

This journal provides immediate open access to its content on the principle that making research freely available to the public supports a greater global exchange of knowledge.

Open Access Policy is based on the rules of the Budapest Open Access Initiative (BOAI) <http://www.budapestopenaccessinitiative.org/>. By "open access" to peer-reviewed research literature, we mean its free availability on the public internet, permitting any users to read, download, copy, distribute, print, search, or link to the full texts of these articles, crawl them for indexing, pass them as data to software, or use them for any other lawful purpose, without financial, legal, or technical barriers other than those inseparable from gaining access to the internet itself. The only constraint on reproduction and distribution, and the only role for copyright in this domain, should be to give authors control over the integrity of their work and the right to be properly acknowledged and cited.

### Subscription Information

TJO is sent free of charge to subscribers. Address changes should be immediately reported to the affiliates and to the managing editor. Subscribers who do not receive the journal in the relevant time period should contact the managing editor. All published volumes in full text can be reached free of charge through the website [www.ofthalmoloji.org](http://www.ofthalmoloji.org). Requests for subscription should be addressed to the Turkish Ophthalmological Association.

Manuscripts can only be submitted electronically through the Journal Agent website (<http://journalagent.com/tjo/>) after creating an account. This system allows online submission and review.

### Membership Procedures

#### Turkish Ophthalmological Association

Bank Account: Yapı Kredi Bankası, Şehremini Şubesi 65774842

IBAN: TR10 0006 7010 0000 0065 7748 42

Annual Subscription: Domestic: 100.-TL (Tax Incl)

Abroad: 100 USD (Tax Incl.)

#### Correspondence Address

Editor-in-Chief, Murat İrkeç, MD, Professor in Ophthalmology  
Hacettepe University Faculty of Medicine, Department of Ophthalmology  
06100 Sıhhiye-Ankara-Turkey

**Phone:** +90 212 801 44 36/37 Fax: +90 212 801 44 39

**E-mail:** [mirkec@hacettepe.edu.tr](mailto:mirkec@hacettepe.edu.tr)

#### Secretary, Selvinaz Arslan

**E-mail:** [dergi@ofthalmoloji.org](mailto:dergi@ofthalmoloji.org) - [sekreter@ofthalmoloji.org](mailto:sekreter@ofthalmoloji.org)

**Address:** Avrupa Konutları Kale, Maltepe Mah. Yedikule Çırpıcı Yolu Sk.

9. Blok No: 2 Kat:1 Ofis:1 Zeytinburnu-Istanbul-Turkey

**Phone:** +90 536 656 87 26 Fax: +90 212 801 44 39

**Web Page:** [www.ofthalmoloji.org](http://www.ofthalmoloji.org)

#### Permissions

Requests for permission to reproduce published material should be sent to the editorial office.

**Editor-in-Chief:** Murat İrkeç, MD, Professor in Ophthalmology

**Address:** Avrupa Konutları Kale, Maltepe Mah. Yedikule Çırpıcı Yolu Sk.

9. Blok No: 2 Kat:1 Ofis:1 Zeytinburnu-Istanbul-Turkey

**Phone:** +90 212 801 44 36/37 Fax: +90 212 801 44 39

**Web Page:** [www.ofthalmoloji.org](http://www.ofthalmoloji.org)

**E-mail:** [dergi@ofthalmoloji.org](mailto:dergi@ofthalmoloji.org) - [sekreter@ofthalmoloji.org](mailto:sekreter@ofthalmoloji.org)

#### Advertisement

Applications for advertisement should be addressed to the editorial office.

**Address:** Avrupa Konutları Kale, Maltepe Mah. Yedikule Çırpıcı Yolu Sk.

9. Blok No: 2 Kat:1 Ofis:1 Zeytinburnu-Istanbul-Turkey

**Phone:** +90 212 801 44 36/37 Fax: +90 212 801 44 39

**Web Page:** [www.ofthalmoloji.org](http://www.ofthalmoloji.org)

**E-mail:** [dergi@ofthalmoloji.org](mailto:dergi@ofthalmoloji.org) - [sekreter@ofthalmoloji.org](mailto:sekreter@ofthalmoloji.org)

#### Publisher Corresponding Address

**Publisher:** Erkan Mor

Galenos Yayınevi Tic. Ltd. Şti.

**Address:** Molla Gürani Mah. Kaçamak Sk. No: 21, 34093

Fındıkzade-Istanbul-Turkey

**Phone:** +90 212 621 99 25 Fax: +90 212 621 99 27

**E-mail:** [info@galenos.com.tr](mailto:info@galenos.com.tr)

#### Instructions for Authors

Instructions for authors are published in the journal and on the website [www.ofthalmoloji.org](http://www.ofthalmoloji.org)

#### Material Disclaimer

The author(s) is (are) responsible for the articles published in the Turkish Journal of Ophthalmology.

The editor, editorial board and publisher do not accept any responsibility for the articles.

The journal is printed on acid-free paper.

This work is licensed under a Creative Commons Attribution-Non Commercial-No Derivatives 4.0 International License.

## INSTRUCTIONS TO AUTHORS

The Turkish Journal of Ophthalmology is an official peer-reviewed publication of the Turkish Ophthalmological Association. Accepted manuscripts are printed in Turkish and published online in both Turkish and English languages. Manuscripts written in Turkish should be in accordance with the Turkish Dictionary and Writing Guide ("Türkçe Sözlüğü ve Yazım Kılavuzu") of the Turkish Language Association. Turkish forms of ophthalmology-related terms should be checked in the TODNET Dictionary ("TODNET Sözlüğü" <http://www.todnet.org/sozlu/>) and used accordingly.

The Turkish Journal of Ophthalmology does not charge any article submission or processing charges.

A manuscript will be considered only with the understanding that it is an original contribution that has not been published elsewhere.

Reviewed and accepted manuscripts are translated either from Turkish to English or from English to Turkish by the Journal through a professional translation service. Prior to publishing, the translations are submitted to the authors for approval or correction requests, to be returned within 7 days. If no response is received from the corresponding author within this period, the translation is checked and approved by the editorial board.

The abbreviation of the Turkish Journal of Ophthalmology is TJO, however, it should be denoted as Turk J Ophthalmol when referenced. In the international index and database, the name of the journal has been registered as Turkish Journal of Ophthalmology and abbreviated as Turk J Ophthalmol.

The scientific and ethical liability of the manuscripts belongs to the authors and the copyright of the manuscripts belongs to the Turkish Journal of Ophthalmology. Authors are responsible for the contents of the manuscript and accuracy of the references. All manuscripts submitted for publication must be accompanied by the Copyright Transfer Form. Once this form, signed by all the authors, has been submitted, it is understood that neither the manuscript nor the data it contains have been submitted elsewhere or previously published and authors declare the statement of scientific contributions and responsibilities of all authors.

All manuscripts submitted to the Turkish Journal of Ophthalmology are screened for plagiarism using the 'iThenticate' software. Results indicating plagiarism may result in manuscripts being returned or rejected.

Experimental, clinical and drug studies requiring approval by an ethics committee must be submitted to the Turkish Journal of Ophthalmology with an ethics committee approval report confirming that the study was conducted in accordance with international agreements and the Declaration of Helsinki (revised 2013) (<https://www.wma.net/policies-post/wma-declaration-of-helsinki-ethical-principles-for-medical-research-involving-human-subjects/>). The approval of the ethics committee and the fact that informed consent was given by the patients should be indicated in the Materials and Methods section. In experimental animal studies, the authors should indicate that the procedures followed were in accordance with animal rights as per the Guide for the Care and Use of Laboratory Animals (<http://oacu.od.nih.gov/regs/guide/guide.pdf>) and they should obtain animal ethics committee approval.

Authors must provide disclosure/acknowledgment of financial or material support, if any was received, for the current study.

If the article includes any direct or indirect commercial links or if any institution provided material support to the study, authors must state in the cover letter that they have no relationship with the commercial product, drug, pharmaceutical company, etc. concerned; or specify the type of relationship (consultant, other agreements), if any.

Authors must provide a statement on the absence of conflicts of interest among the authors and provide authorship contributions.

The Turkish Journal of Ophthalmology is an independent international journal based on single-blind peer-review principles. The manuscript is assigned to the Editor-in-Chief, who reviews the manuscript and makes an initial decision based on manuscript quality and editorial priorities. Manuscripts that pass initial evaluation are sent for external peer review, and the Editor-in-Chief assigns an Associate Editor. The Associate Editor sends the manuscript to three reviewers (internal and/or external reviewers). The reviewers must review the manuscript within 21 days. The Associate Editor recommends a decision based on the reviewers' recommendations and returns the manuscript to the Editor-in-Chief. The Editor-in-Chief makes a final decision based on editorial priorities, manuscript quality, and reviewer recommendations. If there are any conflicting recommendations from reviewers, the Editor-in-Chief can assign a new reviewer.

The scientific board guiding the selection of the papers to be published in the Journal consists of elected experts of the Journal and if necessary, selected from national and international authorities. The Editor-in-Chief, Associate Editors, biostatistics expert and English language consultant may make minor corrections to accepted manuscripts that do not change the main text of the paper.

In case of any suspicion or claim regarding scientific shortcomings or ethical infringement, the Journal reserves the right to submit the manuscript to the supporting institutions or other authorities for investigation. The Journal accepts the responsibility of initiating action but does not undertake any responsibility for an actual investigation or any power of decision.

The Editorial Policies and General Guidelines for manuscript preparation specified below are based on "Recommendations for the Conduct, Reporting, Editing, and Publication of Scholarly Work in Medical Journals (ICMJE Recommendations)" by the International Committee of Medical Journal Editors (2013, archived at <http://www.icmje.org/>).

Preparation of research articles, systematic reviews and meta-analyses must comply with study design guidelines: CONSORT statement for randomized controlled trials (Moher D, Schultz KF, Altman D, for the CONSORT Group. The CONSORT statement revised recommendations for improving the quality of reports of parallel group randomized trials. *JAMA* 2001; 285: 1987-91) (<http://www.consort-statement.org/>);

PRISMA statement of preferred reporting items for systematic reviews and meta-analyses (Moher D, Liberati A, Tetzlaff J, Altman DG, The PRISMA Group. Preferred Reporting Items

for Systematic Reviews and Meta-Analyses: The PRISMA Statement. *PLoS Med* 2009; 6(7): e1000097.) (<http://www.prisma-statement.org/>);

STARD checklist for the reporting of studies of diagnostic accuracy (Bossuyt PM, Reitsma JB, Bruns DE, Gatsonis CA, Glasziou PP, Irwig LM, et al., for the STARD Group. Towards complete and accurate reporting of studies of diagnostic accuracy: the STARD initiative. *Ann Intern Med* 2003;138:40-4.) (<http://www.stard-statement.org/>);

STROBE statement, a checklist of items that should be included in reports of observational studies (<http://www.strobe-statement.org/>);

MOOSE guidelines for meta-analysis and systemic reviews of observational studies (Stroup DF, Berlin JA, Morton SC, et al. Meta-analysis of observational studies in epidemiology: a proposal for reporting Meta-analysis of observational Studies in Epidemiology (MOOSE) group. *JAMA* 2000; 283: 2008-12).

### GENERAL GUIDELINES

Manuscripts can only be submitted electronically through the Journal Agent website (<http://journalagent.com/tjo/>) after creating an account. This system allows online submission and review.

The manuscripts are archived according to ICMJE, Index Medicus (Medline/PubMed) and Ulakbim-Turkish Medicine Index Rules.

**Format:** Manuscripts should be prepared using Microsoft Word, size A4 with 2.5 cm margins on all sides, 12 pt Arial font and 1.5 line spacing.

**Abbreviations:** Abbreviations should be defined at first mention and used consistently thereafter. Internationally accepted abbreviations should be used; refer to scientific writing guides as necessary.

**Cover letter:** The cover letter should include statements about manuscript type, single-journal submission affirmation, conflict of interest statement, sources of outside funding, equipment (if applicable), approval of language for articles in English and approval of statistical analysis for original research articles.

### REFERENCES

Authors are solely responsible for the accuracy of all references.

**In-text citations:** References should be indicated as a superscript immediately after the period/full stop of the relevant sentence. If the author(s) of a reference is/are indicated at the beginning of the sentence, this reference should be written as a superscript immediately after the author's name. If relevant research has been conducted in Turkey or by Turkish investigators, these studies should be given priority while citing the literature.

Presentations presented in congresses, unpublished manuscripts, theses, Internet addresses, and personal interviews or experiences should not be indicated as references. If such references are used, they should be indicated in parentheses at the end of the relevant sentence in the text, without reference number and written in full, in order to clarify their nature.

**References section:** References should be numbered consecutively in the order in which they are first mentioned in the text. All authors should be listed regardless of number.

## INSTRUCTIONS TO AUTHORS

The titles of journals should be abbreviated according to the style used in the Index Medicus.

### Reference Format

**Journal:** Last name(s) of the author(s) and initials, article title, publication title and its original abbreviation, publication date, volume, the inclusive page numbers. Example: Collin JR, Rathbun JE. Involitional entropion: a review with evaluation of a procedure. Arch Ophthalmol. 1978;96:1058-1064.

**Book:** Last name(s) of the author(s) and initials, chapter title, book editors, book title, edition, place of publication, date of publication and inclusive page numbers of the extract cited. Example: Herbert L. The Infectious Diseases (1st ed). Philadelphia; Mosby Harcourt; 1999:11;1-8.

**Book Chapter:** Last name(s) of the author(s) and initials, chapter title, book editors, book title, edition, place of publication, date of publication and inclusive page numbers of the cited piece.

Example: O'Brien TP, Green WR. Periocular Infections. In: Feigin RD, Cherry JD, eds. Textbook of Pediatric Infectious Diseases (4th ed). Philadelphia; W.B. Saunders Company; 1998:1273-1278.

Books in which the editor and author are the same person: Last name(s) of the author(s) and initials, chapter title, book editors, book title, edition, place of publication, date of publication and inclusive page numbers of the cited piece. Example: Solcia E, Capella C, Kloppel G. Tumors of the exocrine pancreas. In: Solcia E, Capella C, Kloppel G, eds. Tumors of the Pancreas. 2nd ed. Washington: Armed Forces Institute of Pathology; 1997:145-210.

### TABLES, GRAPHICS, FIGURES, AND IMAGES

All visual materials together with their legends should be located on separate pages that follow the main text.

**Images:** Images (pictures) should be numbered and include a brief title. Permission to reproduce pictures that were published elsewhere must be included. All pictures should be of the highest quality possible, in JPEG format, and at a minimum resolution of 300 dpi.

**Tables, Graphics, Figures:** All tables, graphics or figures should be enumerated according to their sequence within the text and a brief descriptive caption should be written. Any abbreviations used should be defined in the accompanying legend. Tables in particular should be explanatory and facilitate readers' understanding of the manuscript, and should not repeat data presented in the main text.

### BIOSTATISTICS

To ensure controllability of the research findings, the study design, study sample, and the methodological approaches and applications should be explained and their sources should be presented.

The "P" value defined as the limit of significance along with appropriate indicators of measurement error and uncertainty (confidence interval, etc.) should be specified. Statistical terms, abbreviations and symbols used in the article should be described and the software used should be defined. Statistical terminology (random, significant, correlation, etc.) should not be used in non-statistical contexts.

All results of data and analysis should be presented in the Results section as tables, figures and graphics; biostatistical methods used and application details should be presented

in the Materials and Methods section or under a separate title.

### MANUSCRIPT TYPES

#### Original Articles

Clinical research should comprise clinical observation, new techniques or laboratories studies. Original research articles should include title, structured abstract, key words relevant to the content of the article, introduction, materials and methods, results, discussion, study limitations, conclusion references, tables/figures/images and acknowledgement sections. Title, abstract and key words should be written in both Turkish and English. The manuscript should be formatted in accordance with the above-mentioned guidelines and should not exceed sixteen A4 pages.

**Title Page:** This page should include the title of the manuscript, short title, name(s) of the authors and author information. The following descriptions should be stated in the given order:

1. Title of the manuscript (Turkish and English), as concise and explanatory as possible, including no abbreviations, up to 135 characters
2. Short title (Turkish and English), up to 60 characters
3. Name(s) and surname(s) of the author(s) (without abbreviations and academic titles) and affiliations
4. Name, address, e-mail, phone and fax number of the corresponding author
5. The place and date of scientific meeting in which the manuscript was presented and its abstract published in the abstract book, if applicable

**Abstract:** A summary of the manuscript should be written in both Turkish and English. References should not be cited in the abstract. Use of abbreviations should be avoided as much as possible; if any abbreviations are used, they must be taken into consideration independently of the abbreviations used in the text. For original articles, the structured abstract should include the following sub-headings:

**Objectives:** The aim of the study should be clearly stated.

**Materials and Methods:** The study and standard criteria used should be defined; it should also be indicated whether the study is randomized or not, whether it is retrospective or prospective, and the statistical methods applied should be indicated, if applicable.

**Results:** The detailed results of the study should be given and the statistical significance level should be indicated.

**Conclusion:** Should summarize the results of the study, the clinical applicability of the results should be defined, and the favorable and unfavorable aspects should be declared.

**Keywords:** A list of minimum 3, but no more than 5 key words must follow the abstract. Key words in English should be consistent with "Medical Subject Headings (MESH)" ([www.nlm.nih.gov/mesh/MBrowser.html](http://www.nlm.nih.gov/mesh/MBrowser.html)). Turkish key words should be direct translations of the terms in MESH.

Original research articles should have the following sections:

**Introduction:** Should consist of a brief explanation of the topic and indicate the objective of the study, supported by information from the literature.

**Materials and Methods:** The study plan should be clearly described, indicating whether the study is randomized or not, whether it is retrospective or prospective, the number of trials, the characteristics, and the statistical methods used.

**Results:** The results of the study should be stated, with tables/figures given in numerical order; the results should

be evaluated according to the statistical analysis methods applied. See General Guidelines for details about the preparation of visual material.

**Discussion:** The study results should be discussed in terms of their favorable and unfavorable aspects and they should be compared with the literature. The conclusion of the study should be highlighted.

**Study Limitations:** Limitations of the study should be discussed. In addition, an evaluation of the implications of the obtained findings/results for future research should be outlined.

**Conclusion:** The conclusion of the study should be highlighted.

**Acknowledgements:** Any technical or financial support or editorial contributions (statistical analysis, English/Turkish evaluation) towards the study should appear at the end of the article.

**References:** Authors are responsible for the accuracy of the references. See General Guidelines for details about the usage and formatting required.

### Case Reports

Case reports should present cases which are rarely seen, feature novelty in diagnosis and treatment, and contribute to our current knowledge. The first page should include the title in Turkish and English, an unstructured summary not exceeding 150 words, and key words. The main text should consist of introduction, case report, discussion and references. The entire text should not exceed 5 pages (A4, formatted as specified above).

### Review Articles

Review articles can address any aspect of clinical or laboratory ophthalmology. Review articles must provide critical analyses of contemporary evidence and provide directions of current or future research. Most review articles are commissioned, but other review submissions are also welcome. Before sending a review, discussion with the editor is recommended.

Reviews articles analyze topics in depth, independently and objectively. The first chapter should include the title in Turkish and English, an unstructured summary and key words. Source of all citations should be indicated. The entire text should not exceed 25 pages (A4, formatted as specified above).

### Letters to the Editor

Letters to the Editor should be short commentaries related to current developments in ophthalmology and their scientific and social aspects, or may be submitted to ask questions or offer further contributions in response to work that has been published in the Journal. Letters do not include a title or an abstract; they should not exceed 1,000 words and can have up to 5 references.

### CORRESPONDENCE

All correspondence should be directed to the TJO editorial board:

Post: Turkish Ophthalmological Association  
Avrupa Konutları Kale, Maltepe Mah. Yedikule Çırpıcı Yolu  
Sk. 9. Blok No: 2 Kat:1 Ofis:1 Zeytinburnu-Istanbul-Turkey  
**Phone:** +90 212 801 44 36/37 Fax: +90 212 801 44 39  
**Web Page:** [www.ofthalmoloji.org](http://www.ofthalmoloji.org)  
**E-mail:** [dergi@ofthalmoloji.org](mailto:dergi@ofthalmoloji.org) / [sekreter@ofthalmoloji.org](mailto:sekreter@ofthalmoloji.org)

## CONTENTS

### Research Articles

- 257 Superiority of Baseline Biomechanical Properties over Corneal Tomography in Predicting Keratoconus Progression  
Mehmet Akif Erol, Eray Atalay, Onur Özalp, Abdullah Divarçı, Nilgün Yıldırım; Eskişehir, Turkey
- 265 Retrospective Evaluation of Corneal Foreign Bodies with Anterior Segment Optical Coherence Tomography  
Elif Akbaş, Özlem Barut Selver, Melis Palamar; İzmir, Turkey
- 269 Survey of the Impact of the COVID-19 Pandemic on Ophthalmology Clinical Practice in Turkey  
Melisa Zişan Karşlıoğlu, Cem Öztürkmen, Cem Kesim, Ayşe Yıldız Taş, Pınar Günel Karadeniz, Afsun Şahin; İstanbul, Gaziantep, Turkey
- 282 The Causes and Frequency of Monocular and Binocular Blindness in Adults Applying to the Health Committee of a University Hospital in Central Anatolia  
Günsu Deniz Mirza, Mehmet Okka, Enver Mirza, Selman Belviranlı; Konya, Turkey
- 288 The Surgeon's Role in Inducing and Controlling Motion Errors During Intraocular Membrane Peeling Procedures  
Mahmut Dođramacı, David Steel; Essex, Newcastle Upon Tyne, United Kingdom
- 294 Experimental Laboratory Modeling of Choroidal Vasculature: A Study of the Dynamics of Intraoperative Choroidal Hemorrhage during Pars Plana Vitrectomy  
Mahmut Dođramacı, Funda Dikkaya, Fevzi Şentürk, Cengiz Aras; Essex, United Kingdom, İstanbul, Turkey

### Review

- 301 Does Ophthalmology Need Philosophy?  
Dođan Ceyhan, Tekin Yaşar; Nicosia, TRNC, İstanbul, Turkey

### Case Reports

- 308 Traumatic Dislocation of the Globe into the Ethmoid Sinus  
Zafer Onaran, Gökçe Şimşek, Onur Konuk; Kırkkale, Ankara, Turkey
- 313 Lipemia Retinalis Diagnosed Incidentally After Laser Photocoagulation Treatment for Retinopathy of Prematurity  
Taylan Öztürk, Ezgi Karataş Yiğitaslan, Pelin Teke Kısa, Hüseyin Onay, Ali Osman Saatci; İzmir, Turkey
- 317 Challenges in the Diagnosis of Intraocular Lymphoma  
Mahmut Kaya, Ferit Hakan Öner, Banu Lebe, Sermin Özkal, Süleyman Men, Ali Osman Saatci; İzmir, Turkey
- 326 Serpiginous Choroiditis Complicated with Choroidal Neovascular Membrane Detected using Optical Coherence Tomography Angiography: A Case Series and Literature Review  
Asli Perente, Dimitra Kotsiliti, Sergios Taliantzis, Eirini Kanella Panagiotopoulou, Maria Gkika, Irfan Perente, Doukas Dardabounis, Georgios Labiris; Alexandroupoli, Greece

### Letter to the Editor

- 334 Letter to the Editor re: "The Relationship Between Keratoconus Stage and the Thickness of the Retinal Layers"  
Masoud Khorrami-nejad, Mohsen Heirani; Tehran, Iran

### Reply to Letter to the Editor

- 336 Reply to Letter to the Editor re: "The Relationship Between Keratoconus Stage and the Thickness of the Retinal Layers"  
Cemal Özsaygılı, Yener Yıldırım; Kayseri, Turkey

## EDITORIAL

### 2021 Issue 5 at a Glance:

This issue of our journal features 6 original studies, 1 review, 4 case reports, a letter to the editor, and a reply to the letter to the editor, through which researchers from both the national and international communities have furthered our knowledge.

In the first original article of this issue, Erol et al. present their study aiming to identify corneal biomechanical and tomographic factors associated with progression of keratoconus (KC). The authors reported that parameters derived from the second applanation signal of the ocular response analyzer (ORA) were superior to other ORA and Pentacam parameters in predicting KC progression. This study is valuable because it demonstrates that biomechanical properties may be determinants of KC progression and is the first report on this topic. We believe it may serve as an important reference in the follow-up of KC patients (see pages 257-264).

Akbaş et al. conducted a study evaluating the characteristic findings of different corneal foreign bodies on anterior segment optical coherence tomography. Their results make valuable contributions in determining a foreign body's location, depth, and structural characteristics and selecting an appropriate treatment method accordingly for these injuries, which we encounter frequently in our daily practice (see page 265-268).

Karslıoğlu et al. share the results of their comprehensive survey study investigating the effect of the current COVID-19 pandemic on the clinical practice of ophthalmologists in our country. In the midst of this global pandemic, we believe you will read with interest this article containing valuable information and comments regarding the rates at which elective and emergency ophthalmological treatments can be performed, the extent to which ophthalmologists are affected socially, psychologically, and economically, and within the framework of this information, the measures necessary to avoid the disruption of ophthalmology clinical practice (see page 269-281).

In another study, Mirza et al. retrospectively analyzed the data of patients who applied to the Health Board of the Meram Medical Faculty Hospital in Central Anatolia. Based on their evaluation of the frequency and characteristics of pathologies causing blindness in and around the Konya province, the authors reported that most causes of blindness they identified were preventable or treatable diseases. They also drew attention to solutions to this wide-reaching and important public health problem by noting that raising awareness of this issue

would be beneficial in terms of taking the necessary measures (see page 282-287).

In their study to understand the role of the surgeon in the induction and correction of movement errors during vitreoretinal surgical procedures, Dođramacı and Steel aimed to record movement errors at the distal end of 23-gauge pneumatic forceps. To do this, they recorded data for the x, y, and z axes using optical reflector sensors and conducted a comparative analysis. Based on the results of their study, they describe techniques that surgeons new to the profession should use to reduce movement errors and provide valuable tips to use in the future (see pages 288-293).

In another study, Dođramacı et al. used a scale model to investigate the causes of the choroidal hemorrhage that occasionally occurs during surgical procedures. The model is a system consisting of a rubber tube 1 cm wide and 10 cm long and wrapped with special conductive thread. Stress levels in the system were measured under varying systemic intravascular blood pressure, intraocular pressure levels (IOP), and distortion levels. The authors reported that excessive distortion of the globe during surgical procedures may be the main cause of intraoperative choroidal hemorrhage. Other important findings of the study that should be kept in mind are that using a non-expansile ocular tamponade provides better support for the vascular bed, while excessively increasing IOP has a limited effect in mitigating the risk of hemorrhage in the choroidal vessels caused by distortion (see pages 294-300).

Ceyhan and Yaşar provide comprehensive and useful information about philosophy in their review article titled "Does Ophthalmology Need Philosophy?", stating that philosophy offers important intellectual skills and tools that can impart wisdom to the individual and the profession. In this context, the authors emphasized that ophthalmologists need philosophy in a broad range of areas, from contributing to the development of scientific research to defending themselves against professional accusations. In fact, we think you will read with interest this original article, which draws us into the depths of wisdom in a different subject that we live in but do not often bring to conscious thought (see pages 301-307).

In the first case report of this issue, Onaran et al. report a rare case of traumatic dislocation of the globe into the ethmoid sinus. This exciting and educational case presentation is valuable because it demonstrates that successful functional and cosmetic results can be achieved with rapid and appropriate treatment if the globe is displaced but remains intact (see pages 308-312).

## EDITORIAL

In another case report, Öztürk et al. incidentally diagnosed stage 3 lipemia retinalis in the 2-week dilated fundoscopic examination of a preterm infant who underwent laser photocoagulation for stage 3 retinopathy of prematurity, thus emphasizing the importance of careful ophthalmological examinations in premature newborns (see page 313-316).

In their case series of 3 patients, Kaya et al. addresses difficulties in the diagnosis of intraocular lymphoma. The authors note that clinical suspicion is the first step in the early diagnosis of this insidious disease, followed by multimodal imaging methods to support the diagnosis. In addition, they emphasize that after diagnosis, vitreous and retinal biopsy is necessary for oncological treatment and that these procedures can also confirm the diagnosis (see pages 317-325).

In the last case report of this issue, Perente et al. report two patients diagnosed with serpiginous choroiditis (SC), which is a rare, chronic, recurrent, progressive disease of unknown cause. The most common complication of SC is the development of choroidal neovascular membrane (CNV) in 10-35% of cases. The patients in this report also had CNV, and the authors report that they used a new non-invasive imaging method, optical coherence tomography angiography, to establish the diagnosis and treated the patients a series of anti-VEGF injections (see pages 326-333).

In their letter to the editor, Khorrami-nejad and Heirani from Tehran, Iran report that they read with interest a study by Özsaygılı and Yıldırım examining the relationship between KC stages and the thickness of the

retinal layers, but thought there may be deficiencies in the possible mechanisms suggested in the article to explain the changes in the inner nuclear layer and retinal pigment epithelium layer. They state that in addition to the different biochemical, oxidative, genetic, and cellular mechanisms suggested by the authors, these changes may also occur in response to other associated factors, including myopia secondary to KC (see pages 334-335).

In their reply, Özsaygılı and Yıldırım emphasized that patients with myopia greater than 6 diopters and axial length greater than 26 mm were not included in the study due to the possible effect of optical focal deviation caused by high myopia on the retinal layers, and that they analyzed measurements obtained from the more reliable central 1 mm macular area instead of the periphery. Moreover, they stated that neurophysiological explanations were not based on evidence that goes beyond assumption and reiterated their belief that the changes were closely related to the stage of KC disease (see pages 336-337).

**Respectfully on behalf of the Editorial Board,  
Tomris Şengör, MD**





# Superiority of Baseline Biomechanical Properties over Corneal Tomography in Predicting Keratoconus Progression

© Mehmet Akif Erol, © Eray Atalay, © Onur Özalp, © Abdullah Divarçı, © Nilgün Yıldırım

Eskişehir Osmangazi University Faculty of Medicine, Department of Ophthalmology, Eskişehir, Turkey

## Abstract

**Objectives:** To determine corneal biomechanical and tomographic factors associated with keratoconus (KC) progression.

**Materials and Methods:** This study included 111 eyes of 111 KC patients who were followed-up for at least 1 year. Progression was defined as the presence of progressive change between the first two consecutive baseline visits in any single parameter (A, B, or C)  $\geq 95\%$  confidence interval or two parameters  $\geq 80\%$  confidence interval for the KC population evaluated by the Belin ABCD progression display. The eye with better initial tomographic findings was chosen as the study eye. Analyzed Pentacam parameters were maximum keratometry (Kmax), minimum pachymetry (Kmin), central corneal thickness, thinnest corneal thickness, 90° vertical anterior and posterior coma data in Zernike analysis, and Belin Ambrosio Enhanced Ectasia Display Final D value. Corneal hysteresis (CH) and corneal resistance factor (CRF) were analyzed together with the waveform parameters obtained with Ocular Response Analyzer (ORA). Factors related to KC progression were evaluated using t-tests and logistic regression tests. Statistical significance was accepted as  $p < 0.05$ .

**Results:** There were 44 (mean age:  $27.1 \pm 8.5$  years, female: 25) and 67 (mean age:  $31.1 \pm 9.1$  years, female: 36) patients in the progressive and non-progressive groups, respectively. Although Pentacam parameters along with CH and CRF were similar between the two groups, ORA waveform parameter derived from the second applanation signal p2area was statistically significantly lower in the progressive group ( $p = 0.02$ ). Each 100-unit decrease in p2area increased the likelihood of keratoconus progression by approximately 30% in the logistic regression analysis ( $\beta = 0.707$ ,  $p = 0.001$ , model  $r^2 = 0.27$ ).

**Conclusion:** Parameters derived from the second applanation signal of ORA may be superior to conventional ORA parameters and corneal tomography in predicting KC progression.

**Keywords:** Keratoconus, progression, ORA, biomechanics, tomography, topography

## Introduction

Keratoconus (KC) is a progressive ectatic disease with unknown pathogenesis, characterized by thinning and cone-like steepening of the cornea. The general prevalence of KC is 1/2,000, but recent studies using more advanced tomographic/topographic methods have reported rates of 1.5% to 3.6%.<sup>1,2,3</sup> KC often begins in adolescence and usually shows asymmetric involvement.<sup>4,5,6</sup> Although onset seems to occur in the second

decade of life, a Netherlands-based study found that patients with KC were diagnosed at a later age (mean age: 28.3 years).<sup>7</sup> Delayed diagnosis and difficulty in the early detection of progression affect the treatment approach algorithm in progressive KC.

Corneal cross-linking (CXL) therapy was developed to prevent progression of KC and also significantly reduces the need for keratoplasty.<sup>8,9</sup> The decision to perform CXL is based on monitoring of progression in KC patients over 18 years of age,

**Address for Correspondence:** Eray Atalay, Eskişehir Osmangazi University Faculty of Medicine, Department of Ophthalmology, Eskişehir, Turkey  
E-mail: eatalay@ogu.edu.tr **ORCID-ID:** orcid.org/0000-0002-2536-4279

**Received:** 17.10.2020 **Accepted:** 05.11.2020

**Cite this article as:** Erol MA, Atalay E, Özalp O, Divarçı A, Yıldırım N. Superiority of Baseline Biomechanical Properties over Corneal Tomography in Predicting Keratoconus Progression. Turk J Ophthalmol 2021;51:257-264

© Copyright 2021 by Turkish Ophthalmological Association  
Turkish Journal of Ophthalmology, published by Galenos Publishing House.

whereas for pediatric patients the general approach is to perform CXL when the initial diagnosis is made because progression occurs in up to 88% in this group.<sup>10,11</sup>

Although many different parameters are used to detect KC progression, there is no consensus on the definition of progression. Based on the ABCD KC staging system developed by Belin et al.<sup>12</sup>, the Belin ABCD progression display was added to the Pentacam software in 2017, bringing a more systematic new approach to KC progression. This program presents the anterior (A) and posterior (B) radius of curvature in the 3-mm zone centered on the thinnest point of the cornea, the thinnest corneal thickness (TCT) (C), and best corrected visual acuity (D) values within the 80% and 95% confidence intervals of measurement variability in normal and KC eyes. Measurements beyond these variability confidence intervals are interpreted as indicating progression.

This study was conducted to examine the association between progression and baseline tomographic and biomechanical characteristics in KC patients with progression according to Belin ABCD analysis.

### Materials and Methods

This retrospective study included 111 KC patients who were followed up in the corneal unit of the ophthalmology department of Eskişehir Osmangazi University Hospital between 2015 and 2019 and had at least 1 year of follow-up and 3 separate Scheimpflug corneal tomography (Pentacam HR, Oculus Optikgeräte GmbH, Wetzlar, Germany) measurements at intervals of at least 3 months and Ocular Response Analyzer (ORA, Reichert Inc., Depew, NY, USA) measurement at baseline. The study was conducted in accordance with the requirements of the Declaration of Helsinki after obtaining approval from the Eskişehir Osmangazi University Faculty of Medicine Non-invasive Clinical Research Ethics Committee (12.05.2020/07).

KC was diagnosed in the presence of slit-lamp findings such as Fleischer ring, Vogt striae, and apical scar; keratometry values (K1/K2) >48 diopters (D); and corneal tomographic findings consistent with KC such as maximum keratometry (Kmax) >49 D, axial distortion, inferior steepening, irregular astigmatism, abnormal posterior elevation, and abnormal corneal thickness distribution.<sup>1</sup> Patients with history of ocular surgery including CXL, penetrating keratoplasty, deep anterior lamellar keratoplasty, and cataract surgery, patients with corneal scarring and ocular surface problems, patients under 18 years of age, and patients with no potential for progression due to stage 4 (end-stage) KC according to topographic KC classification (TKC) were excluded.

Pentacam measurements performed at the patient's first two consecutive visits at an interval of 3±1 months were evaluated separately on the Belin ABCD KC progression display. Progression was defined as any one of the parameters A,

B, and C on this screen exceeding the ≥95% confidence interval for the KC patient population (solid red line) or any two of the parameters exceeding the ≥80% confidence interval for the KC patient population (dotted red line). We did not evaluate criterion D, visual acuity, because studies have shown it is not a valuable finding in terms of progression.<sup>11,13</sup> One eye of each patient was included in the study. Patients with progression in either eye were evaluated on a case basis as progression. In patients with unilateral progression, the progressive eye was included in the analysis; for patients with bilateral progression or no progression, the eye with better baseline values was included. As is routine practice in our clinic, Pentacam and ORA readings were performed at least 1 hour after removing contact lenses.

Pentacam parameters analyzed in relation to progression were Kmax, TCT, central corneal thickness (CCT), 90° vertical anterior and posterior coma, and Belin Ambrosio Enhanced Ectasia Display Final D value (BAD D). ORA parameters analyzed were corneal hysteresis (CH), corneal resistance factor (CRF) and applanation waveform parameters (p1area, p2area, uslope1, uslope2, dslope1, dslope2, w1, w2, h1, h2) (Table 1).

### Statistical Analysis

IBM SPSS version 22.0 (IBM Corp, Armonk, NY, USA) was used for statistical analyses. Independent groups t-test and univariate and multivariate logistic regression analysis were used to evaluate factors associated with KC progression. Variables that showed significance in univariate logistic regression (p<0.05) and did not show multicollinearity were included in the multivariate model. Paired samples t-test was used to compare initial and final examinations within groups. A p value <0.05 was considered statistically significant.

### Results

The mean age of the 111 patients included in the study was 29.4±9.0 years, 50 (45%) were male, and the frequency of progression within the mean follow-up period of 26.4±12.0 months was 39.6% (n=44). The male to female ratio in the progression and non-progression groups was 25/19 and 36/31, respectively, and the difference was not statistically

**Table 1. Ocular Response Analyzer waveform parameter descriptions**

Parameter	Definitions
p1area/p2area	Area of the upper 75% of the peak of applanation waves 1 and 2
uslope1/uslope2	Upward slope in the upper 75% of applanation waves 1 and 2
dslope1/dslope2	Downward slope in the upper 75% of applanation waves 1 and 2
w1/w2	Width of applanation waves 1 and 2 at 25% elevation
h1/h2	Height of applanation waves 1 and 2 from 25% elevation to peak

significant ( $p=0.75$ ). The progression group was younger than the non-progression group (mean age  $27.1\pm 8.5$  and  $31.1\pm 9.1$ , respectively,  $p=0.02$ ). The mean follow-up time was longer in the progression group ( $29.5\pm 10.9$  and  $24.4\pm 11.7$  months, respectively,  $p=0.03$ ). During follow-up, there was a statistically significant increase in Kmax and mean keratometry (Kmean) values ( $p<0.05$ ) and marginally significant decreases in CCT and TCT in the progression group (Figure 1). These four parameters were stable in the non-progression group during follow-up (Figure 1).

The TKC stages at initial examination of patients in the progression and non-progression groups are shown in Table 2. According to TKC staging, 63.6% (28/44) of patients with progression and 58.2% (39/67) of those without progression were stage 2 or 3. The ABC criteria indicating progression in patients in the progression group were, in order of frequency, B (84%), A (77%), and C (64%) (Figure 2).

The two groups had similar initial mean values for Kmax, Kmean, TCT, CCT, 90 vertical anterior and posterior coma, final BAD D, minimum/maximum/mean Ambrosio-related thickness (ART Min/Max/Avg, respectively) ( $p>0.05$  for all; Table 3). Although the mean initial CRF and CH values were also similar in both groups ( $p>0.05$ ), the p2area, uslope2, dslope1, h1, and h2 values obtained from the waveform were significantly lower in the progression group compared to the non-progression group ( $p=0.026$ ,  $0.036$ ,  $0.021$ ,  $0.034$ , and  $0.029$ , respectively; Table 3).

In the univariate logistic regression analysis examining tomographic and biomechanical factors associated with KC progression with correction for age, sex, Kmax, and follow-up time, none of the initial Pentacam variables were associated with progression (Table 4). However, progression was associated with the ORA parameters h2 (for each 10-unit increase, odds ratio [OR]: 1.06, 95% CI: 1.01-1.11,  $p=0.03$ ) and p2area (for each 100-unit increase, OR: 1.08, 95% CI: 1.01-1.15,  $p=0.02$ ; Table 4) derived from the second applanation wave. In the same analysis, age (for each year increase, OR: 1.07,  $p=0.01$ ) and follow-up period (for each year increase, OR: 1.60,  $p=0.03$ ; Table 4) were also associated with progression. In the multivariate model, age, follow-up time, and p2area were found to be independent determinants of progression (Table 4). Superimposition of the ORA applanation curves of patients with and without progression showed that patients with progression had a relatively earlier applanation in the first applanation and

later recovery in the second applanation, and lower height in both the first and second applanation curves compared to patients without progression (Figure 3).

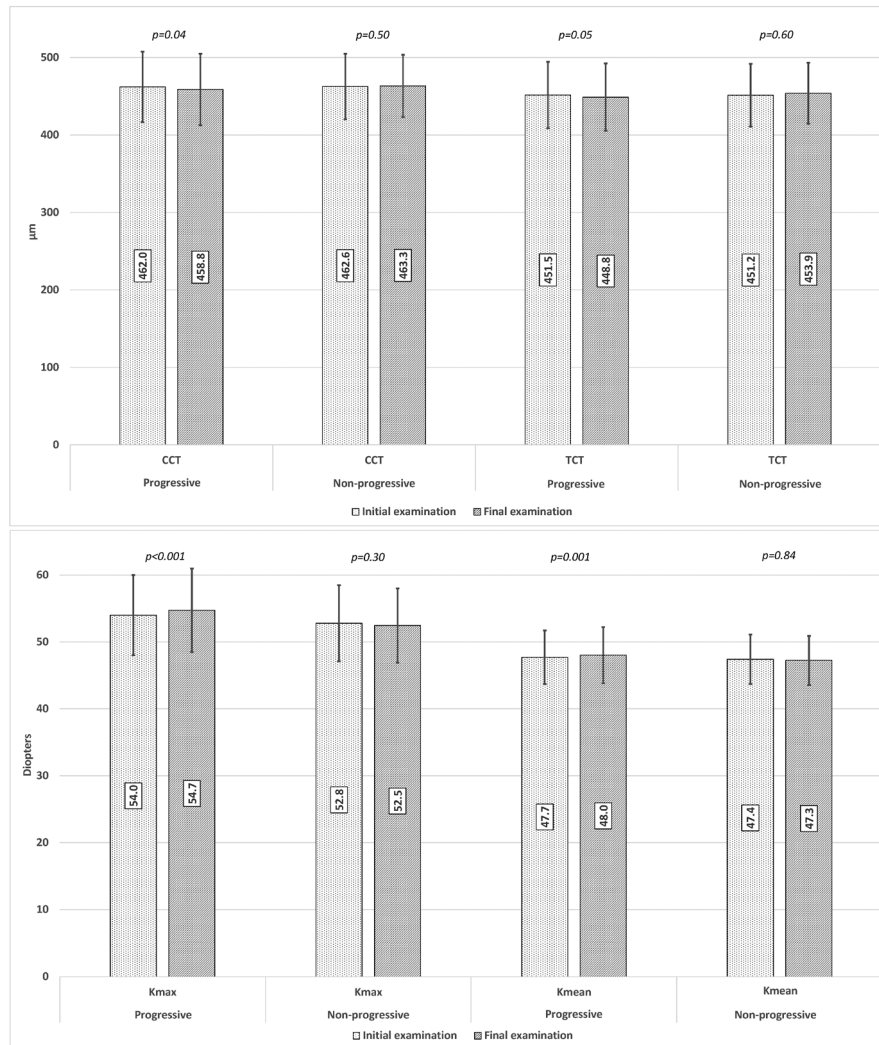
### Discussion

In this study, progression defined according to parameters A, B, and C on the Belin ABCD progression display was observed in 39.6% ( $n=44$ ) of the patients. In patients with progression, we observed that Kmax and Kmean increased by 1.0 D and 0.5 D, respectively, and CCT and TCT decreased by approximately 5  $\mu\text{m}$  during follow-up (Figure 1). The parameter most effective in determining progression was posterior surface radius of curvature (criterion B, 84%), followed by anterior surface radius of curvature (criterion A, 77%) and thinnest pachymetry value (criterion C, 64%) (Figure 2). KC progression was associated with younger age (for each additional year, OR: 1.08,  $p=0.006$ ), longer follow-up time (for each additional year, OR: 1.78,  $p=0.01$ ), and lower p2area on initial ORA measurement (for each 100-unit increase, OR: 1.07,  $p=0.01$ ) (Table 3).

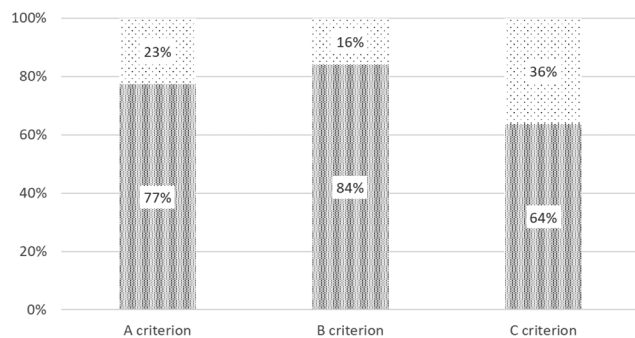
According to the 2015 global consensus report on KC and ectatic diseases created by Delphi panel, progression was defined as meeting at least two of three criteria (steepening of the anterior corneal surface, steepening of the posterior corneal surface, and corneal thinning and/or an increase in the rate of thickness change from the peripheral cornea to the thinnest point), but it was not clearly stated what amount of change in these parameters should be considered progression.<sup>11</sup> Many topographic/tomographic parameters are used in routine progression monitoring. The most important of these, Kmax, represents only the anterior surface of the cornea but does not provide information about the posterior surface, may vary in patients using hard gas-permeable contact lenses, and has been reported to remain unchanged or even decrease in progression, resulting in controversy regarding its use in the follow-up of progression and CXL effectiveness.<sup>14,15,16,17</sup> This idea is supported by our finding that the radius of curvature of the posterior corneal surface (criterion B) was a more frequent sign of progression than the anterior surface radius of curvature radius (criterion A) (84% and 77%, respectively, Figure 2). In a meta-analysis examining changes in other parameters used in progression monitoring during the natural course of KC, it was reported that best corrected visual acuity and sphere/cylinder values did not show statistically significant changes during the follow-up period and thus its use in follow-up would not provide meaningful results.<sup>18</sup>

The Belin ABCD progression display offers a different perspective on progression based on changes in the ABCD staging system developed by Belin et al.<sup>12</sup> Unlike the Amsler-Krumeich classification, it also takes into account the posterior corneal surface, evaluates not the entire cornea but the central cone where the main changes are seen (3-mm area centered on the thinnest point of the cornea), presents separate ratings on

	TKC stage, n (%)				p value
	0	1	2	3	
<b>No progression</b>	13 (19.4%)	15 (22.4%)	28 (41.8%)	11 (16.4%)	0.10
<b>Progression</b>	2 (4.5%)	14 (31.8%)	17 (38.6%)	11 (25.0%)	



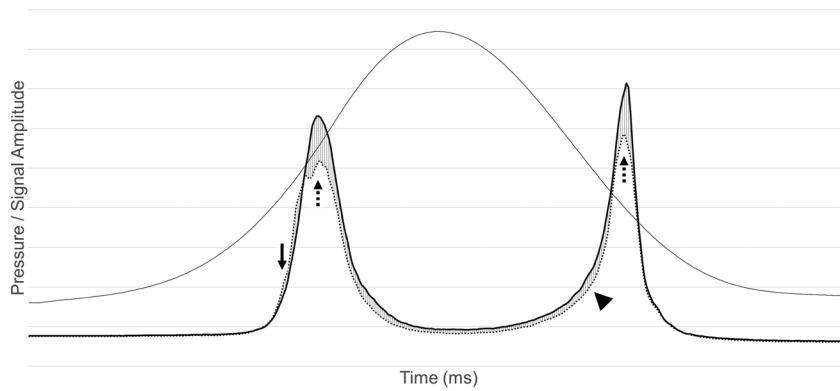
**Figure 1.** Analyses of corneal thickness and keratometry values according to progression status  
 CCT: Central corneal thickness, TCT: Thinnest corneal thickness, Kmax: Maximum keratometry value, Kmean: Mean keratometry value



**Figure 2.** Frequency of A, B, and C parameters exceeding the  $\geq 95\%$  confidence interval for one criterion or  $\geq 80\%$  in any two criteria simultaneously on the Belin ABCD progression display according to the first two visits (shaded area, proportion of cases)

the basis of 4 parameters, and is consistent with the criteria proposed in the global consensus report.<sup>15,16,17</sup> Kösekahya et al.<sup>19</sup> compared the Belin ABCD progression display with traditional criteria (Kmax, CCT, and anterior/posterior elevation changes) in the detection of progression and showed that the Belin ABCD progression display could provide an acceptable level of differentiation.

In the literature, parameters reported to have predictive value in KC progression include young age,<sup>20,21,22,23</sup> low TCT,<sup>24</sup> high Kmean,<sup>24</sup> high anterior Kmax<sup>18,23</sup> and posterior Kmax,<sup>25</sup> high central posterior<sup>24</sup> or anterior<sup>20</sup> elevation, index of surface variance (ISV),<sup>26</sup> high index of height decentration (IHD),<sup>26</sup> and vertical coma.<sup>25</sup> The fact that none of the initial corneal tomography parameters had predictive value for progression in this study whereas some initial biomechanical parameters showed



**Figure 3.** Superimposition of the ORA applanation curves of patients with and without progression shows that patients with progression (dotted line) had a relatively earlier applanation (solid arrow) in the first applanation and later recovery (arrowhead) in the second applanation. In addition, the height of the first and second applanation curves were lower in patients with progression (dotted arrows) than those without progression

Table 3. Tomographic and biomechanical parameter values and significance levels according to progression status			
Parameter	No progression	Progression	
	Mean ± SD	Mean ± SD	P value
Kmax	52.8±5.7	54.0±6.0	0.29
Kmean	47.4±3.7	47.7±4.0	0.70
CCT	462.6±42.4	462.0±45.4	0.94
TCT	451.3±40.5	451.5±42.8	0.97
Anterior vertical 90° coma	-1.38±1.04	-1.67±0.90	0.14
Posterior vertical 90° coma	0.36±0.28	0.44±0.22	0.12
Final BAD D	7.1±3.7	7.5±3.6	0.51
ART Min	388±189	402±236	0.74
ART Max	194±81	179±61	0.30
ART Avg	276±109	263±94	0.53
IOPg	10.5±3.5	9.7±3.2	0.28
IOPcc	14.7±3.1	14.3±2.4	0.51
CRF	6.5±1.6	6.1±1.8	0.22
CH	7.6±1.2	7.4±1.3	0.34
p1area	3166±1198	2753±1047	0.07
p2area	2424±984	2026±762	0.02
uslope1	46.8±18.7	40.4±16.2	0.07
uslope2	57.2±31.6	44.8±26.1	<b>0.04</b>
dslope1	28.5±9.9	24.1±9.1	<b>0.02</b>
dslope2	29.0±13.1	24.7±13.8	0.10
w1	20.4±3.7	21.1±4.3	0.38
w2	18.6±5.3	19.9±5.7	0.24
h1	337±103	294±100	<b>0.03</b>
h2	306±108	261±95	<b>0.03</b>

Kmax: Maximum keratometry value, Kmean: Mean keratometry value, CCT: Central corneal thickness, TCT: Thinnest corneal thickness, Final BAD D: Belin Ambrosio Enhanced Ectasia Display Final D, ART Min/Max/Avg: Minimum/maximum/average Ambrosio relational thickness, CRF: Corneal resistance factor, CH: Corneal hysteresis

Table 4. Univariate and multivariate model analysis and significance levels of parameters in the study				
Variable	Univariate model <sup>‡</sup>		Multivariate model	
	OR (95% CI)	p value	OR (95% CI)	p value
Age (1 year)*	1.07 (1.02-1.13)	<b>0.01</b>	1.08 (1.02-1.14)	<b>0.006</b>
Sex (male)	0.79 (0.34-1.82)	0.58		
Follow-up period (1 year) <sup>‡</sup>	1.60 (1.04-2.47)	<b>0.03</b>	1.78 (1.14-2.75)	<b>0.01</b>
Kmax (1 D) <sup>‡</sup>	1.03 (0.96-1.10)	0.46		
TCT (10 µm) <sup>‡</sup>	1.007 (0.99-1.02)	0.30		
BAD D (1 unit) <sup>‡</sup>	0.90 (0.69-1.17)	0.41		
ART Max (10 units) <sup>‡</sup>	1.00 (0.99-1.01)	0.85		
CRF (1 unit)*	1.15 (0.85-1.54)	0.36		
CH (1 unit)*	1.17 (0.80-1.69)	0.42		
p1area (100 units)*	1.05 (0.99-1.10)	0.08		
p2area (100 units)*	1.08 (1.01-1.15)	<b>0.02</b>	1.07 (1.01-1.13)	<b>0.01</b>
uslope1 (10 units)*	1.14 (0.88-1.46)	0.32		
uslope2 (10 units)*	1.15 (0.98-1.35)	0.08		
dslope1 (10 units)*	1.52 (0.95-2.46)	0.08		
dslope2 (10 units)*	1.30 (0.92-1.84)	0.14		
w1 (10 units) <sup>‡</sup>	1.06 (0.35-3.17)	0.92		
w2 (10 units) <sup>‡</sup>	1.44 (0.65-3.18)	0.37		
h1 (10 units)*	1.05 (1.00-1.10)	0.08		
h2 (10 units)*	1.06 (1.01-1.11)	<b>0.03</b>		

\*Decrease, †Increase, ‡Univariate models were corrected for age, sex, Kmax, and follow-up time. OR: Odds ratio, CI: Confidence interval, Kmax: Maximum keratometry value, TCT: Thinnest corneal thickness, BAD D: Belin Ambrosio Enhanced Ectasia Display Final D, ART Max: Maximum Ambrosio relational thickness, CRF: Corneal resistance factor, CH: Corneal hysteresis

significant differences between the groups supports the argument that the primary derangement in KC is biomechanical and that tomographic changes follow biomechanical disruption.<sup>27,28,29</sup> Age is a confirmed surrogate for corneal biomechanics<sup>30</sup> and was a significant predictive of progression in previous studies as well as our own, which strengthens the likelihood that biomechanical changes in KC are more important in the early stage.

The non-significance of CRF and CH, the basic ORA parameters, in our study while some waveform parameters showed significance requires explanation. CRF and CH are calculated based on the pressure difference between the first and second applanations, and CRF is calculated using a coefficient that emphasizes the first applanation. Although these two parameters are lower in eyes with KC, it has been reported that they have low diagnostic sensitivity and specificity and their ranges may overlap in normal and KC eyes.<sup>31</sup> Although the importance of the ORA waveform parameters is still not clearly understood, various assumptions have been put forward.<sup>32</sup>  $p1area$  and  $p2area$  are proportional to the time required for the cornea to transition from its natural convex shape to concave and back again;  $w1$  and  $w2$  (applanation width) are proportional to the transition speed of the cornea between convex and concave forms,  $h1$  and  $h2$  (applanation height) are proportional to the amount of light reflected from the corneal surface to the detector during applanation, and lower values for these parameters are suggested to be associated with a weaker corneal structure.<sup>33,34,35</sup> In parallel with the findings of our study, the presence of other studies demonstrating that waveform parameters have greater diagnostic value than pressure-based parameters (CRF and CH) in eyes with early-stage KC suggests that these parameters may be better biomechanical indicators.<sup>36,37</sup> In another study evaluating biomechanical changes with ORA before and after CXL,  $p2area$ , which is the most valuable predictive parameter in progression, was reported to be the parameter that best demonstrates biomechanical changes after CXL, but there was no significant change in CRF and CH values.<sup>38</sup> In a study by Küçümen et al.<sup>39</sup> examining changes in CRF and CH after CXL, no statistically significant change was observed in CH in the early or late postoperative period, while the change in CRF showed early significance that disappeared in the late postoperative period.

In our study, when ORA curves were averaged for all eyes with and without progression, we observed that corneas showing progression flattened earlier, started to recover later, and had significantly lower wave height for both applanations. Earlier applanation of a biomechanically weaker cornea is a finding that can be explained biologically. On the other hand, the air puff continues for a short while after the first applanation and the cornea becomes concave, and the transition back to the cornea's normal state seems to be prolonged in progressive eyes. This may also be due to the relationship between the maximum

concave radius of curvature, which is also a parameter of Corvis ST, and biomechanical strength. This radius is more resistant to deformation and has higher values in biomechanically stiff eyes.<sup>31</sup> In other words, a weak cornea forms a deeper concavity when subjected to the air puff and thus takes longer to normalize, while a stronger cornea forms a shallower concavity and has a shorter normalization.

#### Study Limitations

One of the limitations of this study may be the exclusion of Belin ABCD progression criterion D (visual acuity) from our evaluation. However, although progression has been associated with a decrease in visual acuity in many articles in the literature, the widespread view in recent years is that uncorrected and best corrected visual acuity are not significant criteria for demonstrating progression.<sup>11,18</sup> Evaluating progression according to a change based on a single initial visit would increase variability and thus the false positivity rate; therefore, it has been stipulated that change based on two consecutive initial visits must be seen to be called progression. Since patients under the age of 18 were excluded from this study, our findings may not be valid for pediatric cases. Although the progression group had longer follow-up, statistical correction was made for the follow-up period in our analysis of predictive factors. Some patients included in the study used hard gas permeable or soft contact lenses. Although corneal contact lenses vary according to fitting choice, they may cause changes in the curvature of the anterior and posterior surfaces due to the mechanical effect and the hypoxia they cause, and even if the contact lenses are removed, the stabilization process may take several weeks.<sup>40,41</sup> Because it is not possible to wait this long in practice, measurements were obtained from our patients at least 1 hour after lens removal, as per routine practice in our clinic. The extent to which the ORA device performs a true biomechanical assessment is controversial, as the pressure and waveform-based parameters obtained with the ORA are seriously affected by the geometric properties of the cornea (e.g., thickness) and by intraocular pressure. In addition, the ORA has variable air puff pressure and utilizes an infrared camera that can provide low-resolution data, which are shortcomings compared to the Corvis ST.<sup>31</sup> For this reason, conducting similar studies with new generation devices such as Corvis ST and Brillouin spectroscopy, which provide advanced biomechanical evaluation, will better elucidate the extent to which biomechanical properties are associated with progression.

#### Conclusion

In conclusion, this study demonstrates that younger age and biomechanical properties may be indicators of future progression and that tomographic parameters follow biomechanical changes. This study is the first report showing that the biomechanical parameters obtained with the ORA device may be important in predicting the progression of KC.

## Ethics

**Ethics Committee Approval:** Ethics committee approval was obtained from Eskişehir Osmangazi University Non-Interventional Clinical Research Ethics Committee with the decision no. 07 dated 12.05.2020.

**Informed Consent:** Retrospective study.

**Peer-review:** Externally peer reviewed.

## Authorship Contributions

Concept: E.A., M.A.E., Design: E.A., M.A.E., N.Y., Data Collection or Processing: M.A.E., O.Ö., A.D., Analysis or Interpretation: E.A., M.A.E., N.Y., Literature Search: E.A., M.A.E., N.Y., A.D., Writing: E.A., M.A.E., O.Ö.

**Conflict of Interest:** No conflict of interest was declared by the authors.

**Financial Disclosure:** The authors declared that this study received no financial support.

## References

- Rabinowitz YS. Keratoconus. *Surv Ophthalmol.* 1998;42:297-319.
- Shehadeh MM, Diakonis VF, Jalil SA, Younis R, Qadoumi J, Al-Labadi L. Prevalence of Keratoconus Among a Palestinian Tertiary Student Population. *Open Ophthalmol J.* 2015;9:172-176.
- Hashemi H, Heydarian S, Yekta A, Ostadimoghaddam H, Aghamirsalim M, Derakhshan A, Khabazkhoob M. High prevalence and familial aggregation of keratoconus in an Iranian rural population: a population-based study. *Ophthalmic Physiol Opt.* 2018;38:447-455.
- Jonas JB, Nangia V, Matin A, Kulkarni M, Bhojwani K. Prevalence and associations of keratoconus in rural maharashtra in central India: the central India eye and medical study. *Am J Ophthalmol.* 2009;148:760-765.
- McGhee CN, Kim BZ, Wilson PJ. Contemporary Treatment Paradigms in Keratoconus. *Cornea.* 2015;34(Suppl 10):S16-23.
- Kennedy RH, Bourne WM, Dyer JA. A 48-year clinical and epidemiologic study of keratoconus. *Am J Ophthalmol.* 1986;101:267-273.
- Godefrooij DA, de Wit GA, Uiterwaal CS, Imhof SM, Wisse RP. Age-specific Incidence and Prevalence of Keratoconus: A Nationwide Registration Study. *Am J Ophthalmol.* 2017;175:169-172.
- Sandvik GF, Thorsrud A, Raen M, Ostern AE, Saethre M, Drolsum L. Does Corneal Collagen Cross-linking Reduce the Need for Keratoplasties in Patients With Keratoconus? *Cornea.* 2015;34:991-995.
- Godefrooij DA, Gans R, Imhof SM, Wisse RP. Nationwide reduction in the number of corneal transplantations for keratoconus following the implementation of cross-linking. *Acta Ophthalmol.* 2016;94:675-678.
- Chatzis N, Hafezi F. Progression of keratoconus and efficacy of pediatric [corrected] corneal collagen cross-linking in children and adolescents. *J Refract Surg.* 2012;28:753-758.
- Gomes JA, Tan D, Rapuano CJ, Belin MW, Ambrosio R, Jr., Guell JL, Malecaze F, Nishida K, Sangwan VS, Group of Panelists for the Global Delphi Panel of K, Ectatic D. Global consensus on keratoconus and ectatic diseases. *Cornea.* 2015;34:359-369.
- Belin MW, Meyer JJ, Duncan JK, Gelman R, Borgstrom M, Ambrósio JR. Assessing Progression of Keratoconus and Cross-linking Efficacy: The Belin ABCD Progression Display. *Int J Kerat Ect Cor Dis.* 2017;6:1-10.
- Zadnik K, Barr JT, Edrington TB, Everett DF, Jameson M, McMahon TT, Shin JA, Sterling JL, Wagner H, Gordon MO. Baseline findings in the Collaborative Longitudinal Evaluation of Keratoconus (CLEK) Study. *Invest Ophthalmol Vis Sci.* 1998;39:2537-2546.
- Duncan JK, Belin MW, Borgstrom M. Assessing progression of keratoconus: novel tomographic determinants. *Eye Vis (Lond).* 2016;3:6.
- Mahmoud AM, Nunez MX, Blanco C, Koch DD, Wang L, Weikert MP, Frueh BE, Tappeiner C, Twa MD, Roberts CJ. Expanding the cone location and magnitude index to include corneal thickness and posterior surface information for the detection of keratoconus. *Am J Ophthalmol.* 2013;156:1102-1111.
- de Sanctis U, Loiacono C, Richiardi L, Turco D, Mutani B, Grignolo FM. Sensitivity and specificity of posterior corneal elevation measured by Pentacam in discriminating keratoconus/subclinical keratoconus. *Ophthalmology.* 2008;115:1534-1539.
- Tomidokoro A, Oshika T, Amano S, Higaki S, Maeda N, Miyata K. Changes in anterior and posterior corneal curvatures in keratoconus. *Ophthalmology.* 2000;107:1328-1332.
- Ferdi AC, Nguyen V, Gore DM, Allan BD, Rozema JJ, Watson SL. Keratoconus Natural Progression: A Systematic Review and Meta-analysis of 11 529 Eyes. *Ophthalmology.* 2019;126:935-945.
- Kosekahya P, Caglayan M, Koc M, Kiziltoprak H, Tekin K, Atilgan CU. Longitudinal Evaluation of the Progression of Keratoconus Using a Novel Progression Display. *Eye Contact Lens.* 2019;45:324-330.
- Choi JA, Kim MS. Progression of keratoconus by longitudinal assessment with corneal topography. *Invest Ophthalmol Vis Sci.* 2012;53:927-935.
- Ahn SJ, Kim MK, Wee WR. Topographic progression of keratoconus in the Korean population. *Korean J Ophthalmol.* 2013;27:162-166.
- Wagner H, Barr JT, Zadnik K. Collaborative Longitudinal Evaluation of Keratoconus (CLEK) Study: methods and findings to date. *Cont Lens Anterior Eye.* 2007;30:223-232.
- Kato N, Negishi K, Sakai C, Tsubota K. Baseline factors predicting the need for corneal crosslinking in patients with keratoconus. *PLoS One.* 2020;15:e0231439.
- Hamilton A, Wong S, Carley F, Chaudhry N, Biswas S. Tomographic indices as possible risk factors for progression in pediatric keratoconus. *J AAPOS.* 2016;20:523-526.
- Tellouck J, Touboul D, Santhiago MR, Tellouck L, Paya C, Smadja D. Evolution Profiles of Different Corneal Parameters in Progressive Keratoconus. *Cornea.* 2016;35:807-813.
- Kanellopoulos A, Moustou V, Asimellis G. Evaluation of visual acuity, pachymetry and anterior-surface irregularity in keratoconus and crosslinking intervention follow-up in 737 cases. *J Kerat Ect Cor Dis.* 2013;2:95-103.
- Roberts C. Symposium on Corneal Cross-Linking: Current Status and Future Perspectives. ESCRS/EuCornea. Viyana; 2018.
- Piñero DP, Alio JL, Barraquer RI, Michael R, Jiménez R. Corneal biomechanics, refraction, and corneal aberrometry in keratoconus: an integrated study. *Invest Ophthalmol Vis Sci.* 2010;51:1948-1955.
- Roberts CJ, Dupps WJ Jr. Biomechanics of corneal ectasia and biomechanical treatments. *J Cataract Refract Surg.* 2014;40:991-998.
- Wisse RPL, Simons RWP, van der Vossen MJB, Muijzer MB, Soeters N, Nuijts RMMA, Godefrooij DA. Clinical Evaluation and Validation of the Dutch Crosslinking for Keratoconus Score. *JAMA Ophthalmol.* 2019;137:610-616.
- E Esporcatte LPG, Salomão MQ, Lopes BT, Vinciguerra P, Vinciguerra R, Roberts C, Elsheikh A, Dawson DG, Ambrósio R Jr. Biomechanical diagnostics of the cornea. *Eye Vis (Lond).* 2020;7:9.
- Kotecha A. What biomechanical properties of the cornea are relevant for the clinician? *Surv Ophthalmol.* 2007;52(Suppl 2):109-114.
- Schweitzer C, Roberts CJ, Mahmoud AM, Colin J, Maurice-Tison S, Keratret J. Screening of forme fruste keratoconus with the ocular response analyzer. *Invest Ophthalmol Vis Sci.* 2010;51:2403-2410.
- Roberts CJ. Concepts and misconceptions in corneal biomechanics. *J Cataract Refract Surg.* 2014;40:862-869.
- Mikielewicz M, Kotliar K, Barraquer RI, Michael R. Air-pulse corneal applanation signal curve parameters for the characterisation of keratoconus. *Br J Ophthalmol.* 2011;95:793-798.
- Galletti JD, Ruiseñor Vázquez PR, Fuentes Bonthoux F, Pfortner T, Galletti JG. Multivariate Analysis of the Ocular Response Analyzer's Corneal Deformation Response Curve for Early Keratoconus Detection. *J Ophthalmol.* 2015;2015:496382.
- Ventura BV, Machado AP, Ambrósio R Jr, Ribeiro G, Araújo LN, Luz A, Lyra JM. Analysis of waveform-derived ORA parameters in early forms of keratoconus and normal corneas. *J Refract Surg.* 2013;29:637-643.

38. Spoerl E, Terai N, Scholz F, Raiskup F, Pillunat LE. Detection of biomechanical changes after corneal cross-linking using Ocular Response Analyzer software. *J Refract Surg.* 2011;27:452-457.
39. K uiimen RB, ahan B, Yıldıırım CA, ifti F. Evaluation of Corneal Biomechanical Changes After Collagen Crosslinking in Patients with Progressive Keratoconus by Ocular Response Analyzer. *Turk J Ophthalmol.* 2018;48:160-165.
40. Soeters N, Visser ES, Imhof SM, Tahzib NG. Scleral lens influence on corneal curvature and pachymetry in keratoconus patients. *Cont Lens Anterior Eye.* 2015;38:294-297.
41. Tsai PS, Dowidar A, Naseri A, McLeod SD. Predicting time to refractive stability after discontinuation of rigid contact lens wear before refractive surgery. *J Cataract Refract Surg.* 2004;30:2290-2294.





# Retrospective Evaluation of Corneal Foreign Bodies with Anterior Segment Optical Coherence Tomography

Elif Akbaş, Özlem Barut Selver, Melis Palamar

Ege University Faculty of Medicine, Department of Ophthalmology, İzmir, Turkey

## Abstract

**Objectives:** To assess the anterior segment optical coherence tomography (AS-OCT) findings of various types of corneal foreign bodies.

**Materials and Methods:** The medical records of patients with corneal foreign body were retrospectively analyzed. Patients who underwent anterior segment photography and Spectralis AS-OCT (Heidelberg Engineering GmbH, Germany) imaging were included.

**Results:** The AS-OCT findings of 22 eyes of 20 patients with corneal foreign body were reviewed. The mean age was  $34.9 \pm 14.98$  years (range, 15-71) with a female/male ratio of 4/16. The mean best corrected visual acuity at presentation was  $0 \pm 0$  LogMAR (range, 0-0). There were 18 metallic, 3 organic (chestnut burr), and 1 chemical clay foreign bodies. The metal materials demonstrated hyperreflectivity with a mirror effect. Chemical clay, which is an opaque material, had a hyperreflective appearance. Chestnut burr is an organic foreign body with a feather-like pattern and was not detected with AS-OCT.

**Conclusion:** AS-OCT is a valuable non-invasive tool to define the characteristics of foreign bodies, as well as decide the proper treatment method and monitor patients with corneal foreign bodies.

**Keywords:** Cornea, anterior segment optical coherence tomography, trauma, foreign body

## Introduction

Ocular injuries are one of the most important eye-related emergencies.<sup>1</sup> Although they can often be prevented with the use of safety glasses, the conscious use of such equipment is still uncommon.<sup>2,3</sup> Ocular injuries are more common among males and are usually a result of work or home accidents.<sup>4</sup> Most ocular injuries are mild in nature (e.g., corneal abrasions, periorbital contusions, and lacerations) and do not lead to permanent visual impairment.<sup>5,6</sup> The majority of emergency admissions for ocular injury are due to corneal foreign bodies, which are characteristically painful.<sup>6,7</sup> In addition to pain, corneal foreign body should be considered in every patient with a history of trauma associated with eye redness, watering, decreased visual acuity, photophobia, and foreign body sensation.<sup>8</sup> A meticulous slit-lamp examination together with a thorough clinical history

including risk factors and exposure are important for accurate diagnosis and treatment.<sup>8</sup>

While superficial corneal foreign bodies present a low risk of complications and sequelae, the risk with deeply embedded foreign bodies varies depending on factors such as the size, depth, and type of foreign body.<sup>9</sup> Deep corneal foreign bodies require more careful handling due to the risk of perforation in particular.<sup>10</sup> Under certain conditions, foreign body type and depth cannot be clearly discerned on slit-lamp examination, and inappropriate interventions to remove deep corneal foreign bodies may result in corneal perforation.<sup>11</sup>

With the rapid technological advancement in ophthalmology, optical coherence tomography (OCT) has become routinely used in most clinics. Anterior segment OCT (AS-OCT) allows the detailed objective evaluation of the anterior segment (angle, cornea, sclera).<sup>10</sup> AS-OCT examination of a healthy cornea shows

**Address for Correspondence:** Melis Palamar, Ege University Faculty of Medicine, Department of Ophthalmology, İzmir, Turkey

E-mail: melispalamar@hotmail.com **ORCID-ID:** orcid.org/0000-0002-2494-0131

**Received:** 15.06.2020 **Accepted:** 24.11.2020

**Cite this article as:** Akbaş E, Barut Selver Ö, Palamar M. Retrospective Evaluation of Corneal Foreign Bodies with Anterior Segment Optical Coherence Tomography. Turk J Ophthalmol 2021;51:265-268

all layers of the cornea with a highly reflective tear film over the epithelium.<sup>12</sup>

There are few studies in the literature reporting on the AS-OCT imaging of corneal foreign bodies.<sup>13,14,15,16,17</sup> In this study, we aimed to evaluate corneal foreign bodies with different characteristics using AS-OCT and to investigate their characteristic findings.

## Materials and Methods

The medical records of patients with corneal foreign bodies who presented to our center in 2019 were reviewed retrospectively. Patients who were diagnosed as having a corneal foreign bodies but whose records did not include anterior segment photographs and AS-OCT (Heidelberg Engineering GmbH, Germany) imaging were excluded. The study was approved by the Ege University Faculty of Medicine Ethics Committee and conducted in accordance with the Declaration of Helsinki.

The patients' medical records were examined in detail, including their best corrected visual acuity (BCVA), anterior and posterior segment examination findings, anterior segment photographs, and AS-OCT imaging. The AS-OCT device used provides high-resolution anterior segment imaging, with 16 mm spectral-domain OCT scanning for dual-angle imaging.

### Statistical Analysis

Descriptive statistical analysis of the study data was performed using SPSS 21.0 software (IBM Corp, Armonk, NY, USA).

## Results

The study included 20 eyes of 20 patients with corneal foreign body who underwent anterior segment photography and anterior segment optical coherence tomography. All of the patients were admitted within 72 hours of the incident.

Their mean age was  $34.9 \pm 14.98$  years (range, 15-71) and the female/male ratio was 4/16. Corneal foreign bodies were unilateral in 18 patients and bilateral in 2 patients. The mean baseline BCVA of the eyes in the study sample was  $0 \pm 0$  LogMAR (range, 0-0). In terms of their type, 18 of the corneal

foreign bodies were metallic, 3 were organic (hairy chestnut spines), and 1 was a chemical clay substance.

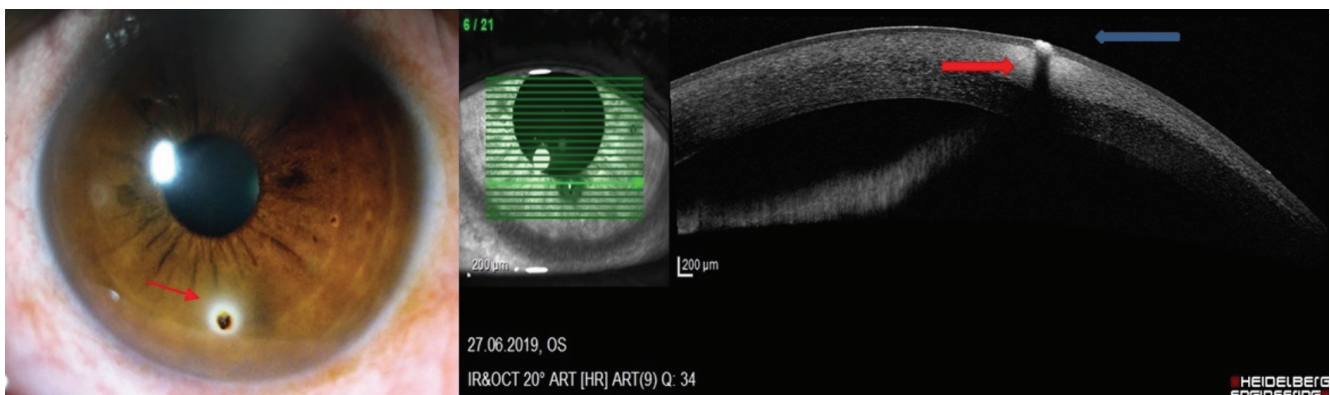
In our evaluation of the AS-OCT results, we observed that metal foreign bodies had hyperreflective properties and caused a mirroring effect (Figure 1). The opaque chemical clay material also had a hyperreflective appearance like the metal objects (Figure 2). However, the chestnut spines were hair-like in nature and were not detected on AS-OCT or have any characteristic AS-OCT findings (Table 1).

## Discussion

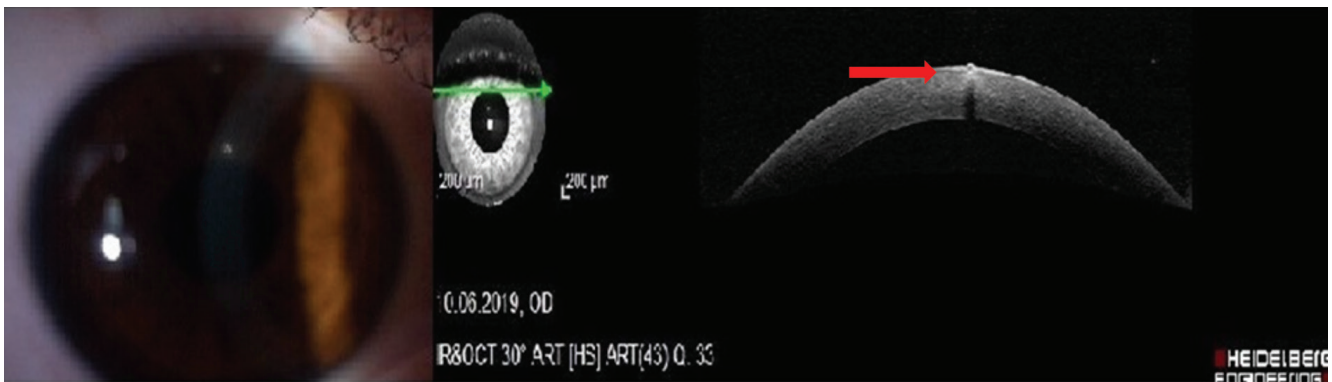
Corneal foreign bodies constitute a significant portion of ocular injuries, which are the leading emergencies of the eye.<sup>1,6,7</sup> A detailed history including risk factors and thorough examination are important in the diagnosis of corneal foreign bodies.<sup>8</sup> Ocular injuries, including corneal foreign bodies, are generally more common in young males.<sup>4</sup> Corneal foreign body injuries were also more frequent in young adults and males in this study, consistent with the literature.

Slit-lamp examination of corneal foreign bodies cannot be performed properly in various situations, such as the presence of a transparent foreign body, corneal turbidity, or anterior chamber hyphema.<sup>13</sup> Deeply embedded transparent corneal foreign bodies are particularly difficult to assess.<sup>13</sup> Furthermore, in areas with corneal opacity, small corneal foreign bodies may be missed in microscopic examination.<sup>14</sup> Determining the type of corneal foreign body is important in determining the urgency of its removal.<sup>15</sup> In cases of injury with better tolerated inert substances such glass and plastic, emergency intervention can be postponed if necessary.<sup>15</sup> In clinical situations where it is difficult to understand how deep into the cornea the foreign body has penetrated and whether or not there is full-thickness penetration, imaging modalities that facilitate determination of the type, size, and location of the corneal foreign body may be guiding in treatment, especially in cases that require surgery.<sup>11</sup>

AS-OCT, a non-invasive method that provides high-resolution images from various depths of the ocular anterior segment, offers an advantage in the examination of corneal



**Figure 1.** Anterior segment photograph of metallic corneal foreign body (red arrow) (a). On anterior segment optical coherence tomography, the metallic foreign body is hyperreflective (blue arrow) and causes a mirror effect (red arrow) (b)



**Figure 2.** Anterior segment photograph of a chemical clay substance in the cornea (a). On anterior segment optical coherence tomography, the chemical clay substance appears hyperreflective (red arrow)

Patient	Gender	Age, years	Eye	FB type	OCT results
1	Male	24	Left	Metal	Hyperreflective, mirror effect
2	Male	30	Right	Metal	Hyperreflective, mirror effect
3	Male	28	Right	Metal	Hyperreflective, mirror effect
4	Male	29	Right	Metal	Hyperreflective, mirror effect
5	Male	37	Right	Metal	Hyperreflective, mirror effect
6	Male	19	Right	Metal	Hyperreflective, mirror effect
7	Male	50	Bilateral	Metal	Hyperreflective, mirror effect
8	Female	37	Right	Chestnut	Not detected on OCT
9	Female	32	Right	Chestnut	Not detected on OCT
10	Female	15	Left	Chestnut	Not detected on OCT
11	Male	51	Right	Metal	Hyperreflective, mirror effect
12	Male	50	Left	Metal	Hyperreflective, mirror effect
13	Male	55	Left	Metal	Hyperreflective, mirror effect
14	Male	27	Right	Metal	Hyperreflective, mirror effect
15	Male	24	Left	Metal	Hyperreflective, mirror effect
16	Male	34	Right	Metal	Hyperreflective, mirror effect
17	Male	71	Bilateral	Metal	Hyperreflective, mirror effect
18	Female	18	Right	Clay	Hyperreflective, no mirror effect
19	Male	49	Left	Metal	Hyperreflective, mirror effect
20	Male	18	Right	Metal	Hyperreflective, mirror effect

FB: Foreign body, OCT: Optical coherence tomography

foreign bodies because it is reliable and reproducible, has rapid image acquisition, and enables the depth of the foreign body to be determined.<sup>11</sup> There are few studies and case reports in the literature related to determining the details of corneal foreign body location and characteristics by AS-OCT. In an experimental study by Armarnik et al.<sup>11</sup>, opaque objects (metal, wood, pencil graphite) were found to be hyperreflective in AS-OCT, and a mirror effect was observed with metal and pencil graphite.

Transparent foreign bodies (glass and plastic) were reported to be hyperreflective with areas of hyporeflectivity.<sup>11</sup> Goel et al.<sup>16</sup> showed in a case report that a metallic corneal foreign body was hyperreflective on AS-OCT. In another case report by Celebi et al.<sup>17</sup>, a metallic foreign body appeared hyperreflective with shadowing on AS-OCT. We also observed hyperreflectivity and the mirroring effect with the metallic corneal foreign bodies in this study, consistent with the literature. Although the foreign

body made of the opaque chemical clay substance exhibited hyperreflectivity, no mirror effect was observed. Organic foreign bodies from hairy chestnut spines were not detectable on AS-OCT.

## Conclusion

In light of the limited literature information, it has been shown that there are characteristic links between the type of foreign body and their OCT findings on AS-OCT. This study contributes to the literature related to the description of foreign body materials and their OCT findings and is also important in highlighting the value of OCT in the diagnosis and follow-up of these patients. In the coming years, with corroboration by controlled prospective studies including larger case series, AS-OCT will likely play a more important role in determining the location, depth, and nature of foreign bodies and making treatment decisions accordingly.

## Ethics

**Ethics Committee Approval:** The study was approved by the Ege University Faculty of Medicine Ethics Committee and conducted in accordance with the Declaration of Helsinki.

**Informed Consent:** Obtained.

**Peer-review:** Externally peer reviewed.

## Authorship Contributions

Concept: Ö.B.S., M.P., Design: Ö.B.S., M.P., Data Collection or Processing: E.A., Ö.B.S., Analysis or Interpretation: E.A., Ö.B.S., M.P., Literature Search: E.A., Ö.B.S., M.P., Writing: E.A., Ö.B.S., M.P.

**Conflict of Interest:** No conflict of interest was declared by the authors.

**Financial Disclosure:** The authors declared that this study received no financial support.

## References

- Nash EA, Margo CE. Patterns of emergency department visits for disorders of the eye and ocular adnexa. *Arch Ophthalmol.* 1998;116:1222-1226.
- Pizzarello LD. Ocular trauma: time for action. *Ophthalmic Epidemiol.* 1998;5:115-116.
- Henderson D. Ocular trauma: one in the eye for safety glasses. *Arch Emerg Med.* 1991;8:201-204.
- May DR, Kuhn FP, Morris RE, Witherspoon CD, Danis RP, Matthews GP, Mann L. The epidemiology of serious eye injuries from the United States Eye Injury Registry. *Graefes Arch Clin Exp Ophthalmol.* 2000;238:153-157.
- Karlson TA, Klein BE. The incidence of acute hospital-treated eye injuries. *Arch Ophthalmol.* 1986;104:1473-1476.
- McGwin G Jr, Owsley C. Incidence of emergency department-treated eye injury in the United States. *Arch Ophthalmol.* 2005;123:662-666.
- Uzun İ, Gül A. Yüzeysel korneal yabancı cisimlerde tedaviye kadar geçen süre ile ilişkili faktörlerin değerlendirilmesi. *Cumhuriyet Tıp Derg.* 2013;35:239-243.
- Ahmed F, House RJ, Feldman BH. Corneal Abrasions and Corneal Foreign Bodies. *Prim Care.* 2015;42:363-375.
- Schein OD, Hibberd PL, Shingleton BJ, Kunzweiler T, Frambach DA, Seddon JM, Fontan NL, Vinger PE. The spectrum and burden of ocular injury. *Ophthalmology.* 1988;95:300-305.
- Şahin A. Konjonktiva, Kornea, Sklera Yaralanmaları. *Turk J Ophthalmol.* 2012;42:23-26.
- Armarnik S, Mimouni M, Goldenberg D, Segev F, Meshi A, Segal O, Geffen N. Characterization of deeply embedded corneal foreign bodies with anterior segment optical coherence tomography. *Graefes Arch Clin Exp Ophthalmol.* 2019;257:1247-1252.
- Sridhar MS, Martin R. Anterior segment optical coherence tomography for evaluation of cornea and ocular surface. *Indian J Ophthalmol.* 2018;66:367-372.
- Arora T, Arora S, Sinha R. Management of intrastromal glass foreign body based on anterior segment optical coherence tomography and Pentacam analysis. *Int Ophthalmol.* 2015;35:1
- Maeda N. Optical coherence tomography for corneal diseases. *Eye Contact Lens.* 2010;36:254-259.
- Covert DJ, Henry CR, Sheth BP. Well-tolerated intracorneal wood foreign body of 40-year duration. *Cornea.* 2009;28:597-598.
- Goel N, Pangtey BPS, Raina UK, Ghosh B. Anterior segment optical coherence tomography in intracorneal foreign body. *Oman J Ophthalmol.* 2012;5:131-132.
- Celebi AR, Kilavuzoglu AE, Altıparmak UE, Cosar CB, Ozkiris A. The role of anterior segment optical coherence tomography in the management of an intra-corneal foreign body. *Springerplus.* 2016;5:1559.



# Survey of the Impact of the COVID-19 Pandemic on Ophthalmology Clinical Practice in Turkey

© Melisa Zişan Karslıoğlu\*, © Cem Öztürkmen\*\*, © Cem Kesim\*, © Ayşe Yıldız Taş\*,  
© Pınar Günel Karadeniz\*\*\*, © Afsun Şahin\*

\*Koç University Faculty of Medicine, Department of Ophthalmology, İstanbul, Turkey

\*\*Göznuru Eye Hospital, Gaziantep, Turkey

\*\*\*Sanko University Faculty of Medicine, Department of Biostatistics, Gaziantep, Turkey

## Abstract

**Objectives:** To investigate the effect of the novel coronavirus disease 2019 (COVID-19) pandemic on the clinical practice of ophthalmologists in our country.

**Materials and Methods:** A questionnaire consisting of 22 questions was delivered to 250 ophthalmologists via e-mail and a smartphone messaging application. A total of 113 ophthalmologists completed the survey. The questions included the participants' demographic data (age, years in practice, institution, and city), changes in their working conditions and institutional preventive measures implemented during the pandemic, their personal COVID-19 experiences, the prevalence of telemedicine applications, and their attitudes toward these practices.

**Results:** Nearly half (47.8%) of the 113 ophthalmologists were 36 to 45 years old. In terms of years in practice, the largest proportion of respondents (28.3%) had 6-10 years of experience. Most of the participants worked in private/foundation universities (37.2%), while 22.1% worked in education and research clinics. Participants working at public universities most often reported that they or a close contact had to work in COVID wards (89.5%). Triage was performed in 51.5% of ophthalmology outpatient clinics, with 88.0% of these participants reporting that patients with fever, cough, or dyspnea were directed to the pandemic clinic without ophthalmological examination. All participants working in public hospitals, education and research clinics, and public university hospitals had postponed elective surgeries, whereas 12.5% of those working in private practice and 20.5% of those working in private/foundation universities reported that they continued elective surgeries. While 80.8% of the participants did not conduct online interviews or examinations, 40.4% stated that they considered telemedicine applications beneficial. Seventy-seven percent of participants expressed concern about a decrease in their income during the pandemic, with this being especially common among participants working in private practice (87.5%) and private/foundation university hospitals (85.7%).

**Conclusion:** Ophthalmologists across our country have been affected by this pandemic at a level that will change their clinical approach. We think that ophthalmologists impacted by the difficulty of providing personal protective equipment and economic concerns should be supported more during the pandemic.

**Keywords:** COVID-19 pandemic, ophthalmology clinical practice, survey

**Address for Correspondence:** Afsun Şahin, Koç University Faculty of Medicine, Department of Ophthalmology, İstanbul, Turkey

Phone: +90 505 671 32 24 E-mail: afsunshahin@gmail.com **ORCID-ID:** orcid.org/0000-0002-8963-5146

**Received:** 22.08.2020 **Accepted:** 05.11.2020

**Cite this article as:** Karslıoğlu MZ, Öztürkmen C, Kesim C, Yıldız Taş A, Günel Karadeniz P, Şahin A. Survey of the Impact of the COVID-19 Pandemic on Ophthalmology Clinical Practice in Turkey. Turk J Ophthalmol 2021;51:269-281

## Introduction

The novel coronavirus disease 2019 (COVID-19) pandemic is a global health problem. This highly contagious virus, called “severe acute respiratory syndrome coronavirus 2 (SARS-CoV-2)”, causes severe acute respiratory failure, with an incubation period ranging from 2 to 14 days.<sup>1</sup> Due to the high rates of transmission and asymptomatic carriers, a substantial proportion of health workers are at risk of infection.<sup>2</sup> Unfortunately, ophthalmology practice requires prolonged close contact with patients in high-volume outpatient clinics, and the literature clearly states that care must be taken regarding SARS-CoV-2 transmission through the ocular surface.<sup>3</sup> For this reason, ophthalmologists are in a branch at higher risk of COVID-19 infection.<sup>4</sup> In fact, Dr. Li Wenliang, an ophthalmologist working in Wuhan, China, the starting point of the pandemic, died of this infection before it was even called an epidemic.<sup>5</sup>

At the time of this writing, the COVID-19 pandemic has infected more than 12 million people worldwide and killed more than 550 thousand patients, and although its impact has abated in many countries, the pandemic continues. When the first case was reported in our country on March 11, 2020, strict measures were implemented in many areas, resulting in community-wide social and occupational reorganization. Even during quarantine periods when all citizens were expected to physically isolate themselves from the outside world, the health sector and all healthcare professionals continued to provide service, even beyond COVID-19 treatments. However, many drastic revisions in these health services were introduced, and these changes were also reflected in ophthalmology clinical practice practices (COVID-19 Novel Coronavirus Disease, Infection Control Measures in Health Institutions, Ministry of Health, <https://covid19bilgi.saglik.gov.tr>).

In line with the COVID-19 guidelines published by the Turkish Ministry of Health, the Turkish Ophthalmological Association also prepared guidelines for physicians and patients. The Turkish Ophthalmological Association made important suggestions in its article titled “Guide to Protection Principles for Ophthalmologists” published on its official website (Göz hekimleri için korunma prensipleri rehberi [English not available], Turkish Ophthalmological Association, <https://koronavirus.todnet.org>).

These recommendations can be summarized as frequent hand washing, wearing surgical masks and protective goggles or visors, surface disinfection, social distancing except for examination, questioning symptoms before examination, and especially wearing a mask (N95) when in contact with people with diagnosed or suspected COVID-19. In a message dated March 28, 2020, the Ocular Infection Society of the Turkish Ophthalmological Association shared methods to create a barrier between patient and physician during biomicroscopic examination and emphasized the need to reduce patient density and regularly ventilate outpatient waiting rooms. In a message dated March 30, 2020, the Turkish Ophthalmological

Association Glaucoma Society reported that there was no clear preference in terms of intraocular pressure measurement technique, although some scientists argued that non-contact methods may disperse micro-aerosol particles and were therefore not recommended. They also emphasized that in contact tonometry methods, probes that come into contact with the patient must be effectively disinfected. Similarly, they recommended cleaning instruments such as gonioscopes and pachymetry devices with an appropriate surface disinfectant. In a post dated April 24, 2020, the Contact Lens Society stated that there is no harm in continuing to use contact lenses if normal personal hygiene rules and restrictions are followed independent of COVID-19 infection.

Although many guidelines have been published in a short time, it is not known exactly how many of these recommendations are being reflected in the ophthalmology clinical practice in our country and to what extent they are applied. The aim of this study was to conduct a survey investigating the effects of the COVID-19 pandemic on the clinical practices of ophthalmologists in our country.

## Materials and Methods

Approval was obtained from the Ministry of Health Scientific Research Platform and the Human Clinical Research Review Ethics Committee to conduct the study in accordance with the ethical principles and practices stated in the Declaration of Helsinki (Sanko University Clinical Research Ethics Committee 2020/10, decision no: 01, date: June 18, 2020). This cross-sectional study was conducted using a 22-item questionnaire we created using a special survey program (Qualtrics<sup>SM</sup>, Boston, United States) and practically and quickly sent to practicing ophthalmologists via e-mail or a smartphone messaging application using the same program (Appendix 1). According to this program, a respondent cannot fill in the questionnaire more than once and their responses are instantly sent to the researcher’s registered account, allowing rapid target-oriented analysis of the collected data. The obtained data were completely anonymous, containing no participant identifying information, and user privacy was observed. Qualtrics is a commonly used application worldwide that has been shown to be secure in terms of user privacy.

### Parameters Evaluated in the Survey

The questionnaire included items asking about the participants’ demographic data such as age, years in practice, institution and city, changes in working conditions during the pandemic, provision of personal protective equipment (PPE) by their institution, disinfection practices, whether they or a close contact had COVID-19 infection, and their level of anxiety regarding COVID-19 infection. There were also items regarding the pre-examination patient questioning practices in their ophthalmology outpatient clinic, approach to elective surgeries, their personal approach to patients in follow-up units (cornea, glaucoma, retina, etc.), as well as their recommendations regarding contact lens use and intraocular pressure measurement

technique. Finally, we included items to evaluate the prevalence of telemedicine practices in our country, the participants' general attitude toward this practice, and pandemic-induced economic concerns.

**Statistical Analysis**

Statistical analyses were performed using the “data and analysis” module in the Qualtrics application. Percentage values were given as descriptive statistics.

**Results**

**Demographic Data**

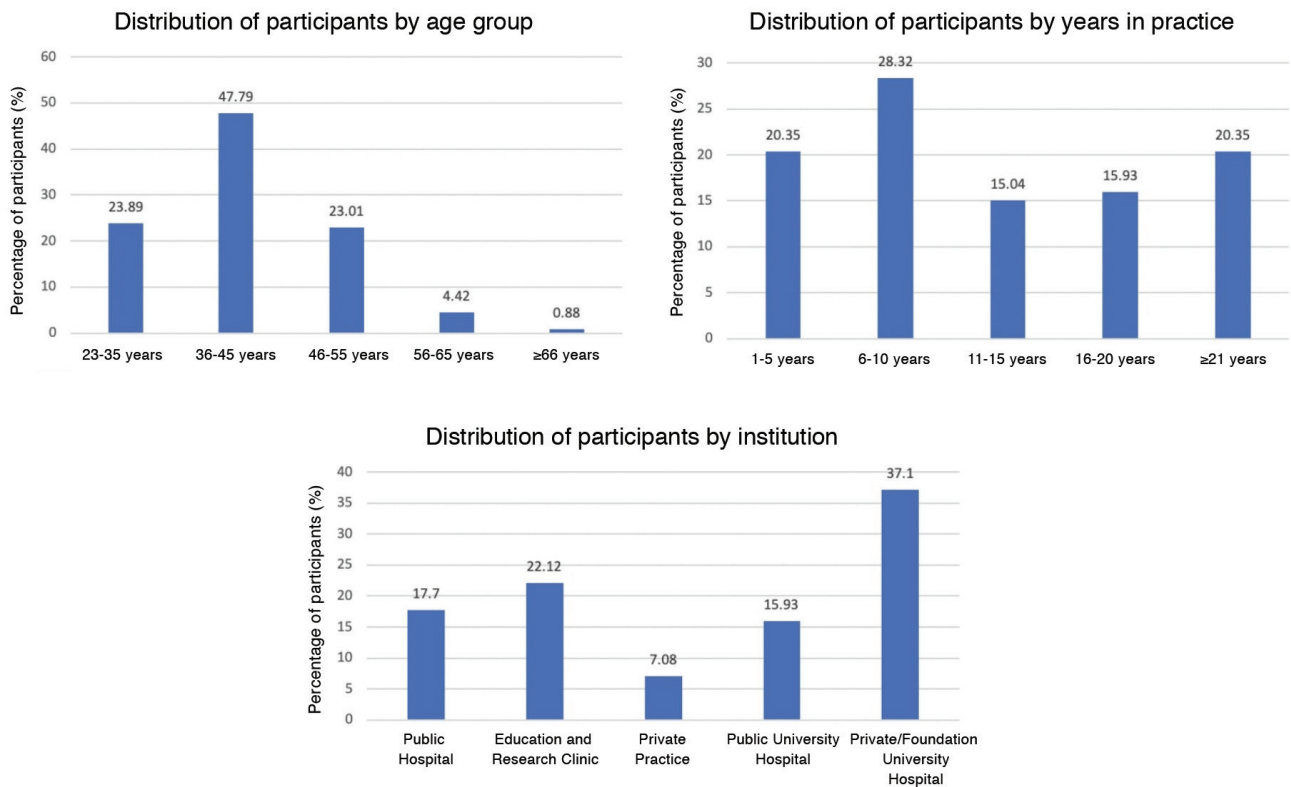
The questionnaire was sent to 250 ophthalmologists via e-mail and a smartphone messaging application. A total of 113 ophthalmologists completed the questionnaire, although 23 participants did not answer all of the items. Of the 113 participants, 47.79% (n=54) were 36-45 years old and 23.01% (n=26) were 46-55 years old (Figure 1). In terms of years in practice, 28.32% (n=32) of the participants had been working for 6-10 years, followed by 20.35% (n=23) in each the 1-5 years and ≥21 years categories (Figure 1). The largest proportion of participants worked in private or foundation universities (37.17%, n=42), while 22.12% (n=25) worked in education and research clinics (Figure 1). When the participants' cities were evaluated, 22.12% (n=25), 11.5% (n=13), and 1.77% (n=2) of the participants were working in the three largest cities

in Turkey (İstanbul, Ankara, and İzmir, respectively) and the remaining 64.6% (n=73) were working in places other than these three major cities.

**Changes in Working Conditions and Institutional Precautionary Measures**

Of the 101 participants answered the questions in this part of the survey, 89.11% (n=90) reported that their institutions had implemented rotating shift schedules during the period between the detection of the first case in Turkey on March 11, 2020 and the relaxation of the restrictions on May 11, 2020. However, 85.15% (n=86) stated that they continued to provide outpatient clinic services through the appointment system (Figure 2).

Nearly all (98.02%, n=99) of the 101 ophthalmologists who answered the questions under this subheading had access to adequate hand sanitizer and 83.17% (n=84) had access to protective equipment such as surgical masks, gloves, goggles, visors, and aprons (Figure 2). Of the 99 ophthalmologists who answered the question about whether they had access to specialty masks such as FFP2 or FFP3 in their institutions, 42.42% (n=48) said they could get them immediately upon request and 35.35% (n=35) said they could only obtain them when they would be in contact with diagnosed or suspected COVID-19 patients, while 22.22% (n=22) reported that they could not obtain specialty masks through their institutions and had purchased them by their own means.



**Figure 1.** Distribution of participants according to age, years in practice, and employing institution

According to the responses from the 101 participants who answered the questions about the precautions taken in outpatient clinics, the recommended seating arrangement for maintaining social distance in outpatient clinic waiting rooms could be implemented in 64.36% (n=65) of institutions and that examination room precautions such as wearing a visor to prevent virus transmission or positive pressure air filtration were implemented in 68.32% (n=69) of institutions (Figure 2). Of these 101 participants, 66.34% (n=67) stated that they admitted patients to the examination room alone unless the patient could not communicate for themselves, while 33.66% (n=34) said that they also admitted patient relatives into the examination room provided that they maintained social distance. The 99 ophthalmologists who answered the question about environmental disinfection indicated that disinfection was done after each patient in 34.34% (n=34) and after a patient with diagnosed or suspected COVID-19 in 51.52% (n=51) of the institutions. The remaining 14.14% (n=14) reported that environmental disinfection was not performed.

**COVID-19 Contact**

Of the 107 participants who responded to the items evaluating COVID-19 contact during the pandemic, 10.28% (n=11) said that they or a close contact had been infected, with the highest rate of infection in self or a close contact reported by participants working in public hospitals (26.3%, 5/19). During this period, 89.5% (17/19) of the participants working in public hospitals and 75% (18/24) of the participants working in education and research clinics stated that they or a close contact had to work or take shifts in a COVID-19 ward.

Of the 107 ophthalmologists who answered the multi-part item evaluating anxiety, 67.29% (n=72) reported that they feared COVID-19 infection, 79.44% (n=85) reported that thinking about it made them uneasy, and 30.84% (n=33) reported that they feared dying due to COVID-19 (Figure 3). When the anxiety levels of the participants were analyzed according to age range, we determined that the distribution of responses did not differ by age (Figure 4).

**Symptom Inquiry Before Eye Examination**

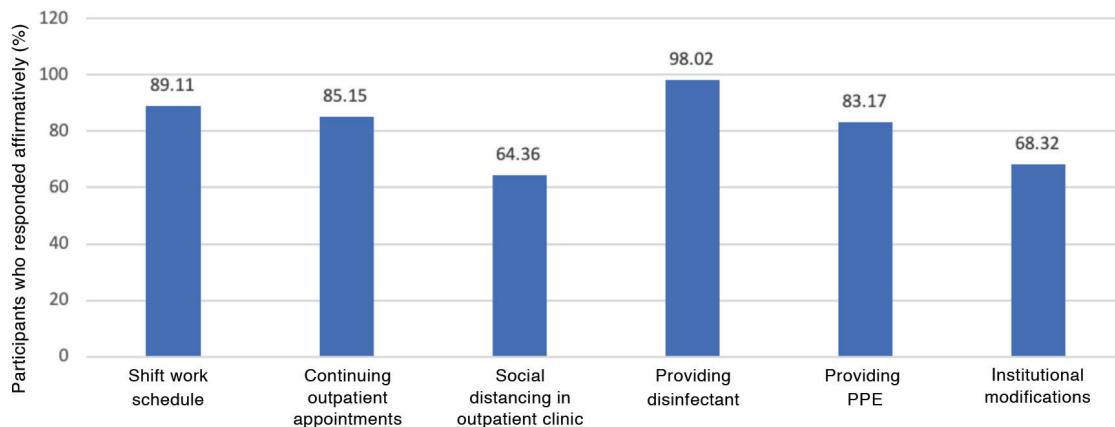
The participants were asked whether they questioned patients about COVID-19 symptoms before starting ophthalmological examinations. Of the 101 participants who responded to this question, 51.49% (n=52) said that patients were asked about symptoms upon admission and before beginning the examination, and of these participants, 88% (n=44) referred patients with fever, cough, or dyspnea and 76% (n=38) referred patients with a history of overseas travel directly to the pandemic outpatient clinic without performing ophthalmological examination.

**Approach to Surgery**

Of the 107 participants who answered the question about the decision to perform surgery, 19.63% (n=21) stated that they did not perform any surgeries, 39.25% (n=42) were continuing to perform emergency surgeries but postponed elective cases for at least 1 month, and 32.71% (n=35) continued to perform emergency surgeries but postponed elective cases for at least 3 months (Figure 5). Of the 8.41% (n=9) of participants who continued elective surgeries unconditionally, 88.8% (n=8) worked at private or foundation universities. Elective surgeries were postponed by all ophthalmologists working in public hospitals, education and research clinics, and public university hospitals, whereas 12.5% (1/8) of those working in private practice and 20.5% (8/39) of those working in private or foundation universities continued elective surgeries unconditionally.

**Approach to Cornea and Contact Lens, Uvea, Retina, Glaucoma, Ocular Oncology, Strabismus, and Oculoplasty Unit Patients**

Of the 107 participants who answered the relevant question in the survey, 83.18% (n=89) said that they followed up with unit patients, and of the 87 participants who answered the following multi-part question, no postponement of follow-up appointments was reported by 59.77% (n=52) for ocular oncology, 58.62% (n=51) for uvea, 50.57% (n=44) for retina, 48.28% (n=42) for glaucoma, and 34.48% (n=30) for cornea and contact lens patients. High proportions of participants reported



**Figure 2.** Operational changes and preventive measures taken in the participants' institutions (PPE: Personal protective equipment)



postponing follow-up appointments for oculoplastic (67.82%, n=59) and strabismus (62.07%, n=54) patients.

Of the 107 participants who responded to the question about contact lens use, 44.86% (n=48) did not recommend the use of contact lenses, while 55.14% (n=59) recommended the use of contact lenses under appropriate hand washing and hygiene conditions. Among the methods of intraocular pressure measurement, non-contact tonometry was most preferred (73.83%, n=79) and applanation tonometry was least preferred (9.35%, n=10).

### Approach to Telemedicine Applications

In the survey, 80.8% (n=80) of the 99 participants who answered the question evaluating telemedicine practices stated that they did not conduct online appointments or examinations during the pandemic. The proportion of participants who did conduct online appointment/examinations was highest among ophthalmologists working in private practice (37.5%, 3/8) and private or foundation university hospitals (35.1%, 13/37). Regardless of whether they used telemedicine applications or not, 40.4% (n=40) of all participants reported that they found them useful (Figure 6).

### Economic Concerns

Finally, 76.99% (n=87) of the 113 participants stated that they were concerned about a decrease in their income during the pandemic. This concern was expressed most often by ophthalmologists working in private or foundation university hospitals (88.9%, 37/42) and those in private practice (87.5%, 7/8). When the anxiety about loss of income was evaluated based on city, we observed that this concern was felt by both of the participants working in İzmir (100%, n=2), 76% (19/25) of those working in İstanbul, 58.3% (7/13) of those working in Ankara, and 80.8% (59/73) of those working in other cities.

### Discussion

The worldwide COVID-19 pandemic has not yet been brought under control, treatment protocols must be frequently updated, and there is not yet a vaccine to protect against

infection; therefore, the problem of SARS-CoV-2 infection remains a pressing current issue. Many countries are conducting their own studies to evaluate the situation during periods of rising COVID-19 infections and enable the development of action plans for all types of scenarios that may cause this to happen. There are a few studies in the literature evaluating changes, new approaches, or influences during this period in the field of ophthalmology.

According to the survey we created for this study, between when the first case was officially reported in our country on March 11 and when the “new normal” was introduced on May 11, it was determined that PPE supply, changes in working schedules and settings, psychological trauma, and economic concerns caused by the COVID-19 pandemic were strong determinants of ophthalmologists’ clinical approaches.

Different countries around the world are conducting various studies to investigate the national effects of the pandemic. Survey studies provide insight on prospective beneficial changes by enabling the concurrent evaluation of many different issues, such as the organization of operations or emotional states of individuals in the sector being studied. In a survey from India, Nair et al.<sup>6</sup> evaluated ophthalmology practice through a 9-item questionnaire that was sent to a total of 1260 ophthalmologists through social media platforms during a 21-day quarantine period and remained open to responses for 48 hours. It was reported that 61.52% of the participants worked in the private sector and 14.8% were affiliated with an institution. Although the number of employees in the private sector was quite high, the authors determined that 72.5% of all ophthalmologists did not examine any patients during the quarantine period and postponed elective cases, and 82.9% of those who saw patients only saw emergency cases. In addition, 77.5% of all ophthalmologists participating in the survey provided consultancy services via telephone, e-mail, video, or social media platforms, and 59.1% expressed feeling they were more at risk when examining patients compared to clinicians in other branches. Over half (57.8%) of the participants said that they did not know when elective surgeries would resume, while

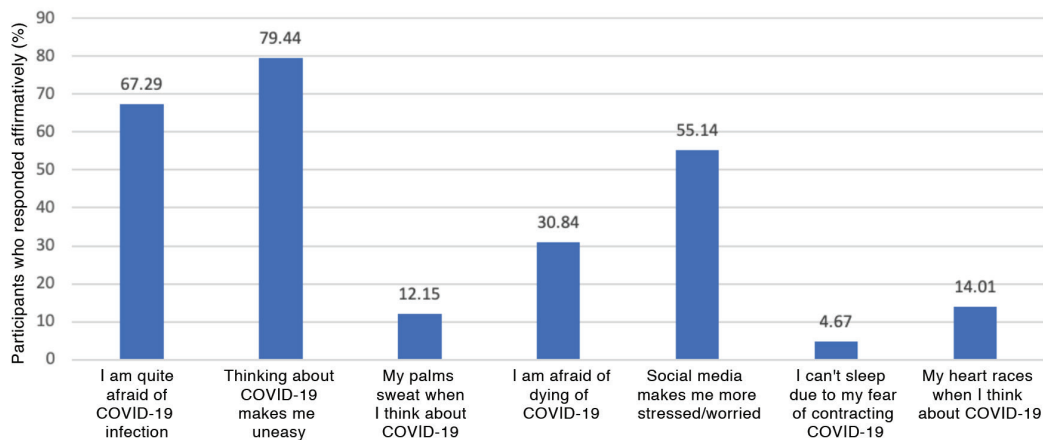
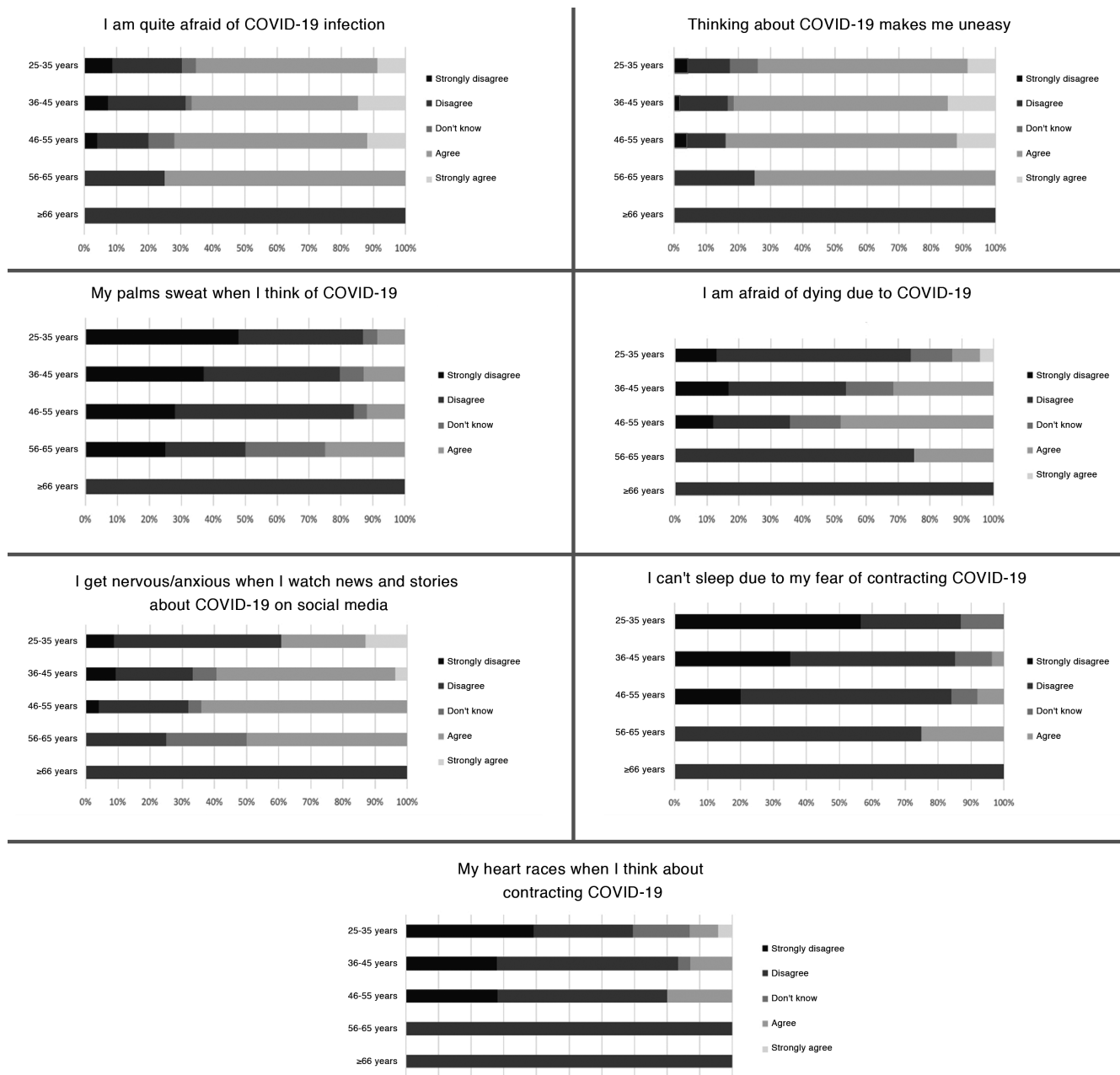


Figure 3. Evaluation of psychological anxiety due to novel coronavirus disease 2019 (COVID-19)

62.8% stated that they did not know what protective measures and screening strategies to use and were waiting for updated guidelines about this in order to resume. In terms of change in wards, it was reported that 27.5% of the ophthalmologists were temporarily assigned to emergency departments.<sup>6</sup> In contrast, in our study we used a 22-item questionnaire to also evaluate ophthalmologists' economic concerns, use of PPE, and changes in working conditions and operations in their institutions. While 19.63% of ophthalmologists in our country stated that

they did not perform any elective surgeries, most (88.8%) of the 8.41% who did not postpone any surgeries were employees in private or foundation universities, which demonstrates the impact of economic concerns on the decision to perform surgery. In addition, although telemedicine applications were performed at a much lower rate than in India (only 19.39%), 40.81% of our ophthalmologists considered these applications beneficial.

In a survey by Khanna et al.<sup>7</sup> evaluating only the psychological effects of the pandemic on ophthalmology



**Figure 4.** Distributions of COVID-19-related anxiety according to age group (COVID-19: Novel coronavirus disease 2019)

residents and specialists, it was determined that 32.6% of the 2,355 participants had very mild depression and 21.4% had mild depression, and these values were higher than the 10% prevalence of common mental disorders reported in the general Indian population. In addition, it was found that depression was more common in young ophthalmologists and decreased by 3% with each year increase in age. In our study, 67.2% of all ophthalmologists reported serious anxiety related to the COVID-19 pandemic, but there was no significant difference in anxiety levels according to age.

In New York City, one of the places most affected by the pandemic, a survey was done to assess COVID-19 exposure among medical residents in different institutions.<sup>4</sup> The study included 2306 residents in 24 different specialties in a total of 91 training programs. Of these, 101 of the physicians had positive COVID-19 test results, 163 were presumed positive (consistent symptoms and clinical picture but not tested), and 76 had negative test results despite suspicious symptoms. The remaining 1,748 residents had no suggestive symptoms and

thus were not tested. Over one-quarter (27.3%) of the residents had been assigned to work in COVID-19 wards, with the largest proportion of these being residents of anesthesiology. Based on the residents' positive test results, it was noted that anesthesiology, emergency medicine, and ophthalmology were branches at higher risk of transmission. Among all participants, 1832 residents (79.4%) used a standard surgical mask or N95 mask depending on the patient's condition, 323 residents (14%) only used standard surgical masks, and 31 residents (5.7%) were always able to obtain N95 masks. In general, 1314 residents (56.9%) reported that the PPE they used was substandard. In that study, the total proportion of residents with confirmed or suspected COVID-19 was calculated as 11.5%, whereas 10.28% of the ophthalmologists in our study reported that they or a close contact had been diagnosed as having COVID-19. While 27.3% of all residents had a change in where they were assigned to work during the pandemic, a large proportion of the ophthalmologists who participated in our survey (63.55%) were assigned to work in COVID wards. In terms of PPE, we noted that 22.2% of the

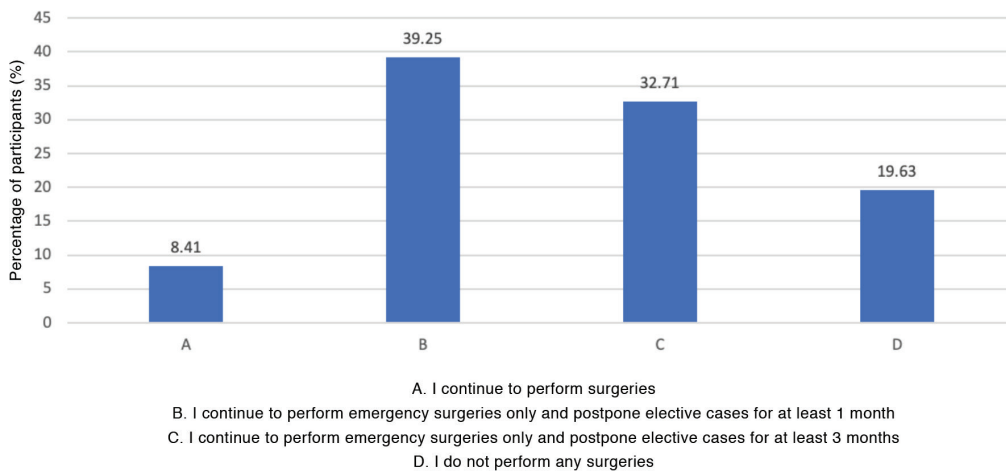


Figure 5. Approaches to patients with surgical indications

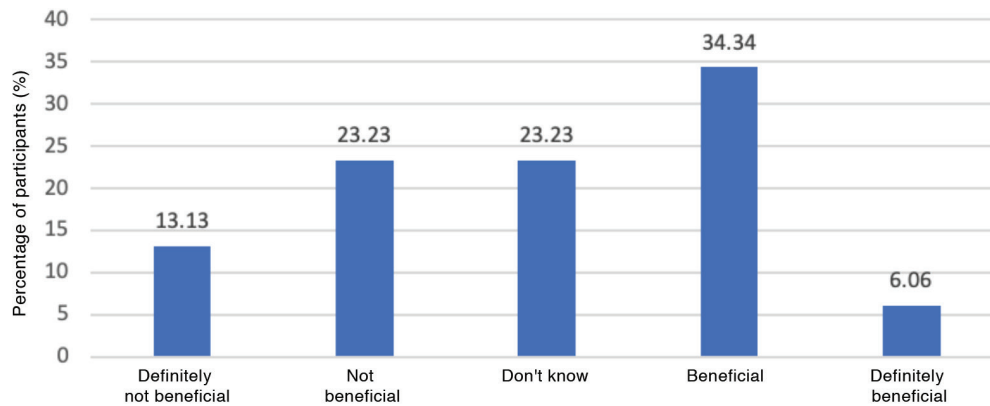


Figure 6. Attitude toward health services provided by online video calls or examinations

ophthalmologists in our country could only request standard surgical masks from their institutions and 42.4% could request N95 masks depending on the patient's status.

Minocha et al.<sup>8</sup> conducted a survey via Google Forms including a total of 100 people (80 ophthalmologists, 11 optometrists, 8 nurses, 1 healthcare professional) working in ophthalmology clinics of 3 major hospitals in the UK to evaluate their perceived risk of contracting COVID-19, the comprehensibility and reliability of national public health regulations, and the recommended PPE and training in its use in the relevant hospitals. Eighty percent of the participants reported that they felt at risk of COVID-19 transmission because they worked in an ophthalmology clinic, while 55% said public health institutions did not provide adequate information or guidance in terms of identifying patients with COVID-19 or at risk of having COVID-19, and 79% reported that they had not been trained in the use of PPE. In our study, 67.2% of Turkish ophthalmologists expressed severe anxiety about their risk of contracting COVID-19, but because the survey did not include any questions about PPE training or Ministry of Health COVID-19 treatment guidelines, we did not evaluate these.

In a study conducted in Israel, Wasser et al.<sup>9</sup> assessed changes in ophthalmologists' clinical and surgical approaches using a 17-item questionnaire on SurveyMonkey.com early in the pandemic, when a government-issued official regulation was not yet in place. No limitations in the number of outpatients and elective surgery appointments were reported by 52.7% and 69.9% of the participating ophthalmologists, respectively. In addition, 46.4% of the participants questioned patients before eye examination, 60.5% were aware of COVID-19 guidelines, and 50.6% were able to obtain PPE from their institution. However, when asked at what level they would recommend providing outpatient services or performing surgery, 62.9% and 72.7% of the participants respectively supported only evaluating emergency cases. In our study, only 8.41% of Turkish ophthalmologists stated that they did not postpone elective surgeries, while 39.25% stated that they postponed elective surgeries for at least 1 month and 32.71% for at least 3 months. We noted that patients were questioned before undergoing an eye examination in 51.49% of institutions. A fairly high percentage (77.7%) of ophthalmologists participating from across the country reported that they had access to PPE when needed.

Our study has strengths and shortcomings. During the "new normal" period in our country, we also received surveys related to the COVID-19 pandemic in the field of ophthalmology. However, the questions in these surveys did not investigate the effect of the pandemic on ophthalmologists' clinical practice and the results have not yet been published to the best of our knowledge. In this context, there has been no previous assessment of how pandemic-induced concerns among physicians and healthcare professionals affect ophthalmology clinical practice and to what degree institutions influence the physician's behavioral model. A shortcoming of our study is the small number of

ophthalmologists that participated in the survey. However, despite the small sample size, the fact that the frequency of responses to some questions approached 80% shows that the COVID-19 pandemic affects ophthalmology practice in our country. This suggests that more extensive studies are needed.

## Conclusion

The COVID-19 pandemic has caused significant changes in ophthalmologists' clinical practices, and these changes may persist for some time after the pandemic. Based on our results, we believe that psychological and economic support as well as institutional modifications and personal protective measures are necessary for Turkish ophthalmologists to act in accordance with national and international guidelines in their clinical approaches and choices.

## Ethics

**Ethics Committee Approval:** Approval was obtained from the Ministry of Health Scientific Research Platform and the Human Clinical Research Review Ethics Committee to conduct the study in accordance with the ethical principles and practices stated in the Declaration of Helsinki (Sanko University Clinical Research Ethics Committee 2020/10, decision no: 01, date: June 18, 2020).

**Peer-review:** Externally peer reviewed.

## Authorship Contributions

Concept: C.Ö., A.Ş., Design: M.Z.K., C.Ö., A.Ş., Data Collection or Processing: M.Z.K., C.K., A.Y.T., P.G.K., Analysis or Interpretation: M.Z.K., C.K., A.Ş., Literature Search: C.K., A.Y.T., Writing: M.Z.K., A.Ş.

**Conflict of Interest:** No conflict of interest was declared by the authors.

**Financial Disclosure:** The authors declared that this study received no financial support.

## References

- Lai CC, Shih TP, Ko WC, Tang HJ, Hsueh PR. Severe acute respiratory syndrome coronavirus 2 (SARS-CoV-2) and coronavirus disease-2019 (COVID-19): The epidemic and the challenges. *Int J Antimicrob Agents.* 2020;55:105924.
- Chang D, Xu H, Rebaza A, Sharma L, Dela Cruz CS. Protecting health-care workers from subclinical coronavirus infection. *Lancet Respir Med.* 2020;8:13.
- Lu CW, Liu XF, Jia ZF. 2019-nCoV transmission through the ocular surface must not be ignored. *Lancet.* 2020;395:39.
- Breazzano MP, Shen J, Abdelhakim AH, Glass LRD, Horowitz JD, Xie SX, de Moraes CG, Chen-Plotkin A, Chen RW; New York City Residency Program Directors COVID-19 Research Group. New York City COVID-19 resident physician exposure during exponential phase of pandemic. *J Clin Invest.* 2020;130:4726-4733.
- Petersen E, Hui D, Hamer DH, Blumberg L, Madoff LC, Pollack M, Lee SS, McLellan S, Memish Z, Praharaj J, Wasserman S, Ntoumi F, Azhar EI, Mchugh TD, Kock R, Ippolito G, Zumla A, Koopmans M. Li Wenliang, a face to the frontline healthcare worker. The first doctor to notify the emergence of the SARS-CoV-2, (COVID-19), outbreak. *Int J Infect Dis.* 2020;93:205-207.
- Nair AG, Gandhi RA, Natarajan S. Effect of COVID-19 related lockdown on ophthalmic practice and patient care in India: Results of a survey. *Indian J Ophthalmol.* 2020;68:725-730.

7. Khanna RC, Honavar SG, Metla AL, Bhattacharya A, Maulik PK. Psychological impact of COVID-19 on ophthalmologists-in-training and practising ophthalmologists in India. *Indian J Ophthalmol.* 2020;68:994-998.
8. Minocha A, Sim SY, Than J, Vakros G. Survey of ophthalmology practitioners in A&E on current COVID-19 guidance at three Major UK Eye Hospitals. *Eye (Lond).* 2020;34:1243-1245.
9. Wasser LM, Assayag E, Tsessler M, Weill Y, Becker-Cohen M, Zadok D. Response of ophthalmologists in Israel to the novel coronavirus (2019-nCoV) outbreak. *Graefes Arch Clin Exp Ophthalmol.* 2020;258:1419-1426.

Appendix 1. Effect of the COVID-19 pandemic on ophthalmology clinical practice questionnaire

**Question 1. How old are you?**

- 23-35
- 36-45
- 46-55
- 56-65
- 66 years or older

**Question 2. How many years have you been working as an ophthalmologist?**

- 1-5
- 6-10
- 11-15
- 16-20
- 21 years or more

**Question 3. What type of institution do you work in?**

- Public hospital
- Education and research clinic
- Private practice
- Public university hospital
- Private/foundation university hospital

**Question 4. What city do you work in?**

- İstanbul
- Ankara
- İzmir
- Other (please write)

**Question 5. Are you concerned that your income will decrease during the pandemic?**

- Yes
- No

**Question 6. Have you or someone close to you been diagnosed with COVID-19?**

- Yes
- No

**Question 7. Have you or someone close to you had to work/take shifts in a ward for patients with COVID-19?**

- Yes
- No

**Question 8. Please choose the expression that best represents your opinion about the following statements.**

	Strongly disagree	Disagree	I don't know	Agree	Strongly agree
- I'm quite afraid of COVID-19 infection					
- Thinking about COVID-19 makes me uneasy					
- My palms sweat when I think of COVID-19					
- I am afraid of dying due to COVID-19					
- I get nervous or anxious when I watch news and stories about COVID-19 on social media					
- I can't sleep due to my fear of contracting COVID-19					
- My heart races when I think about contracting COVID-19					

**Question 9. What is your approach toward the use of contact lenses during the pandemic?**

- I definitely do not recommend using them
- I recommend using them if the user can provide appropriately hygienic conditions.

**Question 10. Which method do you use to measure intraocular pressure during the pandemic?**

- Non-contact tonometry
- Applanation tonometry
- Finger tension

**Question 11. What is your approach to patients who have a surgical indication during the pandemic?**

- I continue to perform surgeries
- I continue to perform emergency surgeries only and postpone elective cases for at least 1 month
- I continue to perform emergency surgeries only and postpone elective cases for at least 3 months
- I do not perform any surgeries

**Question 12. Do you see patients in follow-up units (glaucoma, retina, cornea, etc.)?**

- Yes
- No

**Question 13. How long do you postpone routine follow-up appointments of patients in follow-up units (glaucoma, retina, cornea, etc.)?**

	I do not postpone them	1 month	3 months
Glaucoma			
Uvea			
Retina			
Cornea and contact lens			
Ocular oncology			
Strabismus			
Oculoplasty			

**Question 14. Please answer “Yes” or “No” to the following questions.**

	Yes	No
- Was a rotating shift work schedule implemented in the institution where you work between when the first COVID-19 case was reported in our country on March 11, 2020 to when social restrictions were eased on May 11, 2020?		
- Do you continue to provide outpatient services through the appointment system?		
- Are you able to apply the recommended seating arrangements to maintain social distance in the waiting room of the outpatient clinic?		
- Do you have access to a sufficient amount of disinfectant for hand hygiene in your institution?		
- Do you have access to sufficient personal protective equipment (e.g., masks, gloves, goggles, visors, coveralls) to prevent virus transmission in your institution?		
- Have any modifications been made in the outpatient clinic rooms in your institution to prevent virus transmission (e.g., installing shields on examination units, positive pressure air filtration)?		

**Question 15. Do you admit patient relatives into the outpatient examination rooms together with patients?**

- Yes, I admit patient relatives provided they maintain social distance
- No, I admit patients only into the examination room unless they are not able to communicate for themselves

**Question 16. Do you apply triage at outpatient admission?**

- Yes
- No

**Question 17. In your admission triage practice, what happens if a patient has fever (>38 °C), cough, and dyspnea?**

- I refer the patient to the “pandemic outpatient clinic” without performing ophthalmological examination.
- I provide the patient a mask and perform a routine ophthalmological examination, but postpone the elective examinations (optical coherence tomography, topography, computerized visual field testing).
- I provide the patient a mask and perform all kinds of ophthalmological examinations and imaging.

**Question 18. In your triage practice, what happens if a patient has traveled to one of the international pandemic zones in the last 14 days or has contact with someone who has?**

- I refer the patient to the “pandemic outpatient clinic” without performing ophthalmological examination.
- I provide the patient a mask and perform a routine ophthalmological examination, but postpone the elective examinations (optical coherence tomography, topography, computerized visual field testing).
- I provide the patient a mask and perform all kinds of ophthalmological examinations and imaging.



**Question 19. How is environmental disinfection achieved after the outpatient clinic in your institution?**

- The examination unit, instruments used, and door handles are disinfected by the cleaning staff after each patient.
- The examination unit, instruments used, and door handles are disinfected by the cleaning staff not after every patient, but after patients with confirmed or suspected COVID-19.
- Environmental disinfection is not performed.

**Question 20. Do you have adequate access to specialty masks (FFP2, FFP3) other than surgical masks in your institution?**

- I can obtain them immediately upon request.
- I can only obtain them when I will come into contact with confirmed or suspected COVID-19 patients.
- I cannot obtain specialty masks other than surgical masks in my institution.

**Question 21. Do you use an online video call/examination application with your patients through your institution?**

- Yes
- No

**Question 22. Do you think that online video calls/examination applications are beneficial to the health service received by the patient? Please choose from the expressions below which best represents your opinion.**

- Strongly disagree
- Disagree
- I don't know
- Agree
- Strongly agree



# The Causes and Frequency of Monocular and Binocular Blindness in Adults Applying to the Health Committee of a University Hospital in Central Anatolia

© Günsu Deniz Mirza, © Mehmet Okka, © Enver Mirza, © Selman Belviranlı

Necmettin Erbakan University Meram Faculty of Medicine, Department of Ophthalmology, Konya, Turkey

## Abstract

**Objectives:** The aim of this study was to investigate the frequency of blindness and the pathologies that cause blindness in the Konya province of Turkey.

**Materials and Methods:** The records of individuals over 18 years of age who applied to the health committee of Meram School of Medicine Hospital between January 2015 and December 2018 were evaluated retrospectively.

**Results:** After reviewing the records of 4,268 applicants, a total of 222 applicants were included in the study (159 patients with monocular blindness, 63 patients with binocular blindness). The most common causes of monocular blindness were optic atrophy (13%), amblyopia (11%), and phthisis bulbi (10%). The most common causes of binocular blindness were retinitis pigmentosa (28%), proliferative diabetic retinopathy (13%), and unoperated cataract (11%). The frequency of monocular blindness was 3.7% (95% confidence interval [CI]: 3.2-4.3%) and binocular blindness was 1.5% (95% CI: 1.1-1.9%) in the sample. The frequency of blindness increased with age, with a positive correlation between mean age and blindness ( $p=0.002$ ). Monocular blind applicants had a significantly lower mean age than binocular blind applicants ( $48.8\pm 13.3$  vs.  $55.0\pm 13.1$  years,  $p=0.002$ ) and binocular blind women had a significantly higher mean age than binocular blind men ( $62.7\pm 16.0$  vs.  $53.2\pm 11.7$  years,  $p=0.023$ ). The prevalence of monocular and binocular blindness was significantly higher in men than women ( $p=0.032$ ).

**Conclusion:** The results of this study show that many of the pathologies that cause blindness are preventable or treatable, and that blindness is associated with age.

**Keywords:** Blindness, prevalence, retinitis pigmentosa, proliferative diabetic retinopathy, cataract

## Introduction

Visual impairment or blindness is a disability that restricts a person's life in many ways. Blindness is not only an individual disability; it is also a major public health problem, because blindness also affects millions of others who assist and care for blind people, such as their relatives. Ultimately, it affects the national economy.<sup>1</sup> According to data from two different studies conducted in Japan and Canada, it was calculated that visual impairment and blindness impose an economic burden of \$15-73 million per year.<sup>2,3</sup>

Approximately 33 to 39 million people worldwide are believed to be blind.<sup>4,5,6,7</sup> According to data from the World Health Organization (WHO), the global blind population increases by 1-2 million every year.<sup>8</sup> However, it is known that the majority of pathologies that cause blindness are preventable or treatable.<sup>8</sup> Early diagnosis and proper treatment of the pathologies that cause blindness may help rehabilitate these patients and enable them to rejoin society. Further research will contribute to the development of policies and programs for blindness prevention that could reduce the economic burden of this health problem.

**Address for Correspondence:** Günsu Deniz Mirza, Necmettin Erbakan University Meram Faculty of Medicine, Department of Ophthalmology, Konya, Turkey  
E-mail: gayretli.deniz@gmail.com **ORCID-ID:** orcid.org/0000-0002-3073-1213

**Received:** 28.05.2020 **Accepted:** 15.12.2020

**Cite this article as:** Mirza GD, Okka M, Mirza E, Belviranlı S. The Causes and Frequency of Monocular and Binocular Blindness in Adults Applying to the Health Committee of a University Hospital in Central Anatolia. Turk J Ophthalmol 2021;51:282-287

In addition, according to WHO's more recent 2019 World Report on Vision, eye health problems and visual impairment affect over 2.2 billion people worldwide, 1 billion of whom have visual impairment that was preventable or is unaddressed.<sup>9</sup> This includes people with uncorrected refractive errors (123.7 million) and presbyopia (826 million) as well as those with cataract (65.2 million), glaucoma (6.9 million), corneal opacities (4.2 million), diabetic retinopathy (3 million), and trachoma (2 million). This report reveals once again that many pathologies that cause visual impairment are preventable and treatable.<sup>9</sup>

Turkey is a developing country with a total population of over 80 million and a large young population. However, the worldwide population is increasingly older and as a result, the prevalence of age-related ocular pathologies and blindness is also increasing.<sup>4</sup> Konya is a major city in the Central Anatolia region, capital of the Konya province, and the seventh most populous city in Turkey, with a total metropolitan population of over 2 million. Moreover, the Konya province neighbors several smaller provinces and patients from these areas also come to Konya for diagnosis and treatment. As a result, hospitals in Konya serve a population of approximately 3 million.

In light of this information, we aimed in this study to evaluate the frequency of blindness and determine the pathologies that cause blindness in the Konya province by reviewing the data of people who applied to the health committee of Meram School of Medicine Hospital.

## Materials and Methods

In this study, the records of individuals over 18 years of age who applied to the health committee of Necmettin Erbakan University Meram School of Medicine Hospital between January 2015 and December 2018 were examined retrospectively. Necmettin Erbakan University, Meram Medical Faculty Ethics Committee approved with the decision numbered 2019/1722 and the principles of the Declaration of Helsinki were adhered to throughout the study.

Best-corrected visual acuity (BCVA) was evaluated for all applicants according to their education level (Snellen chart for literate applicants, reduced logMAR tumbling-E chart for illiterate applicants). All applicants underwent automated refraction (Topcon KR-8900 Auto Kerato-refractometer). Intraocular pressure (IOP) was measured by air-puff tonometry. If IOP was  $\geq 21$  mmHg, Goldmann applanation tonometry was used to confirm the IOP value. Slit-lamp biomicroscopic and dilated funduscopy examinations were performed. If necessary, applicants were examined by spectral-domain optical coherence tomography (Heidelberg Engineering, Heidelberg, Germany), fundus angiography (Heidelberg Engineering, Heidelberg, Germany), corneal topography (Pentacam HR, Oculus Optikgerate, Wetzlar, Germany), and Humphrey Field Analyzer (HFA: Carl Zeiss Meditec, Dublin, CA, USA). Examination and demographic data of the applicants were recorded only once.

Using the WHO criteria, blindness was defined as BCVA worse than 20/400 in the better eye or constriction of visual field to  $<10^\circ$  from central fixation. Monocular blindness was defined as BCVA less than 20/400 in the worse eye and higher than 20/400 in the better eye.

## Statistical Analysis

SPSS version 22.0 package program (IBM Corp, Armonk, NY, USA) was used for statistical analysis of the data. The Kolmogorov-Smirnov test was used to confirm normal distribution of the variables. Categorical variables were expressed as number and percentage, and continuous variables were expressed as mean  $\pm$  standard deviation. Categorical data were analyzed using chi-square test with 95% confidence intervals (CI). Student's t-test was used to compare normally distributed continuous variables between monocular and binocular blindness groups. Pearson correlation test was used to calculate correlation coefficients and their statistical significance. A p value  $<0.05$  was considered statistically significant.

## Results

Of 4,268 records reviewed, 897 (21%) of the applicants wanted to obtain a health report for reasons such as applying for a job or firearms license and 3,371 (79%) wanted to obtain a disability report in order to exercise their legal rights. Of these, a total of 222 applicants who were diagnosed as blind (monocular blindness,  $n=159$  and binocular blindness,  $n=63$ ) were included in this study. The demographic characteristics of the sample are shown in Table 1.

The frequency of monocular blindness in the sample was 3.7% (95% CI: 3.2%-4.3%). The most common causes of monocular blindness were optic atrophy (13%), amblyopia (11%), and phthisis bulbi (10%). The other causes of monocular blindness are shown in Figure 1. The diagnosis of optic atrophy was generally associated with a primary disease such as neurodegenerative disease, central nervous system tumor (e.g., brain, pituitary), or cranial trauma due to traffic accidents. Subtypes of amblyopia were anisometropic amblyopia ( $n=17$ ) and deprivation amblyopia ( $n=1$ ). Moreover, the applicants evaluated under phthisis bulbi diagnosis were those who underwent perforation repair due to penetrating eye injury and subsequently developed blindness due to various ocular pathologies such as ocular trauma, infection, inflammatory diseases, ocular surgery, and chronic retinal detachment (RD). Ocular trauma was the most common of cause of phthisis bulbi and all of these applicants were male ( $n=15$ ).

The frequency of monocular blindness in women was 2.2% (95% CI: 1.2-3.6%). Optic atrophy (29%), age-related macular degeneration (AMD; 22%), and cataract (14%) were the first three causes of monocular blindness among female applicants. Other reasons are given in Table 2. The causes in the "other" category in Table 2 were retinitis pigmentosa (RP; 1%) and proliferative diabetic retinopathy (PDRP; 1%). Of the applicants with monocular blindness, 91% ( $n=145$ ) were men.

The frequency of monocular blindness in men was 4% (95% CI: 3.4-4.7%). The first three causes of monocular blindness in male applicants were amblyopia (12%), optic atrophy (11%), and phthisis bulbi (10%). Other reasons are given in Table 2. The "other" category for men included cataract (8%), RD (8%), other corneal diseases (8%), other retinal diseases (7%), PDRP (6%), glaucoma (3%), RP (3%), AMD (2%), keratoconus (1.5%), and myopic macular degeneration (MMD; 1.5%).

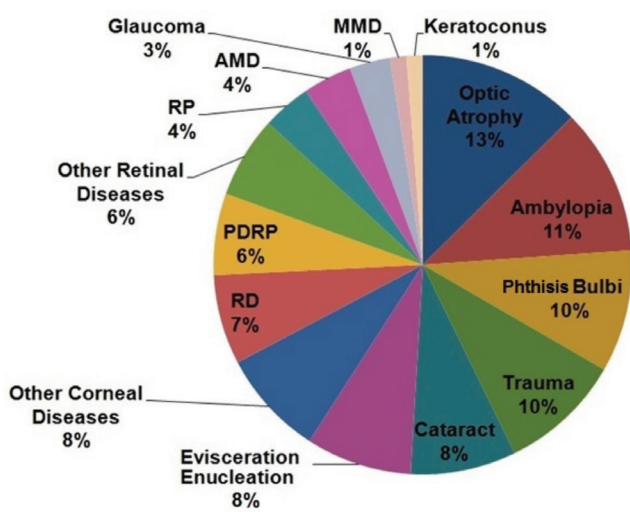
The frequency of binocular blindness was 1.5% in the sample (95% CI: 1.1-1.9%). The most common causes of binocular blindness were RP (28%), PDRP (13%), and cataract (11%). The other causes of binocular blindness are shown in Figure 2. Pathologies such as posterior staphyloma, macular scar secondary to angioid streak, previous RD surgery, and retinochoroidal coloboma were classified as "other retinal diseases" and pathologies such as bullous keratopathy, band keratopathy, corneal leukoma/scar, and corneal dystrophy as "other corneal diseases." The general diagnosis of optic atrophy included subgroups of central nervous system tumor (brain, pituitary, etc.), neurodegenerative diseases, cranial trauma due to traffic accidents, and optic neuropathy.

We determined that 81% (n=51) of the binocular blind applicants were male. The frequency of binocular blindness was

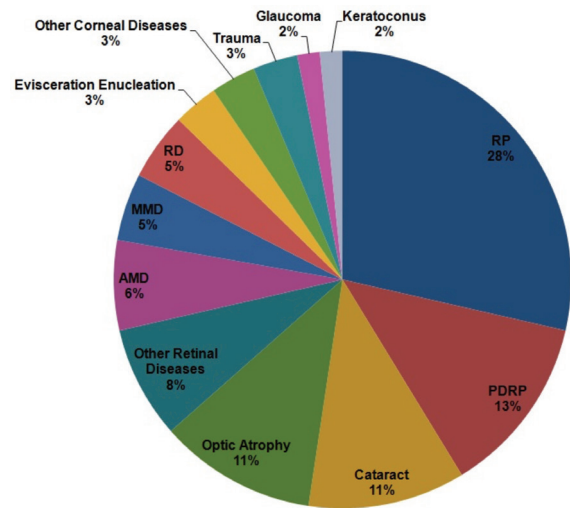
1.4% (95% CI: 1.0-1.8%) in men and 1.8% (95% CI: 1.0-3.2%) in women. The first three causes of binocular blindness were cataract (33%), RP (25%), and PDRP (17%) among women and RP (29%), optic atrophy (13%), and PDRP (12%) among men (Table 3). Other causes in men were cataract (6%), MMD (6%), RD (6%), evisceration/enucleation (4%), blunt/perforating trauma (4%), keratoconus (2%), and other corneal diseases (2%).

A remarkable finding was the significant male predominance among both monocular and binocular blind applicants (p=0.032). Moreover, the mean age of monocular blind applicants was significantly lower than that of binocular blind applicants (48.8±13.3 vs. 55.0±13.1 years, p=0.002). When monocular blind female and male applicants were compared, no statistically significant difference was found in terms of mean age (50.6±22.9 vs. 48.7±12.1 years, p=0.605). However, the mean age of binocular blind female applicants was significantly higher than that of binocular blind male applicants (62.7±16.0 vs. 53.2±11.7 years, p=0.023).

Lastly, we observed a positive correlation between mean age and blindness, with the frequency of blindness increasing with age (p=0.002).



**Figure 1.** The distribution of the causes of monocular blindness  
 RD: Retinal detachment, PDRP: Proliferative diabetic retinopathy, RP: Retinitis pigmentosa, MMD: Macular degeneration



**Figure 2.** The distribution of the causes of binocular blindness  
 RP: Retinitis pigmentosa, PDRP: Proliferative diabetic retinopathy, AMD: Age-related macular degeneration, MMD: Myopic macular degeneration, RD: Retinal detachment

	n	Binocular blindness			Monocular blindness		
		n (%)	Frequency	Age (years) mean ± SD	n (%)	Frequency	Age (years) mean ± SD
<b>Female</b>	643	12 (19%)	1.9%	62.7±16.0	14 (9%)	2.2%	50.6±22.9
<b>Male</b>	3,625	51 (81%)	1.4%	53.2±11.7	145 (91%)	4.0%	48.7±12.1
<b>Total</b>	4,268	63	1.5%	55.0±13.1	159	3.7%	48.8±13.3

SD: Standard deviation

## Discussion

In this study, the three most common causes of binocular blindness were RP, PDRP, and unoperated cataract. The leading cause of binocular blindness was RP, which was diagnosed in a total of 18 applicants, 3 of whom were considered to be binocular blind based on visual field results despite having BCVA better than 10/200. There is no research about the prevalence or distribution of RP in our country, but its high frequency is probably due to the fact that consanguineous marriages are common in our region.

The number of people with diabetes has increased considerably in recent years.<sup>10</sup> In this study, PDRP was the second most common cause of binocular blindness. Eight applicants had binocular blindness due to PDRP and 3 of them had tractional RD. These patients should be diagnosed and treated earlier, before reaching this advanced stage.

Although cataract was the most common cause of blindness in many other prevalence studies, it was the third most common cause of binocular blindness in our study. The main reason for this is likely that cataract surgery was recommended to health committee applicants and their medical board reports were prepared following cataract surgery. Cataract diagnoses in this study were in applicants who refused surgery or could not undergo surgery due to impaired general condition. Another reason is that in the literature, it has been reported that patients

lack access to health services or hospitals where cataract surgery can be performed for different reasons, resulting in cataract being more common in the etiology of binocular blindness in some studies.<sup>11,12</sup>

In this study, men significantly outnumbered women among individuals with binocular and monocular blindness applying for health committee reports. In the greater part of our society, men are more likely to be involved in business life than women. In the event of men's disability, families are faced with a lack of income which makes them more likely to apply for a report. Many visually impaired women do not need to apply for a report because men continue to provide for their families. This is supported by the fact that 85% of the 4,268 health committee applicants in our study were men.

In Turkey, there is substantial variability in the demographic and genetic characteristics of the population, economic opportunities, and other environmental factors. There is no recent comprehensive epidemiological study on blindness in this diverse country because a qualified team and equipment to evaluate a sample of randomly selected individuals that accurately represents the population would require extensive time and cost. However, epidemiological studies have great importance in determining health problems in societies. Even if such large studies cannot be conducted in our country, at least this study and similar studies may provide some insight into blindness and its causes.

**Table 2. Distribution of pathologies causing monocular blindness by gender**

Male			Female		
Pathology	n	%	Pathology	n	%
Amblyopia	17	12	Optic atrophy	4	29
Optic atrophy	16	11	AMD	3	22
Phthisis bulbi	15	10	Cataract	2	14
Blunt/perforating trauma	15	10	Other corneal diseases	2	14
Evisceration/enucleation	13	9	Amblyopia	1	7
Other	69	48	Other	2	14
Total	145	100	Total	14	100

AMD: Age-related macular degeneration

**Table 3. Distribution of pathologies causing binocular blindness by gender**

Male			Female		
Pathology	n	%	Pathology	n	%
RP	15	29	Cataract	4	33
Optical atrophy	7	13	RP	3	25
PDRP	6	12	PDRP	2	17
Other retinal diseases	4	8	Glaucoma	1	8
AMD	4	8	Other cornea diseases	1	8
Other	15	29	Other retinal diseases	1	8
Total	51	100	Total	12	100

RP: Retinitis pigmentosa, PDRP: Proliferative diabetic retinopathy, AMD: Age-related macular degeneration

As a result of our literature research, the only known epidemiological study related to blindness in our country is a study by Negrel et al.<sup>13</sup> The study included 8,571 subjects around the provinces of Diyarbakır and Mardin. The prevalence of blindness in the region was reported as 0.4% and the main causes of blindness were cataract (50%), corneal opacity (15%), glaucoma (12%), phthisis bulbi (6%), and optic atrophy (6%).<sup>13</sup> The diagnosis of corneal opacity may be associated with trachoma, as trachoma was common in the years that the study was performed. However, it is clear that this may not reflect the current primary causes of blindness in the same region, as more than two decades have passed since the study was conducted. Moreover, their results cannot be generalized to the nation as a whole.

In another prospective study conducted in a rural area of Central Anatolia, Mirza et al.<sup>14</sup> reported that the frequency of blindness was 1.5% and the three leading causes of blindness were cataract (42%), AMD (21%), and uncorrected refractive defect (13%). This study was not an epidemiological study because the study sample determined by the authors was not chosen from random individuals.<sup>14</sup> Nevertheless, this study had a relatively large sample (n=3,423) and reflected the frequency and common causes of blindness in a rural region of Turkey. Another study conducted in our country was by Ceyhan et al.<sup>15</sup>, who grouped people receiving reports from the Yüzüncü Yıl University Faculty of Medicine Hospital Health Committee (n=415) according to the frequency of ocular pathology as maculopathy (13.9%), phthisis bulbi/evicseration (12%), amblyopia (11%), and optic nerve diseases (10.6%).<sup>15</sup>

In addition, Sahin et al.<sup>16</sup> conducted a retrospective study including 88 blind people with no systemic disease who applied to the Dicle University Research Hospital Health Committee. The most important causes of blindness were collected under the heading of retinal pathologies (n=35) and RP (n=15). The leading causes of monocular blindness (n=79) were corneal and anterior segment pathologies (n=30), the most common of which was cataract/congenital cataract (n=11). However, their results did not fully reflect the true rates of blindness and ocular pathologies due to the exclusion of people with systemic diseases. As mentioned before, it is known that blindness increases with age, and the ocular pathologies that can lead to blindness at older ages were ignored in their study.<sup>16</sup>

In many developed countries, as in the US and Europe, the most common cause of blindness is AMD.<sup>7,17</sup> AMD was also reported as the most common cause of blindness in the Copenhagen and Rotterdam studies.<sup>18,19</sup> Other causes were MMD (14%), glaucoma (14%), RP (11%), and PDRP (7%) in the Copenhagen study and glaucoma (8%), cataract (6%), MMD (6%), and optic neuropathy (6%) in the Rotterdam study.<sup>18,19</sup> Looking at the rest of the world, the most common cause of blindness has been reported as cataract, especially in underdeveloped or developing countries.<sup>20,21,22,23,24</sup> In the Beijing Eye study in China, the most common causes of blindness were reported as cataract (38.5%), MMD (15.4%), and glaucoma (7%).<sup>25</sup> Cataract was also reported as the primary cause of

blindness (59.3%) in the Singapore-India Eye study, with other causes including AMD (11.1%), uncorrected refractive disorder (7.4%), MMD (7.4%), glaucoma (3.7%), PDRP (3.7%), and amblyopia (3.7%).<sup>26</sup> In the Tajimi study, which included 3,021 people in Japan, the primary causes of monocular blindness were reported to be MMD (22.4%), glaucoma (12.2%), and trauma (12.2%).<sup>27</sup> In the Barbados Eye study, the leading causes of blindness were reported to be primary open angle glaucoma (25%) and AMD (25%), followed by retinal/choroidal diseases (15%) and optic atrophy (11%).<sup>28</sup>

In the studies mentioned above, the prevalence of blindness ranged from 0.04% to 30%.<sup>12,13,14,15,16,17,18,19,20,21,22,23,24,25,26,27,28</sup> As the sample of our study did not consist of randomly selected individuals, the results do not fully reflect the prevalence of blindness in this region. Nevertheless, our study includes not only people with disabilities but also those seeking health reports for various reasons (e.g., job application, registration to higher education institutions, firearms license application). This detail should also be considered. When all age groups were examined together irrespective of gender, the frequency of monocular blindness was found to be 3.7%. Monocular blindness was seen in 2.2% of female applicants and 4% of male applicants. The frequency of binocular blindness was 1.5% in the sample overall, 1.8% in female applicants, and 1.4% in male applicants.

## Conclusion

In brief, the most important result of the present study was the detailed presentation of the ocular pathologies causing blindness. Our findings demonstrate that many of the pathologies causing monocular blindness (amblyopia, phthisis bulbi, trauma, and evicseration) and binocular blindness (PDRP, cataract, RD, trauma, glaucoma, and keratoconus) are preventable or treatable conditions. In addition, this study shows a cross-section of the diagnoses which can cause blindness. Further research to determine why these diseases continue to cause blindness is warranted. To reiterate, blindness is an important public health problem. Being aware of the pathologies that cause blindness, providing early diagnosis and treatment, and most importantly, taking preventive measures against the causes of blindness are essential both for public health and reducing the economic burden of blindness.

## Ethics

**Ethics Committee Approval:** The local ethics committee approved the study, which adhered to the principles of the Declaration of Helsinki.

**Informed Consent:** In this study, the records of individuals over 18 years of age who applied to the health committee of Meram School of Medicine Hospital between January 2015 and December 2018 were examined retrospectively.

**Peer-review:** Externally peer reviewed.

## Authorship Contributions

Concept: G.D.M., M.O., Design: G.D.M., M.O., E.M., Data Collection or Processing: G.D.M., E.M., Analysis or

Interpretation: G.D.M., S.B., M.O., Literature Search: G.D.M., E.M., Writing: G.D.M.

**Conflict of Interest:** No conflict of interest was declared by the authors.

**Financial Disclosure:** The authors declared that this study received no financial support.

## References

- Taylor HR. LXIII Edward Jackson Memorial Lecture: Eye Care: Dollars and Sense. *Am J Ophthalmol*. 2007;143:1-8.
- Roberts CB, Hiratsuka Y, Yamada M, Pezzullo ML, Yates K, Takano S, Miyake K, Taylor HR. Economic cost of visual impairment in Japan. *Arch Ophthalmol*. 2010;128:766-771.
- Cruess AF, Gordon KD, Bellan L, Mitchell S, Pezzullo ML. The cost of vision loss in Canada. 2. Results. *Can J Ophthalmol*. 2011;46:315-318.
- Resnikoff S, Pascolini D, Etya'ale D, Kocur I, Pararajasegaram R, Pokharel GP, Mariotti SP. Global data on visual impairment in the year 2002. *Bull World Organ*. 2004;82:844-851.
- Pascolini D, Mariotti SP. Global estimates of visual impairment: 2010. *Br J Ophthalmol*. 2012;96:614-618.
- Stevens GA, White RA, Flaxman SR, Price H, Jonas JB, Keeffe J, Leasher J, Naidoo K, Pesudovs K, Resnikoff S, Taylor H, Bourne RRA; Vision Loss Expert Group. Global prevalence of vision impairment and blindness: magnitude and temporal trends, 1990-2010. *Ophthalmology*. 2013;120:2377-2384.
- Bourne RRA, Flaxman SR, Braithwaite T, Cicinelli MV, Das A, Jonas JB, Keeffe J, Kempen JH, Leasher J, Limburg H, Naidoo K, Pesudovs K, Resnikoff S, Silvester A, Stevens GA, Tahhan N, Wong TY, Taylor HR; Vision Loss Expert Group. Magnitude, temporal trends, and projections of the global prevalence of blindness and distance and near vision impairment: A systematic review and meta-analysis. *Lancet Glob Health*. 2017;5:888-897.
- World Health Organization. Programme for the Prevention of Blindness and Deafness. (2000). Global initiative for the elimination of avoidable blindness. <https://apps.who.int/iris/handle/10665/63748>
- World Health Organization. World report on vision. (2019). <https://www.who.int/publications/i/item/world-report-on-vision>
- Forouhi NG, Wareham NJ. Epidemiology of diabetes. *Medicine*. 2014;42:698-702.
- Zhang XJ, Jhanji V, Leung CK, Li EY, Liu Y, Zheng C, Musch DC, Chang DF, Liang YB, Lam DS. Barriers for poor cataract surgery uptake among patients with operable cataract in a program of outreach screening and low-cost surgery in rural China. *Ophthalmic Epidemiol*. 2014;21:153-160.
- Finger RP. Cataracts in India: current situation, access, and barriers to services over time. *Ophthalmic Epidemiol*. 2007;14:112-118.
- Negrel AD, Minassian DC, Sayek F. Blindness and low vision in southeast Turkey. *Ophthalmic Epidemiol*. 1996;3:127-134.
- Mirza E, Mirza GD, Oltulu R, Okka M, Ozkagnici A. The Frequency and Causes of Blindness in a Rural Region of Central Anatolia of Turkey. *Eurasian J Med*. 2019;51:242-246.
- Ceyhan D, Yaşar T, Demirok A, Çınal A, Esmer O, Batur M. Causes of Visual Impairment in the Van City Area According to the Health Committee's Reports. *Turk J Ophthalmol*. 2012;42:131-134.
- Sahin M, Yuksel H, Sahin A, Cingu AK, Turkcu FM, Cinar Y, Özkurt ZG, Yılmaz A. Sağlık Kurulu Raporlarına Göre Diyarbakır Bölgesindeki Görme Kaybının Sebepleri. *Selçuk Tıp Derg*. 2014;30:115-117.
- Congdon N, O'Colmain B, Klaver CC, Klein R, Muñoz B, Friedman DS, Kempen J, Taylor HR, Mitchell P; Eye Diseases Prevalence Research Group. Causes and prevalence of visual impairment among adults in the United States. *Arch Ophthalmol*. 2004;122:477-485.
- Buch H, Vinding T, La Cour M, Appleyard M, Jensen GB, Nielsen NV. Prevalence and causes of visual impairment and blindness among 9980 Scandinavian adults: the Copenhagen City Eye Study. *Ophthalmology*. 2004;111:53-61.
- Klaver CC, Wolfs RC, Vingerling JR, Hofman A, de Jong PT. Age-specific prevalence and causes of blindness and visual impairment in an older population: the Rotterdam Study. *Arch Ophthalmol*. 1998;116:653-658.
- Ahmad K, Khan MD, Qureshi MB, Munami S, Shah RA, Rasheed H, Jamali B, Baluch A, Khan MA. Prevalence and causes of blindness and low vision in a rural setting in Pakistan. *Ophthalmic Epidemiol*. 2005;12:19-23.
- Oluleye TS, Ajaiyeoba AI, Akinwale MO, Olusanya BA. Causes of blindness in Southwestern Nigeria: A general hospital clinic study. *Eur J Ophthalmol*. 2006;16:604-607.
- Abdull MM, Sivasubramaniam S, Murthy GV, Gilbert C, Abubakar T, Ezelum C, Rabi MM; Nigeria National Blindness and Visual Impairment Study Group. Causes of Blindness and Visual Impairment in Nigeria: The Nigeria National Blindness and Visual Impairment Survey. *Invest Ophthalmol Vis Sci*. 2009;50:4114-4120.
- Sainz-Gómez C, Fernández-Robredo P, Salinas-Alamán A, Montañés JM, Escudero Berasategui JM, Guillén-Grima F, Ruiz-Moreno JM, García-Layana A. Prevalence and causes of bilateral blindness and visual impairment among institutionalized elderly people in Pamplona, Spain. *Eur J Ophthalmol*. 2010;20:442-450.
- Rabi MM, Al Bdour MD, Abu Ameerh MA, Jadoon MZ. Prevalence of blindness and diabetic retinopathy in northern Jordan. *Eur J Ophthalmol*. 2015;25:320-327.
- Xu L, Wang Y, Li Y, Wang Y, Cui T, Li J, Jonas JB. Causes of blindness and visual impairment in urban and rural areas in Beijing: the Beijing Eye Study. *Ophthalmology*. 2006;113:1134-1141.
- Zheng Y, Lavanya R, Wu R, Wong WL, Wang JJ, Mitchell P, Cheung N, Cajucom-Uy H, Lamoureux E, Aung T, Saw SM, Wong TY. Prevalence and causes of visual impairment and blindness in an urban Indian population: The Singapore Indian Eye Study. *Ophthalmology*. 2011;118:1798-1804.
- Iwase A, Araie M, Tomidokoro A, Yamamoto T, Shimizu H, Kitazawa Y; Tajimi Study Group. Prevalence and causes of low vision and blindness in a Japanese adult population: the Tajimi Study. *Ophthalmology*. 2006;113:1354-1362.
- Hyman L, Wu SY, Connell AM, Schachat A, Nemesure B, Hennis A, Leske MC. Prevalence and causes of visual impairment in the Barbados Eye Study. *Ophthalmology*. 2001;108:1751-1756.



# The Surgeon's Role in Inducing and Controlling Motion Errors During Intraocular Membrane Peeling Procedures

✉ Mahmut Dođramacı\*, ✉ David Steel\*\*

\*Princess Alexandra Hospital, Clinic of Ophthalmology, Essex, United Kingdom

\*\*Sunderland Eye Infirmary, Queen Alexandra Rd, Sunderland, UK and Bioscience Institute, Newcastle University, Newcastle Upon Tyne, United Kingdom

## Abstract

**Objectives:** To understand the surgeon's role in inducing and correcting movement inaccuracies during intraocular membrane peeling procedures.

**Materials and Methods:** Optical sensors were used to record movement errors during actuation at the distal tip of 23-gauge pneumatic forceps both when the handle was handheld and when fixed with no human contact. Movements were also recorded at the proximal part of the forceps shaft (near the sclerotomy site) and compared to movement recorded at the distal end. The root mean square (RMS) and range values of the signals obtained from the sensors were calculated before and after applying high (7-13 Hz) and low (<5 Hz) frequency filters.

**Results:** Comparison of RMS and range values of movement errors at the distal end of the forceps during actuation when the forceps handle was fixed and handheld showed that without human contact, these values were significantly lower in the X axis at all frequencies and in the Z axis at high frequencies compared to handheld ( $p<0.05$ ), while there were no significant differences in the Y axis. Comparison of values from the distal and proximal ends of the forceps showed that when the forceps were fixed, RMS and range values were significantly higher for movement errors at the distal end compared to the proximal end at all frequencies ( $p<0.05$ ). There was significant positive correlation between the extent of actuation and the RMS and range values for high-frequency movement errors but not low-frequency errors in all three axes with the fixed pneumatic handle ( $r=0.21-0.51$ ,  $p<0.05$ ).

**Conclusion:** Surgeon- and non-surgeon-related errors are apparent in all axes, but skilled surgeons correct these errors through visual feedback, resulting in better correction in the visible planes. Sclerotomy sites provide a pivoting and stabilizing point for the shaft of the forceps and it is likely that skilled surgeons make use of the sclerotomy point to dampen motion errors, a skill worth teaching to beginners.

**Keywords:** Vitrectomy, epiretinal membrane, intraocular forceps, macular hole, surgical errors

## Introduction

Handheld vitreoretinal forceps are widely used to peel membranes from the retinal surface.<sup>1,2</sup> Unintentional movement errors at the forceps tips may occur during membrane peeling, with loss of precision and potential surgical trauma. Previous studies showed that significant movement errors can happen while actuating the system, which adds another layer of activity

and consumes the surgeon's attention. This correlation was not restricted to one surgeon or to one type of instrument handle.<sup>3,4,5,6</sup> In an attempt to provide better control over the actuation process and reduce unintentional movements, pneumatically driven handpieces were introduced (CONSTELLATION® Pneumatic Hand Piece, GRIESHABER® Advanced DSP tips). These handles are designed to be lightweight and ergonomic with superior control of actuation through a foot

**Address for Correspondence:** Mahmut Dođramacı, Princess Alexandra Hospital, Clinic of Ophthalmology, Essex, United Kingdom  
E-mail: mahmutdogramaci@hotmail.com **ORCID-ID:** orcid.org/0000-0002-0424-8455

**Received:** 07.08.2020 **Accepted:** 05.11.2020

**Cite this article as:** Dođramacı M, Steel D. The Surgeon's Role in Inducing and Controlling Motion Errors During Intraocular Membrane Peeling Procedures. Turk J Ophthalmol 2021;51:288-293



pedal. However, opinions about pneumatically powered forceps vary, with some surgeons feeling that it offers an easier way to initiate internal limiting membrane peeling, while others demonstrated using optical sensors that pneumatically driven handles were not superior to manually operated handles in reducing low-frequency inadvertent movements when used by surgeons experienced in manually driven handles.<sup>4,7</sup> This finding suggests that some of these movement errors could be due to surgeons' muscle memory or perhaps the interaction of different parts of the forceps with each other and with surrounding tissues. In this study we aimed to understand surgeons' contributions, both positive and negative, to movement errors in pneumatically driven forceps.

## Materials and Methods

We used optical sensors to record the Cartesian coordinates of the grasping tips of intraocular forceps and simultaneously monitor the extent of their actuation. The testing system has been described previously. Briefly, reflective optical sensors (ROS) (Vishay semiconductors, model TCRT5000) were used. The reflective sensors include infrared emitters with a wavelength of 950 nm and phototransistors that are blocked to visible light. The ROS dimensions were 10.2x5.8x7 mm with a peak operating distance of 2.5 mm and an operating range of 0.2 to 15 mm. Three peripheral ROS were fitted into purpose-built slots on a 42 mm diameter plastic hemisphere. The slots were designed to hold the ROS at a distance of 10 mm from and at a right angle to the panels. A central ROS was also fitted to the shaft-forming tube facing the first panel, which was perpendicular to the grasping end of the tool. Three flat circular plastic panels were also attached to the shaft of the intraocular forceps at right angles to each other.<sup>2</sup> A front panel was fitted perpendicular to the end of the grasping tip and two side panels were fitted parallel to the shaft of the forceps. The shaft of the forceps was introduced into the hemisphere through a hole mimicking a sclerotomy.<sup>4</sup> During the experiments, the tip of a pneumatic hand piece (CONSTELLATION®) attached to a 23-gauge tip (GRIESHABER® Advanced DSP) was held in the center of the hemisphere to enable recordings from all three sensors while the actuation process was carried out. Measurements were repeated for 4 actuation cycles using foot pedal control. When the system was used to record movement errors in the absence of the surgeons' influence, the handle of the forceps was attached to the plastic hemisphere housing the optical sensors to eliminate any movements between the handle and the sensors. However, when the system was used to record the surgeons' influence, two vitreoretinal surgeons who were trained in the United Kingdom, had previous surgical experience of at least 2,000 retinal and 500 macular surgeries, and held substantive vitreoretinal consultant posts in the National Health Service at the time of study were asked to hold the pneumatic handle manually and try to keep the tip under a fixed stylus which was fitted to a point at the center of the field. Each four-cycle experiment was repeated 5 times and carried

out under direct viewing system with an operating microscope to mimic the operative situation.

Furthermore, in the current study we also compared the movements of the forceps shaft both at its distal part (away from sclerotomy site) and its proximal part (closer to sclerotomy site) in the absence of the surgeon's influence. This was done by modifying the panels to enable their attachment to the proximal part of the forceps while the handle was attached to the plastic hemisphere and recording the panels' movements during actuation. Figure 1 shows the details of the recording system, the modified panels attached to the proximal and distal parts of the shaft, and the alignment of the axes in relation to the forceps distal end.

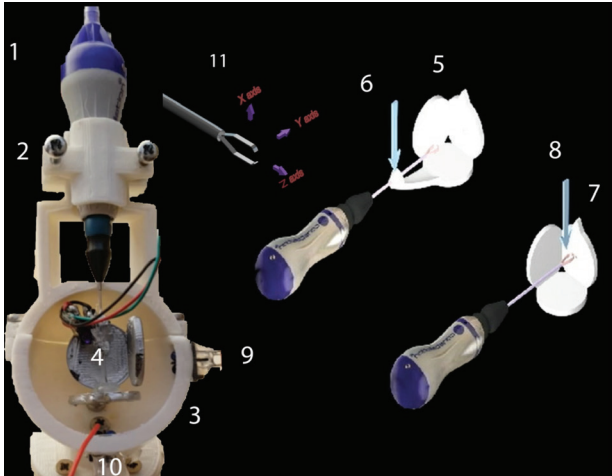
During the experiments, data were recorded in 4 meridians: (1) anteroposterior (X axis): deflection of the grasping tip towards or away from the user, an axis that is perpendicular to the user in the sagittal plane and therefore the least visible to the user, (2) lateral (Y axis): deflection of the grasping tip sideways, (3) depth (Z axis): the length of forceps shaft inside the sphere, reflecting the movement of the forceps tip closer to and further from the retina, and (4) actuation (A axis): advancement of the shaft from its actuation tube. Data regarding the distance between the peripheral ROS and the panels were used to determine the position of the grasping tip within the hemisphere, and data regarding the distance between the central ROS and the front panel were used to determine the extent of actuation. Calibration was performed as described in our previous study.<sup>4</sup> Figure 2 shows movement errors in the X, Y, and Z axes and actuation extent recorded from pneumatically driven forceps being held by hand but pneumatically actuated by foot pedal.

Root mean square (RMS) values for the recorded data were calculated before and after applying a third-order Butterworth filter with corner frequencies at 7 and 13 Hz, and a low pass filter with corner frequency of 5 Hz to enable specific analysis of high-frequency (physiologic tremor) and low-frequency (drifts and jerks) involuntary movements, respectively. The resulting data were nonparametric; therefore, the Spearman correlation coefficient was used to determine the significance of the correlation between extent of actuation and involuntary movements, and the Mann-Whitney U test was used to compare the RMS and ranges of involuntary movements for different settings.  $P < 0.05$  was considered statistically significant.

## Results

In the Y axis, the RMS and range values of movement errors for a fixed pneumatic handle at all frequencies, low frequencies, and high frequencies were not significantly different from those for a handheld pneumatic handle. Regarding the X axis, the RMS and range values of movement errors for a fixed pneumatic handle for all frequencies, low frequencies, and high frequencies were significantly lower than those recorded with the handheld pneumatic handle ( $p < 0.05$ ). In the Z axis, the RMS and range

values of movement errors for a fixed pneumatic handle for all frequencies and low frequencies were not significantly different from those for handheld forceps. However, the RMS and range values of high-frequency movement errors for a fixed pneumatic were significantly higher compared to those detected with handheld handle ( $p < 0.05$ ). Table 1 shows the RMS and range values in each axis and all frequencies both with fixed and handheld forceps.



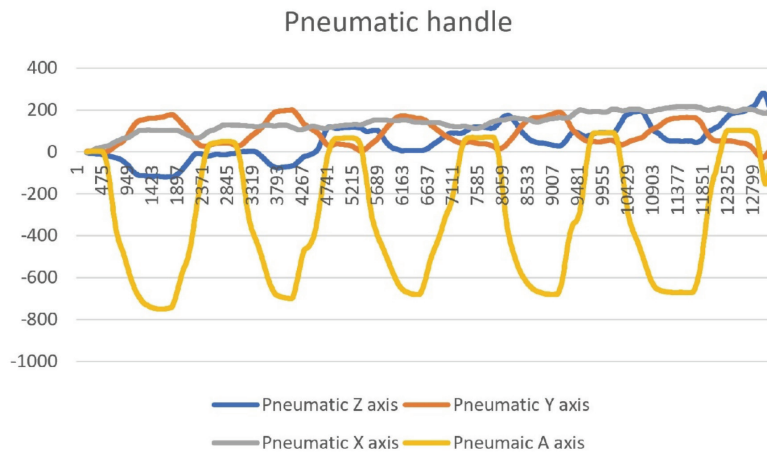
**Figure 1.** The system used to record movement errors. 1: Pneumatically powered handle (Constellation pneumatic DSP). 2: Specially designed slot for secure attachment of the handle to the hemisphere that houses the optical sensor, to eliminate surgeon related errors. 3: A plastic hemisphere, housing 3 optical sensors to monitor movements in directions X, Y, and Z. 4: An optical sensor attached to the shaft of the forceps to monitor the extent of actuation. 5: Plastic panels designed to translate movements from the proximal part of the shaft of the forceps, closer to sclerotomy site. 6: Proximal attachment location. 7: Plastic panels designed to translate movements from the distal part of the forceps away from sclerotomy site. 8: Distal attachment location. 9: Optical sensors detecting movement errors in the Y axis. 10: Optical sensors detecting movement in the Z axis. Note optical sensors detecting movements in the X axis are located behind the forceps. 11: The definition of the X, Y, and Z axes in relation to the distal end of the forceps

When the distal and proximal parts of the forceps were compared, RMS and range values of overall movement errors in all 3 axes in all frequencies, low frequencies, and high frequencies for the distal end of the forceps were significantly higher than those for the proximal parts of the forceps. Table 2 shows the RMS and range values for the distal and the proximal parts of the forceps shaft.

Regarding the relationship between movement errors and extent of actuation, there was a statistically significant positive correlation between the extent of actuation and the RMS and range values for high-frequency movement errors with the fixed pneumatic handle with no human contact in all three axes ( $p \leq 0.05$ ). Spearman's rho correlation coefficients for this correlation were 0.285 and 0.205 in the X axis, 0.478 and 0.415 in the Y axis, and 0.506 and 0.431 in the Z axis, respectively. However, correlations between the extent of actuation and low-frequency movement and all-frequency movements were not statistically significant. Table 3 shows the correlation between the extent of actuation and low-frequency errors at the distal end of a 23-gauge forceps attached to a fixed pneumatic handle.

### Discussion

Movement errors during intraocular membrane peel procedures may result in tissue damage and irreversible sight-threatening complications.<sup>8,9</sup> Such errors have been previously investigated and separated into high-frequency movement errors representing physiological tremor, and low-frequency movement errors representing jerks, deflections, and drifts. Low-frequency movement errors are of greater amplitude than high-frequency ones and could be more harmful and more noticeable when the operator attempts to actuate the forceps manually by squeezing the handle to achieve closure of the forceps blades.<sup>3,4,10,11,12,13,14</sup> Therefore, pneumatically powered forceps remotely actuated via foot pedals were introduced to reduce such errors. However, previous studies showed that



**Figure 2.** Movement errors before applying frequency filters detected in the X, Y and Z axes along with actuation extent recorded for pneumatically driven forceps being held by hand but pneumatically actuated by foot pedal

such forceps were only superior to manually actuated ones in reducing high-frequency movement errors. Previous studies have suggested that the effect of actuation on movement errors was less prominent when the surgeon factor was eliminated; however, the nature of the surgeon's influence on movement errors was not investigated further.<sup>4</sup> In this study, we performed an in-depth analysis of surgeons' influence on inducing/dampening movement errors in different axes and frequencies using pneumatically powered and foot pedal-controlled forceps. We chose to use optical sensors to record movements at different parts of the forceps shaft. This methodology is not only proven to be reliable but also gives the option of eliminating surgeon influence by attaching the handle to the frame of the testing rig.<sup>4</sup>

Our study showed that holding pneumatically powered forceps by hand influenced movement errors in different ways in different axes. In the Y and Z axes, for example, holding

the forceps by hand did not significantly influence movement errors with the exception of an increase in high-frequency errors in the Z axis. However, eliminating the influence of the surgeons' hand by attaching the forceps to the frame of the rig improved movement errors in all frequencies in the X axis. This meant that surgeon-related movement errors were more prominent in the X axis. One possible explanation for this finding is that the X axis was less visible to the surgeons during the experiments, while the Y and Z axes were in the plane perpendicular to their visual axis, which possibly provided visual feedback on movement errors caused by their hands and enabled them to dampen these errors.

The current study also revealed that movement errors are more pronounced at the distal end, away from the pivoting point at the sclerotomy site. Previous studies also showed higher movement errors when the sensors were attached to the handle end of the forceps away from sclerotomy site.<sup>15</sup>

**Table 1. Comparison of the RMS and range values of all-, low-, and high-frequency movement errors with a handheld pneumatically powered forceps and fixed pneumatically powered forceps with no human contact. The data show that eliminating the surgeon factor reduces movement errors, but only in the X axis, the axis not visible to the operating surgeon**

Frequency	Parameter	Operator	Vector Y			Vector X			Vector S		
			Mean	SD	p value*	Mean	SD	p value*	Mean	SD	P value*
All	RMS	Fixed	165.16	77.69	0.10	34.35	22.66	<0.001	277.90	196.50	0.93
		Handheld	89.98	36.66		148.93	26.27		220.83	94.26	
	Range	Fixed	438.67	166.94	0.12	116.67	45.30	<0.001	1032.67	570.53	0.31
		Handheld	326.00	115.02		438.00	179.78		678.00	294.48	
Low (<5 Hz)	RMS	Fixed	164.21	77.67	0.10	34.06	22.77	<0.001	276.37	196.56	0.93
		Handheld	89.22	36.67		148.05	25.85		219.87	94.29	
	Range	Fixed	416.07	157.92	0.12	104.92	41.34	<0.001	935.36	552.34	0.55
		Handheld	316.46	121.91		410.92	166.78		665.52	289.31	
High (7-13 Hz)	RMS	Fixed	2.43	0.84	0.14	0.78	0.21	<0.001	9.62	4.09	<0.001
		Handheld	1.82	0.27		1.82	0.29		1.89	0.45	
	Range	Fixed	35.99	12.16	0.05	8.73	2.82	<0.001	154.49	59.61	<0.001
		Handheld	21.40	10.11		19.35	4.71		24.28	4.33	

\*Mann-Whitney U test, RMS: Root mean square, SD: Standard deviation

**Table 2. Comparison of the RMS and range values of movement errors at the distal and proximal parts of the forceps shaft revealed significant differences between movement errors at the distal end and proximal parts of the forceps**

Frequency	Location	RMS			Range		
		Mean	SD	p value*	Mean	SD	p value*
All	Distal	160.94	170.62	<0.001	543.78	631.05	<0.001
	Proximal	55.51	47.82		140.78	88.45	
Low (<5 Hz)	Distal	150.83	170.53	<0.001	448.63	535.60	<0.001
	Proximal	54.68	47.15		132.20	86.93	
High (7-13 Hz)	Distal	15.48	36.99	0.05	164.80	302.18	0.04
	Proximal	1.29	1.16		19.07	21.04	

\*Mann-Whitney U test, RMS: Root mean square, SD: Standard deviation

**Table 3. Correlations between the extent of actuation and movement errors of different frequencies and in different axes for the distal end of a 23-gauge tip mounted on a pneumatically driven fixed handle in the absence of human contact. There was a statistically significant positive correlation between the extent of actuation and high-frequency movement errors but no significant correlation with all- and low-frequency movement errors**

Correlations Spearman's rho RMS							
Frekans		X_RMS	Y_RMS	Z_RMS	X_RMS	Y_RMS	Z_RMS
All	Correlation coefficient	-0.06	0.01	-0.14	-0.13	-0.07	-0.11
	Sig. (2-tailed)	0.61	0.91	0.18	0.22	0.54	0.30
Low	Correlation coefficient	0.00	0.06	-0.07	-0.08	0.01	-0.08
	Sig. (2-tailed)	0.98	0.56	0.51	0.43	0.91	0.48
High	Correlation coefficient	0.29	0.48	0.51	0.21	0.42	0.43
	Sig. (2-tailed)	0.01	<0.001	<0.001	0.05	<0.001	<0.001

RMS: Root mean square

This finding is most likely due to the stabilizing effect of the sclerotomy site. However, it should be noted that the distal end of the forceps is where the action of peeling takes place. The distance between the distal end of the forceps and the finger position of the surgeon is roughly 40 mm with a pivot point at sclerotomy site located approximately at the mid-distance.<sup>4</sup> It is likely that experienced surgeons are making the use of the stabilizing effect of sclerotomy sites to dampen movement errors that they become aware of through visual feedback.<sup>5,16</sup>

Another interesting finding of the current study was the disappearance of the correlation between low-frequency movement errors and the actuation process when the influence of the surgeons' hand was eliminated. This kind of correlation was previously reported not only with manually actuated forceps but also with pneumatically powered forceps when held by hand.<sup>4</sup> Our finding supports the hypothesis put forward in previous studies, that surgeons who are more experienced in manually actuating forceps tend to inadvertently use their hand muscles during foot pedal actuation due to long-term muscle memory.

#### Study Limitations

One of the limitations of the study was the influence of surgeons' experience on the outcome. However both surgeons were experienced, and bias was further reduced by repeating the experiments multiple times.

#### Conclusion

In conclusion, surgeon- and non-surgeon-related motion errors are apparent in all axes, but skilled surgeons adopt a mechanism to correct these errors. The correction mechanism works best in the plane that provides the most visual feedback to the surgeon. Sclerotomy sites provide a pivoting and stabilizing point for the shaft of the forceps and it is likely that skilled surgeons with good visual-motor coordination make use of the sclerotomy point to dampen motion errors, a skill worth teaching to beginners.<sup>17</sup> Eye surgery simulation systems like Eye Si could play an important part in developing visual-motor coordination and reducing unintentional hand

movements.<sup>17,18,19,20</sup>

#### Ethics

**Ethics Committee Approval:** Since this research is a laboratory study, ethics committee approval is not required.

**Peer-review:** Externally peer reviewed.

#### Authorship Contributions

Surgical and Medical Practices: M.D., D.S., Concept: M.D., D.S., Design: M.D., D.S., Data Collection or Processing: M.D., D.S., Analysis or Interpretation: M.D., D.S., Literature Search: M.D., Writing: M.D.

**Conflict of Interest:** No conflict of interest was declared by the authors.

**Financial Disclosure:** The authors declared that this study received no financial support.

#### References

- Dogramaci M, Williamson TH. Dynamics of epiretinal membrane removal off the retinal surface: a computer simulation project. *Br J Ophthalmol*. 2013;97:1202-1207.
- Henrich PB, Monnier CA, Halfter W, Haritoglou C, Strauss RW, Lim RY, Lopicar M. Nanoscale Topographic and Biomechanical Studies of the Human Internal Limiting Membrane. *Nanoscale Studies of the Human ILM*. Invest Ophthalmol Vis Sci. 2012;53:2561-2570.
- Riviere CN, Rader RS, Khosla PK. Characteristics of hand motion of eye surgeons. *IEEE*. 1997;4:1690-1693.
- Dogramaci M, Steel DH. Unintentional movements during the use of vitreoretinal forceps. *Transl Vis Sci Technol*. 2018;7:28.
- Balicki M, Uneri A, Iordachita I, Handa J, Gehlbach P, Taylor R. Micro-force Sensing in Robot Assisted Membrane Peeling for Vitreoretinal Surgery. *Med Image Comput Comput Assist Interv*. 2010;13:303-310.
- Gonenc B, Feldman E, Gehlbach P, Handa J, Taylor RH, Iordachita I. Towards Robot-Assisted Vitreoretinal Surgery: Force-Sensing Micro-Forceps Integrated with a Handheld Micromanipulator. *IEEE Int Conf Robot Autom*. 2014;2014:1399-1404.
- Charles M. Closed system and expanded instrumentation improves MIVS outcomes. *Retina Today*. 2011:84-89.
- Gonenc B, Balicki MA, Handa J, Gehlbach P, Riviere CN, Taylor RH, Iordachita I. Evaluation of a Micro-Force Sensing Handheld Robot for Vitreoretinal Surgery. *Rep U S*. 2012;2012:4125-4130.
- Hubschman JP, Bourges JL, Choi W, Mozayan A, Tsiaras A, Kim CJ, Schwartz SD. 'The Microhand': a new concept of micro-forceps for ocular robotic surgery. *Eye (Lond)*. 2010;24:364-367.

10. Harwell RC, Ferguson RL. Physiologic tremor and microsurgery. *Microsurgery*. 1983;4:187-192.
11. Schenker PS, Barlow EC, Boswell C, Das H, Lee S, Ohm TR, Paljug ED, Rodriguez G, Charles ST. Development of a telemanipulator for dexterity enhanced microsurgery. *2nd Intl Symp Med Robot Comput Assist Surg* 1995:81-88.
12. Song C, Gehlbach PL, Kang JU. Swept source optical coherence tomography based smart handheld vitreoretinal microsurgical tool for tremor suppression. *Annu Int Conf IEEE Eng Med Biol Soc* 2012;2012:1405-1408.
13. Song C, Gehlbach PL, Kang JU. Active tremor cancellation by a "Smart" handheld vitreoretinal microsurgical tool using swept source optical coherence tomography. *Opt Express*. 2012;20:23414-23421.
14. Riviere CN, Khosla PK. Accuracy in positioning of handheld instruments. *Engineering in Medicine and Biology Society, Bridging Disciplines for Biomedicine. Annu Int Conf IEEE Eng Med Biol Soc*. 1996:212-213.
15. Gomez-Blanco M, Riviere CN, Khosla PK. Intraoperative tremor monitoring for vitreoretinal microsurgery. *Stud Health Technol Informs*. 2000;70:99-101.
16. Mazinani BA, Rajendram A, Walter P, Roessler GF. Does surgical experience have an effect on the success of retinal detachment surgery? *Retina*. 2012;32:32-37.
17. Kottke FJ, Halpern D, Easton JK, Ozel AT, Burrill CA. The training of coordination. *Arch Phys Med Rehabil*. 1978;59:567-572.
18. Omata S, Someya Y, Adachi S, Masuda T, Hayakawa T, Harada K, Mitsuishi M, Totsuka K, Araki F, Takao M, Aihara M, Arai F A. A surgical simulator for peeling the inner limiting membrane during wet conditions. *PLoS one*. 2018;13:e0196131.
19. Hunter IW, Jones LA, Sagar MA, Lafontaine SR, Hunter PJ. Ophthalmic microsurgical robot and associated virtual environment. *Comput Biol Med*. 1995;25:173-182.
20. Grodin MH, Johnson TM, Acree JL, Glaser BM. Ophthalmic surgical training: a curriculum to enhance surgical simulation. *Retina*. 2008;28:1509-1514.



# Experimental Laboratory Modeling of Choroidal Vasculature: A Study of the Dynamics of Intraoperative Choroidal Hemorrhage during Pars Plana Vitrectomy

✉ Mahmut Dođramacı\*, ✉ Funda Dikkaya\*\*, ✉ Fevzi Őentürk\*\*, ✉ Cengiz Aras\*\*

\*Princess Alexandra Hospital, Clinic of Ophthalmology, Essex, United Kingdom

\*\*Medipol University Faculty of Medicine, Department of Ophthalmology, İstanbul, Turkey

## Abstract

**Objectives:** Choroidal hemorrhages (CH) result from rupture of choroidal vessels leading to extravasation of blood into the suprachoroidal space. In this study, we aimed to understand the hemodynamics of CH by developing a purpose-built scale model of the choroidal vasculature and calculating stress levels in the model under different conditions.

**Materials and Methods:** We modeled the choroidal vasculature using a rubber tube 10 cm in length and 1 cm in diameter that was wrapped with conductive thread to enable the measurement of stress at the walls of the tube. Stress levels across the tube were continuously measured under different systemic intravascular blood pressure levels (IVP), intraocular pressure (IOP) levels, and distortion.

**Results:** Stress values across the choroidal vessel model correlated negatively with IOP and positively with IVP and distortion. All correlations were statistically significant ( $p < 0.05$ ) and were stronger when the model was filled with expansile tamponade compared to non-expansile tamponades. Distortion showed the strongest correlation in terms of increasing stress across the model, while IVP showed stronger correlation compared to IOP. Raising IOP to counteract the stress in the model was effective when the stress in the model was secondary to increased IVP, but this approach was not effective when the stress in the model was caused by distortion.

**Conclusion:** Excessive distortion of the globe during surgical maneuvers could be the primary reason for the rarely observed intraoperative CH. Non-expansile ocular tamponade provides better support for the vascular bed against CH and should be the recommended choice of tamponade in patients with existing CH. Increasing IOP excessively is of limited effect in preventing CH in vessels that are under stress as a result of distorting surgical maneuvers.

**Keywords:** Choroid hemorrhage, vitrectomy, choroid, suprachoroidal space

## Introduction

Choroidal hemorrhages (CH) are relatively uncommon but can lead to devastating outcomes. They result from rupture of arterioles, venules, and capillaries which initially lead to extravasation of blood into the choroid and subsequently into the suprachoroidal space.<sup>1</sup> Possible mechanisms for vascular ruptures are believed to be drop in intraocular pressure (IOP), increase in systemic blood pressure, distortion of the vascular architecture, and direct injury to the blood vessels. However, these suppositions have not been supported by experimental

data. Therefore, research to understand the hemodynamics of CH is important to enable surgeons to take effective measures to reduce the risks. Surgeons are generally advised to avoid hypotony during surgery, refrain from operating on patients with high systemic blood pressure, and minimize the use of expansile tamponades in high-risk patients. However, the role of avoiding inadvertent intraoperative distortion of ocular tissues in prevention of CH is generally underemphasized. Nevertheless, mathematical models showed that globe distortion from mechanical strain plays a more important

**Address for Correspondence:** Funda Dikkaya, Medipol University Faculty of Medicine, Department of Ophthalmology, İstanbul, Turkey

E-mail: fundadikkaya@hotmail.com **ORCID-ID:** orcid.org/0000-0003-2312-2521

**Received:** 24.07.2020 **Accepted:** 29.12.2020

**Cite this article as:** Dođramacı M, Dikkaya F, Őentürk F, Aras C. Experimental Laboratory Modeling of Choroidal Vasculature: A Study of the Dynamics of Intraoperative Choroidal Hemorrhage during Pars Plana Vitrectomy. Turk J Ophthalmol 2021;51:294-300

©Copyright 2021 by Turkish Ophthalmological Association  
Turkish Journal of Ophthalmology, published by Galenos Publishing House.

role in causing CH compared to hypotony or increased systemic blood pressure.<sup>2</sup> Therefore, in this study we aimed to understand the hemodynamics of CH by creating a purpose-built scale model of the choroidal vasculature and calculating stress levels in the model under different conditions.

## Materials and Methods

The choroidal vasculature was modeled using a rubber tube 10 cm in length and 1 cm in diameter wrapped with conductive thread to enable the measurement of stress at the walls of the tube. The tube was filled with clear water and pressurized to various levels using an electric pump to simulate systemic intravascular blood pressure (IVP) and placed into a sealed container which was also pressurized to various levels to simulate variable IOP. A hydraulic actuator was also used to apply various longitudinal strain on the tube to simulate ocular distortion during surgical maneuvers. The stress levels in the tube were continuously monitored under different IVP, IOP, and distortion levels. IOP and IVP were measured in mmHg and stress was measured in Pascals (Pa), while distortion was measured as percentage of change in the length of the model (e.g., stretching the 10-cm rubber tube to 11 cm correlated to 10% distortion) (Figure 1, 2).

The experiments were carried out in two phases. Phase 1 consisted of 3 sets of experiments that aimed to observe changes in stress levels in the choroidal vasculature in relation to changes in IOP, systemic blood pressure, and longitudinal strain. Phase 2 consisted of 2 sets of experiments that aimed to observe the benefits of increasing the IOP to counteract high stress levels in the choroidal vasculature secondary to high systemic blood pressure and ocular distortion.

During phase 1, initially stress measurements were taken while dropping the IOP from 35 mmHg to 0 mmHg while maintaining IVP at 120 mmHg and distortion at 0%. These conditions reflected the effect of hypotony on the choroidal vasculature. Subsequently, stress measurements were taken while increasing IVP from 120 mmHg to 200 mmHg while maintaining IOP at 35 mmHg and distortion at 0%. These conditions reflected the effect of high systemic blood pressure on the choroidal vasculature. Finally, stress measurements were taken while gradually distorting the model up to 12% of its length while maintaining IOP at 35 mmHg and IVP at 120 mmHg. These conditions reflected the effect of perioperative ocular distortion on the choroidal vasculature.

In phase 2, stress levels in the choroidal vasculature were first increased up to 6 Pa by raising the IVP followed by a gradual increase in IOP from 35 mmHg to 80 mmHg to counteract the stress. These conditions reflected the role of increasing IOP during surgery to prevent CH in patients with high systemic blood pressure. Subsequently, the tests were repeated but this time distortion was used to raise the stress levels in the choroidal vasculature to 6 Pa while the

IVP remained at 120 mmHg followed by a gradual increase in IOP from 35 mmHg to 80 mmHg to counteract the stress. These conditions reflected the role of increasing IOP during surgery to prevent CH in eyes subjected to distortion during surgery.

## Statistical Analysis

All tests were performed separately while the container was filled with water and with air to reflect eyes filled with non-expansile tamponades and with expansile tamponades, respectively. To enhance accuracy and enable statistical analysis, each test was repeated 10 times. Spearman's correlation was used to assess the statistical significance of the observations. Correlations were considered significant when p value was  $\leq 0.05$ . Statistical analyses were performed using SPSS software version 18 (SPSS Inc., Chicago, IL, USA) (Table 1).

## Results

The first set of experiments in phase 1 showed a statistically significant negative correlation between stress in the choroidal vasculature and IOP while IVP was fixed at 120 mmHg and distortion was 0%. The correlation was stronger when the model was filled with expansile tamponade. Spearman's correlation rho was -0.504 ( $p < 0.001$ ) and stress levels reached 1.7 Pa when the model was filled with expansile tamponade compared to Spearman's rho of -0.190 ( $p < 0.001$ ) and stress levels up to 0.1 Pa when the model was filled with non-expansile tamponade. The second set of experiments in phase 1 also showed a statistically significant but positive correlation between stress in the choroidal vasculature and IVP while IOP was fixed at 35 mmHg and distortion was 0%. The correlation was stronger when the model was filled with expansile tamponade, as Spearman's correlation rho was -0.771 ( $p < 0.001$ ) and stress levels reached a maximum of 61 Pa when the model was filled with expansile tamponade compared to Spearman's rho of 0.570 ( $p < 0.001$ ) and stress levels up to 9.9 Pa when the model was filled with non-expansile tamponade. The third set of experiments in phase 1 also showed a statistically significant positive correlation between stress in the choroidal vasculature and the extent of distortion applied on the tubular structure while IOP was fixed at 35 mmHg and IVP was fixed at 120 mmHg. However, the strength of the correlation was almost the same both when the container was filled with expansile tamponade (Spearman's rho 0.624,  $p < 0.001$ ) and with non-expansile tamponade (Spearman's rho 0.629,  $p < 0.001$ ) (Figure 3).

When the role of increasing IOP in counteracting stress in the choroidal vasculature was tested in phase 2, the first set of experiments showed a statistically significant negative correlation between IOP and stress in the choroidal vasculature when the stress was due to increased IVP. This correlation was marginally stronger when the container was filled with expansile

tamponade (Spearman’s rho -0.670,  $p < 0.001$ ) compared to non-expansile tamponade (Spearman’s rho -0.580,  $p < 0.001$ ). However, the second set of experiments in phase 2 surprisingly showed a statistically significant positive correlation between IOP and stress in the choroidal vasculature when the stress was caused by distortion. This correlation was almost the same both when the container was filled with expansile tamponade (Spearman’s rho 0.419,  $p < 0.001$ ) and non-expansile tamponade (Spearman’s rho 0.413,  $p < 0.001$ ) (Figure 4).

### Discussion

Hemorrhages in highly vascular choroid can arise from ciliary arteries, arterioles, venules, and capillaries. Hypotony<sup>3,4,5,6</sup> and high systemic blood pressure<sup>7,8</sup> are regarded as common contributing factors in addition to glaucoma<sup>7,9</sup>, aphakia<sup>10</sup>, and advanced age.<sup>3,9</sup> It is believed that hypotony (e.g., caused by incising the eyeball) induces a vascular pressure gradient that leaves the vascular bed unsupported. Blood pressure can rise in the unsupported vascular bed, leading to a rupture, particularly in the presence of other contributing factors like arteriolar necrosis of the short and long posterior ciliary arteries.<sup>7,11</sup> Alternatively, increased IVP (e.g., from obstructing the outflow of the vortex veins) can also increase pressure

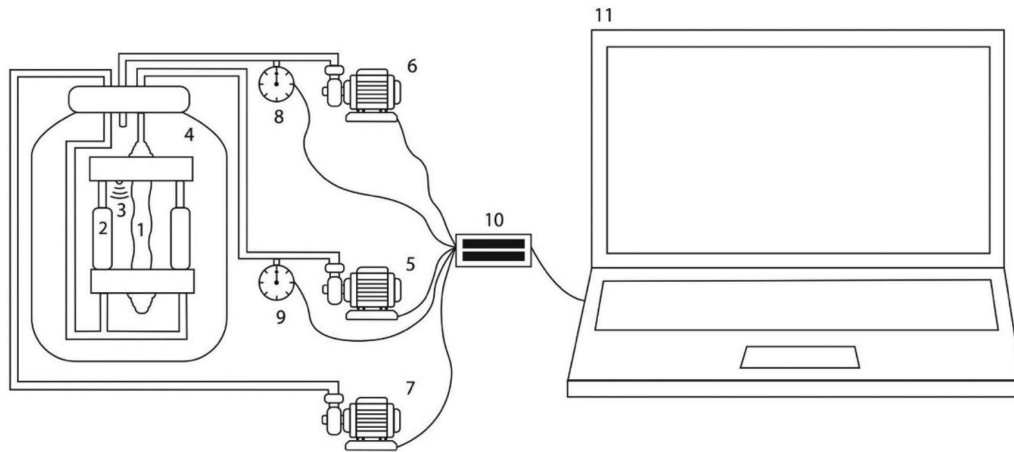
in the long and short posterior ciliary arteries, leading to rupture.<sup>8,12</sup> Nevertheless, pressure in the choroidal vasculature is also susceptible to direct or indirect distortion, such as when the eyeball is inadvertently deformed during surgical maneuvers. Ocular distortion can force the outer and middle ocular coats to slide over each other, as these coats are only separated by a thin layer of fluid and sheets of fine collagen fibrils. Therefore, the vasculature around the suprachoroidal space must be competent enough to withstand not only the transmural pressure gradient but also the relative motion between ocular coats to avoid suprachoroidal hemorrhage.<sup>13,14</sup>

Several reports in the literature have described experimental rabbit eye models of expulsive CH. In all these models, high IVP was induced by obstructing the venous flow through blocking or ligating the vortex veins or by inducing proptosis using latex bands, while hypotony in these models was induced by incising the globe or removing the corneal button.<sup>12,13,14</sup> In contrast to earlier studies, we used a novel in vitro model of the choroidal vasculature, this approach enabled us to precisely calculate stress levels in the choroidal vasculature and study their relation with gradual changes in IOP, IVP, and distortion levels both when the model was filled with non-expansile and expansile tamponades.

**Table 1. Initial and final values for IOP, IVP, distortion, and stress in each experiment set in phase 1 and phase 2 while the model was filled with expansile and non-expansile tamponade. Note the final stress values are the average of 10 values measured at the end of each experiment**

Phase	Set	Aim	Tamponade	No of tests	IOP (mmHg)		IVP (mmHg)		Distortion (%)		Stress (Pa)	
					Initial	Final	Initial	Final	Initial	Final	Initial	Final
One	1	To investigate the effect of low IOP on stress in choroidal vessels	Non-expansile	10	35	0	120	120	0	0	0	0.1
			Expansile	10	35	0	120	120	0	0	0	1.7
	2	To investigate the effect of high IVP on stress in choroidal vessels	Non-expansile	10	35	35	120	200	0	0	0	9.9
			Expansile	10	35	35	120	200	0	0	0	61
	3	To investigate the effect of distortion on stress in choroidal vessels	Non-expansile	10	35	35	120	120	0	12	0	23
			Expansile	10	35	35	120	120	0	12	0	64
Two	1	To investigate the role of increasing IOP in counteracting stress in choroidal vessels caused by high IVP	Non-expansile	10	35	80	180	180	0	0	6	0.6
			Expansile	10	35	80	180	180	0	0	6	0.4
	2	To investigate the role of increasing IOP in counteracting stress in choroidal vessels caused by distortion	Non-expansile	10	35	80	120	120	12	12	6	6.5
			Expansile	10	35	80	120	120	12	12	6	6





**Figure 1.** A diagram of the model. 1: a rubber tube 10 cm in length and 1 cm in diameter wrapped with conductive thread to enable the measurement of stress at the walls of the tube. 2: a hydraulic actuator used to apply various longitudinal strain on the tube to simulate ocular distortion during surgical maneuvers. 3: an infrared distance sensor to measure the strain applied on the tube. 4: a sealed container enclosing the model and pressurized to various levels to simulate variable intraocular pressures (IOP). The tests were performed with the container filled with air or water to simulate expansile and non-expansile tamponades, respectively. 5: a pump to pressurize the tube to various levels to simulate systemic intravascular blood pressure (IVP). 6: a pump to pressurize the container to various levels to simulate IOP. 7: a pump to pressurize the hydraulic actuator to various levels to simulate ocular distortion. 8: a pressure sensor to continuously monitor IVP. 9: a pressure sensor to continuously monitor IOP. 10: a microcontroller to control the pumps, process the signals from the sensors and send the information through a serial connection to a computer. 11: a laptop to save and process data from the microcontroller

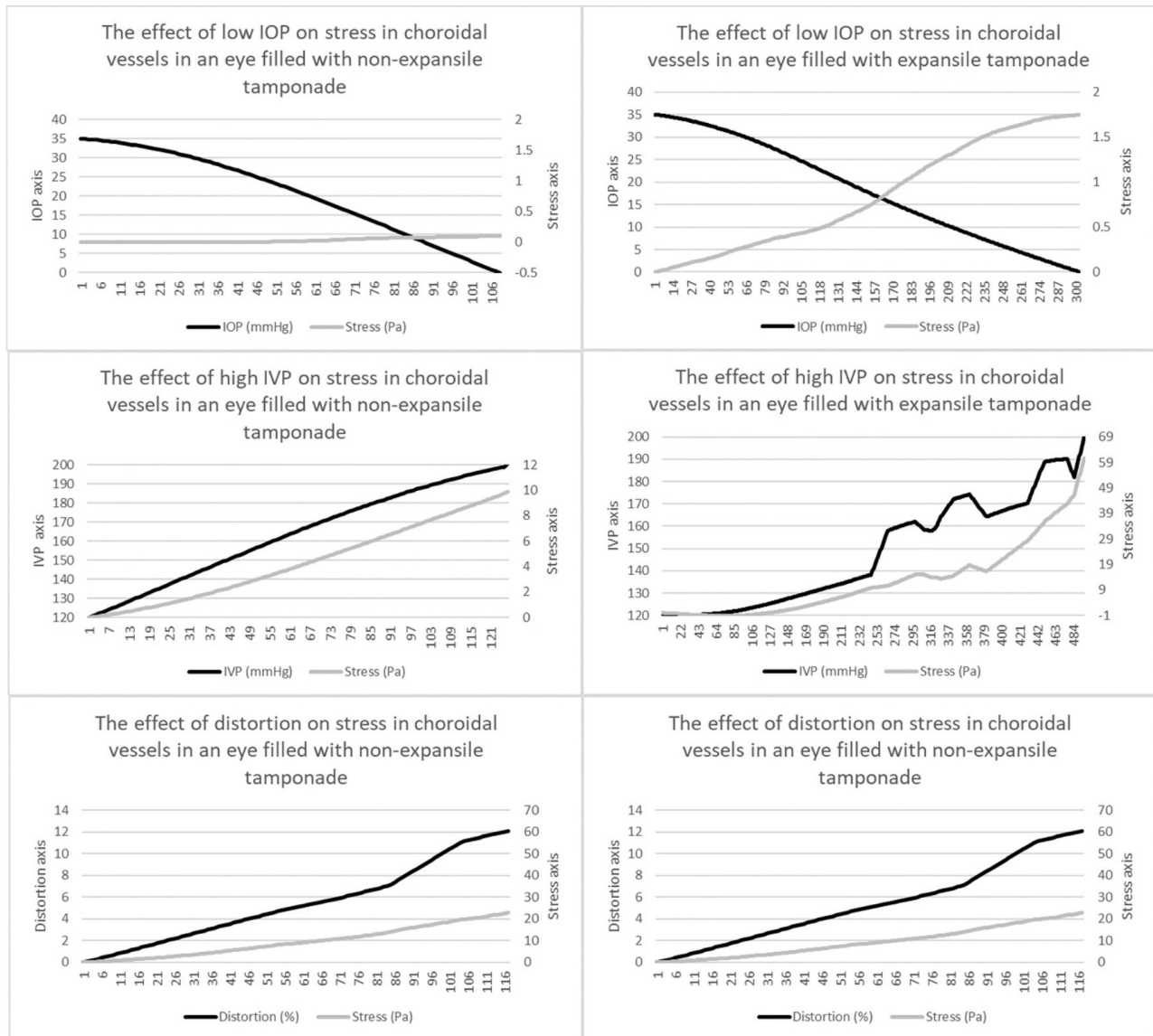


**Figure 2.** The scale model of the choroidal vessel made of a rubber tube 10 cm in length and 1 cm in diameter equipped with stress sensors consisting primarily of conductive thread, fitted in an actuator and placed in a sealed container. The container is partially filled with water. The container and the tube were pressurized using a special pump system to simulate the intraocular pressure (IOP) and systemic blood pressure (IVP). The actuator was used to apply controlled longitudinal strain on the tube to simulate eye distortion during surgery. Stress levels in the tube were continuously monitored under various IOP, IVP, and strain levels

Our model suggested that distorting the globe plays a more important role in inducing stress in the choroidal vasculature compared to increased IVP, which in turn has a greater effect than hypotony. Based on this, traumatic CH in patients with closed globe injuries and intraoperative CH during certain surgical maneuvers like indenting and tightening sutures over an external buckle could primarily be explained by distortion of the choroidal vasculature.<sup>15,16</sup> It also explains the limited effect of hypotony in experimental induction of CH reported in previous studies.<sup>17,18</sup> In fact, the reasons for CH in hypotonic eyes are believed to be indirectly related to distortion of the choroidal vasculature. It has been postulated that hypotony increases the filtration rate by magnifying the transmural pressure differential, resulting in choroidal effusion which in turn stretches and distorts the long and short ciliary blood vessels, leading to their rupture and hemorrhage.<sup>6,12,13,19,20,21,22,23,24</sup>

The current model also showed that the risk of CH due to high systemic IVP and hypotony is higher when the eye is filled with expansile tamponades. This is most likely due to the extra support for the vascular bed provided by the density of non-expansile tamponades compared to expansile tamponades.<sup>7,11</sup> This explains why it is advisable to use non-expansile tamponades if CH is detected or suspected during surgery.<sup>2</sup>

The model also revealed that increasing IOP to counteract high stress in the choroidal vasculature is only effective when the stress in the vasculature is generated by high IVP. High IOP levels are not effective in reducing stress in the choroidal vascular if the stress was primarily generated by distortion. This is an important finding, as increasing IOP is the most



**Figure 3.** The results of phase 1 experiments when the model was filled with non-expansile tamponade (left column) and expansile tamponade (right column), showing the relationships between stress in the choroidal vasculature and intraocular pressure (top row), systemic intravascular pressure (middle row), and ocular distortion (bottom row)

common strategy used to counteract intraoperative CH, while efforts to minimize surgical distortions are often ignored.

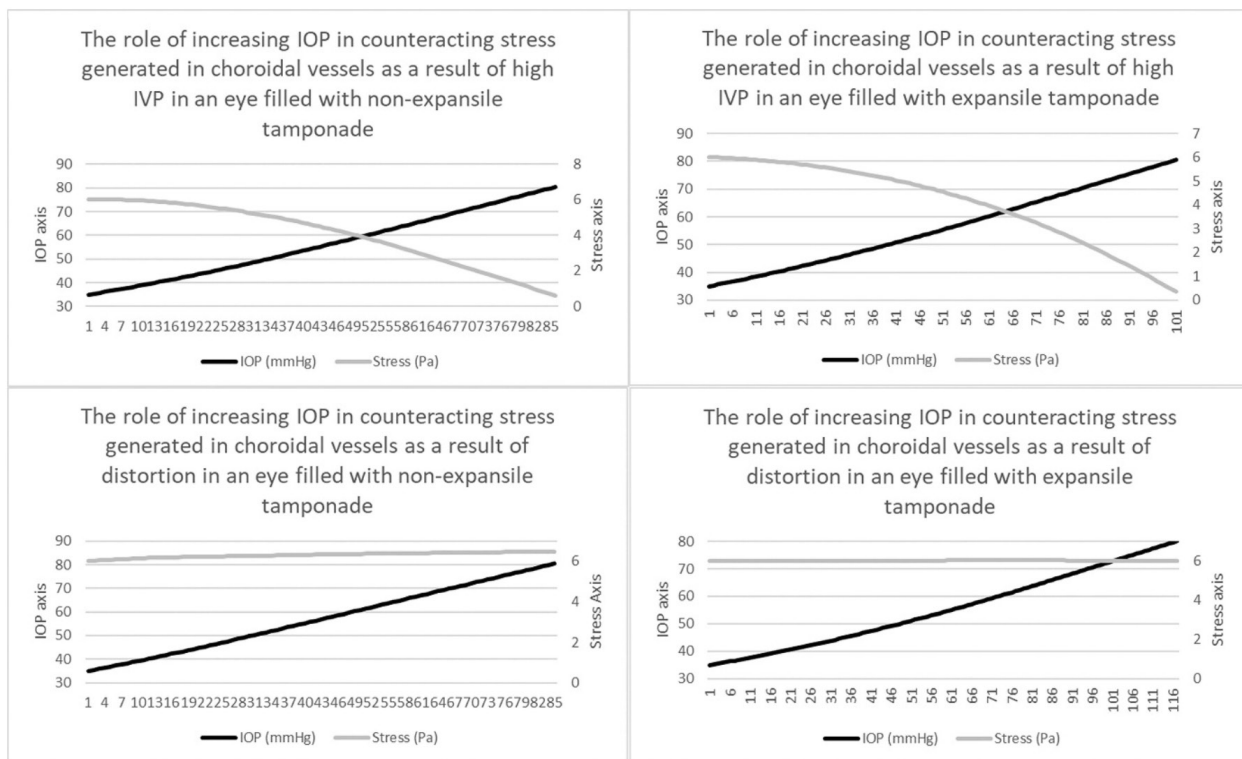
### Study Limitations

One of the shortfalls of the study was that the model was a scaled up model of the choroidal vasculature. Although this method provided more precise measurement of the changes in stress levels, the actual stress levels in the choroidal vasculature could be different from those measured in our model.

### Conclusion

Inadvertent excessive distortion of the globe during surgical maneuvers could be the primary reason for the

rarely observed intra-operative CH. Therefore, care must be exercised to avoid unnecessary distortion of ocular tissues during surgery. Non-expansile ocular tamponade provides better support for the vascular bed against CH and should be the recommended choice of tamponade in patients with existing CH. Hypotony should be avoided during surgery, particularly when the eye is filled with expansile tamponade, and maximum effort should be made to avoid distorting a hypotonic globe filled with expansile tamponade. Finally, raising IOP excessively during intraocular surgery has limited effect in preventing CH that may arise from distortion of the delicate ocular tissues.



**Figure 4.** The results of phase 2 experiments when the model was filled with non-expansile tamponade (left column) and expansile tamponade (right column), showing the role of increasing intraocular pressure in counteracting stress in the choroidal vasculature produced by high systemic intravascular blood pressure (top row) and produced by distortion (bottom row)

### Acknowledgments

We would like to thank Selin Doğramacı for her help in drawing the diagram.

### Ethics

**Ethics Committee Approval:** Ethics committee approval was not obtained because our study was conducted with an experimental model in the laboratory without including human and animal elements.

### Informed Consent:

**Peer-review:** Externally peer reviewed.

### Authorship Contributions

Concept: M.D., F.Ş., Design: M.D., C.A., Data Collection or Processing: F.D., Analysis or Interpretation: M.D., C.A., Literature Search: M.D., F.Ş., Writing: M.D., F.D.

**Conflict of Interest:** No conflict of interest was declared by the authors.

**Financial Disclosure:** The authors declared that this study received no financial support.

### References

1. Wolter JR. Expulsive hemorrhage: a study of histopathological details. *Graefes Arch Clin Exp Ophthalmol.* 1982;219:155-158.
2. Williamson, T.H., *Intraocular Surgery: A Basic Surgical Guide.* Switzerland; Springer International Publishing; 2016:87-110.
3. Gressel MG, Parrish RK, Heuer DK. Delayed nonexpulsive suprachoroidal hemorrhage. *Arch Ophthalmol.* 1984;102:1757-1760.

4. Purcell JJ Jr, Krachmer JH, Doughman DJ, Bourne WM. Expulsive Hemorrhage in Penetrating Keratoplasty. *Ophthalmology.* 1982;89:41-43.
5. Manschor WA. The pathology of expulsive hemorrhage. *Am J Ophthalmol.* 1955;40:15-24.
6. Maumenee AE, Schwartz MF. Acute intraoperative choroidal effusion. *Am J Ophthalmol.* 1985;100:147-154.
7. Taylor DM. Expulsive hemorrhage. *Am J Ophthalmol.* 1974;78:961-966.
8. Zauberman H. Expulsive choroidal haemorrhage: an experimental study. *Br J Ophthalmol.* 1982;66:43-45.
9. Samuels B. Postoperative nonexpulsive subchoroidal hemorrhage. *Arch Ophthalmol.* 1931;6:840-851.
10. Ruderman JM, Harbin TS Jr, Campbell DG. Postoperative suprachoroidal hemorrhage following filtration procedures. *Arch Ophthalmol.* 1986;104:201-205.
11. Taylor DM. Expulsive hemorrhage: some observations and comments. *Trans Am Ophthalmol Soc.* 1974;72:157-169.
12. Beyer CF, Peyman GA, Hill JM. Expulsive choroidal hemorrhage in rabbits: a histopathologic study. *Arch Ophthalmol.* 1989;107:1648-1653.
13. Fuchs E. Ablösung der aderhaut nach staaroperation. *Albrecht von Graefes Arch Ophthalmol.* 1900;51:199-224.
14. Lakhnani V. Experimental and clinical observations on massive suprachoroidal hemorrhage. *Trans Am Ophthalmol Soc.* 1993;91:545-652.
15. Wolter JR. Expulsive Hemorrhage During Retinal Detachment Surgery: A case with survival of the eye after Verhoeff sclerotomy. *Am J Ophthalmol.* 1961;51:264-266.
16. Chandra A, Jazayeri F, Williamson TH. Warfarin in vitreoretinal surgery: a case controlled series. *Br J Ophthalmol.* 2011;95:976-978.
17. Capper SA, Leopold IH. Mechanism of serous choroidal detachment: A review and experimental study. *AMA Arch Ophthalmol.* 1956;55:101-113.
18. Collins ET. An experimental investigation as to some of the effects of hypotony in rabbits' eyes. *Tr Ophthalmol Soc UK.* 1918;38:217-227.

19. Wolter JR, Garfinkel RA. Ciliochoroidal effusion as precursor of suprachoroidal hemorrhage: a pathologic study. *Ophthalmic Surg.* 1988;19:344-349.
20. Pederson JE, Gaasterland DE, MacLellan HM. Experimental ciliochoroidal detachment: effect on intraocular pressure and aqueous humor flow. *Arch Ophthalmol.* 1979;97:536-541.
21. Verhoeff FH, Waite JH. Separation of the choroid, with report of a spontaneous case. *Trans Am Ophthalmol Soc.* 1925;23:120-139.
22. Chylack LT Jr, Bellows AR. Molecular sieving in suprachoroidal fluid formation in man. *Invest Ophthalmol Vis Sci.* 1978;17:420-427.
23. Brubaker RF. Intraocular surgery and choroidal hemorrhage. *Arch Ophthalmol.* 1984;102:1753-1754.
24. Campbell J. Expulsive choroidal hemorrhage and effusion: A reappraisal. *Ann Ophthalmol.* 1980;12:332-340.



# Does Ophthalmology Need Philosophy?

Doğan Ceyhan\*, Tekin Yaşar\*\*

\*Near East University, Department of Ophthalmology, Nicosia, TRNC

\*\*University of Health Sciences İstanbul Beyoğlu Eye Education and Research Hospital, İstanbul, Turkey

## Abstract

Although ophthalmology has made significant progress and awareness about eye care and the accessibility of health technology has increased, there are still aspects that might be improved. One of the ways to achieve improvement is philosophical investigation of some reasoning and behavior styles in ophthalmology. Philosophy means love of wisdom, and the philosophical approach can contribute to increasing the wisdom of ophthalmologists. Logical fallacies currently affecting the decisions of ophthalmologists can be reduced. "ontology" can contribute to a better understanding of "the nature of reality". A detailed inquiry about the basic concepts concerning ophthalmology may support better reasoning styles. Reflecting on epistemological questions such as "What is true knowledge?", justifying information, and having a skeptical attitude may help to make decisions with more accurate information. The philosophy of science is concerned with the detailed investigation, questioning, and understanding of ophthalmologists' scientific activities and may form the missing link between ophthalmology and philosophy. Moreover, the claim that philosophy's contribution to science is of no interest to scientists warrants consideration. The philosophers of science Karl Popper and Thomas Kuhn have made significant contributions to the perception of science that are still valid today. Karl Popper proposed that a demarcation between science and pseudo-science might be made through the concept of "falsification". According to this concept, a statement is scientific if it can be tested and falsified using valid methods. Thomas Kuhn stated that major scientific changes (i.e., revolutions) occur through paradigm shifts. Although the areas of moral philosophy/ethics/bioethics have generated useful ideas and practices for the improvement of the art of medicine, bioethics in particular deserves to be questioned philosophically by physicians living in real life. Ophthalmologists can develop more beneficial and realistic ophthalmology education, research, diagnosis, treatment, and rehabilitation practices by utilizing the basic methods of philosophy.

**Keywords:** Philosophy, ophthalmology, wisdom, philosophy of science, moral philosophy

## Introduction

Ophthalmology has shown significant progress and achievements, particularly in the last 20 to 30 years. Surgical incisions are made on a micron scale, and drugs that act against pathological vascularization are providing more "successful" results in incurable diseases. Societal awareness of eye health has increased, and technological products for diagnosis and treatment have become widespread and more accessible. Thus, in many parts of the world, ophthalmology utilizes these advanced

capabilities to reduce vision loss and improve people's quality of life.

Although science in general and ophthalmology in particular have made major progress, when examined objectively, one can recognize aspects of both that can be improved.<sup>1,2,3,4,5</sup> One means of improving these aspects is a philosophical approach that subjects some established thoughts and behaviors to more rigorous examination and inquiry.<sup>6,7,8,9,10,11,12</sup> Philosophy is not an "ivory tower" activity that quotes important philosophers, deals only with the theoretical realm, and is carried out

**Address for Correspondence:** Doğan Ceyhan, Near East University, Department of Ophthalmology, Nicosia, TRNC

E-mail: doganceyhan@yahoo.com **ORCID-ID:** orcid.org/0000-0003-4984-7459

**Received:** 03.09.2020 **Accepted:** 01.03.2021

**Cite this article as:** Ceyhan D, Yaşar T. Does Ophthalmology Need Philosophy?. Turk J Ophthalmol 2021;51:301-307

©Copyright 2021 by Turkish Ophthalmological Association

Turkish Journal of Ophthalmology, published by Galenos Publishing House.

with complex words. Although unnoticed, philosophy is an activity that positively or negatively affects life in many ways and determines the basic mental processes that guide life. Ophthalmology practices, like all activities of life, are shaped by some fundamental philosophical approaches.

This article provides an introduction to philosophy and the areas in which philosophy and ophthalmology interact. Philosophy in Turkish means “love of wisdom,” and we will discuss the connection and relationship between ophthalmology and philosophy based on the premise that the main purpose of philosophy is to “acquire wisdom.” We use the concept of “wisdom” within the scope and historical meaning of the Turkish language, not implying a “mystical” wisdom of Far East or similar origin. We use a plain language, avoiding expressions and terms that are not used by people outside the field of academic philosophy, such as “geist,” “phenomenology,” and “transcendental.” This article will attempt to raise the call to carefully reexamine ophthalmology, which has historical ties and interaction with philosophy, within the conditions of our language (Turkish) and country.

## Philosophy

As is widely known, “philosophy” is formed from the words *philo* and *sophia* and means “love of wisdom.” In the Turkish language, the concept of wisdom (*bilgelik*) is based on the root for “know” (*bil-*) and has a common origin with words such as knowledge (*bilgi*), science (*bilim*), scientific (*bilimsel*), and consciousness (*bilinç*). “Know” (*bil-*) in our language is also used in the sense of “having the power, skill, and ability to do” in the Turkish words for “able to do” (*yapa-bilmek*), “able to see” (*görebilmek*), and “able to know” (*bile-bilmek*). Considering the dictionary definitions, “wise” (*bilge*) can be defined as a person who has comprehensive knowledge and can use their knowledge correctly and beneficially, and “wisdom” can be defined as the state of evaluating what transpires with a superiority born of virtue and knowledge. Essentially, wisdom can be described as “to comprehensively know and be aware; to implement in a correct, beneficial, and virtuous way.”

## Logic and Fallacies

Logic is among the essentials of philosophy and works on the principles of correct reasoning. Logic defines the methods and rules by which experienced realities and mental processes can be conveyed through words (or symbols) in a way that other minds can understand and process. Although there are different definitions, in our opinion, logic structurally examines the processes involved in using words (and symbols) connected to thoughts to enable realities to be conveyed in accordance with actuality.

The most important logic topic that concerns ophthalmologists is logical fallacies. Logical fallacies are erroneous thought processes that occur unconsciously. Although ophthalmology is largely carried out through rigorous cognitive processes, logical fallacies can mislead patients and

ophthalmologists just as everyone else. Publications on logical fallacies and how to reduce them are also found in medical literature.<sup>13,14,15</sup> In this article we address several important and common fallacies concerning the field of ophthalmology.

A common fallacy in life and ophthalmology is called *post hoc ergo propter hoc* in Latin, or the “post hoc fallacy” for short.<sup>16</sup> This fallacy can be described as the assumption that unrelated events are connected because they occur in temporal proximity (one after the other). It manifests as an erroneous causal relationship drawn between events with very low or no probability of connection. It can be regarded as essentially an extension of the problem of induction in philosophy.<sup>17</sup>

As an example related to ophthalmology, if a person with atopic tendency and complaints of intense eye itching, redness, and off-white discharge uses antibiotic drops at home, leaves the city, and then attributes the cessation of their symptoms to the antibiotic, this is an example of post hoc fallacy. Their symptoms likely resolved because they moved away from an allergen, but they think the antibiotic cured their condition. Another example is to assume that intravitreal injections alone improved or worsened a patient’s condition, without adequately considering some other important factors, such as blood glucose regulation. To believe that the intravitreal drug is definitively effective or ineffective carries the possibility of post hoc fallacy, because the presumption of (in)efficacy is being made in a multifactorial clinical condition based on only one variable, without a comprehensive evaluation of the causal relationship.

Statements such as “drug A is effective and safe in eye disease B” that bear truth/falsity and provision/judgment values are called propositions. When a phenomenon inconsistent with this proposition is observed, from a philosophical standpoint this proposition is no longer as strong as it was; in a sense, it is “refuted.” In this case, new scientific observations and studies are conducted in an attempt to gain a more comprehensive understanding of the subject of the proposition. A new study shows that drug A is more effective in patients with intraocular pressure of 20–25 mmHg. Therefore, the proposition becomes “drug A is effective and safe in eye disease B when intraocular pressure is between 20 and 25 mmHg.” Now more is known about disease B and drug A and there is more comprehensive knowledge of which patient group drug A will be effective in. The hypothetical phenomenon given here is an example of the “thought experiment” concept in philosophy. Thought experiments aim to scrutinize reality within the framework of existing information, according to reason and logic but with imaginary/hypothetical situations. This thought experiment is an example of the process of better understanding the incompletely understood disease B, creating a more correct approach, and avoiding post hoc fallacy.

Post hoc fallacy can be seen in some patients in examples such as “my head hurts, my intraocular pressure is high,” or in exfoliative zonular weakness, “surgery was performed incorrectly, my lens shifted.” Headache may be associated with intraocular pressure in a group of patients; however,

if intraocular pressure is implicated when the headache was actually caused by a factor such as tension or stress, then a post hoc fallacy was committed. Similarly, a patient with advanced exfoliation who undergoes normal cataract surgery and later attributes intraocular lens dislocation due to severe zonular weakness as “incorrect surgery” is another example of post hoc fallacy. The capsule is no longer adequately supported due to structural alterations in the patient’s eye, yet the patient believes the surgery was performed incorrectly.

The problem with the post hoc fallacy is that it is difficult to determine whether successive events are truly connected, i.e., to determine causality. Even randomized controlled studies cannot fully solve this problem; the complexity of the human organism makes it difficult to reach the truth.<sup>18,19</sup> “Confounding” and “bias,” which exist in medicine and the nature of life, also create challenges in identifying causal relationships. Although this logical fallacy can be overcome to some extent through more careful observations and interpretations based on a better scientific method, it is an important problem of science and philosophy that has yet to be solved.<sup>17</sup> Ophthalmologists can reduce the frequency of post hoc fallacy by being more aware of the fact that successive events can also occur by chance.

Apart from the post hoc fallacy, some habits in the medical field may also lead to erroneous thinking and decision-making by physicians.<sup>13</sup> The habits of appealing to authority and appealing to convention are also common fallacies. These are examples of logical fallacies in that well-known people may not always show the right path, or the majority may be misguided.<sup>20,21,22,23</sup> In the case of ophthalmology, it should also be borne in mind that despite being published in reputable journals, study results may be biased due to factors such as academic or financial concerns. Using publications with a high citation index and a practical orientation, as well as checking the accuracy of information related to the physicians’ workplace, hospital conditions, and patient group may help prevent these logical fallacies.<sup>21,22,23,24,25</sup>

Varner<sup>25</sup> reported that there are problems in the ophthalmology literature regarding issues such as study validity and bias, patient selection and eligibility, compliance with standards of comparison, insufficient patient numbers, lack of comparison to the gold standard or placebo, confounders, and a lack of clear research objectives.

An important part of logic studies is the branch of propositional logic. When many statements used in ophthalmology are examined within the framework of propositional logic, one can gain a more in-depth perspective in the diagnosis, treatment, and follow-up stages. For example, the expression “this person has glaucoma” is perceived as a true, clear, and understandable proposition by ophthalmologists. However, ophthalmologists being acquainted with subjects like whether a judgment is accepted as “true” because it is “concordant with the facts” or because it is “consistent with all other propositions of the system to which that proposition belongs” may contribute to more solid foundations of ophthalmological knowledge.<sup>26</sup>

## Ontology: The Philosophy of Being/Existence

One means by which physicians can achieve wisdom is to scrutinize basic definitions and concepts that influence their thinking and practices, such as “disease,” “health,” “therapy,” “healing,” “innovation,” or “the latest treatment.” Although this area is considered to be related to the branch of ontology, which is translated into Turkish as “the philosophy of existence,” it also falls into the domain of epistemology and aims to provide a better understanding of the nature of reality. The reason ontology concerns ophthalmologists is that basic definitions and concepts influence their ways of thinking that lead practices in that field of knowledge. For example, the phrase “complete well-being” in the World Health Organization’s definition of health indicates a very high level of well-being and creates a goal that is difficult to achieve in real life.

Another example of the importance of definitions and concepts for physicians and patients is statements such as “the latest treatment” or “innovation.”<sup>27</sup> While such words can be presented as a hope and cure for the patient, they also carry meanings such as “treatment whose effects and side effects are not yet fully known.” Ontology examines words’ mental correlates in real life, thereby enriching perceptions and understanding of the subject and contributing to wisdom. Although philosophy scholars and philosophers examine such basic concepts in theoretical terms, physicians can make more realistic contributions to these examinations and explanations from real life.

## Epistemology: The Philosophy of Knowledge

Along with ontology, another important branch of philosophy is epistemology, or the philosophy of knowledge. Epistemology is defined as “a general reckoning with knowledge,” and it leads philosophical discussions such as “the nature of knowledge and justification” and “the position/attitude of skepticism.”<sup>28</sup> Knowledge is defined as “justified true belief,” and valid and adequate indications that a proposition is true are accepted as evidence.

Epistemology is a branch of philosophy that adopts a measured skepticism and seeks answers to questions such as “What is true knowledge?”, “What factors make knowledge true?”, and “Is the information given by people known as authorities always reliable?” Epistemology is one of the most fundamental areas of philosophy and deals with the “having true and comprehensive knowledge” aspect of wisdom. Seeking an answer to the question “Does industry funding influence research results?” is in fact an epistemological pursuit. A more detailed form of epistemology is the philosophy of science, which subjects scientific thought and practices to philosophical scrutiny and inquiry.

## Ophthalmology and the Philosophy of Science

Ophthalmology, which is actually a branch of science, is most connected to philosophy through the philosophy of science. The

philosophy of science is concerned with more closely examining, questioning, and understanding the procedures and processes called “scientific activity.” It has been stated that in traditional education, there is a “missing link” between science and philosophy and that philosophy’s contribution to science is of no interest whatsoever to scientists.<sup>29</sup>

Philosophy of science aims to contribute to many questions such as “What is science and its purpose?”, “What properties distinguish scientific knowledge from other types of knowledge?”, “What is scientific explanation?”, and “Under what conditions is science useful?” Ophthalmologists can examine and review their activities as science practitioners within the framework of the philosophy of science. This examination and review process may allow ophthalmology practices to further mature and be more open to development.

Although many scientists and philosophers have contributed to the philosophy of science, Karl Popper and Thomas Kuhn in particular made significant changes in perspectives of science, the impact of which persist even today.<sup>30</sup> Therefore, we will briefly discuss some ideas of these two science philosophers.

Popper<sup>31</sup> made the concept of “falsifiability” central to science. According to this idea, the distinction between scientific and non-scientific information is whether it can be falsified. Information that cannot be tested experimentally and falsified by the scientific method is not considered scientific, but is relegated to the realm of pseudoscience.<sup>31</sup> Karl Popper’s concept of falsifiability, which promotes scientific skepticism, also offers ophthalmologists an important approach and useful research style. According to this research style, if ophthalmology knowledge and practices can be falsified by an experiment or observation, that knowledge and practice is scientific. For example, the proposition that “elevated intraocular pressure damages the optic nerve” is considered scientific because it can be confirmed or shown to be false by experiment or observation. It is observed that people with glaucomatous damage have high intraocular pressure, and it is understood that intraocular pressure damages the optic nerve. However, as time progresses and observations increase, the observation of a person with glaucomatous damage who does not have high intraocular pressure indicates a fault in the proposition “high intraocular pressure damages the optic nerve” and it becomes clear that another explanation for glaucomatous damage is needed. Thus, the explanation of low tension glaucoma emerges and glaucoma is better understood.

An important point learned from Popper is that findings contrary to established knowledge and general belief should not be disregarded, because they will contribute to a better understanding of medical truths. Applying the falsifiability principle in daily life exposes the errors and fallacies of general beliefs and thoughts and allows them to be corrected and strengthened. Without a skeptical approach based on the falsifiability principle, ophthalmologists would probably still be diagnosing and monitoring glaucoma with Schiøtz tonometry. Demonstrating the shortcomings of this device enabled follow-up and treatment to be performed using better methods. When

current methods are also shown to be flawed, it will immediately open the way for more useful diagnostic and therapeutic methods for nearly all eye diseases. By means of the falsifiability principle, findings that falsify established practices are given more attention, theories and explanations are closer to the truth, and practices are improved.

The scientific philosopher Kuhn<sup>32</sup> introduced the concept of “paradigm shift,” which explains how scientific revolutions, or major changes in scientific understanding, have occurred throughout history. This explanation rejects the view that science is an activity that evolves and is perfected by the gradual accumulation of knowledge over time. According to Kuhn, people in a profession group, with the influence of their professional perspectives, develop scientific propositions (i.e., “paradigms”) that explain events within a certain framework. Although these scientific propositions do not always reflect the most accurate and truthful information, those within the group perceive them as true knowledge. Over time, however, new findings reveal important flaws in the existing paradigm, and a new paradigm is developed to explain the situation. An example of paradigm shift in ophthalmology is the transition from explaining glaucomatous damage by the mechanical effect of intraocular pressure to the explanation of vascular autoregulation, and even the transition to considering it an eye disease related to systemic neurodegeneration.<sup>33</sup>

The concept of paradigm shift draws attention to the fact that established ideas are understood and explained with the existing level of knowledge and that these truths can change with new information. Instead of assuming medical findings that contradict the general view are errors or inadequate observations, seeing them as an opportunity to improve the general view can initiate large-scale changes. In terms of ophthalmology, Kuhn’s major contribution is that existing knowledge is considered “valid according to the present understanding” and that more comprehensive understanding and perceptions of reality can be achieved through new findings and new perceptions. From Kuhn’s perspective, the attitude that will further advance ophthalmology is not research that replicates and confirms established knowledge, but adopting an approach that encourages development and change by demonstrating deficiencies in the current understanding.

Popper and Kuhn have made some important contributions to the perceptions and application of science and the scientific method. In our opinion, the most important contributions of these two science philosophers are that they draw attention to the need for existing knowledge to nearly always be open to inquiry and even challenge. Ophthalmologists may be inclined to consider findings that are inconsistent with general knowledge and understanding as incomplete or inaccurate observations. Ophthalmology journals, like all journals, can fall prey to publication (or non-publication) bias, particularly toward articles stating that drugs and treatments are not effective.<sup>25,34,35</sup> Publication bias in the field ophthalmology can be observed as a higher publication rate of studies with positive results, i.e., showing that there are benefits of treatment, especially in



journals with a high impact factor.<sup>35</sup> This suggests that studies showing that drugs and treatments are ineffective are less likely to be published, especially in high-impact journals.

In addition, misconduct by those regarded as authority is met by silence due to the culture of respect for elders in the profession, which has persisted from the Hippocratic Oath to the present day. Although it is important to preserve ophthalmological traditions, which are an extension of our country's culture, measured and logical objections to established inadequate practices can help ophthalmology advance in the right direction.

An important feature of science and ophthalmology is the different approaches to science in countries or institutions that “produce knowledge” and those that “use knowledge.” Although the scientific method has the same standards, there may be differences among individuals and institutions that produce scientific knowledge and those who transfer and use it. The people, institutions, and countries that produce knowledge “promote” the scientific product with the inherent aim of ultimately profiting from it. For this promotion, inadequacies and flaws of a method may be overlooked while so-called “scientific” methods are used to convince others of its superiority. So-called “scientific” studies can also be seen in research and knowledge-generation processes for reasons such as academic promotion, recognition, and industry affiliations.<sup>20,36</sup> By seeking answers to questions such as “What are its inadequacies and advantages?” and “Does it contribute significantly to clinical practice?”, the users of scientific information and technological products can more accurately evaluate scientific products. This way of thinking contributes to a more comprehensive understanding of reality and wisdom through questions like “What is true knowledge?” and “Who benefits from this information?”, which are actually among the fundamental questions of epistemology.

### Moral Philosophy/Ethics/Bioethics

The area of greatest interaction between philosophy and medicine is the field of deontology/ethics/moral philosophy. Changes in the last few decades have resulted in a silent shift from the concept of “deontology” to the concept of “ethics” in medical education and practice. As ethics, derived from “ethos,” is perceived as an area that more encompasses professional rules, we prefer the more comprehensive term “moral philosophy” in this article. Moral philosophy is the field of philosophy that discusses the morality of thoughts and behaviors through questions such as “What is the right behavior?”, “What is virtuous behavior?”, and “What makes a behavior moral?”

In addition to big problems in the field of academic philosophy such as “Can there be moral standards other than religious edicts?”, moral philosophy can also be used for other everyday life problems. Frank discussions of questions such as “What boundaries make industrial relationships with physicians moral?”, “Is it morally appropriate to present a medical practice as a new treatment while in the research stage?”, and “Can a

revenue/performance-based pricing system negatively affect the principle of doing no harm?” are also included in the field of moral philosophy. In addition, the philosophical and moral examination of the concepts of health law cited in malpractice claims such as “failure to inform,” “strict liability,” and “professional inexperience” also warrants philosophical inquiry in terms of expressing the physician's viewpoint.

It has been stated that for the art of medicine to be performed with decency, it must be determined not only by technical rules but also by medical ethics, and many criticisms of medicine arise from the patient feeling that they have been subjected to excessive and unnecessary interventions.<sup>37</sup> Excessive medicalization has been called a real danger in many countries due to situations that can be described as the abuse of drugs and medicine.<sup>38</sup> Biomedical ethics is also expected to answer the questions of what to do, what not to do, and how to solve problems encountered while conducting research or practicing the profession.<sup>39</sup> Moreover, it becomes a moral imperative to test practices that are currently being presented as scientific, such as leeching, ozone therapy, homeopathy, and acupuncture, according to real scientific standards, and only allow practices that are not of “pseudoscience” status. Such trials by philosophical inquiry contribute to a deeper understanding of medical practices and the enhancement of their morality.

The field of medical ethics has been shaped by the concept of “bioethics” since the 1970s, largely due to the contributions of philosophy and medical history scholars.<sup>40</sup> Bioethics is a theoretical field of study that has contributed significantly to the strengthening of human rights in the field of medicine and health and to making medical practices more humane. Today, bioethical principles are used as a moral norm/standard in a wide range of areas, from health law to medical research. The Turkish Ophthalmological Association adopts the Professional Ethics Guide for Ophthalmologists: Ethical Principles and Professional Principles and determines the ethical principles of ophthalmological activities in our country.<sup>41</sup> In addition, the Turkish Medical Association Professional Ethics Code is shaped by the four principles of bioethics.<sup>42</sup>

While some additions may be made, the core bioethical principles of beneficence, non-maleficence, justice, and autonomy have remained strong over the years. In fact, although ophthalmologists may not realize it, a significant proportion of everyday practices are shaped by these four principles of bioethics. For example, practices such as informed consent are carried out within the scope of the bioethical principles of patients being autonomous/self-governing and the procedure being beneficial for the patient. Although such bioethical practices create some difficulties for physicians and health institutions, they ensure the implementation of many practices that are for the patient's benefit.

While bioethics has made significant contributions to more humane medical practices, this field must also be subjected to philosophical inquiry by physicians, i.e., by those who apply these principles in practice. When the literature is examined, there are many articles that regard bioethical principles positively,

as well as criticisms that these principles reflect the traditions of Western moral philosophy, politics, and social theory and are even a tool of moral imperialism.<sup>43,44</sup> Taking into account these and similar criticisms, the field of bioethics is due for a philosophical examination using the questioning tools of moral philosophy.

Ophthalmologists, as people who are living and observing in real life, can make important contributions to the theoretical field of bioethics. Some moral standards developed at an office desk may not be compatible with the realities of daily life. Some well-intentioned theoretical practices can turn into impositions that strain the human dignity of physicians. Under the guise of actualizing bioethical norms, physicians may be exposed to practices outside the norms of human rights. Ophthalmologists should also try to utilize philosophical inquiry for support in the scientific and moral criticism of the legal norms associated with bioethical principles and to avoid being subject to undignified allegations of malpractice.

## Conclusion

Science and philosophy had nearly the same meaning historically but have been divergent for several centuries, and today the connections between science and philosophy are rather obscure. For thousands of years, philosophy has involved thinking and producing written works on various subjects, whereas science has used mental abilities to innovate practices to make life better. Over time, the ties between science and philosophy have weakened; philosophy remained purely a field of intellectual production, while science continued on to become a field of intensive technology production and use, but limited in terms of inquiry.

Even if ophthalmologists are not interested in philosophy, just asking the question “Is it possible that what is said may be untrue?” will constitute the first stage of wisdom. Philosophy can contribute to an ophthalmology practice that is firmly grounded and consistent with how physicians want themselves and their families treated, not swayed by the researchers, authors, and opinion leaders (although rare) who abuse the drug industry’s support. For such medical practices, there may be important benefits to revisiting and reconstructing both the “logos” and “ethos” areas of ophthalmology (i.e., ophthalmologos).

A philosophical attitude that pursues wisdom makes an important contribution to more accurately observing, thinking about, and interpreting one’s experiences. This may enable a more comprehensive and sound evaluation of professional practices. The essence of the professional activity performed can be better recognized and understood. Philosophy provides individuals and the profession with valuable intellectual abilities and tools applicable in a broad range of contexts, from advancing ophthalmology research to defending against malpractice claims. For these reasons, ophthalmologists need philosophical activity and the wisdom they can gain from it.

**Peer-review:** Internally peer reviewed.

## Authorship Contributions

Concept: D.C., T.Y., Data Collection or Processing: D.C., T.Y., Writing: D.C.

**Conflict of Interest:** No conflict of interest was declared by the authors.

**Financial Disclosure:** The authors declared that this study received no financial support.

## References

- Casadevall A, Fang FC. Reforming science: Methodological and cultural reforms. *Infect Immun*. 2012;80:891-896.
- Casadevall A, Ferric FC. Rigorous science: a How to guide. *mBio*. 2016;7:1902-1916.
- Abraham C. Scientific thinking in ophthalmology. *Indian J Ophthalmol*. 1998;46:105-108.
- Bojikian KD, Gupta D, Dettori JM, Dettori NJ, Dettori JR, Chang P, Slabaugh MA. Evidence in Ophthalmology: Are We Doing Better? *Ophthalmology*. 2015;122:2584-2586.
- Ceyhan D, Bektaş H, Emre S, Kurt M. Tıpta bazı yeni yaklaşımlar ve hekimler üzerine olası etkileri: “Kanıtı Dayalı Tıp”. *Turk J Ophthalmol*. 2007;37:172-177.
- Bartley GB. In praise of ignorance (seriously!), epistemology (Sort of...), and the circle of least confusion. *Ophthalmology*. 2013;120:881-882.
- Caplan AL. Does the philosophy of medicine exist? *Theor Med*. 1992;13:67-77.
- Stempsey WE. Philosophy of Medicine is what philosophers of medicine do. *Perspect Biol Med*. 2008;51:379-391.
- Hoff P, Fulford BK, Sadler JZ. History, philosophy and practical psychiatry: neither gap nor contradiction, but mutual enrichment. *Curr Opin Psychiatry*. 2012;25:485.
- Willis BH, Beebe H, Lasserson DS. Philosophy of science and the diagnostic process. *Fam Pract*. 2013;30:501-505.
- Macionis V. History of plastic surgery: Art, Philosophy, and rhinoplasty. *J Plast Reconstr Aesthet Surg*. 2018;71:1086-1092.
- Andreolletti M, Maugeri P. Does medicine need philosophy? *Oral Dis*. 2019;25:1419-1422.
- Gunderman RB, Siström C. Avoiding errors in reasoning: An introduction to logical fallacies. *AJR Am J Roentgenol*. 2006;187:469-471.
- Pinnock R, Welch P. Learning clinical reasoning. *J Paediatr Child Health*. 2014;50:253-257.
- Gibbs NM. Formal and informal fallacies in anaesthesia. *Anaesth Intensive Care*. 2010;38:639-646.
- Bullock JD. Post hoc ergo propter hoc. *Surv Ophthalmol*. 2001;45:355-357.
- DeWitt R. *Worldviews: An Introduction to the History and Philosophy of Science*. (2nd ed). West Sussex, UK; Wiley Blackwell; 2010.
- Zarbin MA. Challenges in applying the results of clinical trials to clinical practice. *JAMA Ophthalmol*. 2016;134:928-933.
- Rothman KJ, Greenland S. Causation and causal inference in epidemiology. *Am J Public Health*. 2005;95(Suppl 1):144-150.
- Arshinoff S. LASIK advertising: We should not sell procedures. *J Cataract Refract Surg*. 2004;30:1823-1824.
- Golozar A, Chen Y, Lindsley K, Rouse B, Musch DC, Lum F, Hawkins BS, Li T. Identification and description of reliable evidence for 2016 American Academy of Ophthalmology Preferred Practice Pattern Guidelines for Cataract in the Adult Eye. *JAMA Ophthalmol*. 2018;136: 514-523.
- Joksimovic L, Koucheki R, Popovic M, Ahmed Y, Schlenker MB, Ahmed IIK. Risk of bias assessment of randomised controlled trials in high-impact ophthalmology journals and general medical journals: a systematic review. *Br J Ophthalmol*. 2017;101:1309-1314.
- Sawano T, Ozaki A, Saito H, Shimada Y, Tanimoto T. Payments from pharmaceutical companies to authors involved in the valsartan scandal in Japan. *JAMA Netw Open*. 2019;2:e193817.

24. Lin ZN, Chen J, Zhang Q, Li Q, Cai MY, Yang H, Cui HP. The 100 most influential papers about cataract surgery: a bibliometric analysis. *Int J Ophthalmol.* 2017;10:1586-1591.
25. Varner P. Potential bias in ophthalmic pharmaceutical clinical trials. *Clin Ophthalmol.* 2008;2:401-411.
26. Grünberg T. Temel Önermeler. (2. Baskı) Bilgi ve Felsefe ve Felsefi Mantık Yazıları. İstanbul; Yapı Kredi Yayınları; 2019:13-14.
27. Cohen BA. How should novelty be valued in science. *ELife.* 2017;6:e28699.
28. Moser PK. Epistemoloji. İçinde: Moser PK. Ankara; Adres Yayınları; 2020:21.
29. Philipp F. Bilim ile Felsefe Arasındaki Bağ. Bilim Felsefesi, İçinde:Kadioğlu D. İstanbul; Say Yayınları; 2017:11.
30. Güzel C. Bilim Felsefesi. (3. Baskı). Ankara; Bilgesu Yayınları; 2018.
31. Popper KR. Bilimsel Araştırmanın Mantığı. (10. Baskı). İstanbul; Yapı Kredi Yayınları; 2020.
32. Kuhn TS. Bilimsel Devrimlerin Yapısı. (8. Baskı). İstanbul; Kırmızı Yayınları; 2019.
33. Erb C. [Paradigm shift in primary open angle glaucoma: From a localized optic neuropathy to a systemic neurodegeneration]. *Klin Monbl Augenheilkd.* 2020;237:126-127.
34. Dunn AG, Bourgeois FT, Coiera E. Industry influence in evidence production. *J Epidemiol Community Health.* 2013;67:537-538.
35. Mimouni M, Krauthammer M, Gershoni A, Mimouni F, Nesher R. Positive results bias and impact factor in ophthalmology. *Curr Eye Res.* 2015;40:858-861.
36. George SL, Buyse M. Data fraud in clinical trials. *Clin Invest (Lond).* 2015;5:161-173.
37. Koslovski P. Etik ve Hekimlik Sanatı. Etik ve Meslek Etikleri, içinde:Tepe H. Ankara; Türkiye Felsefe Kurumu; 2009:47.
38. Soricelli E. Çağdaş Toplumda Tıplaşmanın Aşırılığı. Dünya Problemleri Karşısında Felsefe, içinde. Yayına hazırlayan Kuçuradi İ. Ankara;Türkiye Felsefe Kurumu;1988:30.
39. Kuçuradi İ. Felsefi Etik ve "Meslek Etikleri". Etik ve Meslek Etikleri, içinde. Yayına hazırlayan Tepe H. Ankara; Türkiye Felsefe Kurumu;2009:34.
40. Beauchamp TL, Childress JE. Principles of Biomedical Ethics. New York; Oxford University Press;1979.
41. Göz Hekimleri için Meslek Etiği Rehberi: Etik İlkeler ve Mesleki İlkeler. <https://www.todnet.org/home/ICOEthicsCode-Turkish.pdf>. 13.11.2020 tarihinde erişilmiştir.
42. Türk Tabipleri Birliği Hekimlik Meslek Etiği Kuralları (Madde 6). [https://www.ttb.org.tr/mevzuat/index.php?option=com\\_content&view=article&id=65:hekl-meslek-etkurallari&catid=4:t&Itemid=31](https://www.ttb.org.tr/mevzuat/index.php?option=com_content&view=article&id=65:hekl-meslek-etkurallari&catid=4:t&Itemid=31), 28.06.2020 tarihinde ulaşılmıştır.
43. Silverman WA. The myth of informed consent: in daily practice and in clinical trials. *J Med Ethics.* 1989;15:6-11.
44. Chattopahyay S, De Vries R. Bioethical concerns are global, bioethics is Western. *Eubios J Asian Int Bioeth.* 2008;18:106-109. This study was presented as a poster at the 53rd National Congress of the Turkish Ophthalmological Association, held on November 6-10, 2019 in Antalya, Turkey.



# Traumatic Dislocation of the Globe into the Ethmoid Sinus

✉ Zafer Onaran\*, ✉ Gökçe Şimşek\*\*, ✉ Onur Konuk\*\*\*

\*Kırıkkale University Faculty of Medicine, Department of Ophthalmology, Kırıkkale, Turkey

\*\*Kırıkkale University Faculty of Medicine, Department of Otolaryngology Surgery, Kırıkkale, Turkey

\*\*\*Gazi University Faculty of Medicine, Department of Ophthalmology, Ankara, Turkey

## Abstract

Traumatic globe dislocation into the paranasal sinuses is a rare condition. Globe displacement with preserved integrity can result in functional and cosmetic recovery with rapid and appropriate intervention. In this article, we discuss the presentation and treatment of globe dislocation into the ethmoid sinus in a 36-year-old patient who presented to the emergency department with the complaint of vision loss due to a fall.

**Keywords:** Globe dislocation, orbital trauma, ethmoid sinus

## Introduction

Trauma-induced displacement of the globe outward, into the cranium, or into the paranasal sinuses is called traumatic dislocation. Although the risk of vision loss is high in these rare cases, it has been reported that favorable visual, functional, and aesthetic outcomes can be achieved with rapid and appropriate treatment.<sup>1,2</sup>

Depending on the severity of the trauma, dislocation may be associated with pathologies that adversely affect prognosis, such as globe rupture and injury to the optic nerve, choroid, retina, and extraocular muscles.

Here, we aimed to present a case of traumatic globe dislocation into the ethmoid sinus and its treatment in a patient presenting with vision loss resulting from an impact to the eye.

## Case Report

A 36-year-old woman presented to the emergency department complaining of loss of vision in her left eye after a fall. She reported that she stood on a chair in her home, lost

her balance, and fell, striking her left eye on a door handle. On examination, her right eye was intact but in the left eye she reported no light perception and only soft tissue was visible behind the eyelids, with no sign of the globe. As a diagnosis could not be established based on these findings, orbital computed tomography (CT) was requested. CT revealed a fractured medial orbital wall and intact globe dislocated into the ethmoid sinus (Figure 1a,b). The patient was admitted for emergency surgery. When the eyelid retractor was placed, the visible soft tissue was identified as conjunctiva (Figure 2a) and parting it revealed the temporal margin of the cornea deep on the nasal side (Figure 2b). Attempts were made to grasp the conjunctiva and limbus with forceps and pull the globe from its dislocated position, but it could not be moved. A Lynch incision (a curved skin incision over the medial orbital rim used to reach the medial wall of the orbit) was made to gain access to the upper edge of the medial orbital wall fracture (Figure 2c). The upper edge of the fracture line was enlarged slightly using a Kerrison punch. This freed the globe from the compressed bones and allowed it to be repositioned in the

**Address for Correspondence:** Zafer Onaran, Kırıkkale University Faculty of Medicine, Department of Ophthalmology, Kırıkkale, Turkey

E-mail: drzaferonaran@yahoo.com **ORCID-ID:** orcid.org/0000-0001-8603-601X

**Received:** 17.02.2021 **Accepted:** 22.06.2021

**Cite this article as:** Onaran Z, Şimşek G, Konuk O. Traumatic Dislocation of the Globe into the Ethmoid Sinus. Turk J Ophthalmol 2021;51:308-312

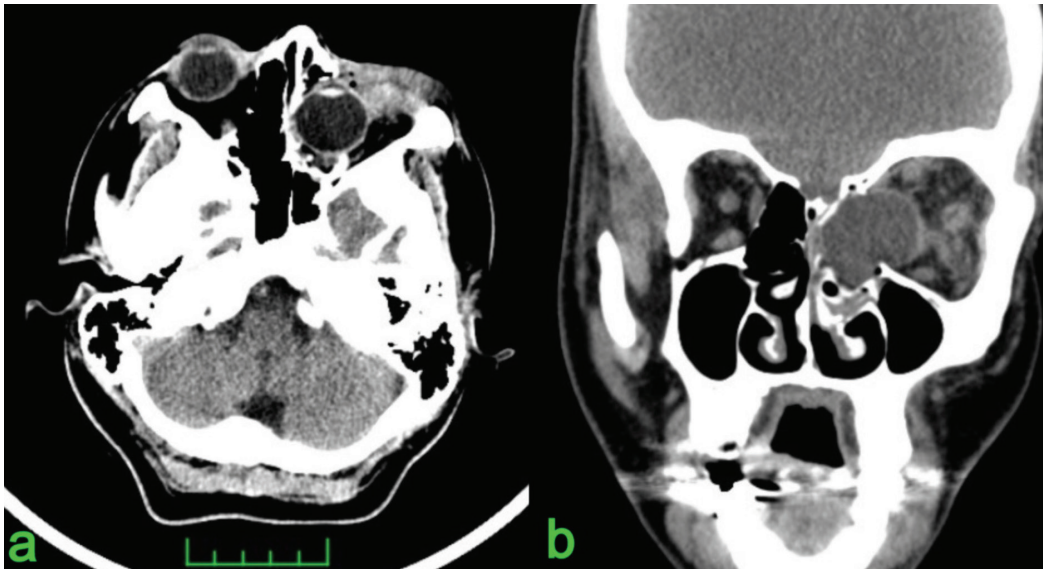
©Copyright 2021 by Turkish Ophthalmological Association

Turkish Journal of Ophthalmology, published by Galenos Publishing House.

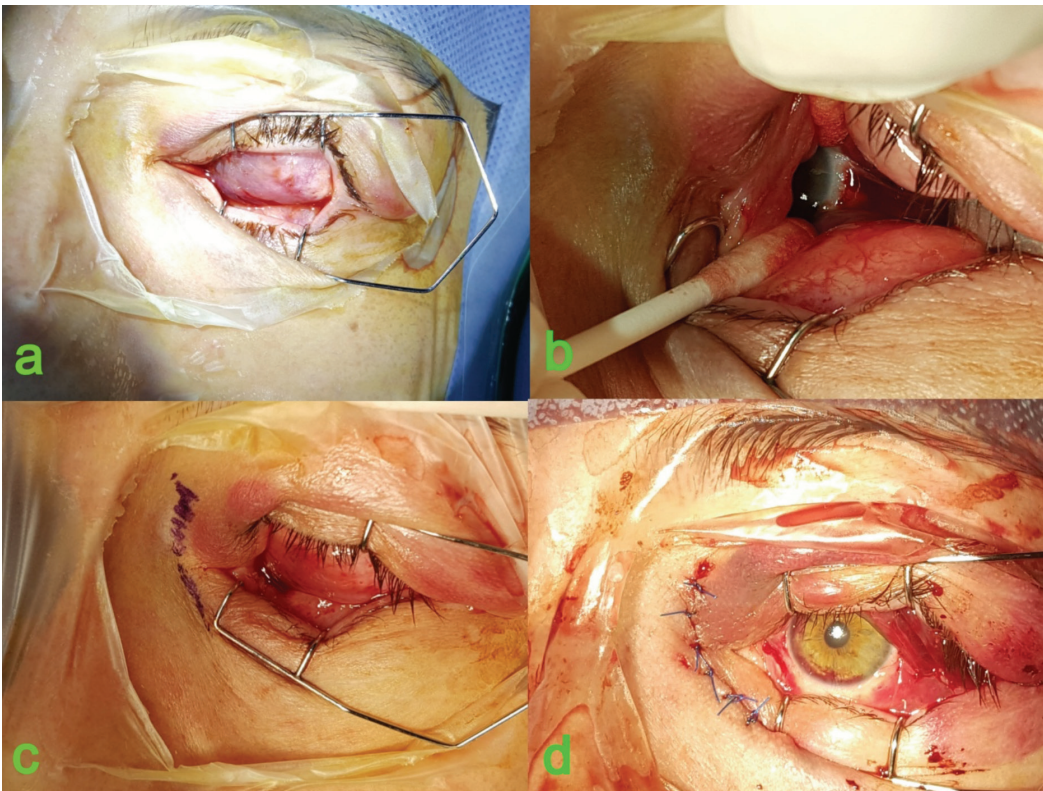
orbit by gentle intranasal digital manipulation. The operation was concluded after ensuring that intraocular pressure and the anterior segment structures were normal (Figure 2d).

The patient was started on postoperative intravenous antibiotic (1 g amoxicillin/200 mg clavulanic acid twice a day)

and methylprednisolone 1 g/day. On the first postoperative day, visual acuity of the affected eye was 0.3, subconjunctival hemorrhage was present, and fundus examination was normal (Figure 3). There was nearly complete limitation of eye movement in all directions, pupillary light reflex was intact,



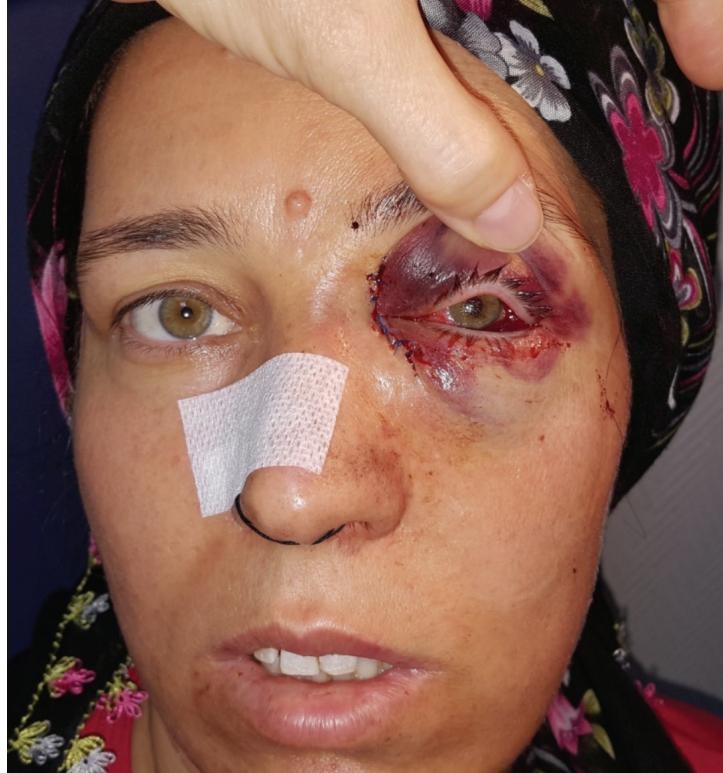**Figure 1. a,b)** Computed tomography showing left globe dislocation into the ethmoid sinus and nasal cavity



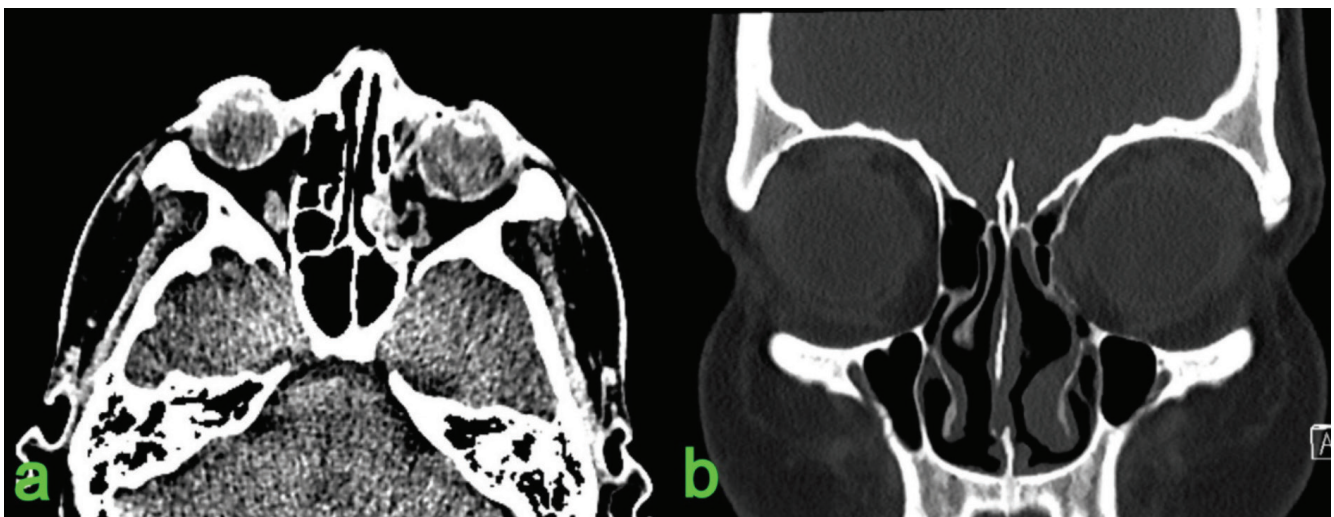
**Figure 2. a)** After the trauma there was no light perception in the affected eye and soft tissue was seen when the eyelids were parted. **b)** The soft tissue was identified as conjunctiva and when parted revealed the temporal cornea deep and nasal to the orbit. **c)** Lynch incision used to reposition the globe. **d)** The eye in its normal position at the end of surgery

and there was no relative afferent pupillary defect. Intravenous treatment was discontinued on day 3. At 1 week, visual acuity was 0.6 with some improvement in eye motility. At 1 month, visual acuity was 0.9 and the eye was orthophoric in primary position but showed -2 limitation of adduction and 2 mm enophthalmos. At 4 months, the patient underwent repair of the medial orbital wall defect through a transcaruncular approach using a Medpor implant. With its thin and flexible

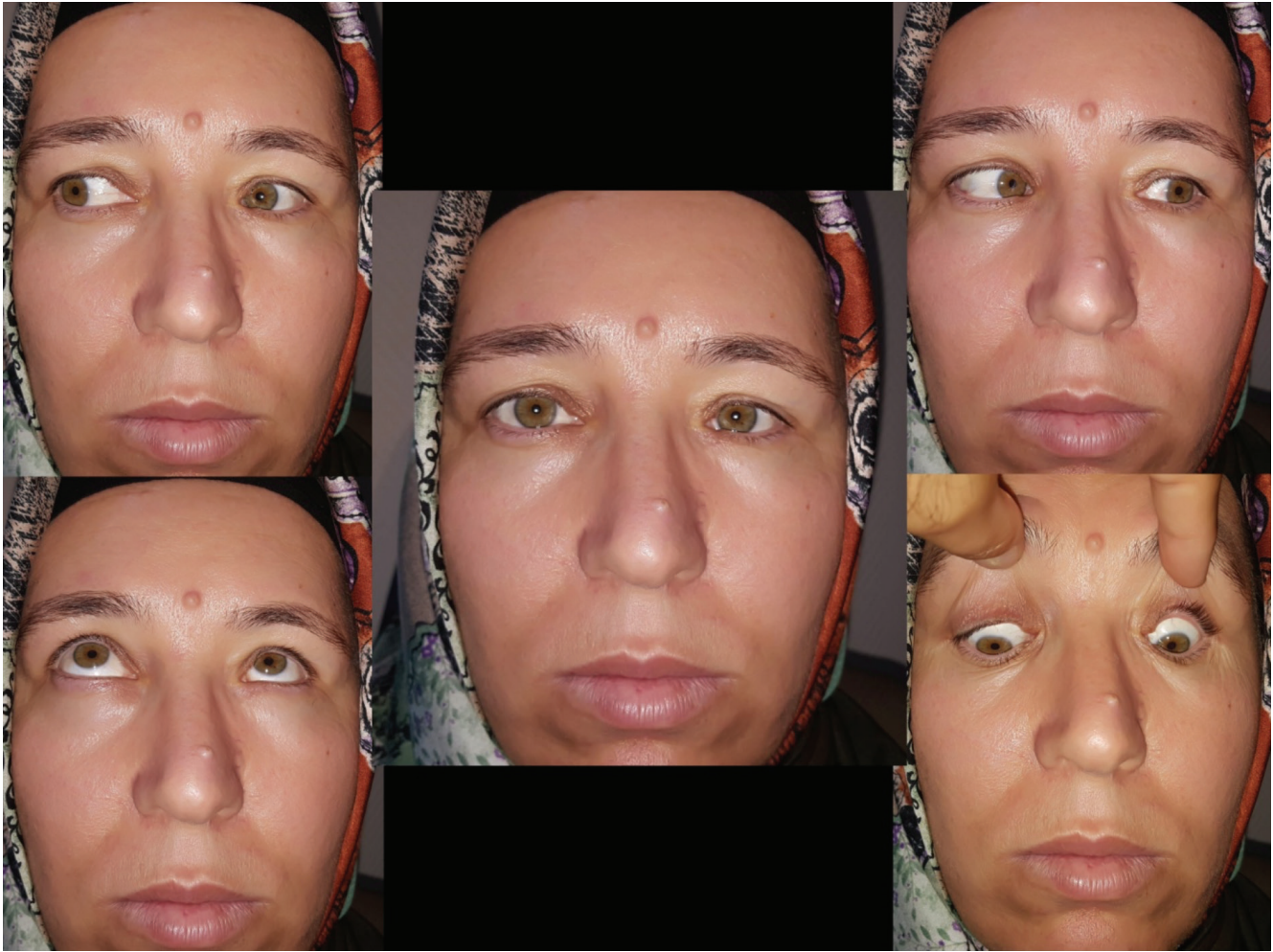structure, this porous, biocompatible polyethylene implant enables a large defect to be repaired through a small space. On postoperative CT, left eye enophthalmos and irregular medial orbital wall were observed (Figure 4a,b). At 6 months, visual acuity was 10/10 (with -1.75 cylinder, 160 axis) with 1 mm enophthalmos and -2 restriction on adduction (Figure 5). It was decided to continue follow-up. There were no changes in the patient's condition during the 3-year follow-up.



**Figure 3.** On postoperative day 1 there was eyelid edema, subconjunctival hemorrhage, and complete limitation of eye movement in all directions



**Figure 4. a,b)** Computed tomography after left globe repositioning and medial wall repair showing enophthalmos and irregularity in the medial wall



**Figure 5.** At 6 months after the trauma, the left eye shows orthophoria in primary position, enophthalmos, and limitation of adduction

## Discussion

In blowout fractures caused by blunt trauma, the globe remains in the orbit despite displacement of the orbital soft tissue and muscle structures toward the adjacent sinus cavities. However, in rare cases of severe trauma and possibly involving a different mechanism, the globe can be dislocated from the orbit to the adjacent cavities.<sup>3</sup> This is also described in the literature as traumatic herniation or subluxation of the globe.<sup>4,5</sup> Dislocation into the maxillary sinus is most common, followed by the ethmoid sinus.<sup>2</sup> Even less common is dislocation into the frontal sinus<sup>6</sup> and the anterior cranial fossa behind the orbit.<sup>7</sup> No cases of globe dislocation into the sphenoid sinus have been reported. With traffic accidents and blunt trauma, the globe is often dislocated intact through a wide fracture line in the medial and inferior walls of the orbit. In our case, a blunt object (doorknob) penetrated nasally from the caruncle and fractured the medial wall without damaging the globe, likely compressing and carrying the globe with it through the fracture before exiting again.

At initial examination, the appearance of an anophthalmic socket when the eyelids are parted and the fact that the patient often has no light perception suggest a catastrophic injury such as traumatic evisceration. Performing orbital CT is absolutely necessary for an accurate diagnosis. Although visualizing the displaced globe in the adjacent sinus cavity on CT confirms the diagnosis, knowing how to intervene and doing so rapidly are crucial for anatomical and visual prognosis of the eye. Visual prognosis is determined by the trauma severity, affected ocular structures, and timing of treatment.<sup>8</sup> An unusual position caused by globe displacement may cause temporary or permanent loss of function due to avulsion, compression, crushing, or stretching of the optic nerve. In addition, damage to the central retinal artery and chorioretinal tissues are other pathologies that should be kept in mind in case of vision loss.<sup>1,9</sup> Ramstead et al.<sup>10</sup> reported a patient with globe dislocation into the maxillary sinus after a rodeo fall whose visual acuity remained at 0.1 despite successful globe repositioning, due to associated choroidal rupture and submacular hemorrhage. Blindness and visual impairment to

the level of light perception have been reported in 46% of documented cases.<sup>3</sup> The fact that all patients reported to have visual improvement underwent globe repositioning on the same day demonstrates the importance of rapid intervention.

In conclusion, rapid globe repositioning indisputably contributes to visual rehabilitation in eyes with visual potential by relieving stress on the optic nerve and central retinal artery. An acceptable cosmetic result can also be achieved by restoring eye movements and orbital volume.

#### **Ethics**

**Informed Consent:** Obtained

**Peer-review:** Externally peer reviewed.

#### **Authorship Contributions**

Surgical and Medical Practices: Z.O., G.Ş., O.K., Concept: Z.O., Design: Z.O., G.Ş., Data Collection or Processing: Z.O., Analysis or Interpretation: Z.O., G.Ş., O.K., Literature Search: Z.O., Writing: Z.O.

**Conflict of Interest:** No conflict of interest was declared by the authors.

**Financial Disclosure:** The authors declared that this study received no financial support.

#### **References**

1. Haggerty CJ, Roman P. Repositioning of a traumatically displaced globe with maxillary antrostomy: review of the literature and treatment recommendations. *J Oral Maxillofac Surg.* 2013;71:1915-1922.
2. Noman SA, Shindy MI. Immediate surgical management of traumatic dislocation of the eye globe into the maxillary sinus: report of a rare case and literature review. *Craniofacial Trauma Reconstr.* 2017;10:151-158.
3. Amaral MB, Nery AC. Traumatic globe dislocation into the paranasal sinuses: Literature review and treatment guidelines. *J Craniofacial Surg.* 2016;44:642-647.
4. Abrishami M, Aletaha M, Bagheri A, Salour SH, Yazdani S. Traumatic subluxation of the globe into the maxillary sinus. *Ophthalmic Plast Reconstr Surg.* 2007;23:156-158.
5. Ginat DT, Freitag SK. Traumatic globe rupture and herniation into the maxillary sinus. *Ophthalmic Plast Reconstr Surg.* 2014;30:168.
6. Ma C, Nerad JA. Orbital roof fracture with ocular herniation. *Am J Ophthalmol.* 1988;105:700-701.
7. Liu H, Hu S, Qin W. Traumatic prolapse of the globe into the anterior cranial fossa: a case report. *BMC Ophthalmol.* 2020;20:128.
8. Tranfa F, Di Matteo G, Di Salle E, Strianese D, Bonavolontà G. Traumatic displacement of the globe into the ethmoid sinus. *Am J Ophthalmol.* 2000;130:253-254.
9. Kreiner B, Amer R, Sharfi G, Solomon A, Ilsar M. Traumatic displacement of the globe into the paranasal sinuses: case report and guidelines for treatment. *J Oral Maxillofac Surg.* 2008;66:826-830.
10. Ramstead C, McCabe J, Alkahtani M, Leong-Sit J, Morhart M. Traumatic dislocation of the globe into the maxillary sinus. *Can J Ophthalmol.* 2008;43:364-366.





# Lipemia Retinalis Diagnosed Incidentally After Laser Photocoagulation Treatment for Retinopathy of Prematurity

© Taylan Öztürk\*, © Ezgi Karataş Yiğitaslan\*, © Pelin Teke Kısa\*\*, © Hüseyin Onay\*\*\*, © Ali Osman Saatci\*

\*Dokuz Eylül University Faculty of Medicine, Department of Ophthalmology, İzmir, Turkey

\*\*Dokuz Eylül University Faculty of Medicine, Department of Pediatrics, İzmir, Turkey

\*\*\*Ege University Faculty of Medicine, Department of Medical Genetics, İzmir, Turkey

## Abstract

A preterm infant who underwent bilateral laser photocoagulation for the treatment of stage 3 retinopathy of prematurity (ROP) is presented because she was incidentally diagnosed with grade 3 lipemia retinalis by dilated funduscopy at post-laser 2 weeks. Meticulous ophthalmologic examination is imperative in premature newborns for not only ROP screening but also detecting any concomitant ocular abnormalities, which can be sight-threatening or even life-threatening.

**Keywords:** Hypertriglyceridemia, lipemia retinalis, newborn, retinopathy of prematurity

## Introduction

Lipemia retinalis (LR) is an unusual and rare pathology characterized by whitening of the retinal vessels due to high plasma triglyceride levels and scattering of light by triglyceride-laden chylomicrons. Early findings are generally observed in the peripheral retina; however, pathognomonic symptoms tend to appear at the posterior pole when plasma triglyceride levels exceed 2,500 mg/mL.<sup>1,2,3</sup> The disease can be graded as early, moderate, or marked according to retinal appearance.<sup>4</sup> As long as LR is not associated with complications like retinal vein occlusion, it generally does not interfere with visual acuity.<sup>4</sup> However, various electroretinographic changes may be noted in cases with LR.<sup>5</sup>

## Case Report

The first daughter of non-consanguineous parents was born prematurely at a gestational age of 26 weeks. Her birth weight

was 680 grams and she had grade 1 intraventricular hemorrhage with patent ductus arteriosus as well as respiratory distress syndrome. She was first screened for retinopathy of prematurity (ROP) at postnatal 6 weeks and was diagnosed with stage 1 zone 2 ROP. During her follow-up examinations, the baby developed bilateral stage 3 zone 2 ROP with plus disease, and was referred to our pediatric retina unit for laser photocoagulation at 35 weeks of gestational age. Her medical history revealed mechanical ventilation for 4 weeks during her neonatal intensive care unit stay, where she received erythrocyte transfusion and her patent ductus arteriosus closed completely with ibuprofen treatment.

Prompt laser photocoagulation treatment was scheduled soon after her initial ophthalmological examination at our pediatric retina unit. At the post-laser second week visit, dilated funduscopy showed widespread pigmented laser burns sparing the posterior pole, and significant regression of plus disease without complications in both eyes (Figure 1A, B). On the next post-laser visit at 39 weeks of gestational age, dilated funduscopy

**Address for Correspondence:** Taylan Öztürk, Dokuz Eylül University Faculty of Medicine, Department of Ophthalmology, İzmir, Turkey

Phone: +90 532 593 92 20 E-mail: ataylan6@yahoo.com **ORCID-ID:** orcid.org/0000-0001-6633-0553

**Received:** 02.05.2021 **Accepted:** 05.07.2021

**Cite this article as:** Öztürk T, Karataş Yiğitaslan E, Teke Kısa P, Onay H, Saatci AO. Lipemia Retinalis Diagnosed Incidentally After Laser Photocoagulation Treatment for Retinopathy of Prematurity. Turk J Ophthalmol 2021;51:313-316

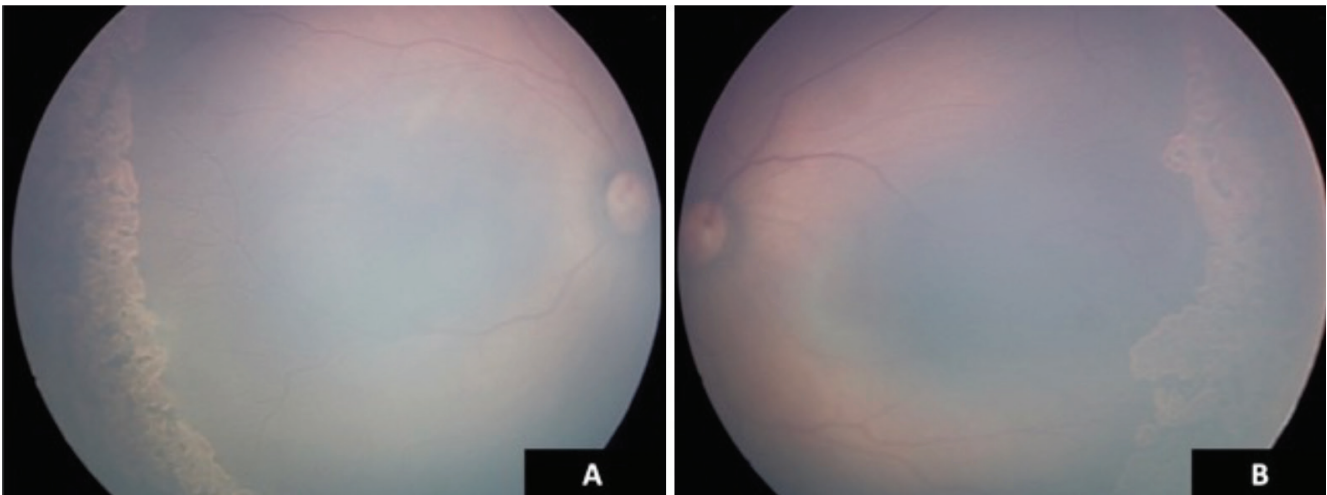
revealed no progression in ROP disease; however, bilateral retinal findings were compatible with LR. Color fundus photography also showed that all retinal vessels had a milky aspect with salmon-colored retina appearance bilaterally (Figure 2A, B). There was no family history of any lipid disorders. Since the diagnosis of grade 3 LR was made, consultation was immediately requested with the division of pediatric metabolism and blood sampling was scheduled. Her serum triglyceride level was measured as higher than 10,000 mg/dL (normal range: <150 mg/dL) and her serum low- and high-density lipoprotein levels were also found to be 490 mg/dL (normal range: <130 mg/dL) and 19 mg/dL (normal range: >40 mg/dL), respectively. The blood sample was otherwise within normal range for liver, kidney, hematologic, and endocrinologic functions, thereby ruling out secondary hyperlipidemia. Her general physical examination also did not reveal any symptoms such as hepatosplenomegaly or xanthomas that could be associated with high triglyceride and/

or cholesterol levels. Simultaneously, molecular genetic testing for apolipoprotein C-II deficiency and lipoprotein lipase (LPL) deficiency was performed by sequencing of *APOC2* and *LPL* genes, respectively, and revealed normal results.

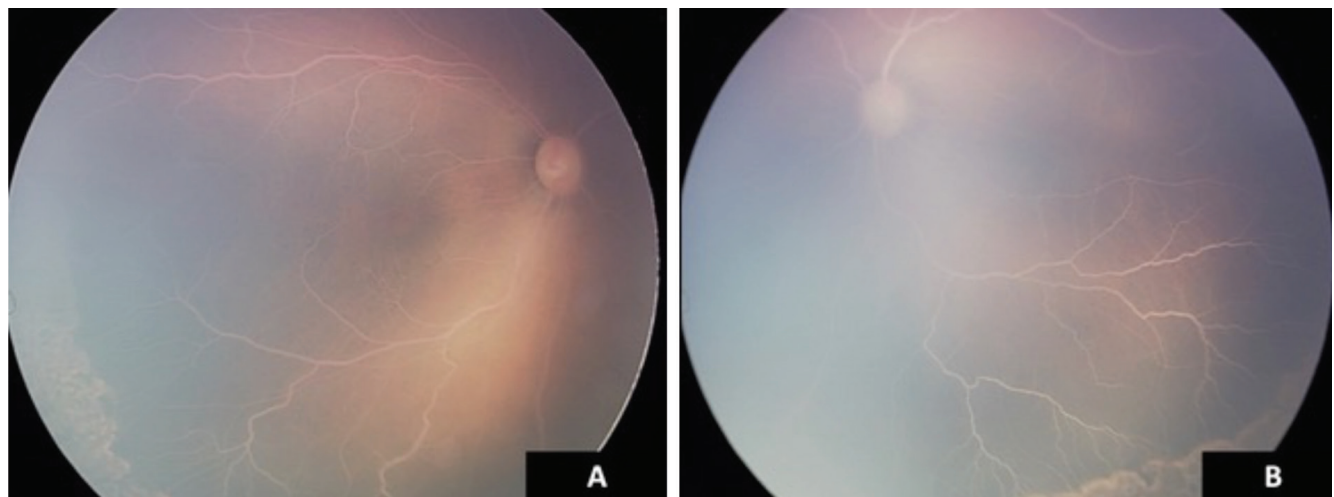
The newborn was then started on a strict low-fat diet consisting of 10-15% of her daily caloric intake comprised of fat with weaning on skimmed milk. Serum triglycerides and total serum cholesterol levels gradually decreased to normal range within 6 weeks. On her last visit, dilated funduscopy showed effective laser burns with no signs of ROP activity, as well as total regression of LR (Figure 3A, B). Her parents were strongly advised to follow her low-fat diet and continue close follow-up by a metabolic diseases specialist.

### Discussion

Careful fundoscopic screening of premature infants is mandatory to identify the signs of ROP. Moreover, various ocular



**Figure 1.** Color fundus photographs of the right (A) and left (B) eye after laser photocoagulation



**Figure 2.** Color fundus photographs depicting milky colored retinal vessels with salmon-colored retina appearance in the right (A) and left (B) eye 4 weeks after laser photocoagulation

and retinal pathologies can be diagnosed incidentally during dilated routine examinations.<sup>6</sup> Several metabolic disorders can also be detected in newborns during a thorough ophthalmic examination, even in very early stages before any prominent symptoms and signs become evident. In 1880, Heyl first described LR, which is characterized by milky-creamy white colored retinal vessels. This typical appearance generally occurs when serum triglyceride level is higher than 2500 mg/dL. Isolated hyperlipidemia without accompanying hypertriglyceridemia does not present with LR.<sup>1,2,3,4,5,6,7</sup> Hypertriglyceridemia may also occur in familial disorders like apolipoprotein C-II deficiency, LPL deficiency, and endogenous circulating low-density lipoprotein inhibitor.<sup>1</sup> Yin et al.<sup>8</sup> reported a homozygous p.G215E mutation in the *LPL* gene in a 6-week-old full-term baby with hypertriglyceridemia and LR.

Babies born preterm and those with intrauterine growth restriction may be more prone to LR due to major risk factors for hypertriglyceridemia such as low LPL activity, parenteral nutrition, and consumption of medium chain triglyceride formulas, which are very common supplements for low-birth-

weight infants.<sup>6,7,8</sup> Persistence of uncontrolled high serum levels of cholesterol and triglycerides may lead to possibly fatal morbidities including premature atherosclerosis and coronary artery disease, pancreatitis, and hepatic failure, especially in preterm and term newborns and infants.<sup>6,7,8,9,10</sup> Hence, early diagnosis of LR in such cases is crucial. Although it is known that LR generally does not affect visual acuity in sufferers, Dinc et al.<sup>11</sup> reported a pregnant Turkish women with no family history of hyperlipidemia who developed bilateral severe visual deterioration and whose visual acuity improved after delivery and increased to 20/20 with a normal fundoscopic appearance in both eyes after low-fat diet, physical exercise, and drug treatment with 3-hydroxy-3-methyl-glutaryl-coenzyme A inhibitor.

In the present case, retinal findings totally regressed in accordance with the rapid decrease in serum triglyceride and cholesterol levels after the commencement of a strict low-fat diet. Systemic assessment and pertinent laboratory tests should be carried out in patients with LR in order to determine the underlying cause, which may seriously affect the end organs due to high serum lipid levels. Therefore, early diagnosis can even be life-saving. Moreover, examination of the parents and siblings, genetic counseling, and dietary recommendations are among the essential steps to be taken.

#### Ethics

**Informed Consent:** Since presented case is a minor, detailed informed consent was obtained from her parents before laser photocoagulation for the treatment of retinopathy of prematurity.

**Peer-review:** Externally and internally peer reviewed.

#### Authorship Contributions

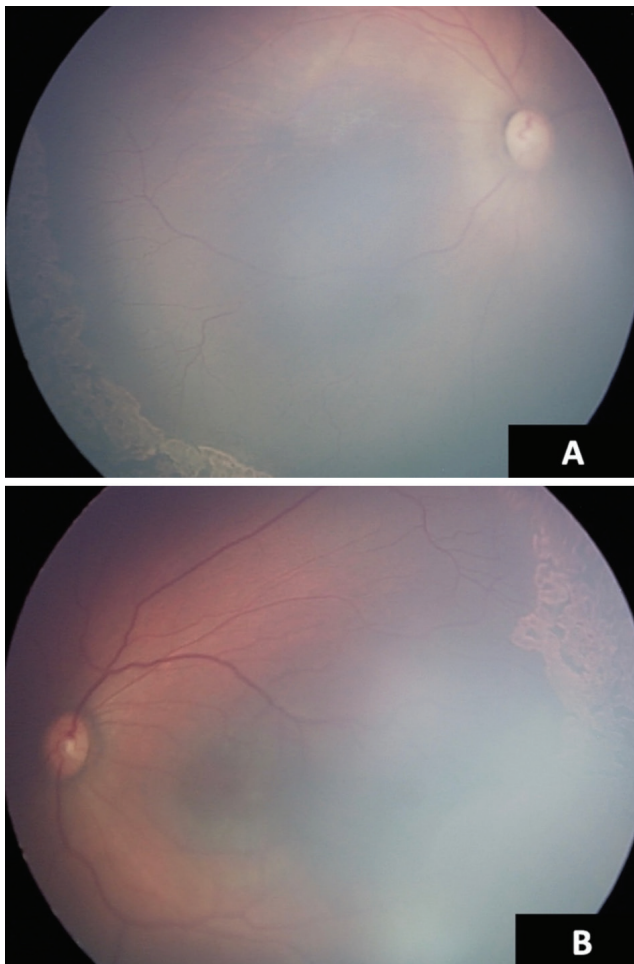
Surgical and Medical Practices: T.Ö., P.T.K., H.O., Concept: T.Ö., A.O.S., Design: T.Ö., E.K.Y., T.K.K., Data Collection or Processing: T.Ö., E.K.Y., P.T.K., Analysis or Interpretation: T.Ö., A.O.S., Literature Search: T.Ö., E.K.Y., Writing: T.Ö., E.K.Y.

**Conflict of Interest:** No conflict of interest was declared by the authors.

**Financial Disclosure:** The authors declared that this study received no financial support.

#### References

- Zahavi A, Snir M, Kella YR. Lipemia retinalis: Case report and review of the literature, *JAAPOS*. 2013;17:110-111.
- Shinkre ND, Usgaonkar UPS. Lipemia retinalis in a 27 day old neonate: A case report. *Indian J Ophthalmol*. 2019;67:954-957.
- Vinger PE, Sachs BA. Ocular manifestations of hyperlipoproteinemia. *Am J Ophthalmol*. 1970;70:563-573.
- Nagra PK, Ho AC, Dugan JD Jr. Lipemia retinalis associated with branch retinal vein occlusion. *Am J Ophthalmol*. 2003;135:539-542.
- Lu CK, Chen SJ, Niu DM, Tsai CC, Lee FL, Hsu WM. Electrophysiological changes in lipemia retinalis. *Am J Ophthalmol*. 2005;139:1142-1145.
- Jain A, Mochi TB, Braganza SD, Agrawal S, Shetty BK, Pachiyappan B. Lipemia retinalis in an infant treated for retinopathy of prematurity. *J AAPOS*. 2017;21:254-257.
- Cermakova I, Pattenazzo A, Perrone S, Burlina A, Zannin ME. Grade III lipaemia retinalis in a newborn. *Acta Ophthalmol*. 2010;88:141-142.



**Figure 3.** Totally normal color fundus photographs of the right (A) and left (B) eye after low-fat diet

8. Yin HY, Warman R, Suh EH, Cheng AM. Exceptionally elevated triglyceride in severe lipemia retinalis. *Int Med Case Rep J.* 2016;9:333-336.
9. Horton M, Thompson K. Lipemia retinalis preceding acute pancreatitis. *Optometry.* 2011;82:475-480.
10. Cortner JA, Coates PM, Liacouras CA, Jarvik GP. Familial combined hyperlipidemia in children: clinical expression, metabolic defects, and management. *J Pediatr.* 1993;123:177-184.
11. Dinc D, Dincer N, Eltutar K. Lipemia retinalis: Case report. *Turkiye Klinikleri J Med Sci.* 2012;32:1433-1436.



# Challenges in the Diagnosis of Intraocular Lymphoma

✉ Mahmut Kaya\*, ✉ Ferit Hakan Öner\*, ✉ Banu Lebe\*\*, ✉ Sermin Özkal\*\*, ✉ Süleyman Men\*\*\*,  
✉ Ali Osman Saatci\*

\*Dokuz Eylül University Faculty of Medicine, Department of Ophthalmology, İzmir, Turkey

\*\*Dokuz Eylül University Faculty of Medicine, Department of Pathology, İzmir, Turkey

\*\*\*Dokuz Eylül University Faculty of Medicine, Department of Radiology, İzmir, Turkey

## Abstract

Intraocular lymphomas are among the rare malignancies that present with a wide variety of clinical manifestations. Differential diagnosis can be very troublesome due to its mimicking nature, insidious disease onset, and partial treatment response to steroids. The most important step in diagnosis is a high index of suspicion. Signs of the disease are now easier to detect using multimodal imaging techniques. In this case series, we reviewed the clinical characteristics of two women aged 70 and 71 years and a 72-year-old man with intraocular lymphoma and described their multimodal imaging findings in detail. Bilateral eye involvement was present in all three cases at our first ophthalmological examination. While the disease first presented with ocular involvement in two of the three cases, ocular involvement was detected seven years after initial heart involvement in one patient. All three patients had diffuse large B-cell lymphomas (one diagnosed with retinal biopsy, one with conjunctival biopsy, and the remaining with stereotactic brain biopsy). Intraocular lymphoma should be diagnosed and treated using a multidisciplinary approach, and we share our experience in this case series.

**Keywords:** Eye, conjunctiva, lymphoma, optical coherence tomography, optical coherence tomography angiography, retina, retinal biopsy

## Introduction

Intraocular lymphoma is a general definition that encompasses tumors that are primary or secondary to systemic (metastatic) lymphoma. The primary type includes primary vitreoretinal lymphoma and primary uveal lymphoma. Primary vitreoretinal lymphoma is a type of non-Hodgkin lymphoma with high malignancy potential that develops with or without central nervous system (CNS) involvement. The secondary type occurs as a result of systemic lymphomas invading the choroid.<sup>1,2,3</sup> Intraocular lymphomas account for less than 1% of all intraocular tumors and 1-2% of extranodal

lymphomas.<sup>4,5,6,7</sup> Most primary intraocular lymphomas are primary CNS non-Hodgkin and diffuse B-cell lymphomas, though CNS involvement is observed in only 60-80% of patients.<sup>8</sup> Four patterns of organ involvement have been reported in intraocular lymphoma: (1) ocular and CNS (61%), (2) intraocular only (17%), (3) ocular and internal organ (17%), and (4) ocular, internal organ, and CNS (5%).<sup>9,10</sup>

Most patients are middle-aged or older (50-70 years) and the female to male ratio is approximately 2:1.<sup>4</sup> Approximately 30% of the patients have unilateral ocular involvement, while 80-90% have bilateral involvement.<sup>6,7</sup> The mortality risk at 12 to 36-month follow-up is 9-81%. The 5-year survival rate is less

**Address for Correspondence:** Ali Osman Saatci, Dokuz Eylül University Faculty of Medicine, Department of Ophthalmology, İzmir, Turkey

E-mail: osman.saatci@deu.edu.tr **ORCID-ID:** orcid.org/0000-0001-6848-7239

**Received:** 23.07.2020 **Accepted:** 03.05.2021

**Cite this article as:** Kaya M, Öner FH, Lebe B, Özkal S, Men S, Saatci AO. Challenges in the Diagnosis of Intraocular Lymphoma. Turk J Ophthalmol 2021;51:317-325

©Copyright 2021 by Turkish Ophthalmological Association

Turkish Journal of Ophthalmology, published by Galenos Publishing House.

than 5% and tumor recurrence usually occurs within the first 3 years of diagnosis.<sup>4,6,7</sup>

Intraocular lymphomas almost always pose serious diagnostic and therapeutic challenges to ophthalmologists. This clinical entity, classically referred to as “uveitis masquerade syndrome,” can mimic chronic uveitis in adult or older patients. However, unlike many uveitis entities, early diagnosis is crucial due to its life-threatening nature.

In this case series, we examine the presenting clinical features, multimodal images, and clinical course and prognosis of two patients with suspected intraocular lymphoma whose diagnosis was confirmed by ocular biopsy and one patient in whom cardiac lymphoma presented years later with ocular involvement.

## Materials and Methods

This report includes 3 patients who presented to the retina unit of the Dokuz Eylül University Faculty of Medicine, Department of Ophthalmology with complaints of blurred vision, reduced visual acuity, and floaters between December 2017 and March 2020. Ocular lymphoma was suspected based on the patients’ ocular and systemic examination findings and the diagnosis was confirmed by histopathologic examination of a biopsy specimen. We retrospectively reviewed the records pertaining to these three cases of histopathologically diagnosed diffuse B-cell non-Hodgkin lymphoma.

## Case Reports

### Case 1

A 71-year-old woman presented with complaints of low vision and floaters in her left eye. The patient had undergone uncomplicated bilateral cataract surgery 8 months earlier. She reported losing vision in her right eye 2 months earlier and the onset of her current complaints in the left eye 4 days earlier. Her history of systemic disease included a 12-year history of systemic hypertension and 4-year history of moderate heart failure. She had no history of cancer.

Best corrected visual acuity (BCVA) was 0.4 in the left eye and there was no light perception in the right eye. On anterior segment examination, both eyes were pseudophakic with +2 cells in the anterior chamber and +1 cells in the anterior vitreous. Intraocular pressure was within normal limits in both eyes. Dilated fundus examination of the right eye revealed intensive vitritis, vitreous condensation, and a raised, yellow/cream-colored lesion with indistinct margins in the macular area that extended to the vascular arcades, spread below and within the retina, and was also associated with intraretinal hemorrhage (Figure 1A). In the left eye, a single large lesion was observed at the inferior vascular arcade, while in the temporal region, multiple poorly defined cream-colored deposits were observed under the retinal pigment epithelium (RPE) (Figure 1B, C). On fluorescein angiography (FA), relatively localized leakage appearing in the early phase and intensifying in the late phase was observed in the area corresponding to the lesion in the right

eye (Figure 1D), while in the left eye, there were early and late hypofluorescent foci in the macula and temporal area with mild leakage from the temporal foci in the late phase (Figure 1E, G). Swept-source optical coherence tomography (SS-OCT) images could not be obtained in the right eye, while the left eye showed disruption of the outer retinal layers, multiple small pigment epithelial detachments (PED), and a hyperreflective sub-RPE lesion (possibly lymphocytic infiltration) with posterior shadowing in the temporal area (Figure 1C). SS-OCT angiography imaging was not possible in the right eye and revealed minimal vascular changes in the superficial and deep capillary plexuses and a hyporeflective area associated with infiltration in the choriocapillaris layer in the left eye. Both SS-OCT angiography and en-face imaging in the left eye showed extensive shadowing corresponding to the superficial, deep, and outer retinal and choriocapillaris layers in the inferotemporal region including the macula (Figure 2A-D). The patient was admitted to our department with a clinical prediagnosis of chronic endophthalmitis and intraocular lymphoma. Pars plana vitrectomy was performed in the right eye to rule out endophthalmitis and lymphoma and a vitreous biopsy specimen was obtained. Polymerase chain reaction (PCR) samples yielded no positive findings. Tests to rule out systemic infectious etiologies resulted negative (herpes simplex virus IgM/IgG, *Toxoplasma* IgM/IgG, cytomegalovirus IgM/IgG, venereal disease research laboratory [VDRL]/rapid plasma reagin [RPR], fluorescent treponemal antibody absorption [FTA-Abs], *Brucella*). Pulmonology consultation was requested for tuberculosis and sarcoidosis but no positive signs were detected. Brain magnetic resonance imaging (MRI) revealed no pathology except for an enhancing mass lesion adjacent to the optic disc in the right globe (Figure 2E). While the patient’s examinations continued, she developed complicated retinal detachment in the right eye after core vitrectomy. With no expectation of vision in the right eye due to the complicated retinal detachment and lack of light perception, retinal biopsy and vitreoretinal surgery with silicone oil were performed after obtaining the patient’s consent. The result of histopathological examination of the biopsy sample was diffuse large B-cell lymphoma (Figure 2F, G). Due to the presence of optic nerve involvement in the right eye, systemic chemotherapy and a single dose of intrathecal methotrexate were administered in the hematology unit of our hospital, and regression of the eye lesions was observed (Figure 3A, B). However, the patient died due to complications associated with systemic chemotherapy approximately 5 months after the onset of ocular complaints.

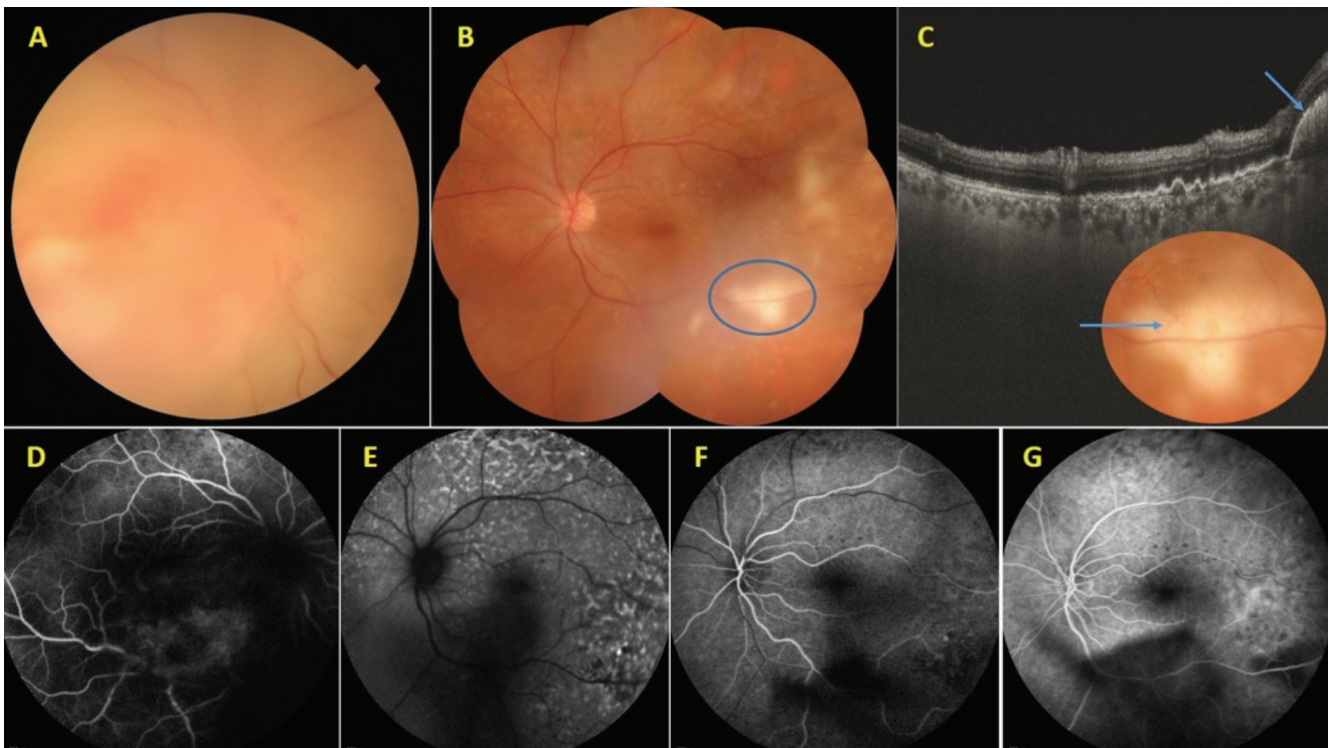
### Case 2

A 70-year-old woman presented to our clinic with complaints of blurred vision in both eyes that had started 4-5 months earlier and became more pronounced in the past month. However, brain MRI performed at another center had not revealed any pathology. One month before presenting to

our clinic, she started treatment with oral methylprednisolone 32 mg/day and topical prednisolone and nepafenac at another center. She had an 8-year history of diabetes mellitus being monitored with insulin. Her BCVA was light perception in the right eye and counting fingers from 1 meter in the left eye. Anterior segment examination revealed a 3x4 mm nodular mass in the upper temporal bulbar conjunctiva (Figure 4A), chemosis and +2 cells in the anterior chamber and +1 cells in the anterior vitreous in the right eye and pseudophakia, +1 cells in the anterior chamber, and +2 cells in the anterior vitreous in the left eye. Intraocular pressures were within normal limits. On dilated fundus examination, there was dense vitritis, a mass including the macula and extending to the periphery, and exudative retinal detachment in the right eye. The left eye showed intense vitritis, exudative retinal detachment involving the macula and extending peripherally, sporadic intraretinal hemorrhages, and multiple large, yellowish cream-colored choroiditis-like lesions (Figure 4B). On FA, no image could be obtained from right eye due to severe media opacity, while mild optic disc staining and leakage from choroidal lesions in the macular and inferior area that appeared in the early phase and intensified in the late phase were observed in the left eye. Spectral-domain optic coherence tomography (SD-OCT) showed no image in the right eye and a hyperreflective lesion consistent with lymphocytic infiltration in the outer retinal layers of the left eye (Figure 4C).

Tests to rule out infectious etiologies resulted negative (herpes simplex virus IgM/IgG, *Toxoplasma* IgM/IgG, cytomegalovirus IgM/IgG, VDRL/RPR, FTA-Abs, *Brucella*). Pulmonology consultation for tuberculosis and sarcoidosis yielded no positive signs for these conditions. For the differential diagnosis of endogenous endophthalmitis and intraocular lymphoma, diagnostic vitrectomy to obtain a vitreous biopsy sample was performed twice in the right eye and once in the left eye. In the same session as the biopsy, intravitreal 1 mg/0.1 mL vancomycin, 2.25 mg/0.1 mL ceftazidime, and 0.4 mg/0.1 mL dexamethasone injections were administered for suspected infectious endophthalmitis. No bacteria, yeast, or hyphae were observed on direct examination; bacterial and fungal cultures were negative. No atypical cells were observed in the cytological examination for lymphoma and no positive results were obtained on PCR. No enhancing focus was detected by positron emission tomography. The patient's visual complaints increased, and a Tenon-conjunctival biopsy specimen was obtained from the nodular mass in the right superotemporal bulbar conjunctiva. The pathology report indicated diffuse large B-cell lymphoma (Figure 4D, E). After diagnosis, intravitreal 400 µg/0.1 mL methotrexate was administered twice to the right eye and once to the left eye in addition to systemic therapy.

A second brain MRI performed 1 month after histopathological diagnosis due to the onset of altered consciousness, malaise,



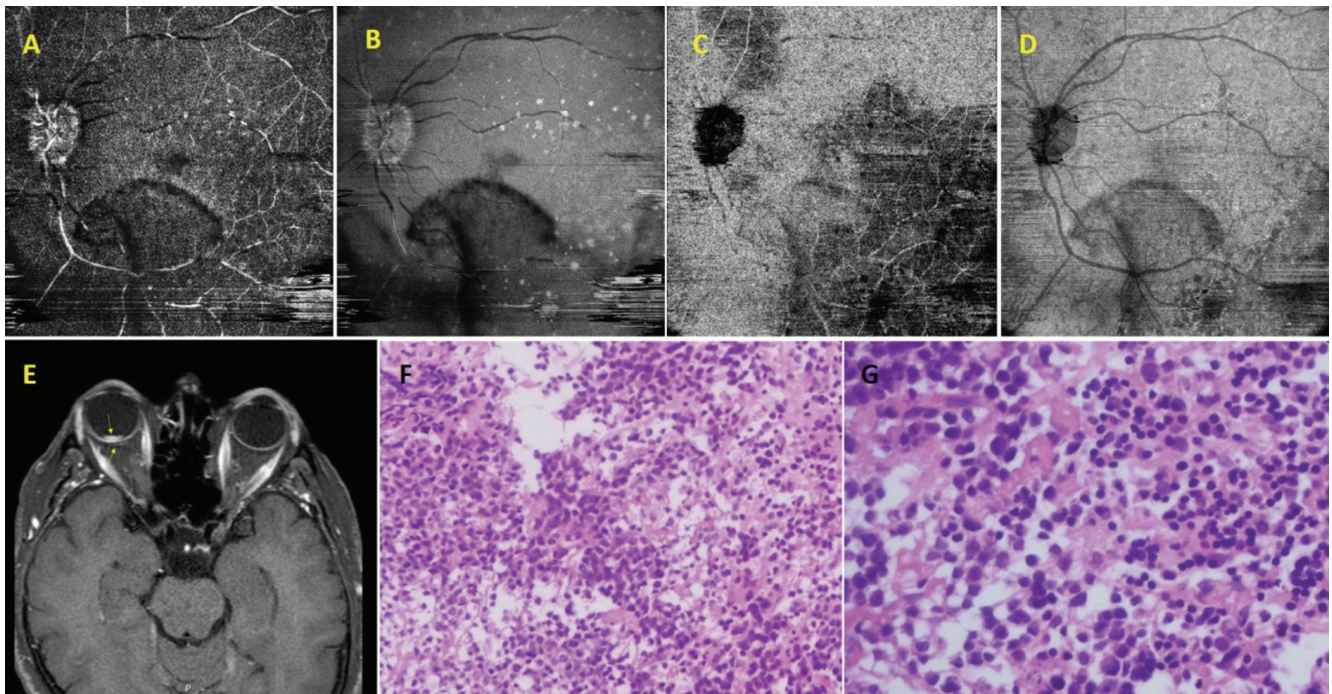
**Figure 1.** Patient 1. Color fundus images show intense vitritis and intraretinal and subretinal yellowish cream-colored lymphoma infiltration filling the macular area in the right eye (A) and multifocal sub-retinal pigment epithelium (RPE) lesions suspected to be infiltrative in the left eye (B and C, blue circle/arrows). Fluorescein angiography of the right eye showed regional leakage appearing in the early phase and intensifying in the late phase (D). In the left eye, fundus autofluorescence imaging revealed multifocal hyperautofluorescent spots (E) and fluorescein angiography showed early and late hypofluorescent foci in the macula and temporal area (F, G)

vomiting, and headache revealed widespread CNS lymphoma. The patient died of CNS lymphoma approximately 12 months after the onset of ocular complaints.

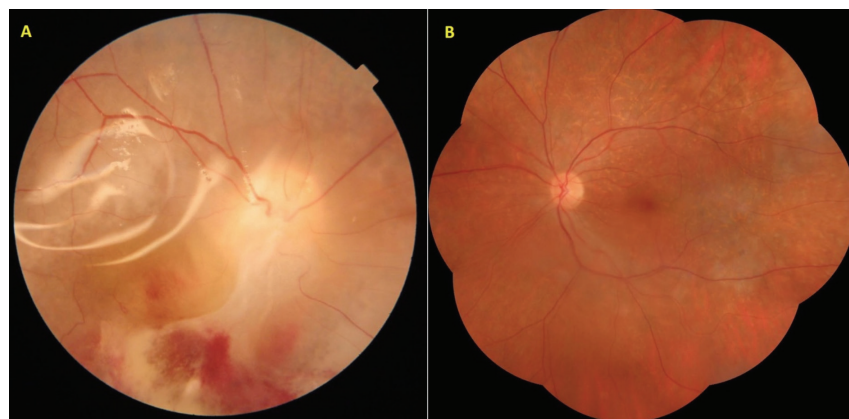
**Case 3**

A 72-year-old man presented to our clinic with complaints of low vision in his right eye. His medical history included a diagnosis of diffuse cardiac large B-cell lymphoma 7 years earlier. He reported having no problems in routine follow-up after chemotherapy and stem cell transplantation. On ophthalmologic examination performed at admission, BCVA was counting fingers at 1 meter in the right eye and 0.8 in the left eye. No

pathology other than bilateral 2+ nuclear sclerosis was detected on biomicroscopic examination. Intraocular pressure was 24 mmHg in the right eye and 23 mmHg in the left eye. Fundus examination revealed vitreous turbidity (+2 vitritis) and a large, poorly defined, yellow/cream-colored subretinal choroidal lesion in the macular temporal region in the right eye and drusen-like small white spots in the posterior pole of the left eye (Figure 5A, C). SD-OCT showed subretinal fluid in the right eye and disruption of the outer retinal layers, multiple small PEDs and hyperechogenicity, and drusen-like structures in the left eye (Figure 5B, D). On FA, multiple leaks appearing in the early

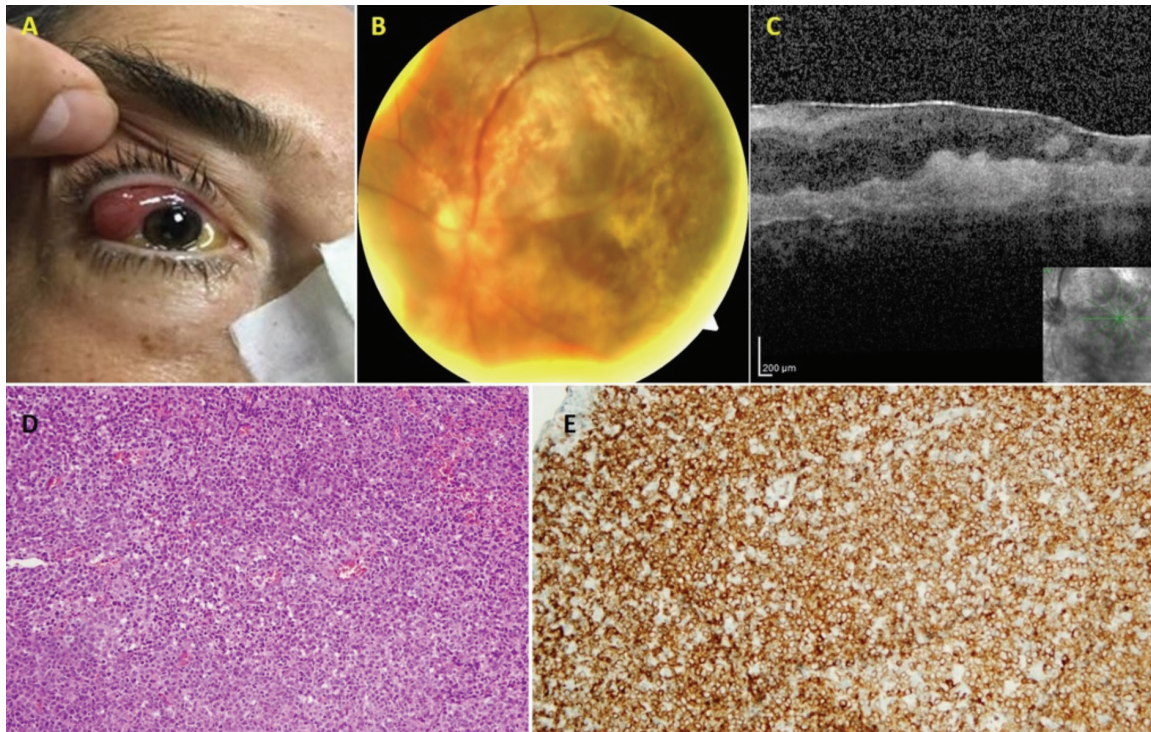


**Figure 2.** Patient 1. On swept-source optical coherence tomography angiography (12x12 mm), deep capillary plexus and corresponding en face images showed a hyporeflective area approximately 3 disc diameters in size in the macular area corresponding to the subretinal/intraretinal lymphocytic infiltration and multifocal hyperreflective spots in the macular area (A-C). In choriocapillaris layer and corresponding en face images, the lymphocytic infiltration appeared as a larger hyporeflective area with multifocal hyporeflective spots (B,-D). Brain magnetic resonance imaging revealed an enhancing mass lesion adjacent to the optic disc in the posterior pole of the right eye (E, yellow arrows). Retinal biopsy showed intense infiltration of large lymphoid cells containing atypical nuclei (right eye, hematoxylin-eosin, x200 [F] and x400 [G])

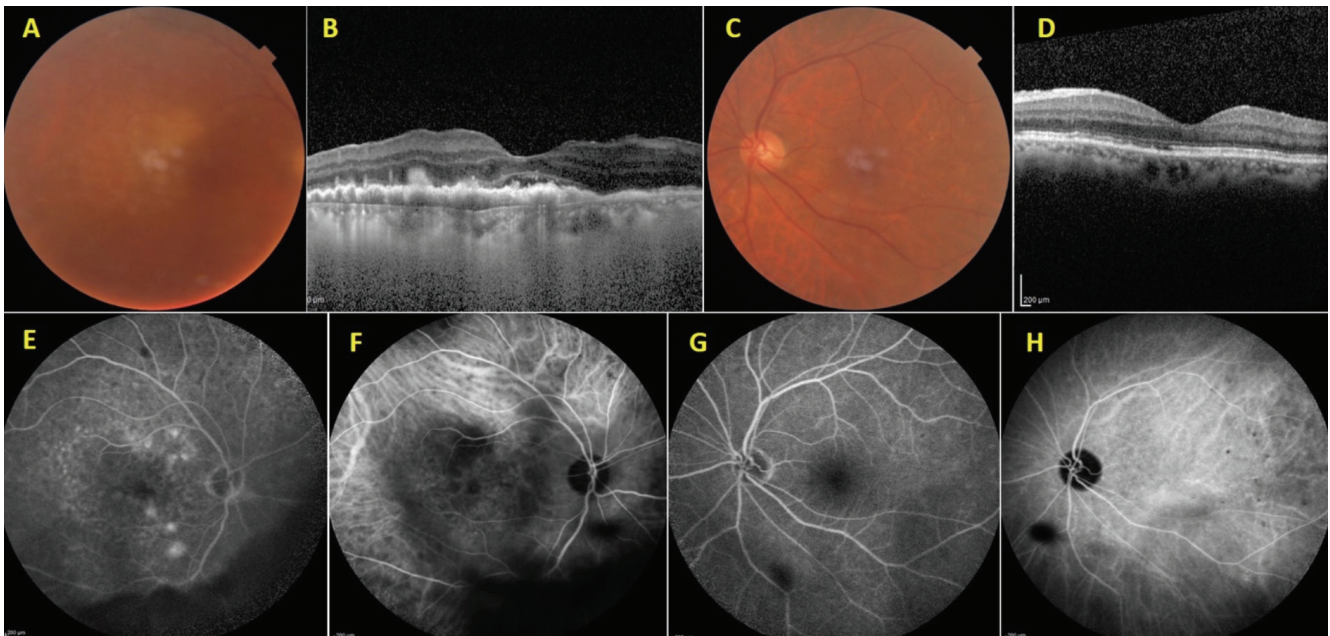


**Figure 3.** Patient 1. During treatment, color fundus images showed regression of the mass and lesion foci in the right and left eyes (A, B)





**Figure 4.** Patient 2. Anterior segment examination showed a pronounced conjunctival lymphoma infiltration in the superotemporal area of the right eye (A). Color fundus image of the left eye showed a yellowish cream-colored lymphoid mass that filled the macular area and extended past the vascular arcades (B). On spectral-domain optical coherence tomography, a cross-section through the lesion in the left eye revealed a hyperreflective lesion suspected to be lymphocytic infiltration in the outer retinal layers (C). Tenon-conjunctival biopsy of the superotemporal nodular conjunctival mass in the right eye showed atypical lymphoid cells in the lamina propria and infiltrating the conjunctival epithelium (D, hematoxylin-eosin x200). On immunohistochemical examination, diffuse cell distribution was observed in CD20 antibody staining (E)



**Figure 5.** Patient 3. Color fundus images showed mild vitritis and multifocal yellowish cream-colored intraretinal and subretinal lymphoma infiltration up to 2-3 disc diameters in size in the temporal macula in the right eye (A) and multifocal, well-defined drusen-like lesions in the temporal macula in the left eye (C). Spectral domain optical coherence tomography showed subretinal fluid and a hyperreflective lesion thought to be intense lymphocytic infiltration in the choroidal, subretinal, and outer retinal layers of the right eye (B) and a hyperreflective drusen-like lesion thought to be lymphocytic infiltration at the retinal pigment epithelium and ellipsoid zone level (D). On fluorescein angiography, late hyper- and hypofluorescence spots and leakage were observed in the right and left eyes (E-G). Indocyanine green angiography revealed hypofluorescent spots that were extensive in the right eye but appeared only in the temporal area in the left eye (F-H)

phase and intensifying in the late phase were observed in the macula in the right eye, while no significant leakage was observed in the left eye (Figure 5E, G). Indocyanine green angiography (ICGA) revealed well-defined areas of hypofluorescence in the macula and peripheral retina of the right eye and the temporal area of the left eye (Figure 5F, H). SS-OCT angiography showed minimal vascular changes in the superficial and deep capillary plexuses in the right eye and no pathology in the left eye. In the right eye, both SS-OCT angiography and en-face imaging showed extensive shadowing from the lesions in the macula and temporal region in the area corresponding to the corresponding to the superficial, deep, and outer retinal and choriocapillaris layers, while the left eye showed multiple hyperreflective lesions corresponding to only the choriocapillaris layer (Figure 6A-H).

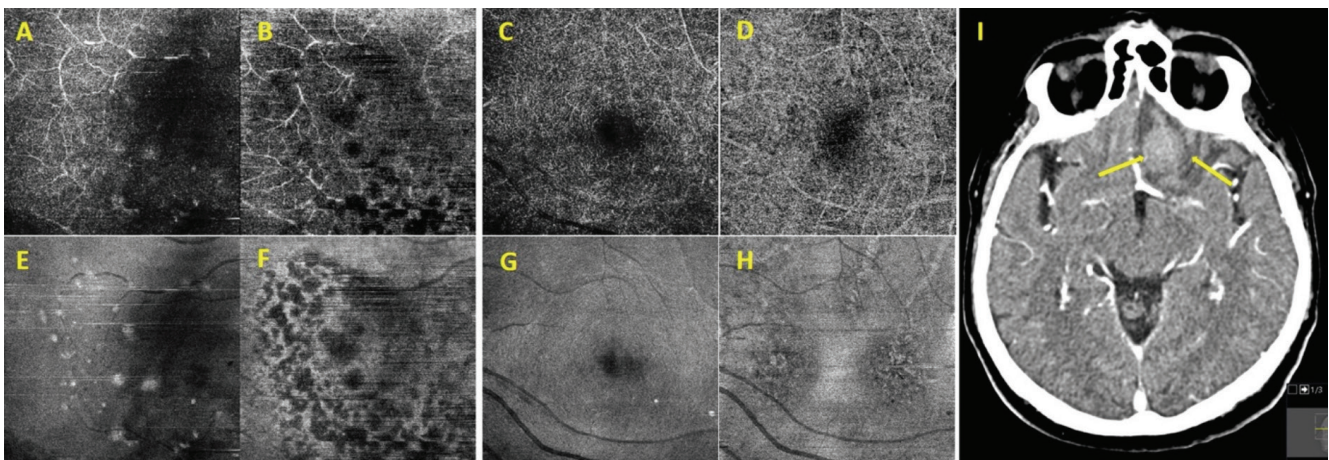
On cranial computed tomography, a hyperdense mass lesion arising from the left frontal lobe gyrus rectus and causing vasogenic edema was observed in axial precontrast and postcontrast sections (Figure 6I). The lesion's isodensity to gray matter in precontrast examination and strong homogeneous enhancement in postcontrast examination were considered typical for lymphomatous involvement. At the patient's request, he was referred with a detailed discharge report back to the other university clinic where he had been followed previously for cardiac lymphoma. In a telephone follow-up with the patient, he reported that diagnostic stereotactic brain biopsy of the lesion had been performed in the neurosurgery department and the pathology results were consistent with lymphoma.

## Discussion

The diagnostic features of primary intraocular lymphoma were determined according to the International Primary CNS Lymphoma Group.<sup>11</sup> These are: (a) age 50 years and older in most patients, (b) painless vision loss and floaters, (c) bilateral eye involvement, initially monocular involvement in

some cases, (d) different types of keratic precipitates, and (e) although uncommon, scleritis, pseudohypopyon, hyphema, and anterior and posterior synechiae. Vitreous cell infiltration is generally observed, appearing as large cells in characteristic streaks in the anterior vitreous. Cell clusters in the vitreous should arouse suspicion of lymphoma, but snow banking, vitreous hemorrhage, and retinal holes are not among the expected findings in lymphoma. Multifocal cream/yellow-white lesions with tendency to confluence in the outer retinal layers or under the RPE, leopard-spot retinal lesions, RPE atrophy, and fibrosis should also raise suspicion for lymphoma. Retinal hemorrhage, retinal vasculitis, macular edema, retinal detachment, and necrotizing retinitis can be seen in advanced stages of disease.<sup>11</sup> Anterior synechiae and iris depigmentation hardly ever occur in these patients. In all three cases presented here, the diagnostic features summarized by the International Uveitis Study Group were also taken into consideration and intraocular lymphoma was suspected during their initial admission examinations.

Intraocular lymphomas are rare malignancies with highly variable clinical manifestations; therefore, differential diagnosis is quite difficult. Delayed diagnosis is common because it has an insidious onset, mimics other uveitis entities, and shows an initial partial response to steroid therapy. In these patients, the disease can often be clinically masked by chronic uveitis and vitritis of unknown cause.<sup>3,6,12</sup> The differential diagnosis of lymphoma should include benign reactive lymphoid hyperplasia of the uvea, systemic non-Hodgkin lymphoma, metastatic tumors, amelanotic melanoma, and uveitic entities. Infectious and inflammatory uveitis entities include endogenous endophthalmitis, toxoplasmosis, acute retinal necrosis, cytomegalovirus retinitis, syphilis, tuberculosis, sarcoidosis, acute posterior multifocal plaque pigment epitheliopathy, multifocal choroiditis, and birdshot chorioretinopathy.<sup>12</sup> The



**Figure 6.** Patient 3. On swept-source optical coherence tomography angiography (6x6 mm), deep capillary plexus and corresponding en face images in the right eye showed multifocal hyperreflective spots corresponding to the choriocapillaris/subretinal/intraretinal lymphocytic infiltration (A, E). In choriocapillaris layer and compatible en face images, the lymphocytic infiltration appeared as a larger hyporeflective area with multifocal confluent hyporeflective spots (B, F). In the left eye, deep capillary plexus and corresponding en face images showed several hyperreflective spots (C, G) and choriocapillaris layer and corresponding en face images showed clusters of multifocal hypo- and hyperreflective spots consistent with lymphocytic infiltration in the macular area (D, H). On brain computed tomography, post-contrast axial sections revealed a hyperdense mass lesion arising from the left frontal lobe gyrus rectus causing adjacent vasogenic edema (I, yellow arrows)

key to early diagnosis of intraocular lymphoma is clinical suspicion. In ophthalmological examination, characteristic findings on multimodal imaging reinforce the suspicion of intraocular lymphoma. In our case series, although lymphoma was initially suspected in patient 2 based on clinical findings of bilateral chronic vitritis that did not respond to treatment, the negative results in cytologic examination of vitreous specimens led to a late diagnosis. Considering endogenous endophthalmitis due to uncontrolled diabetes mellitus, vitreous culture was performed and the patient was treated with intravitreal 1 mg/0.1 mL vancomycin, 2.25 mg/0.1 mL ceftazidime, and 0.4 mg/0.1 mL dexamethasone at regular intervals. However, the vitreous culture was negative. As the patient did not respond to treatment for endophthalmitis and enlargement of the conjunctival mass was observed, a conjunctival biopsy of the nodular mass was performed and enabled the diagnosis of intraocular lymphoma. In most cases reported in our country, a definitive diagnosis was made by brain biopsy. The demographic and clinical characteristics and definitive diagnostic methods of intraocular lymphoma patients reported in the literature from our country are summarized in Table 1.

Although a definitive diagnosis of intraocular lymphoma is made histopathologically, some multimodal fundus imaging findings are typical.<sup>12,13,14,15,16,17,18,19,20,21,22</sup> On fundus examination and color fundus photography, vitreous opacification may be seen due to lymphoma cell infiltration, but most cases present with typical yellowish-white irregular lesions that form in the outer retinal layers and/or under the RPE due to infiltration and tend to merge and expand. The characteristic brownish pigment accumulation in the yellowish-white lesions causes the specific leopard-spot pattern seen in intraocular lymphoma. The yellowish-white lesions in the outer retinal layers and under the RPE may shrink with treatment or atrophy over time without treatment. Although FA findings are not characteristic, some typical findings include round or well-defined hypofluorescent lesions in the early and late phases resulting from blockade by the sub-RPE infiltrative lesion, as well as granular hyperfluorescence and late staining due to RPE irregularity. Less frequently, there may be signs of vasculitic and cystic macular edema. In fundus autofluorescence imaging, confluent punctate appearance or granular hyper- and hypoautofluorescence pattern is a characteristic finding of lymphoma. On SD-OCT, nodular hyperreflective lesions at the RPE level and sub-RPE lesions between the RPE and Bruch's membrane can be observed in the early stage of the disease. In the later stages of the disease, "wave-like" turbulence may occur between the RPE and Bruch's membrane.<sup>23</sup> On ICGA imaging, lymphoma infiltration is less useful in diagnosis due to its intraretinal and/or subretinal location and generally appears as round clusters of hypofluorescent lesions.<sup>17,22</sup> On en face OCT angiography imaging, subretinal nodular infiltrates appear in a granular hyper- and hyporeflective pattern while large lesions are hyporeflective.<sup>24</sup> FA and ICGA findings have a

positive predictive value of 89% and negative predictive value of 85% for intraocular lymphoma.<sup>22</sup> In our three cases, multimodal imaging findings strongly suggested intraocular lymphoma. However, under the current conditions, in our country as well as in other countries, systemic lymphoma treatment cannot be initiated without histopathological confirmation of the diagnosis. The diagnosis and treatment of intraocular lymphoma requires a multidisciplinary team. In the treatment of intraocular lymphoma, a professional team of ophthalmologists and oncologists (especially specialists in neuro-oncology or hematology) is necessary to optimize patient management.

In cases of suspected intraocular lymphoma, methods to employ in etiological studies include cranial imaging methods, lumbar puncture, cytological examination of cerebrospinal fluid, and if these are inconclusive, vitreous biopsy and chorioretinal biopsy.<sup>1,2,3,4,5,6,7,8</sup> A study from the National Eye Institute found that an average of 2.1 procedures (pars plana vitrectomy, vitreous fluid sampling, anterior chamber fluid sampling, chorioretinal biopsy, brain biopsy, and cerebral aneurysm fluid sampling) were used to diagnose vitreoretinal lymphoma.<sup>25</sup> It was reported that ocular cytokine analysis of the vitreous fluid in patients with intraocular lymphoma shows higher levels of interleukin (IL)-10 than IL-6 (IL-10 to IL-6 ratio >1.0).<sup>26</sup> This molecular test is useful in the differential diagnosis of inflammatory conditions. However, as this method is not routinely used in every center in our country, diagnosis is more challenging than in developed countries. The demonstration of malignant lymphocytes in vitreous samples is the most definitive method for the diagnosis of intraocular lymphoma. The positive predictive diagnostic value of cytologic examination of a vitreous sample varies between 30% and 50%.<sup>27</sup> In the literature, it is emphasized that rapid cytotoxicity of tumor cells in the vitreous may make diagnosis difficult and repeated diagnostic vitrectomies may be required. Diagnostic vitrectomy should be done using a 25-gauge (G) system at a low cutting speed (up to 1,500 cuts per minute) to minimize destruction of infiltrative cells and 0.5-1 mL of undiluted vitreous should be obtained before turning on the infusion fluid. If diagnostic vitrectomy is planned for a patient using systemic steroids, they should be discontinued at least 2 weeks in advance if possible.<sup>26</sup> In cases where vitreous sampling is inadequate for diagnosis, retinal biopsy is an invasive method that provides more viable tumor cells. Of our cases, retinal biopsy was performed in patient 1 shortly after obtaining a cytologically negative vitreous sample and the diagnosis of intraocular lymphoma was confirmed by detecting malignant lymphocyte cells in the biopsy specimen. In patient 2, diagnosis was delayed by negative results from two separate cytology samples obtained from the vitreous. In contrast, when patient 3 developed visual complaints with a history of cardiac lymphoma, secondary intraocular lymphoma was presumed based on ophthalmological examination and multimodal imaging, and the diagnosis was confirmed by brain biopsy of a lesion detected on brain MRI at another center.

Table 1. Cases of intraocular lymphoma reported in Turkey								
Author (year, reference no)	Gender, age	Affected eye	Initial site of involvement	Uveitis masquerade syndrome	Vitreous biopsy	Definitive diagnosis	Time from presentation to definitive diagnosis	Prognosis
Ateş et al. <sup>14</sup>								
Case 1	F, 22	Bilateral	Systemic	-	-	Abdominal biopsy	<1 month	Under follow-up
Uysal et al. <sup>15</sup>								
Case 1		Right	Intraocular	+	+	Chorioretinal biopsy	<1 month	Under follow-up
Sürenkök et al. <sup>16</sup>								
Case 1	F, 68	Right	Intraocular	-	+	Retinal biopsy	2 months	Death
Saatci et al. <sup>17</sup>								
Case 1	M, 35	Bilateral	Systemic	-	-	Axillary lymph node biopsy	<1 month	Under follow-up
Tugal-Tutkun et al. <sup>18</sup>								
Case 1	F, 60	Bilateral	Intraocular	-	+	Vitreous biopsy	1.5 months	Under follow-up
Case 2	M, 32	Right	CNS	-	-	Brain biopsy	-	Under follow-up
Case 3	M, 38	Bilateral	CNS	+	-	Brain biopsy	<1 month	Undergoing treatment
Yüksel et al. <sup>19</sup>								
Case 1	F, 60	Bilateral	Intraocular	+	-	?	-	Death
Case 2	M, 58	Bilateral	Intraocular	+	+(twice)	Brain biopsy	3-4 months	Undergoing treatment
Demir et al. <sup>20</sup>								
Case 1	M, 75	Bilateral	Intraocular	+	+	Brain biopsy	?	Under follow-up
Present study (2021)								
Case 1	F, 71	Bilateral	Intraocular	-	+	Retinal biopsy	2 months	Death
Case 2	F, 70	Bilateral	Intraocular	-	+(twice)	Conjunctival biopsy	10 months	Death
Case 3	M, 72	Bilateral	Systemic	-	-	Brain biopsy	3 months	Undergoing treatment
F: Female, M: Male, CNS: Central nervous system								

In conclusion, the differential diagnosis of intraocular lymphoma is challenging. The first step toward early diagnosis is clinical suspicion. If suspected, characteristic findings that support the diagnosis can be detected with multimodal imaging methods. As ocular involvement may be the first clinical presentation, cranial imaging should also be performed due to possible CNS involvement. In patients with suspected intraocular lymphoma, vitreous biopsy and in some cases retinal biopsy is necessary for a definitive diagnosis and subsequent oncological treatment.

#### Ethics

**Informed Consent:** Obtained.

**Peer-review:** Externally and internally peer reviewed.

#### Authorship Contributions

Surgical and Medical Practices: M.K., F.H.Ö., A.O.S, Concept: M.K., A.O.S, Design: M.K., A.O.S, Data Collection or Processing: M.K., Analysis or Interpretation: M.K., F.H.Ö., B.L., S.Ö., S.M.,

A.O.S., Literature Search: M.K., A.O.S, Writing: M.K., B.L., S.M., A.O.S.

**Conflict of Interest:** No conflict of interest was declared by the authors.

**Financial Disclosure:** The authors declared that this study received no financial support.

#### References

1. Buggage RR, Chan CC, Nussenblatt RB. Ocular manifestations of central nervous system lymphoma. *Curr Opin Oncol.* 2001;13:137-142.
2. Fredrick DR, Char DH, Ljung BM, Brinton DA. Solitary intraocular lymphoma as an initial presentation of widespread disease. *Arch Ophthalmol.* 1989;107:395-397.
3. Chan CC, Rubenstein JL, Coupland SE, Davis JL, Harbour JW, Johnston PB, Cassoux N, Touitou V, Smith JR, Batchelor TT, Pulido JS. Primary vitreoretinal lymphoma: a report from an international primary central nervous system lymphoma collaborative group symposium. *Oncologist.* 2011;16:1589-1599.

4. Reichstein D. Primary vitreoretinal lymphoma: an update on pathogenesis, diagnosis and treatment. *Curr Opin Ophthalmol.* 2016;27:177-184.
5. Reddy EK, Bhatia P, Evans RG. Primary orbital lymphomas. *Int J Radiat Oncol Biol Phys.* 1988;15:1239-1241.
6. Mochizuki M, Singh AD. Epidemiology and clinical features of intraocular lymphoma. *Ocul Immunol Inflamm.* 2009;17:69-72.
7. Tang LJ, Gu CL, Zhang P. Intraocular Lymphoma. *Int J Ophthalmol.* 2017;10:1301-1307.
8. Freeman LN, Schachar AP, Knox DL, Michels RG, Green WR. Clinical features, laboratory investigations, and survival in ocular reticulum cell sarcoma. *Ophthalmology.* 1987;94:1631-1639.
9. Pe'er J, Hochberg FH, Foster CS. Clinical review: treatment of vitreoretinal lymphoma. *Ocul Immunol Inflamm.* 2009;17:299-306.
10. Dalvin LA, Lim LS, Ancona-Lezama D, Mazloumi M, Chang M, Porcu P, Martinez NL, Glass J, Mashayekhi A, Shields CL. Clinical Features Predictive of Survival in Patients With Vitreoretinal Lymphoma: Analysis of 70 Patients at a Single Ocular Oncology Center. *Asia Pac J Ophthalmol (Phila).* 2020;9:110-116.
11. Chan CC, Rubenstein JL, Coupland SE, Davis JL, Harbour JW, Johnston PB, Cassoux N, Touitou V, Smith JR, Batchelor TT, Pulido JS. Primary vitreoretinal lymphoma: a report from an International Primary Central Nervous System Lymphoma Collaborative Group symposium. *Oncologist.* 2011;16:1589-1599.
12. Chan CC, Wallace DJ. Intraocular lymphoma: update on diagnosis and management. *Cancer Control.* 2004;11:285-295.
13. Davis JL, Miller DM, Ruiz P. Diagnostic testing of vitrectomy specimens. *Am J Ophthalmol.* 2005;140:822-829.
14. Ateş Y, Yakarcan M, Oktay F, Kaynak S, Payzın B. Oküler Tutulumlu Bir Non-Hodgkin Lenfoma Olgusu. *Ret-Vit.* 2001;9:64-69.
15. Uysal Y, Sobacı G, Sefalı M, Bayraktar MZ. Koryoretinal Biyopsi ile Tanı Konan Primer İntraoküler Lenfoma. *Ret-Vit (Özel Sayı).* 2003;11:1-7.
16. Sürenkök S, Oysul K, Beyzadeoğlu M, Özet A. İntraoküler yerleşimli Non-Hodgkin lenfoma, bir olgu raporu ve literatürün gözden geçirilmesi. *Türk Onkoloji Dergisi.* 2009;24:48-52.
17. Saatci AO, Arikan G, Ozcan MA, Ozkal S, Kargı A, Undar B. Indocyanine green angiographic features of systemic non-Hodgkin's lymphoma and bilateral choroidal involvement. *Ophthalmic Surg Lasers Imaging.* 2006;37:236-239.
18. Tugal Turkun İ, Yıldırım Ö, Kır N. Santral Sinir Sistemi Tutulumu ile Birlikte Primer İntraoküler Lenfoma. *Turk J Ophthalmol.* 2008;38:242-249.
19. Yüksel E, Özdek Ş, Yüksel N, Korkmaz Ş, Hasanreisöğlü H. Panüveitli Multifokal Koroiditi Taklit Eden İntraoküler Lenfoma. *Turk J Ophthalmol.* 2010;40:46-50.
20. Demir MN, Sungur G, Gürelik İG, Özkan G, Bitik B, Ünlü N, Acar MA. İmmünespresif tedavi Sonrası İntraoküler Tüberküloz ve Lenfoma. *Ret-Vit.* 2017;26:169-174.
21. Cassoux N, Merle-Béral H, Leblond V, Bodaghi B, Miléa D, Gerber S, Fardeau C, Reux I, Xuan KH, Chan CC, LeHoang P. Ocular and central nervous system lymphoma: clinical features and diagnosis. *Ocul Immunol İnşamm.* 2000;8:243-250.
22. Fardeau C, Lee CP, Merle-Béral H, Cassoux N, Bodaghi B, Davi E, Lehoang P. Retinal şuorescein, indocyanine green angiography, and optic coherence tomography in non-Hodgkin primary intraocular lymphoma. *Am J Ophthalmol.* 2009;147:886-894.
23. Shields CL, Arepalli S, Pellegrini M, Mashayekhi A, Shields JA. Choroidal lymphoma shows calm, rippled, or undulating topography on enhanced depth imaging optical coherence tomography in 14 eyes. *Retina.* 2014;34:1347-1353.
24. Toledo JJ, Asencio M, García JR, Morales LA, Tomkinson C, Cajigal C. OCT Angiography: Imaging of Choroidal and Retinal Tumors. *Ophthalmol Retina.* 2018;2:613-622.
25. Dalal M, Casady M, Moriarty E, Faia L, Nussenblatt R, Chan CC, Sen HN. Diagnostic procedures in vitreoretinal lymphoma. *Ocul Immunol Inflamm.* 2014;22:270-276.
26. Sugita S, Takase H, Sugamoto Y, Arai A, Miura O, Mochizuki M. Diagnosis of intraocular lymphoma by polymerase chain reaction analysis and cytokine profiling of the vitreous fluid. *Jpn J Ophthalmol.* 2009;53:209-214.
27. Davis JL, Miller DM, Ruiz P. Diagnostic testing of vitrectomy specimens. *Am J Ophthalmol.* 2005;140:822-829.



# Serpiginous Choroiditis Complicated with Choroidal Neovascular Membrane Detected using Optical Coherence Tomography Angiography: A Case Series and Literature Review

Asli Perente, Dimitra Kotsiliti, Sergios Taliantzis, Eirini Kanella Panagiotopoulou, Maria Gkika, Irfan Perente, Doukas Dardabounis, Georgios Labiris

University Hospital of Alexandroupolis, Department of Ophthalmology, Alexandroupoli, Greece

## Abstract

Serpiginous choroiditis (SC) is a rare, chronic, recurrent, progressive disease of unknown origin. The inflammatory process of SC can disrupt Bruch's membrane, allowing occasional choroidal vascular growth, leading to significant visual loss even in the healed stages of the disease. Optical coherence tomography angiography (OCTA) can help in the detection of choroidal neovascular membrane (CNV), leading to a definitive diagnosis and thereby guide the initiation of intravitreal anti-vascular endothelial growth factor (anti-VEGF) treatment. We report herein two cases of SC complicated with a CNV detected with OCTA and treated with a series of anti-VEGF injections.

**Keywords:** Serpiginous choroiditis, neovascular membrane, optical coherence tomography angiography, anti-VEGF

## Introduction

Serpiginous choroiditis (SC), is a rare clinical entity characterized by irreversible damage primarily to the choriocapillaries and secondarily to the retinal pigment epithelium, the rest of the choroid, and the outer retina.<sup>1,2</sup> Lesions typically appear in the peripapillary area, but may extend to the macula as well.<sup>2</sup> The most common complication of SC is the development of choroidal neovascular membrane (CNV), which occurs in 10-35% of all cases.<sup>3,4</sup>

Optical coherence tomography angiography (OCTA) is a novel non-invasive imaging modality that detects flow changes in the choroid, enabling stratified vascular analyses. Compared to fluorescein angiography (FA), OCTA provides high-resolution digital images of the different vascular layers, including the choriocapillaries and choroidal vessels. As a result, OCTA contributes significantly to the identification and monitoring

of chorioretinopathies and their related complications such as CNV.<sup>5,6,7,8,9,10</sup>

Within this context, we would like to present two cases of SC complicated with CNV, confirmed with OCTA, and treated with ranibizumab (Lucentis, Novartis, Greece).

## Case Reports

### Case 1

A 60-year-old woman was referred to the outpatient service of our department due to reduced visual acuity in her left eye. Her systemic history included systemic hypertension, dyslipidemia, and type 2 diabetes mellitus. A full ophthalmological examination was performed. Her best-corrected visual acuity (BCVA) was 20/25 and 20/40 in her right (OD) and left eye (OS), respectively. On dilated funduscopy, no signs of diabetic retinopathy could be observed; however, the presence of peripapillary scarring in both eyes was detected (Figure 1A,

**Address for Correspondence:** Asli Perente, University Hospital of Alexandroupolis, Department of Ophthalmology, Alexandroupoli, Greece

E-mail: asli\_perende-90@hotmail.com **ORCID-ID:** orcid.org/0000-0002-7638-4739

**Received:** 27.12.2020 **Accepted:** 17.08.2021

**Cite this article as:** Perente A, Kotsiliti D, Taliantzis S, Panagiotopoulou EK, Gkika M, Perente I, Dardabounis D, Labiris G. Serpiginous Choroiditis Complicated with Choroidal Neovascular Membrane Detected using Optical Coherence Tomography Angiography: A Case Series and Literature Review.

Turk J Ophthalmol 2021;51:326-333

©Copyright 2021 by Turkish Ophthalmological Association

Turkish Journal of Ophthalmology, published by Galenos Publishing House.

B). OCT demonstrated macular pseudohole in OD and stage 2 macular hole in OS (Figure 2A, B). FA was performed and the diagnosis of SC was established (Figure 3A, B). The patient underwent a full systematic check-up, including Quantiferon Tb Gold test, which resulted negative. As there were no signs of active inflammation, no treatment was suggested at that time. Twenty-three months after initial presentation, the patient urgently visited our department due to bilateral blurred vision. Her BCVA had decreased to 20/50 and 20/200 in OD and OS, respectively. In OD a small subretinal hemorrhage with edema at the edge of the scar adjacent to the macula could be visualized. OCT showed the presence of hyperreflective lesion with intraretinal fluid (IRF) in the macular area of OD, while the macular hole in OS progressed to stage 4 (Figure 4A, B). OCTA revealed a CNV in the area corresponding to the hyperreflective lesion detected by OCT in the OD. To address the worsening clinical picture in OD, the patient was administered intravitreal ranibizumab. After three injections at 2-month intervals, BCVA improved to 20/25 with OCTA showing complete regression of the neovascular membrane (Figure 5). During the follow-up period of 16 months, the patient's BCVA remained stable and no further intravitreal injection was required.

#### Case 2

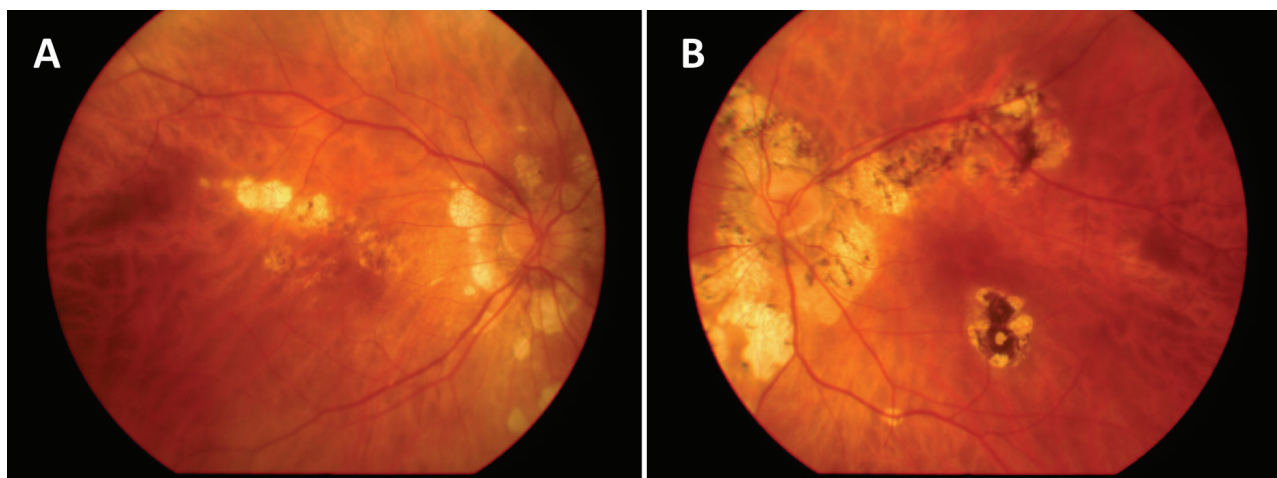
A 55-year-old woman first presented to our outpatient service in March 2010 due to blurred vision in OS. Her systemic and ophthalmic history was uneventful. On presentation, BCVA was 20/20 in OD and counting fingers with positive Amsler test in OS. Dilated fundus examination revealed retinal edema and hemorrhage within the macular region in OS, while OD was normal (Figure 6). OCT detected the presence of subretinal fluid (SRF) under the fovea in OS (Figure 7). Subsequently, FA was performed and a neovascular membrane into the macular area was detected (Figure 8). Since there were no signs of any underlying disease at that time, the CNV was characterized as idiopathic and the patient was treated with 5 injections of intravitreal ranibizumab during the time period of 10 months. Her BCVA improved to 20/200 in OS, while the OCT showed

complete regression of the SRF (Figure 9). In July 2012, her follow-up examination revealed the presence of peripapillary chorioretinal atrophy in OD (Figure 10A) and chorioretinal atrophy extending from the optic disc to the macula and the periphery in OS (Figure 10B), therefore the patient was diagnosed with SC. She underwent a full systemic check-up, including Quantiferon Tb Gold test, which resulted negative, and a regular follow-up program was suggested. Oral methotrexate (10 mg per week) was attempted; however, it was discontinued due to elevation of liver enzymes. As an alternative, short courses of oral methylprednisolone (Medrol, Pfizer, Greece) 16 mg per day was administered. Methylprednisolone contributed to the improvement of the SC-related retinal clinical picture of her OS which remained steady for a follow-up period of 6 years.

In June 2018, the patient visited our outpatient service again due to blurred vision in OD. Dilated funduscopy and OCT imaging indicated no change in OS, however, BCVA in OD dropped to 20/50 with IRF and SRF (Figure 11). Due to deterioration of the clinical picture in OD, a course of oral methylprednisolone (32 mg per day) was administered, but there was no favorable response in BCVA or the clinical picture. Further increase in methylprednisolone was ruled out due to the patient's development of Cushing-like systemic symptomatology. OCTA demonstrated a fine anastomotic network of vessels, suggestive of type 2 CNV secondary to SC. We concluded that the deterioration of the clinical picture was due to the CNV that was misdiagnosed as recurrence of the disease. Subsequently, the patient received three intravitreal injections of ranibizumab. Her BCVA stabilized at 20/25 with complete regression of both macular edema and CNV (Figure 12).

#### Discussion

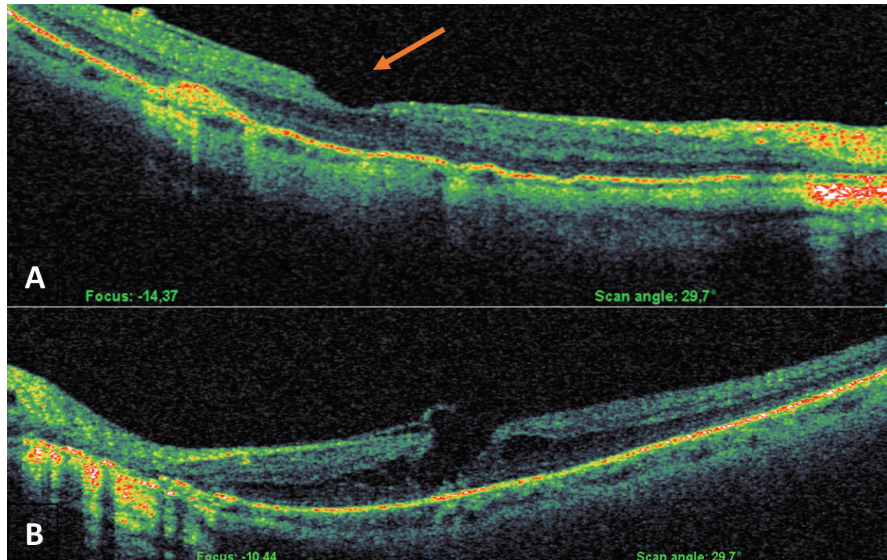
SC, first described by Hutchinson<sup>3</sup> in 1900, is a rare, vision-threatening disease with a prevalence of between 0.2% and 5% of all uveitis cases. It affects individuals from 30 to 70 years old and presents with painless, blurred vision, metamorphopsias, and paracentral scotomas.<sup>4,11</sup> Initially it is unilateral, with



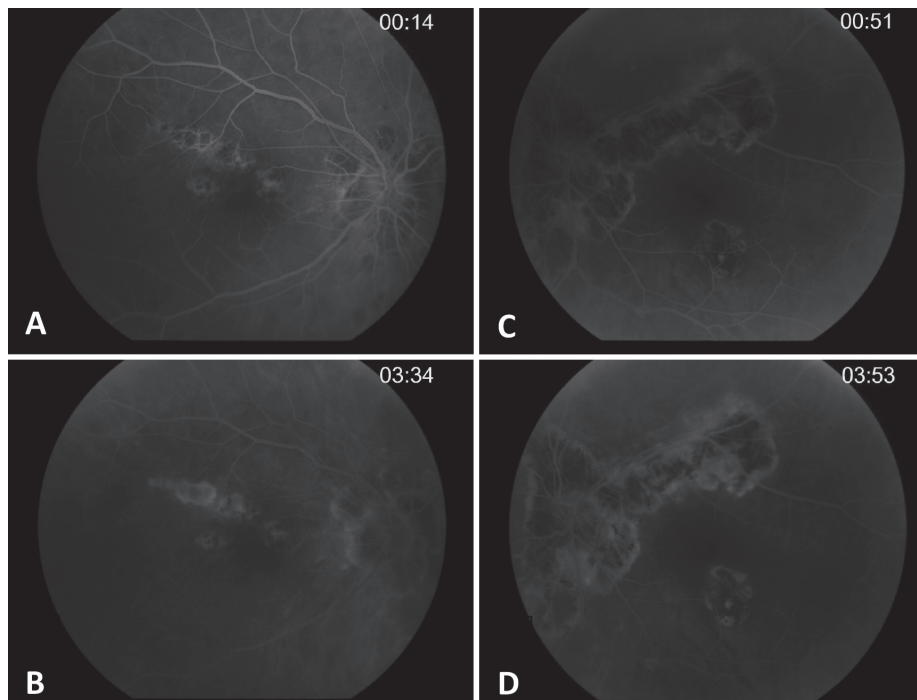
**Figure 1.** Color fundus photographs of patient 1 showing the typical peripapillary scarring with satellite lesions in the right eye (A) and left eye (B)

the majority of cases demonstrating fellow eye involvement within 5 years. Confirmed unilateral cases are most commonly reported from tuberculosis-endemic countries.<sup>11</sup> Dilated fundus examination reveals asymmetric bilateral grayish-yellow lesions and mild inflammation of the vitreous body.<sup>4</sup> Recurrences, usually symptomatic, occur at the edges of the scars.<sup>11</sup> Interestingly, the interval between recurrences varies from weeks to years.<sup>4</sup> When no macular scarring exists, significant improvement of visual acuity is expected, similar to patient 1

and OD of patient 2 in our report. When CNV progresses to macular scarring, the visual outcome is less fortunate (patient 2, OS). The literature suggests that inflammation is the primary cause of CNV following age-related macular degeneration and myopia. Both infectious and non-infectious pathomechanisms can lead to the development of CNV. Although the overall incidence of CNV in non-infectious uveitides is only 2%, its prevalence is significantly higher in multifocal choroiditis, punctate inner choroiditis, and SC, which present with

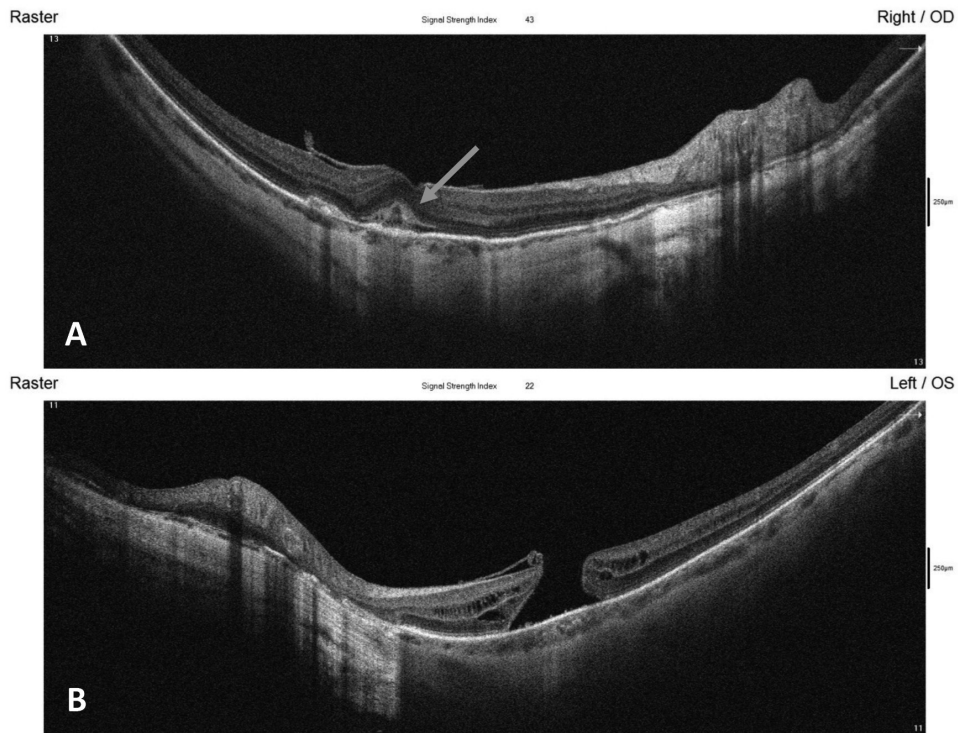


**Figure 2.** Optical coherence tomography images of patient 1 showing macular pseudohole in the right eye (A, red arrow) and stage 2 macular hole in the left eye (B)

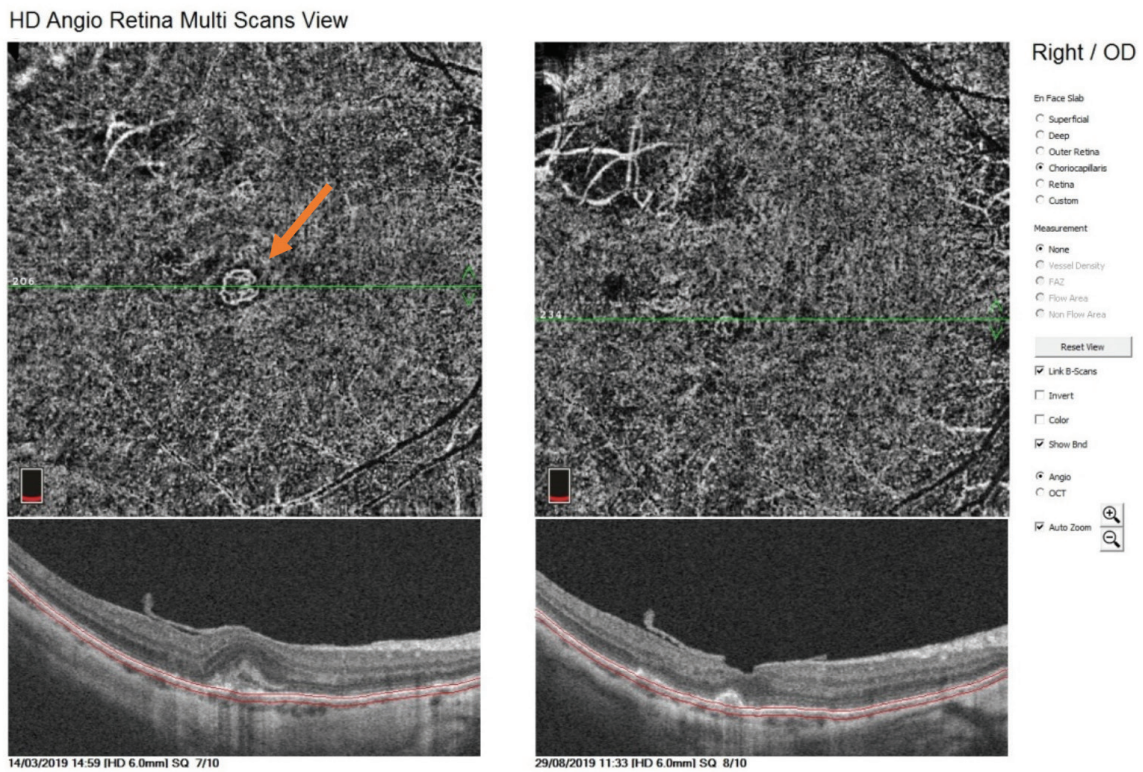


**Figure 3.** Fluorescein angiography images of patient 1 showing early hypofluorescence and late hyperfluorescence of the peripapillary and satellite lesions in the right eye (A, B) and at the lesion margins in the left eye (C, D)

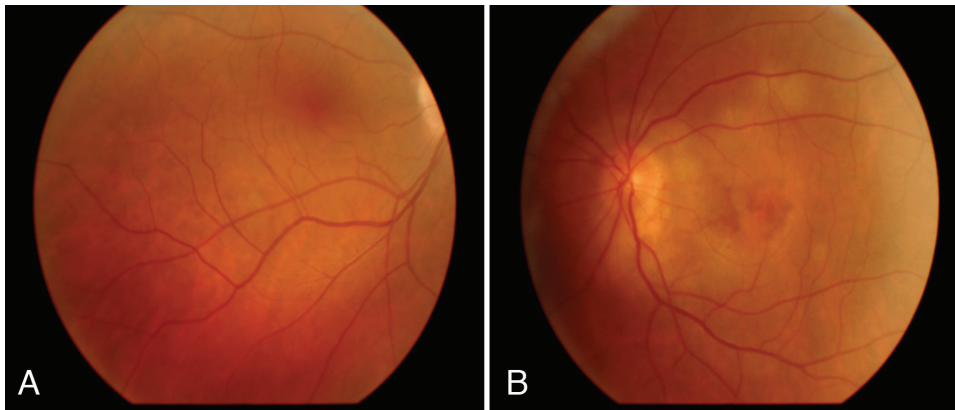




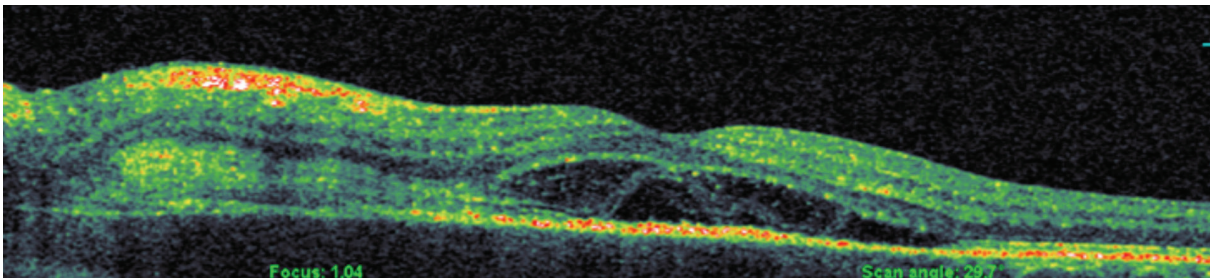
**Figure 4.** Optical coherence tomography images of patient 1 showing a subfoveal hyperreflective lesion and intraretinal fluid in the right eye (A, arrow) and a stage 4 macular hole in the left eye (B)



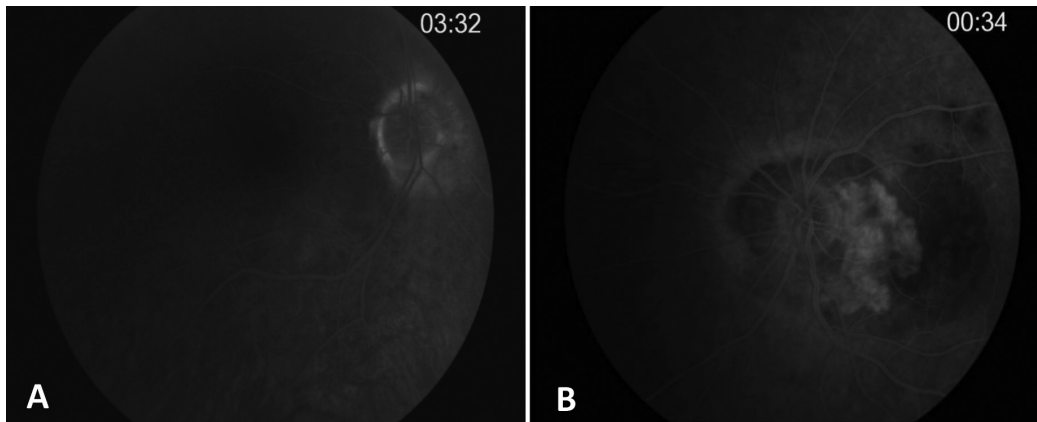
**Figure 5.** Optical coherence tomography angiography image of the right eye of patient 1 showing a fine anastomotic network of vessels indicative of type 2 choroidal neovascular membrane (left, red arrow) and the same eye after three intravitreal injections of ranibizumab (right)



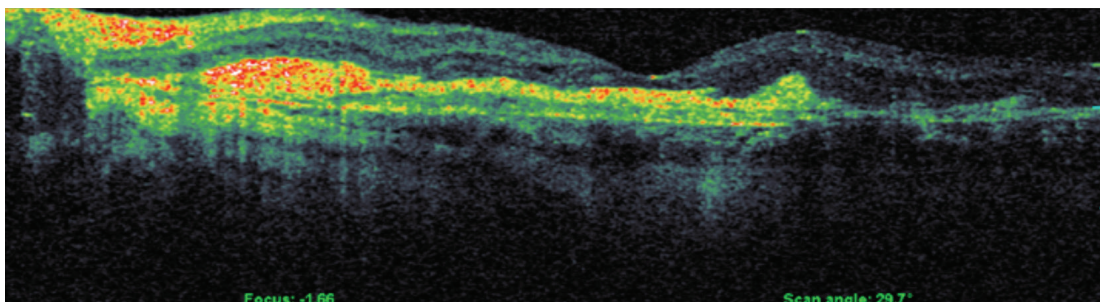
**Figure 6.** Color fundus photographs of patient 2. The right eye looks normal (A), while the left eye presents retinal edema and hemorrhage within the macular area (B)



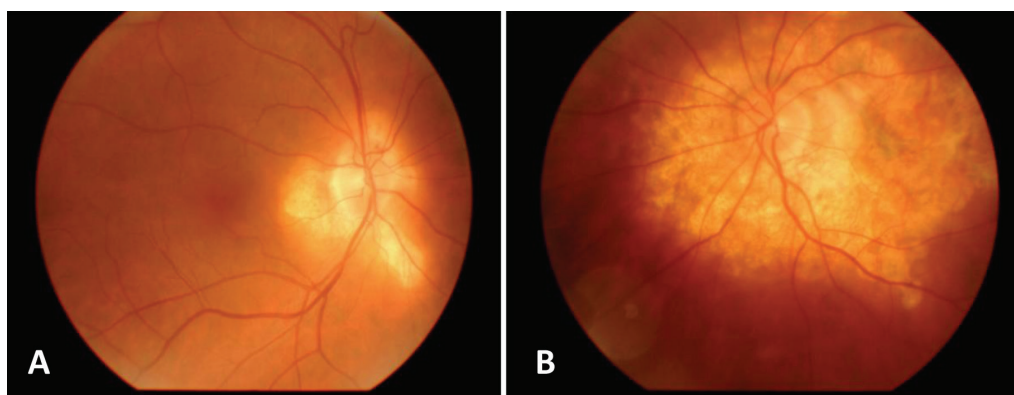**Figure 7.** Optical coherence tomography of the left eye of patient 2 showing subretinal fluid under the fovea



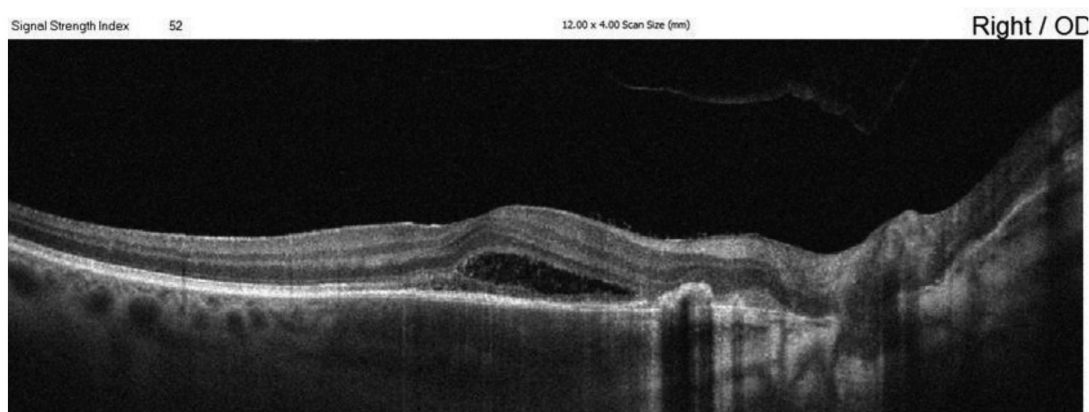
**Figure 8.** Fluorescein angiography in patient 2. No abnormal findings were observed in the right eye (A), while in the left eye a classic choroidal neovascular membrane with leakage into the macular area was detected (B)



**Figure 9.** Optical coherence tomography of the left eye of patient 2 after five intravitreal injections of ranibizumab. Complete regression of the subretinal fluid was observed



**Figure 10.** Color fundus photographs of patient 2 two years after initial presentation showing the peripapillary chorioretinal atrophy typical of SC in the right eye (A) and left eye (B)



**Figure 11.** Optical coherence tomography of the right eye of patient 2 eight years after initial presentation shows the presence of subretinal and intraretinal fluid

choroidal neovascularization in 32-46%, 17-40%, and 10-25% of all cases, respectively.<sup>12,13</sup> Especially in SC, CNV constitutes the most common complication. It typically originates from the border of the choroidal lesions inducing ischemia in the outer retina and inner choroidal layers.<sup>14</sup> Taking into account that SC affects patients at their productive age, prompt diagnosis and treatment of SC-related CNV is of paramount importance to preserve visual capacity.<sup>7</sup>

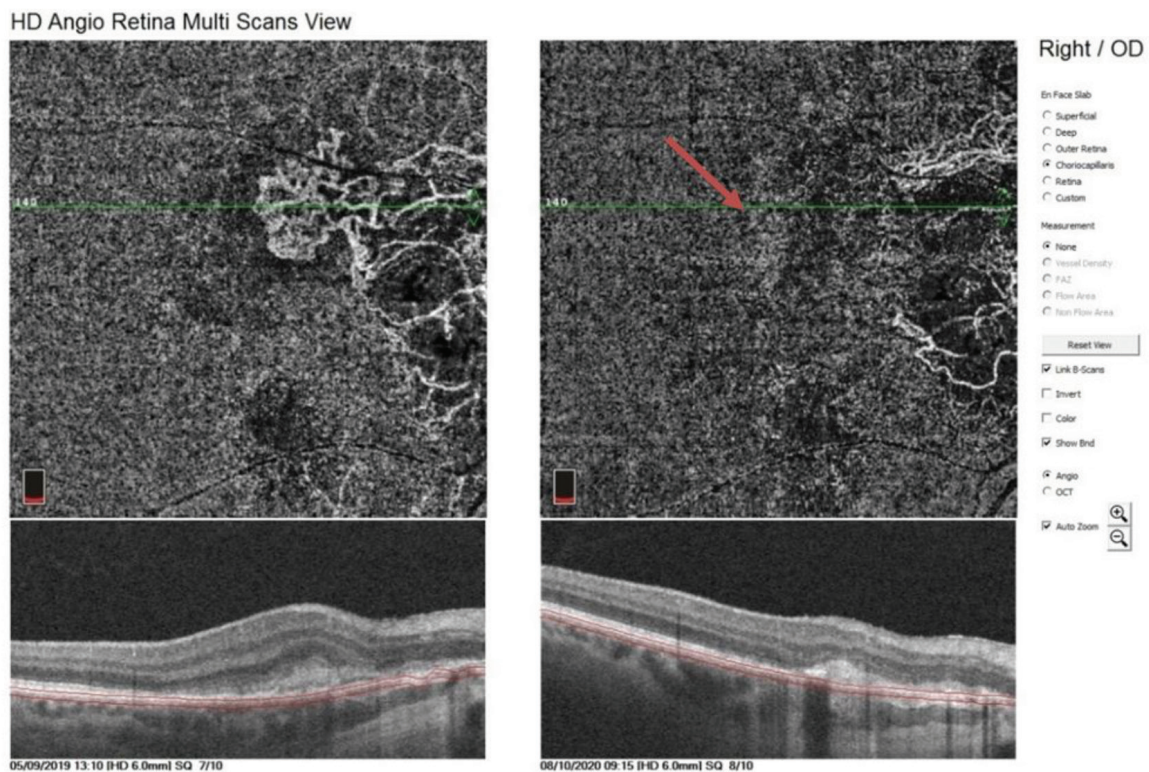
It is known that among the prevalent theories regarding the pathogenesis of CNV is inflammatory-induced angiogenesis mediated by vascular endothelial growth factor (VEGF).<sup>6,12,15</sup> It is no surprise then, that the anti-VEGF medications exert a beneficial impact on CNV. Furthermore, damage to the RPE and Bruch's membrane complex caused by chronic inflammation enables these new capillaries to pass from the choroid to the sub-RPE and subretinal space.<sup>7,12,13</sup> It should be mentioned that in patient 2, CNV in OD manifested prior to the characteristic clinical lesions of SC. To our knowledge, this is the first report of this peculiar incidence.

Contemporary imaging technologies contribute significantly to the diagnosis of SC and its related manifestations. OCTA is a non-invasive imaging modality that facilitates the diagnosis and

management of retinal and choroidal diseases.<sup>3,18</sup> Recently, El Ameen and Herbert<sup>9</sup> reported a case of SC diagnosed by OCTA and concluded that OCTA could even substitute for indocyanine green angiography.

OCTA seems to be useful in the diagnosis of SC-related complications as well, since its associated lesions present diagnostic difficulties with FA.<sup>7</sup> OCTA has excellent reproducibility, is non-invasive, and is easily performed in few minutes.<sup>14</sup> Although the use of OCTA in the diagnosis of type 1 CNV in age-related macular degeneration has been widely studied, published reports referring to the detection of the same complication in uveitis are limited.<sup>7</sup>

Campos Polo et al.<sup>6</sup> used OCTA for the detection of CNV and its response to anti-VEGF injections in SC. Aggarwal et al.<sup>10</sup> reported that OCTA is a helpful diagnostic tool for the detection of type 1 CNV in patients with tuberculous serpiginous-like choroiditis TB-SLC when conventional multimodal imaging methods fail to assist in the diagnosis. Astroz et al.<sup>16</sup> indicated the diagnostic superiority of OCTA over FA in the detection of inflammatory CNV. Furthermore, Karti and Saatci<sup>13</sup> reported that OCTA is useful not only in the differentiation of CNV from active inflammatory lesions, but



**Figure 12.** Optical coherence tomography angiography of the right eye of patient 2 before (left) and after (right) three intravitreal injections of ranibizumab. Thirteen months later, complete regression of choroidal neovascularization (red arrow) was observed

it is also able to picture the characteristic lesions of white dot syndromes.

Until recently, the treatment options for SC-related CNV were photocoagulation, photodynamic therapy, and surgical excision.<sup>15</sup> However, today intravitreal anti-VEGF injections are considered to be the first line of treatment.<sup>7</sup> In our reported cases, we used ranibizumab, which contributed to BCVA improvement and regression of the inflammatory CNV. Our outcomes suggest that this therapeutic intervention is promising. Further cohorts of patients with SC are needed in order to draw safer conclusions in this direction.

#### Ethics

**Informed Consent:** Obtained.

**Peer-review:** Externally and internally peer reviewed.

#### Authorship Contributions

Surgical and Medical Practices: D.D., Concept: A.P., S.T., M.G., Design: A.P., S.T., M.G., G.L., Data Collection or Processing: A.P., D.K., E-K.P., Analysis or Interpretation: D.D., I.P., G.L., Literature Search: A.P., E-K.P., Writing: A.P., D.K., G.L.

**Conflict of Interest:** No conflict of interest was declared by the authors.

**Financial Disclosure:** The authors declared that this study received no financial support.

## References

- Borrego-Sanz L, Gómez-Gómez A, Gurrea-Almeida M, Esteban-Ortega M, Pato E, Díaz-Valle D, Díaz-Valle T, Muñoz-Fernández S, Rodríguez-Rodríguez L; Madrid Uveitis Study Group. Visual acuity loss and development of ocular complications in white dot syndromes: a longitudinal analysis of 3 centers. *Graefes Arch Clin Exp Ophthalmol.* 2019;257:2505-2516.
- Neri P, Lettieri M, Fortuna C, Manoni M, Giovannini A. Inflammatory choroidal neovascularization. *Middle East Afr J Ophthalmol.* 2009;16:245-251.
- Majumder PD, Biswas J, Gupta A. Enigma of serpiginous choroiditis. *Indian J Ophthalmol.* 2019;67:325-333.
- Parodia MB, Iaconob P, Verbraack FD, Bandello F. *Antivascular Endothelial Growth Factors for Inflammatory Chorioretinal Disorders.* Ophthalmol. Basel, Karger; 2010:84-95.
- Pakzad-Vaezi K, Khaksari K, Chu Z, Van Gelder RN, Wang RK, Pepple KL. Swept-Source OCT Angiography of Serpiginous Choroiditis. *Ophthalmol Retina.* 2018;2:712-719.
- Campos Polo R, Rubio Sánchez C, Sánchez Trancón A. Choroidal neovascularisation secondary to serpiginous choroiditis: The value of OCT-angiography in diagnosis and response to therapy with aflibercept. *Arch Soc Esp Oftalmol.* 2019;94:460-464.
- Agarwal A, Invernizzi A, Singh RB, Foulsham W, Aggarwal K, Handa S, Agrawal R, Pavesio C, Gupta V. An update on inflammatory choroidal neovascularization: epidemiology, multimodal imaging, and management. *J Ophthalmic Inflamm Infect.* 2018;8:13.
- Montorio D, Giuffrè C, Miserocchi E, Modorati G, Sacconi R, Mercuri S, Querques L, Querques G, Bandello F. Swept-source optical coherence tomography angiography in serpiginous choroiditis. *Br J Ophthalmol.* 2018;102:991-995.

9. El Ameen A, Herbort CP Jr. Serpiginous choroiditis imaged by optical coherence tomography angiography. *Retin Cases Brief Rep.* 2018;12:279-285.
10. Aggarwal K, Agarwal A, Sharma A, Sharma K, Gupta V; OCTA Study Group. Detection of type 1 choroidal neovascular membranes using optical coherence tomography angiography in tubercular posterior uveitis. *Retina* 2019;39:1595-1606.
11. Nazari Khanamiri H, Rao NA. Serpiginous choroiditis and infectious multifocal serpiginoid choroiditis. *Surv Ophthalmol.* 2013;58:203-232.
12. Karti O, Ipek SC, Ates Y, Saatci AO. Inflammatory Choroidal Neovascular Membranes in Patients With Noninfectious Uveitis: The Place of Intravitreal Anti-VEGF Therapy. *Med Hypothesis Discov Innov Ophthalmol.* 2020;9:118-126.
13. Karti O, Saatci AO. Optical Coherence Tomography Angiography in Eyes with Non-infectious Posterior Uveitis; Some Practical Aspects. *Med Hypothesis Discov Innov Ophthalmol.* 2019;8:312-322.
14. Parodi MB, Iacono P, La Spina C, Knutsson KA, Mansour A, Arevalo JF, Bandello F. Intravitreal bevacizumab for choroidal neovascularisation in serpiginous choroiditis. *Br J Ophthalmol.* 2014;98:519-522.
15. Saatci AO, Ayhan Z, Engin Durmaz C, Takes O. Simultaneous Single Dexamethasone Implant and Ranibizumab Injection in a Case with Active Serpiginous Choroiditis and Choroidal Neovascular Membrane. *Case Rep Ophthalmol.* 2015;6:408-414.
16. Astroz P, Miere A, Mrejen S, Sekfali R, Souied EH, Jung C, Nghiem-Buffer S, Cohen SY. Optical Coherence Tomography Angiography to Distinguish Choroidal Neovascularization from Macular Inflammatory Lesions in Multifocal Choroiditis. *Retina.* 2018;38:299-309.



## Letter to the Editor Re: “The Relationship Between Keratoconus Stage and the Thickness of the Retinal Layers”

© Masoud Khorrami-nejad, © Mohsen Heirani

Translational Ophthalmology Research Center, Farabi Eye Hospital, Tehran University of Medical Sciences, Tehran, Iran

**Keywords:** Keratoconus, cornea, retina

Dear Editor,

We read with interest the recent study conducted by Özsaygılı et al.<sup>1</sup> regarding the relationship between the keratoconus (KC) stages and the thickness of the retinal layers. The authors concluded that patients with more advanced KC had a thicker inner nuclear layer (INL) and thinner retinal pigment epithelium (RPE) layer. They hypothesized different potential mechanisms for changing these two retinal layers in KC eyes. The main novelty of this work was the investigation of retinal layers of KC patients separately. We would like to congratulate the authors on their informative research. However, the conclusion of the study suffers from some shortcomings.

In the study by Özsaygılı et al.<sup>1</sup>, patients with myopia lower than -6.00 D were included. However, the authors attributed the significant changes in the INL and RPE to the different biochemical, oxidative, genetic, and cellular mechanisms in a KC eye. Nevertheless, in KC patients, the induced myopic refractive error might be a compelling factor producing compensatory changes in the retinal layers due to the resultant optical defocus. For example, Liu et al.<sup>2</sup> investigated the effect of myopic refractive error on the thickness of the retinal layers in the healthy population and concluded that various myopic refractions (from mild to high degrees) could significantly affect the profile of the retinal layers of normal subjects. The more

progression in myopia, the more changes in the profile of the retinal layers. Although Özsaygılı et al.<sup>1</sup> measured the refractive state of their patients with manifest refraction, they did not clearly state the range and mean values of the refractive errors of their study subjects. Furthermore, other influential factors on retinal thickness including diurnal variations, segmentation errors, gender, and body mass index were not considered as confounding factors.<sup>3</sup>

In addition to the mentioned likely causes for changes in the retinal layer profile in KC patients, there are two possible neurophysiological explanations. The first theory relates to the induced Stiles-Crawford phenomenon of the first type (SCE-type I) in KC corneas. In KC patients, a kind of multifocality occurs in the affected cornea that could contribute to the reduced luminous strength of incoming light on the retina in a way similar to light entering at the border of the pupil.<sup>4</sup> This phenomenon may stimulate SCE-type I and induce changes to the profile of the retinal layers. Another potential mechanism is a compensatory photostasis phenomenon in KC eyes. This effect is the long-term adaptation of the retinal photoreceptors (rod cells) to the changes in lighting conditions of the eye. KC eyes face sub-normal optical function and the light rays reaching the retina are dimmed. This effect causes some degree of prolonged image degradation and results in light deprivation. Subsequently, photostasis of the

**Address for Correspondence:** Mohsen Heirani, Translational Ophthalmology Research Center, Farabi Eye Hospital, Tehran University of Medical Sciences, Tehran, Iran  
E-mail: dr.heirani@hotmail.com **ORCID-ID:** orcid.org/0000-0002-8426-5924

**Received:** 09.06.2021 **Accepted:** 19.08.2021

**Cite this article as:** Khorrami-nejad M, Heirani M. Letter to the Editor Re: “The Relationship Between Keratoconus Stage and the Thickness of the Retinal Layers”. Turk J Ophthalmol 2021;51:334-335

©Copyright 2021 by Turkish Ophthalmological Association  
Turkish Journal of Ophthalmology, published by Galenos Publishing House.

photoreceptors acts as a compensatory mechanism and could result in photoreceptor elongation.<sup>5</sup>

According to the above explanations, the conclusion of the manuscript could not be restricted to the KC patients. In practice, the significant changes in the INL and RPE layers could be as a compensatory response to other associated factors including induced myopia secondary to the KC, not exclusively the KC disease itself.

**Peer-review:** Internally peer reviewed.

#### **Authorship Contributions**

Concept: M.H., Design: M.K-N., Data Collection or Processing: M.H., M.K-N., Analysis or Interpretation: M.K-N., Literature Search: M.H., Writing: M.H., M.K-N.

**Conflict of Interest:** No conflict of interest was declared by the authors.

**Financial Disclosure:** The authors declared that this study received no financial support.

#### **References**

1. Özsaygılı C, Yıldırım Y. The Relationship between Keratoconus Stage and the Thickness of the Retinal Layers. *Turk J Ophthalmol.* 2021;51:75-82.
2. Liu X, Shen M, Yuan Y, Huang S, Zhu D, Ma Q, Ye X, Lu F. Macular Thickness Profiles of Intraretinal Layers in Myopia Evaluated by Ultrahigh-Resolution Optical Coherence Tomography. *Am J Ophthalmol.* 2015;160:53-61.
3. Wong AC, Chan CW, Hui SP. Relationship of Gender, Body Mass Index, and Axial Length with Central Retinal Thickness Using Optical Coherence Tomography. *Eye.* 2005;19:292-297.
4. Piñero DP, Nieto JC, Lopez-Miguel A. Characterization of Corneal Structure in Keratoconus. *J Cataract Refract Surg.* 2012;38:2167-2183.
5. Bilen NB, Hepsen IF, Arce CG. Correlation between Visual Function and Refractive, Topographic, Pachymetric and Aberrometric Data in Eyes with Keratoconus. *Int J Ophthalmol.* 2016;9:1127-1133.



## Reply to Letter to the Editor re: “The Relationship Between Keratoconus Stage and the Thickness of the Retinal Layers”

© Cemal Özsaygılı, © Yener Yıldırım

Kayseri City Hospital, Clinic of Ophthalmology, Kayseri, Turkey

**Keywords:** Keratoconus, oxidative stress, optical coherence tomography, retinal layer thickness

Dear Editor,

We would like to thank the authors for their comments and evaluation of our study.<sup>1</sup> As mentioned in the study, patients with myopia above 6 diopters and axial length greater than 26 mm were excluded in order to prevent the potential confounding effect of the optical defocus that might be caused by high myopia and the stretching effect on retinal layers. Liu et al. found that there was a difference in the thickness of the retinal layers in the peripheral macular region of eyes with high myopia compared to the emmetropic control group.<sup>2</sup> However, high myopic eyes were not included in our study, and a central 1 mm macular area, not the peripheral macular region, was analyzed. As stated in our study, the groups had statistically similar demographic characteristics and axial length values. We would also like to emphasize again that the spectral domain optical coherence tomography (SD-OCT) imaging of the groups was performed by a single nurse at similar times of the day to avoid possible diurnal variation.

We welcome the authors' mention of the Stiles-Crawford phenomenon, which may have a long-term effect on the thickness of the retinal layers of patients with keratoconus (KC), and the photostasis adaptation of photoreceptors. However, we would like to point out that the Stiles-Crawford phenomenon is more related to the directional sensitivity of the retina and the proper alignment of the receptors. It has been

reported that high astigmatism may cause possible changes in peripapillary measurements due to elliptical distortion of the retinal image in different meridians,<sup>3</sup> but segmentation measurements obtained from the central macular region are quite reliable.<sup>4</sup>

We thank the authors for their possible neurophysiological explanations/contributions that may have an impact on retinal layer thicknesses in KC patients. We think that the changes we observed in the inner nuclear layer and retinal pigment epithelium layer are closely related to the stage of KC disease, since there is no evidence to go beyond the assumptions of additional neurophysiological explanations and the KC groups had similarly low myopic refractive errors.

### Authorship Contributions

Surgical and Medical Practices: C.Ö., Y.Y., Concept: C.Ö., Design: C.Ö., Data Collection or Processing: Y.Y., Analysis or Interpretation: Y.Y., Literature Search: C.Ö., Writing: C.Ö.

**Conflict of Interest:** No conflict of interest was declared by the authors.

**Financial Disclosure:** The authors declared that this study received no financial support.

### References

1. Özsaygılı C, Yıldırım Y. The Relationship between Keratoconus Stage and the Thickness of the Retinal Layers. Turk J Ophthalmol. 2021;51:75-82.

**Address for Correspondence:** Cemal Özsaygılı, Kayseri City Hospital, Clinic of Ophthalmology, Kayseri, Turkey

E-mail: cemalozsaygili@hotmail.com **ORCID-ID:** orcid.org/0000-0002-8236-1728

**Received:** 30.07.2021 **Accepted:** 19.08.2021

**Cite this article as:** Özsaygılı C, Yıldırım Y. Reply to Letter to the Editor re: “The Relationship Between Keratoconus Stage and the Thickness of the Retinal Layers”. Turk J Ophthalmol 2021;51:336-337

©Copyright 2021 by Turkish Ophthalmological Association  
Turkish Journal of Ophthalmology, published by Galenos Publishing House.



2. Liu X, Shen M, Yuan Y, Huang S, Zhu D, Ma Q, Ye X, Lu F. Macular Thickness Profiles of Intraretinal Layers in Myopia Evaluated by Ultrahigh-Resolution Optical Coherence Tomography. *Am J Ophthalmol.* 2015;160:53-61.
3. Hwang YH, Lee SM, Kim YY, Lee JY, Yoo C. Astigmatism and optical coherence tomography measurements. *Graefes Arch Clin Exp Ophthalmol.* 2012;250:247-254.
4. Oberwahrenbrock T, Weinhold M, Mikolajczak J, Zimmermann H, Paul F, Beckers I, Brandt AU. Reliability of Intra-Retinal Layer Thickness Estimates. *PLoS One.* 2015;10:e0137316.