



www.ofthalmoloji.org

ISSN 2149-8695

# TURKISH JOURNAL OF OPHTHALMOLOGY

**TJO**

## Original Articles

*Long-term Results in Pediatric Developmental Cataract Surgery with Primary Intraocular Lens Implantation*  
Elif Demirkılınc Biler et al; Izmir, Adiyaman, Turkey

*Visual Results Following Implantation of a Refractive Multifocal Intraocular Lens in One Eye and a Diffractive in the Contralateral Eye*  
Revan Yıldırım Karabağ et al; Manisa, Izmir, Istanbul, Denizli, Turkey

*Amniotic Membrane Transplantation in Surgical Treatment of Conjunctival Melanoma: Long-term Results*  
Melis Palamar et al; Izmir, Turkey

*The Profile and Management of Glaucoma in Adult Aphakic Patients Following Complicated Cataract Surgery*  
Ümit Ekşioğlu et al; Ankara, Istanbul, Turkey

*Characteristics of Anisometropic Patients with and without Strabismus*  
Reşat Duman et al; Afyonkarahisar, Ankara, Eskişehir, Turkey

*Direct Treatment Costs of Neovascular Age-related Macular Degeneration and Comparison of Gained and/or Preserved Vision with Expenditure*  
Şeyda Yıldırım et al; Izmir, Turkey

## Review

*Stem Cell Treatment in Retinal Diseases: Recent Developments*  
Ayşe Öner; Kayseri, Turkey

## Case Reports

*Primary Conjunctival Tuberculosis*  
Nilgün Solmaz et al; Istanbul, Turkey

*Orbital Apex Syndrome Secondary to Herpes Zoster Ophthalmicus*  
Gamze Kocaoğlu et al; Izmir, Turkey

*Goldmann-Favre Syndrome: Case Series*  
Serdar Özateş et al; Ankara, Kars, Turkey

*Three Cases of Congenital Retinal Macrovascular, One Coexisting with Cilioretinal Artery*  
Bayram Gülpamuk et al; Ankara, Turkey

# TURKISH JOURNAL OF OPHTHALMOLOGY



www.ofthalmoloji.org

TJO

## Editor-in-Chief

### MURAT İRKEÇ, MD

Hacettepe University Faculty of Medicine, Department of Ophthalmology, Ankara, Turkey

Areas of Interest: Cornea and Ocular Surface Disease, Glaucoma, Allergy and Immunology

E-mail: mirkec@hacettepe.edu.tr

ORCID ID: orcid.org/0000-0001-8892-4811

## Associate Editors

### TOMRIS ŞENGÖR, MD

İstanbul Bilim University Faculty of Medicine, Department of Ophthalmology, İstanbul, Turkey

Areas of Interest: Cornea and Ocular Surface Disease, Contact Lens

E-mail: tomris.sengor@gmail.com

ORCID ID: orcid.org/0000-0002-9436-5582

### SAİT EĞRİLMEZ, MD

Ege University Faculty of Medicine, Department of Ophthalmology, İzmir, Turkey

Areas of Interest: Cornea and Ocular Surface Disease, Contact Lens, Refraction, Cataract and Refractive Surgery

E-mail: saitegrilmez@gmail.com

ORCID ID: orcid.org/0000-0002-6971-527X

### ÖZLEM YILDIRIM, MD

Mersin University Faculty of Medicine, Department of Ophthalmology, Mersin, Turkey

Areas of Interest: Uveitis, Medical Retina, Glaucoma

E-mail: dryildirimoz@hotmail.com

ORCID ID: orcid.org/0000-0002-3773-2497

### BANU BOZKURT, MD, FEBO

Selçuk University Faculty of Medicine, Department of Ophthalmology, Konya, Turkey

Areas of Interest: Cornea and Ocular Surface Disease, Glaucoma, Allergy and Immunology

E-mail: drbanubozkurt@yahoo.com

ORCID ID: orcid.org/0000-0002-9847-3521

## Statistical Board

### AHMET DİRİCAN

İstanbul University İstanbul Faculty of Medicine, Department of Biostatistics and Medical Informatics, İstanbul, Turkey

## English Language Editor

JACQUELINE RENEE GUTENKUNST, Maryland, USA

## Publishing House

Molla Gürani Mah. Kaçamak Sokak No: 21,  
34093 Fındıkzade-İstanbul-Turkey

Phone: +90 212 621 99 25 Fax: +90 212 621 99 27

E-mail: info@galenos.com.tr

Printed at: Özgün Ofset Ticaret Ltd. Şti.

Yeşilce Mah. Aytekin Sk. No: 21 34418 4. Levent, İstanbul,  
Türkiye

Phone: +90 212 280 00 09

Date of printing: February 2018

International scientific journal published bimonthly.

ISSN: 2149-8695 E-ISSN: 2149-8709

## Advisory Board

### Yonca Aydın Akova,

Bayındır Kavaklıdere Hospital, Ophthalmology  
Clinic, Ankara, Turkey

### Mustafa Kemal Arıcı,

Bezmialem Vakıf University Faculty of  
Medicine, Department of Ophthalmology,  
İstanbul, Turkey

### Kamil Bilgihan,

Gazi University Faculty of Medicine,  
Department of Ophthalmology, Ankara, Turkey

### İzzet Can,

Ophthalmology, Independent Practitioner,  
Ankara, Turkey

### Jose M. Benitez-del-Castillo,

Universidad Complutense de Madrid,  
Hospital Clinico San Carlos, Department of  
Ophthalmology, Madrid, Spain

### Murat Dođru,

Keio University Faculty of Medicine,  
Department of Ophthalmology, Tokyo, Japan

### Şansal Gedik,

Selçuk University Faculty of Medicine,  
Department of Ophthalmology, Konya, Turkey

### Ömür Uçakhan Gündüz,

Ankara University Faculty of Medicine,  
Department of Ophthalmology, Ankara, Turkey

### Banu Melek Hoşal,

Ankara University Faculty of Medicine,  
Department of Ophthalmology, Ankara, Turkey

### Sibel Çalışkan Kadayıfçılar,

Hacettepe University Faculty of Medicine,  
Department of Ophthalmology, Ankara, Turkey

### Murat Karaçorlu,

İstanbul Retina Institute, Ophthalmology Clinic,  
İstanbul, Turkey

### Sarper Karaküçük,

Anadolu Medical Center, Ophthalmology  
Clinic, Kocaeli, Turkey

### Hayyam Kıratlı,

Hacettepe University Faculty of Medicine,  
Department of Ophthalmology, Ankara, Turkey

### Anastasios G.P. Konstas,

Aristotle University of Thessaloniki, Department  
of Ophthalmology, Thessaloniki, Greece

### Anat Loewenstein,

Tel Aviv University Sackler Faculty of Medicine,  
Department of Ophthalmology, Tel Aviv, Israel

### Mehmet Cem Mocan,

Hacettepe University Faculty of Medicine,  
Department of Ophthalmology, Ankara, Turkey

### Pınar Aydın O'dwyer,

Ophthalmology, Independent Practitioner,  
Ankara, Turkey

### Şengül Özdek,

Gazi University Faculty of Medicine,  
Department of Ophthalmology, Ankara, Turkey

### Hakan Özdemir,

Bezmialem Vakıf University Faculty of  
Medicine, Department of Ophthalmology,  
İstanbul, Turkey

### Banu Turgut Öztürk,

Selçuk University Faculty of Medicine,  
Department of Ophthalmology, Konya, Turkey

### Seyhan Bahar Özkan,

Adnan Menderes University Faculty of  
Medicine, Department of Ophthalmology,  
Aydın, Turkey

### Afsun Şahin,

Koç University Faculty of Medicine, Department  
of Ophthalmology, İstanbul, Turkey

### H. Nida Şen,

George Washington University, National  
Eye Institute, Department of Ophthalmology,  
Washington, USA

### İlknur Tuğal Tutkun,

İstanbul University İstanbul Faculty of Medicine,  
Department of Ophthalmology, İstanbul, Turkey

### Nilgün Yıldırım,

Eskişehir Osmangazi University Faculty of  
Medicine, Department of Ophthalmology,  
Eskişehir, Turkey

### Nurşen Yüksel,

Kocaeli University Faculty of Medicine,  
Department of Ophthalmology,  
Kocaeli, Turkey

## The Turkish Journal of Ophthalmology is an official journal of the Turkish Ophthalmological Association.

On Behalf of Turkish Ophthalmological Association Owner

### T. Reha Ersöz,

Çukurova University Faculty of Medicine, Department of Ophthalmology, Adana, Turkey

# TURKISH JOURNAL OF OPHTHALMOLOGY



www.ofthalmoloji.org

TJO

## ABOUT US

The Turkish Journal of Ophthalmology (TJO) is the only scientific periodical publication of the Turkish Ophthalmological Association and has been published since January 1929. In its early years, the journal was published in Turkish and French. Although there were temporary interruptions in the publication of the journal due to various challenges, the Turkish Journal of Ophthalmology has been published continually from 1971 to the present.

The Turkish Journal of Ophthalmology is currently published in Turkish and English languages. TJO is an independent international periodical journal based on single-blind peer-review principle. TJO is regularly published six times a year and special issues are occasionally released. The aim of TJO is to publish original research papers of the highest scientific and clinical value at an international level. Furthermore, review articles, case reports, editorial comments, letters to the editor, educational contributions and congress/meeting announcements are released.

The target audience includes specialists and physicians in training in ophthalmology in all relevant disciplines.

The editorial policies are based on the "Recommendations for the Conduct, Reporting, Editing, and Publication of Scholarly Work in Medical Journals (ICMJE Recommendations)" by the International Committee of Medical Journal Editors (2013, archived at <http://www.icmje.org/>) rules.

The Turkish Journal of Ophthalmology is indexed in the **PubMed Central (PMC)**, **Web of Science-Emerging Sources Citation Index (ESCI)**, **Directory of Open Access Journals (DOAJ)**, **Gale/Cengage Learning**, **Index Copernicus**, **EBSCO Database**, **Scopus**, **Turkish Medline-National Citation Index**, **Turk Medline**, **Cinahl**, **Proquest**, **TUBITAK/ULAKBIM** and **Turkish Citation Index** databases.

### Open Access Policy

This journal provides immediate open access to its content on the principle that making research freely available to the public supports a greater global exchange of knowledge.

Open Access Policy is based on the rules of the Budapest Open Access Initiative (BOAI) <http://www.budapestopenaccessinitiative.org/>. By "open access" to peer-reviewed research literature, we mean its free availability on the public internet, permitting any users to read, download, copy, distribute, print, search, or link to the full texts of these articles, crawl them for indexing, pass them as data to software, or use them for any other lawful purpose, without financial, legal, or technical barriers other than those inseparable from gaining access to the internet itself. The only constraint on reproduction and distribution, and the only role for copyright in this domain, should be to give authors control over the integrity of their work and the right to be properly acknowledged and cited.

### Subscription Information

TJO is sent free of charge to subscribers. Address changes should be immediately reported to the affiliates and to the managing editor. Subscribers who do not receive the journal in the relevant time period should contact the managing editor. All published volumes in full text can be reached free of charge through the website [www.ofthalmoloji.org](http://www.ofthalmoloji.org). Requests for subscription should be addressed to the Turkish Ophthalmological Association.

Manuscripts can only be submitted electronically through the Journal Agent website (<http://journalagent.com/tjo/>) after creating an account. This system allows online submission and review.

### Membership Procedures

#### Turkish Ophthalmological Association

Bank Account: Yapı Kredi Bankası, Şehremini Şubesi 65774842

IBAN: TR10 0006 7010 0000 0065 7748 42

Annual Subscription: Domestic: 100.-TL (Tax Incl)

Abroad: 100 USD (Tax Incl.)

#### Correspondence Address

Editor-in-Chief, Murat İrkeç, MD, Professor in Ophthalmology  
Hacettepe University Faculty of Medicine, Department of Ophthalmology  
06100 Sıhhiye-Ankara-Turkey

**Phone:** +90 212 801 44 36/37 Fax: +90 212 801 44 39

**E-mail:** [mirkec@hacettepe.edu.tr](mailto:mirkec@hacettepe.edu.tr)

#### Secretary, Arzu Sevdasız

**E-mail:** [dergi@ofthalmoloji.org](mailto:dergi@ofthalmoloji.org) - [sekreter@ofthalmoloji.org](mailto:sekreter@ofthalmoloji.org)

**Address:** Avrupa Konutları Kale, Maltepe Mah. Yedikule Çırpıcı Yolu Sk.

9. Blok No: 2 Kat:1 Ofis:1 Zeytinburnu-Istanbul-Turkey

**Phone:** +90 212 801 44 36/37 Fax: +90 212 801 44 39

**Web Page:** [www.ofthalmoloji.org](http://www.ofthalmoloji.org)

#### Permissions

Requests for permission to reproduce published material should be sent to the editorial office.

**Editor-in-Chief:** Murat İrkeç, MD, Professor in Ophthalmology

**Address:** Avrupa Konutları Kale, Maltepe Mah. Yedikule Çırpıcı Yolu Sk.

9. Blok No: 2 Kat:1 Ofis:1 Zeytinburnu-Istanbul-Turkey

**Phone:** +90 212 801 44 36/37 Fax: +90 212 801 44 39

**Web Page:** [www.ofthalmoloji.org](http://www.ofthalmoloji.org)

**E-mail:** [dergi@ofthalmoloji.org](mailto:dergi@ofthalmoloji.org) - [sekreter@ofthalmoloji.org](mailto:sekreter@ofthalmoloji.org)

#### Advertisement

Applications for advertisement should be addressed to the editorial office.

**Address:** Avrupa Konutları Kale, Maltepe Mah. Yedikule Çırpıcı Yolu Sk.

9. Blok No: 2 Kat:1 Ofis:1 Zeytinburnu-Istanbul-Turkey

**Phone:** +90 212 801 44 36/37 Fax: +90 212 801 44 39

**Web Page:** [www.ofthalmoloji.org](http://www.ofthalmoloji.org)

**E-mail:** [dergi@ofthalmoloji.org](mailto:dergi@ofthalmoloji.org) - [sekreter@ofthalmoloji.org](mailto:sekreter@ofthalmoloji.org)

#### Publisher Corresponding Address

**Publisher:** Erkan Mor

Galenos Yayınevi Tic. Ltd. Şti.

**Address:** Molla Gürani Mah. Kaçamak Sk. No: 21, 34093

Fındıkzade-Istanbul-Turkey

**Phone:** +90 212 621 99 25 Fax: +90 212 621 99 27

**E-mail:** [info@galenos.com.tr](mailto:info@galenos.com.tr)

#### Instructions for Authors

Instructions for authors are published in the journal and on the website [www.ofthalmoloji.org](http://www.ofthalmoloji.org)

#### Material Disclaimer

The author(s) is (are) responsible for the articles published in the Turkish Journal of Ophthalmology.

The editor, editorial board and publisher do not accept any responsibility for the articles.

The journal is printed on acid-free paper.

# TURKISH JOURNAL OF OPHTHALMOLOGY



TJO

## INSTRUCTIONS TO AUTHORS

The Turkish Journal of Ophthalmology is an official peer-reviewed publication of the Turkish Ophthalmological Association. Accepted manuscripts are published in both Turkish and English languages.

Manuscripts written in Turkish should be in accordance with the Turkish Dictionary and Writing Guide ("Türkçe Sözlüğü ve Yazım Kılavuzu") of the Turkish Language Association. Turkish forms of ophthalmology-related terms should be checked in the TODNET Dictionary (<http://www.todnet.org/sozluk/>) and used accordingly.

The Turkish Journal of Ophthalmology does not charge any article submission or processing charges.

A manuscript will be considered only with the understanding that it is an original contribution that has not been published elsewhere.

Reviewed and accepted manuscripts are translated either from Turkish to English or from English to Turkish by the Journal through a professional translation service. Prior to printing, the translations are submitted to the authors for approval or correction requests, to be returned within 7 days. If no response is received from the corresponding author within this period, the translation is checked and approved by the editorial board. The abbreviation of the Turkish Journal of Ophthalmology is TJO, however, it should be denoted as Turk J Ophthalmol when referenced. In the international index and database, the name of the journal has been registered as Turkish Journal of Ophthalmology and abbreviated as Turk J Ophthalmol.

The scientific and ethical liability of the manuscripts belongs to the authors and the copyright of the manuscripts belongs to the Turkish Journal of Ophthalmology. Authors are responsible for the contents of the manuscript and accuracy of the references. All manuscripts submitted for publication must be accompanied by the Copyright Transfer Form. Once this form, signed by all the authors, has been submitted, it is understood that neither the manuscript nor the data it contains have been submitted elsewhere or previously published and authors declare the statement of scientific contributions and responsibilities of all authors.

All manuscripts submitted to the Turkish Journal of Ophthalmology are screened for plagiarism using the 'iThenticate' software. Results indicating plagiarism may result in manuscripts being returned or rejected.

Experimental, clinical and drug studies requiring approval by an ethics committee must be submitted to the Turkish Journal of Ophthalmology with an ethics committee approval report confirming that the study was conducted in accordance with international agreements and the Declaration of Helsinki (revised 2013) (<https://www.wma.net/policies-post/wma-declaration-of-helsinki-ethical-principles-for-medical-research-involving-human-subjects/>). The approval of the ethics committee and the fact that informed consent was given by the patients should be indicated in the Materials and Methods section. In experimental animal studies, the authors should indicate that the procedures followed were in accordance with animal rights as per the Guide for the Care and Use of Laboratory Animals (<http://oacu.od.nih.gov/regs/guide/guide.pdf>) and they should obtain animal ethics committee approval. Authors must provide disclosure/acknowledgment of financial or material support, if any was received, for the current study. If the article includes any direct or indirect commercial links or

if any institution provided material support to the study, authors must state in the cover letter that they have no relationship with the commercial product, drug, pharmaceutical company, etc. concerned; or specify the type of relationship (consultant, other agreements), if any.

Authors must provide a statement on the absence of conflicts of interest among the authors and provide authorship contributions.

The Turkish Journal of Ophthalmology is an independent international journal based on single-blind peer-review principles. The manuscript is assigned to the Editor-in-Chief, who reviews the manuscript and makes an initial decision based on manuscript quality and editorial priorities. Manuscripts that pass initial evaluation are sent for external peer review, and the Editor-in-Chief assigns an Associate Editor. The Associate Editor sends the manuscript to three reviewers (internal and/or external reviewers). The reviewers must review the manuscript within 21 days. The Associate Editor recommends a decision based on the reviewers' recommendations and returns the manuscript to the Editor-in-Chief. The Editor-in-Chief makes a final decision based on editorial priorities, manuscript quality, and reviewer recommendations. If there are any conflicting recommendations from reviewers, the Editor-in-Chief can assign a new reviewer.

The scientific board guiding the selection of the papers to be published in the Journal consists of elected experts of the Journal and if necessary, selected from national and international authorities. The Editor-in-Chief, Associate Editors, biostatistics expert and English language consultant may make minor corrections to accepted manuscripts that do not change the main text of the paper.

In case of any suspicion or claim regarding scientific shortcomings or ethical infringement, the Journal reserves the right to submit the manuscript to the supporting institutions or other authorities for investigation. The Journal accepts the responsibility of initiating action but does not undertake any responsibility for an actual investigation or any power of decision.

The Editorial Policies and General Guidelines for manuscript preparation specified below are based on "Recommendations for the Conduct, Reporting, Editing, and Publication of Scholarly Work in Medical Journals (ICMJE Recommendations)" by the International Committee of Medical Journal Editors (2016, archived at <http://www.icmje.org/>).

Preparation of research articles, systematic reviews and meta-analyses must comply with study design guidelines:

CONSORT statement for randomized controlled trials (Moher D, Schulz KF, Altman D, for the CONSORT Group. The CONSORT statement revised recommendations for improving the quality of reports of parallel group randomized trials. *JAMA* 2001; 285: 1987-91) (<http://www.consort-statement.org/>);

PRISMA statement of preferred reporting items for systematic reviews and meta-analyses (Moher D, Liberati A, Tetzlaff J, Altman DG, The PRISMA Group. Preferred Reporting Items for Systematic Reviews and Meta-Analyses: The PRISMA Statement. *PLoS Med* 2009; 6(7): e1000097.) (<http://www.prisma-statement.org/>);

STARD checklist for the reporting of studies of diagnostic accuracy (Bossuyt PM, Reitsma JB, Bruns DE, Gatsonis CA, Glasziou PP, Irwig LM, et al., for the STARD Group. Towards

complete and accurate reporting of studies of diagnostic accuracy: the STARD initiative. *Ann Intern Med* 2003;138:4-4.) (<http://www.stard-statement.org/>);

STROBE statement, a checklist of items that should be included in reports of observational studies (<http://www.strobe-statement.org/>);

MOOSE guidelines for meta-analysis and systemic reviews of observational studies (Stroup DF, Berlin JA, Morton SC, et al. Meta-analysis of observational studies in epidemiology: a proposal for reporting Meta-analysis of observational Studies in Epidemiology (MOOSE) group. *JAMA* 2000; 283: 2008-12).

### GENERAL GUIDELINES

Manuscripts can only be submitted electronically through the Journal Agent website (<http://journalagent.com/tjo/>) after creating an account. This system allows online submission and review.

The manuscripts are archived according to ICMJE, Index Medicus (Medline/PubMed) and Ulakbim-Turkish Medicine Index Rules.

Format: Manuscripts should be prepared using Microsoft Word, size A4 with 2.5 cm margins on all sides, 12 pt Arial font and 1.5 line spacing.

**Abbreviations:** Abbreviations should be defined at first mention and used consistently thereafter. Internationally accepted abbreviations should be used; refer to scientific writing guides as necessary.

**Cover letter:** The cover letter should include statements about manuscript type, single-journal submission affirmation, conflict of interest statement, sources of outside funding, equipment (if applicable), approval of language for articles in English and approval of statistical analysis for original research articles.

### REFERENCES

Authors are solely responsible for the accuracy of all references.

**In-text citations:** References should be indicated as a superscript immediately after the period/full stop of the relevant sentence. If the author(s) of a reference is/are indicated at the beginning of the sentence, this reference should be written as a superscript immediately after the author's name. If relevant research has been conducted in Turkey or by Turkish investigators, these studies should be given priority while citing the literature.

Presentations presented in congresses, unpublished manuscripts, theses, Internet addresses, and personal interviews or experiences should not be indicated as references. If such references are used, they should be indicated in parentheses at the end of the relevant sentence in the text, without reference number and written in full, in order to clarify their nature.

**References section:** References should be numbered consecutively in the order in which they are first mentioned in the text. All authors should be listed regardless of number. The titles of journals should be abbreviated according to the style used in the Index Medicus.

### Reference Format

**Journal:** Last name(s) of the author(s) and initials, article title, publication title and its original abbreviation, publication date, volume, the inclusive page numbers. Example: Collin JR, Rathbun JE. Involutional entropion: a review with evaluation of

## INSTRUCTIONS TO AUTHORS

a procedure. Arch Ophthalmol. 1978;96:1058-1064.

**Book:** Last name(s) of the author(s) and initials, chapter title, book editors, book title, edition, place of publication, date of publication and inclusive page numbers of the extract cited.

**Example:** Herbert L. The Infectious Diseases (1st ed). Philadelphia; Mosby Harcourt; 1999:11;1-8.

**Book Chapter:** Last name(s) of the author(s) and initials, chapter title, book editors, book title, edition, place of publication, date of publication and inclusive page numbers of the cited piece.

**Example:** O'Brien TP, Green WR. Periocular Infections. In: Feigin RD, Cherry JD, eds. Textbook of Pediatric Infectious Diseases (4th ed). Philadelphia; W.B. Saunders Company; 1998:1273-1278.

**Books in which the editor and author are the same person:** Last name(s) of the author(s) and initials, chapter title, book editors, book title, edition, place of publication, date of publication and inclusive page numbers of the cited piece.

**Example:** Solcia E, Capella C, Kloppel G. Tumors of the exocrine pancreas. In: Solcia E, Capella C, Kloppel G, eds. Tumors of the Pancreas. 2nd ed. Washington: Armed Forces Institute of Pathology; 1997:145-210.

### TABLES, GRAPHICS, FIGURES, AND IMAGES

All visual materials together with their legends should be located on separate pages that follow the main text.

**Images:** Images (pictures) should be numbered and include a brief title. Permission to reproduce pictures that were published elsewhere must be included. All pictures should be of the highest quality possible, in

JPEG format, and at a minimum resolution of 300 dpi.

**Tables, Graphics, Figures:** All tables, graphics or figures should be enumerated according to their sequence within the text and a brief descriptive caption should be written. Any abbreviations used should be defined in the accompanying legend. Tables in particular should be explanatory and facilitate readers' understanding of the manuscript, and should not repeat data presented in the main text.

### BIOSTATISTICS

To ensure controllability of the research findings, the study design, study sample, and the methodological approaches and applications should be explained and their sources should be presented.

The "P" value defined as the limit of significance along with appropriate indicators of measurement error and uncertainty (confidence interval, etc.) should be specified. Statistical terms, abbreviations and symbols used in the article should be described and the software used should be defined. Statistical terminology (random, significant, correlation, etc.) should not be used in non-statistical contexts.

All results of data and analysis should be presented in the Results section as tables, figures and graphics; biostatistical methods used and application details should be presented in the Materials and Methods section or under a separate title.

### MANUSCRIPT TYPES

#### Original Articles

Clinical research should comprise clinical observation, new techniques or laboratories studies. Original research articles should include title, structured abstract, keywords relevant to

the content of the article, introduction, materials and methods, results, discussion, study limitations, conclusion, references, tables/figures/images and acknowledgement sections. Title, abstract and key words should be written in both Turkish and English. The manuscript should be formatted in accordance with the above-mentioned guidelines and should not exceed sixteen A4 pages.

**Title Page:** This page should include the title of the manuscript, short title, name(s) of the authors and author information. The following descriptions should be stated in the given order:

1. Title of the manuscript (Turkish and English), as concise and explanatory as possible, including no abbreviations, up to 135 characters
2. Short title (Turkish and English), up to 60 characters
3. Name(s) and surname(s) of the author(s) (without abbreviations and academic titles) and affiliations
4. Name, address, e-mail, phone and fax number of the corresponding author
5. The place and date of scientific meeting in which the manuscript was presented and its abstract published in the abstract book, if applicable

**Abstract:** A summary of the manuscript should be written in both Turkish and English. References should not be cited in the abstract. Use of abbreviations should be avoided as much as possible; if any abbreviations are used, they must be taken into consideration independently of the abbreviations used in the text. For original articles, the structured abstract should include the following sub-headings:

**Objectives:** The aim of the study should be clearly stated.

**Materials and Methods:** The study and standard criteria used should be defined; it should also be indicated whether the study is randomized or not, whether it is retrospective or prospective, and the statistical methods applied should be indicated, if applicable.

**Results:** The detailed results of the study should be given and the statistical significance level should be indicated.

**Conclusion:** Should summarize the results of the study, the clinical applicability of the results should be defined, and the favorable and unfavorable aspects should be declared.

**Keywords:** A list of minimum 3, but no more than 5 key words must follow the abstract. Key words in English should be consistent with "Medical Subject Headings (MESH)" ([www.nlm.nih.gov/mesh/MBrowser.html](http://www.nlm.nih.gov/mesh/MBrowser.html)). Turkish key words should be direct translations of the terms in MESH.

#### Original research articles should have the following sections:

**Introduction:** Should consist of a brief explanation of the topic and indicate the objective of the study, supported by information from the literature.

**Materials and Methods:** The study plan should be clearly described, indicating whether the study is randomized or not, whether it is retrospective or prospective, the number of trials, the characteristics, and the statistical methods used.

**Results:** The results of the study should be stated, with tables/figures given in numerical order; the results should be evaluated according to the statistical analysis methods applied. See General Guidelines for details about the preparation of

visual material.

**Discussion:** The study results should be discussed in terms of their favorable and unfavorable aspects and they should be compared with the literature. The conclusion of the study should be highlighted.

**Study Limitations:** Limitations of the study should be discussed. In addition, an evaluation of the implications of the obtained findings/results for future research should be outlined.

**Conclusion:** The conclusion of the study should be highlighted.

**Acknowledgements:** Any technical or financial support or editorial contributions (statistical analysis, English/Turkish evaluation) towards the study should appear at the end of the article.

**References:** Authors are responsible for the accuracy of the references. See General Guidelines for details about the usage and formatting required.

#### Case Reports

Case reports should present cases which are rarely seen, feature novelty in diagnosis and treatment, and contribute to our current knowledge. The first page should include the title in Turkish and English, an unstructured summary not exceeding 150 words, and key words. The main text should consist of introduction, case report, discussion and references. The entire text should not exceed 5 pages (A4, formatted as specified above).

#### Review Articles

Review articles can address any aspect of clinical or laboratory ophthalmology. Review articles must provide critical analyses of contemporary evidence and provide directions of current or future research. Most review articles are commissioned, but other review submissions are also welcome. Before sending a review, discussion with the editor is recommended.

Reviews articles analyze topics in depth, independently and objectively. The first chapter should include the title in Turkish and English, an unstructured summary and key words. Source of all citations should be indicated. The entire text should not exceed 25 pages (A4, formatted as specified above).

#### Letters to the Editor

Letters to the Editor should be short commentaries related to current developments in ophthalmology and their scientific and social aspects, or may be submitted to ask questions or offer further contributions in response to work that has been published in the Journal. Letters do not include a title or an abstract; they should not exceed 1,000 words and can have up to 5 references.

#### CORRESPONDENCE

All correspondence should be directed to the TJO editorial board:

**Post:** Turkish Ophthalmological Association  
Adress: Avrupa Konutları Kale, Maltepe Mah. Yedikule Çırpıcı Yolu Sk. 9. Blok No: 2 Kat:1 Ofis:1 Zeytinburnu-İstanbul-Turkey

**Phone:** +90 212 801 44 36/37 Fax: +90 212 801 44 39

**Web Page:** [www.ofthalmoloji.org](http://www.ofthalmoloji.org)

**E-mail:** [dergi@ofthalmoloji.org](mailto:dergi@ofthalmoloji.org) / [sekreter@ofthalmoloji.org](mailto:sekreter@ofthalmoloji.org)

# TURKISH JOURNAL OF OPHTHALMOLOGY



www.offalmoloji.org

TJO

## CONTENTS

### Original Articles

- 1 Long-term Results in Pediatric Developmental Cataract Surgery with Primary Intraocular Lens Implantation  
Elif Demirkılınç Biler, Şeyda Yıldırım, Önder Üretmen, Süheyla Köse; Izmir, Adiyaman, Turkey
- 6 Visual Results Following Implantation of a Refractive Multifocal Intraocular Lens in One Eye and a Diffractive in the Contralateral Eye  
Revan Yıldırım Karabağ, Üzeyir Güneç, Rukiye Aydın, Gül Arıkan, Hüseyin Aslankara; Manisa, Izmir, Istanbul, Denizli, Turkey
- 15 Amniotic Membrane Transplantation in Surgical Treatment of Conjunctival Melanoma: Long-term Results  
Melis Palamar, Banu Yaman, Taner Akalın, Ayse Yağcı; Izmir, Turkey
- 19 The Profile and Management of Glaucoma in Adult Aphakic Patients Following Complicated Cataract Surgery  
Ümit Ekşioğlu, Mehmet Yakın, Özgür Balta, Evin Şingar-Özdemir, Hande Hüsnüye Telek, Firdevs Örnek, Ilgaz Yalvaç; Ankara, Istanbul, Turkey
- 23 Characteristics of Anisometropic Patients with and Without Strabismus  
Reşat Duman, Huban Atilla, Emine Çatak; Afyonkarahisar, Ankara, Eskişehir, Turkey
- 27 Direct Treatment Costs of Neovascular Age-related Macular Degeneration and Comparison of Gained and/or Preserved Vision with Expenditure  
Şeyda Yıldırım, Cezmi Akkın, Zafer Özataş, Serhad Nalçacı, Filiz Afrashi, Jale Menteş; Izmir, Turkey

### Review

- 33 Stem Cell Treatment in Retinal Diseases: Recent Developments  
Ayşe Öner; Kayseri, Turkey

### Case Reports

- 39 Primary Conjunctival Tuberculosis  
Nilgün Solmaz, Feyza Önder, Nedime Demir, Özlem Altuntaş; Aydın, Istanbul, Turkey
- 42 Orbital Apex Syndrome Secondary to Herpes Zoster Ophthalmicus  
Gamze Kocaoğlu, Canan Aslı Utine, Aylin Yaman, Süleyman Men; Izmir, Turkey
- 47 Goldmann-Favre Syndrome: Case Series  
Serdar Özataş, Kemal Tekin, Mehmet Yasin Teke; Ankara, Kars, Turkey
- 52 Three Cases of Congenital Retinal Macrovesel, One Coexisting with Cilioretinal Artery  
Bayram Gülpamuk, Pınar Kaya, Mehmet Yasin Teke; Ankara, Turkey

## EDITORIAL

### 2018 Issue 1 at a Glance:

For this issue we have selected from among the valuable research of our colleagues six original articles, one review, and four case reports that we believe offer interesting contributions to the literature.

Pediatric cataract surgery presents unique challenges compared to adult cataract surgery. Based on advances in surgical techniques, an increasing number of ophthalmologists have preferred primary intraocular lens (IOL) implantation in the treatment of aphakia in recent years. However, the youngest age at which children should receive IOL implants remains controversial. Demirkılınç Biler et al.'s retrospective study of 101 eyes of 65 patients aged 2-16 years who underwent cataract surgery with primary IOL implantation showed that this technique yielded good visual outcomes, even in patients with monocular sensory strabismus and nystagmus. They observed optic axis opacities as the most common postoperative complication and emphasized that a myopic shift is inevitable and more pronounced in younger age groups (see pages 1-5).

Yıldırım Karabağ et al. evaluated the visual results of patients who underwent multifocal IOL implantation with the "mix and match" approach in cataract surgery. Twenty patients received a refractive multifocal IOL (ReZoom NXG1) in the dominant eye and a diffractive multifocal IOL (Tecnis ZMA00) in the non-dominant eye. The authors concluded that in the selected cataract patients, this combination of the complementary features of different multifocal IOLs offers excellent visual results, high patient satisfaction, and spectacle independence (see pages 6-14).

Palamar et al. investigated the long-term efficacy and results of reconstruction with amniotic membrane transplantation in conjunctival melanoma surgery. In their study, 10 patients (5 female, 5 male) underwent total excision of conjunctival melanoma with cryotherapy to the surgical margins. Additionally, corneal epitheliectomy with absolute alcohol was performed in eyes with corneal involvement, and those with scleral involvement underwent lamellar sclerectomy and ocular surface grafting with cryopreserved amniotic membrane. They report that this technique is safe and

effective, causes mild complications, and allows surgeons to excise wider tumor margins (see pages 15-18).

The purpose of a modern cataract surgeon is, in most cases, to place an artificial lens into the capsular sac. Rarely, cataract surgery results in aphakia due to intraoperative complications. Aphakia can lead to aphakic glaucoma as a result of complex mechanical and biochemical changes in the vitreous and anterior segment structures. Eksioğlu et al. evaluated characteristics and clinical course of glaucoma in adults who were aphakic after complicated cataract surgery. They retrospectively reviewed 29 aphakic eyes of 22 patients and report that although glaucoma medications can effectively reduce intraocular pressure, glaucomatous disc changes may still progress, especially in patients with advanced disease. Therefore, they concluded that aphakic patients with suspected glaucoma should be referred to a glaucoma specialist without delay (see pages 19-22).

Duman et al. included 65 patients over the age of 5 years who had anisometropia and unilateral amblyopia in their study, and found that 27 of them also had strabismus. They evaluated depth of amblyopia, degree of anisometropia, and binocular vision function in the anisometropic patients with and without strabismus. They observed that increasing degree of anisometropia was associated with higher risk of developing strabismus and that patients with coexistent anisometropia and strabismus exhibit deeper amblyopia. They emphasized that patients with severe anisometropia should be monitored carefully for strabismus (see pages 23-26).

Yıldırım et al. conducted a study to determine the medical expenses associated with treating exudative age-related macular degeneration (AMD) compared to the degree of preserved or increased vision. They retrospectively reviewed data pertaining to 200 eyes of 175 wet AMD patients who were treated with only intravitreal ranibizumab for at least 2 years and underwent no other ocular surgeries during the study period. Their study revealed that 2 years of AMD treatment cost an average of 9,628 TL in medical expenses, that VA was preserved at the end of 2 years compared to initial levels, and that patients who improved with treatment in the first year spent less in the second year (see pages 27-32).

# TURKISH JOURNAL OF OPHTHALMOLOGY



www.ofthalmoloji.org

TJO

## EDITORIAL

Degenerative retinal diseases are among the most important causes of irreversible vision loss, and stem cell transplantation studies aiming to improve visual function in these diseases have gained momentum in recent years. A review by Ayşe Öner shares general information about stem cells and evaluates the results of recent experimental and clinical studies concerning their use in the treatment of retinal diseases (see pages 33-38).

Solmaz et al. share the results of examination, testing, and treatment of a 12-year-old girl referred to their clinic with refractory unilateral conjunctivitis, reminding us that primary tuberculous conjunctivitis should be considered in the differential diagnosis of treatment-resistant unilateral conjunctivitis. They also emphasized that microbiological and histopathological examination of both the conjunctiva and regional lymph nodes are necessary for definite diagnosis (see pages 39-41).

Kocaoğlu et al. describe a 67-year-old male who developed orbital apex syndrome, a rare complication of herpes zoster ophthalmicus (HZO), during the second week of treatment. Orbital magnetic resonance imaging at the apex showed non-mass-like enhancement, and cranial magnetic resonance venography revealed venous thrombosis in the transverse sinus, supporting the clinical diagnosis. Ophthalmoplegia completely resolved at 2 months with systemic steroid and

antiviral therapies. However, vision loss associated with optic neuropathy could not be prevented. The authors emphasized that patients with a history of HZO should be evaluated for optic nerve, extraocular muscle, and eyelid function at every follow-up examination (see pages 42-46).

Goldmann-Favre syndrome (GFS) is a progressive, autosomal recessive, phenotypically variable retinal degenerative condition that develops due to a mutation in the NR2E3 gene, which is involved in the regulation of cone cell differentiation. In their report, Özateş et al. present the examination findings and clinical characteristics in 5 clinically distinct cases of GFS along with a review of the relevant literature (see pages 47-51).

Congenital retinal macrovessel is a rare vascular pathology. It is usually unilateral and comprises a large branch of the retinal artery or vein. The condition is often detected incidentally. Gülpamuk et al. reported three cases of retinal macrovessels in patients ranging in age from 6 to 16 years, with one also accompanied by a cilioretinal artery. The authors recommended following such patients regularly due to the possibility of developing pathologies that reduce vision (see pages 52-55).

**Respectfully on behalf of the Editorial Board,  
Özlem Yıldırım, MD**





# Long-term Results in Pediatric Developmental Cataract Surgery with Primary Intraocular Lens Implantation

Elif Demirkılınç Biler\*, Şeyda Yıldırım\*\*, Önder Üretmen\*, Süheyla Köse\*\*\*

\*Ege University Faculty of Medicine, Department of Ophthalmology, İzmir, Turkey

\*\*Adıyaman University Research and Training Hospital, Department of Ophthalmology, Adıyaman, Turkey

\*\*\*Private Practice, İzmir, Turkey

## Abstract

**Objectives:** The aim of this study was to evaluate the outcomes of pediatric developmental cataract surgery with primary intraocular lens (IOL) implantation.

**Materials and Methods:** Patients between 2 and 16 years old who underwent cataract surgery with primary IOL implantation were retrospectively evaluated. Age at time of surgery, pre- and postoperative best corrected visual acuities, postoperative ocular complications, and any accompanying ocular pathologies were obtained from the patients' charts. Mean refractive changes and degree of myopic shift were analyzed according to the age groups. Operated eyes were also compared with the fellow eyes in unilateral cases.

**Results:** A total of 101 eyes of 65 patients were included. The average age at time of surgery was  $76 \pm 40$  months and the average follow-up period was  $44 \pm 30$  months. Among the 78 eyes that could be assessed for visual acuity improvement, 66 (84.6%) of them showed  $\geq 2$  lines of improvement. The difference in the mean refractive change between the 2-5 years old and 8-16 years old age groups was found to be statistically significant. However, the mean refractive change per year was not found to be significant between the same age groups. In unilateral cases, the operated eyes showed a greater myopic change than the fellow eyes, with no statistically significant difference. The most common postoperative complication was visual axis opacity.

**Conclusion:** Good visual outcomes can be achieved following pediatric cataract surgery with primary IOL implantation. Optic axis opacities were the most common postoperative complications. Overall, refractive changes following surgery are inevitable, and more prominent in younger age groups.

**Keywords:** Pediatric cataract surgery, myopic shift, primary intraocular lens implantation, pseudophakic glaucoma, visual axis opacity

## Introduction

Pediatric cataract surgery offers unique challenges when compared to adult cataract surgery. These difficulties result from differences in the surgical technique, types of complications, and prevalence.<sup>1</sup> Pediatric aphakia can lead to a group of problems, such as anisometropic amblyopia, posterior capsular opacification, glaucoma, strabismus, and loss of binocular function.<sup>2</sup> Due to advances in operative techniques, an increasing number of ophthalmologists have accepted primary intraocular lens (IOL) implantation as a mode of aphakic rehabilitation in recent years.<sup>3,4,5,6</sup> For children older than 2 years who underwent cataract surgery, IOL implantation is considered to be the gold standard

by most authors.<sup>7</sup> However, although IOL implantation is the standard of care for adult patients, the minimum recommended age for implantation in children remains controversial.<sup>1,7</sup> Because the pediatric eye is still developing, refractive changes occur during the postoperative childhood or adolescent years in patients who underwent IOL implantation for cataracts.<sup>8,9</sup> Moreover, varying degrees of refractive myopic shift after pediatric cataract surgery and IOL implantation have been reported, with a moderate amount of individual variability.<sup>4,8,9,10,11,12,13</sup> A postoperative increased inflammatory response in children is another serious problem which can lead to fibrinous reactions, pigment deposits on the IOL, decentration of the IOL, and posterior synechiae.<sup>14</sup>

**Address for Correspondence:** Elif Demirkılınç Biler MD, Ege University Faculty of Medicine, Department of Ophthalmology, İzmir, Turkey  
Phone: +90 232 390 35 94 E-mail: elif.dem@gmail.com ORCID-ID: orcid.org/0000-0002-3741-1191

**Received:** 22.01.2017 **Accepted:** 07.06.2017

©Copyright 2018 by Turkish Ophthalmological Association  
Turkish Journal of Ophthalmology, published by Galenos Publishing House.

This study was designed to evaluate the postoperative outcomes, such as visual acuity improvement, refractive changes, myopic shift, complications, and additional surgical interventions, following pediatric developmental cataract surgery with primary IOL implantation.

### Materials and Methods

This was a retrospective study carried out on 65 consecutive pediatric patients between 2 and 16 years of age with developmental cataracts, who underwent cataract surgery with primary IOL implantation between January 1998 and May 2014 at the Ege University Faculty of Medicine, Department of Ophthalmology. All of the patients were followed for at least 6 months postoperatively. Eyes with cataracts due to trauma, surgery, or any other ocular pathologies were excluded from this research.

Data were collected from the patients' charts, including gender, age at time of cataract surgery, laterality, surgical procedure, best corrected visual acuity (BCVA) via Snellen chart, the presence, type, and amount of ocular deviation, cycloplegic refraction, slit-lamp examination, fundus examination and B-scan ultrasonography (if needed), IOP measurement, the course of amblyopia therapy, and postoperative complications and management. Axial length measurement (Sonogage Eye Scan, Cleveland, OH, USA) and keratometric evaluation (Topcon KR-7000P; Topcon Europe BV, Netherlands) were performed preoperatively to calculate the IOL power. Because the postoperative myopic shift was anticipated, the postoperative refraction was targeted to be hyperopic in concordance with a survey performed among the members of the American Association for Pediatric Ophthalmology.<sup>6</sup> The age-adjusted target refractions were calculated as recommended by Enyedi et al.<sup>9</sup> We aimed for a postoperative refractive goal of +6 for a 1-year-old, +5 for a 2-year-old, +4 for a 3-year-old, +3 for a 4-year-old, +2 for a 5-year-old, +1 for a 6-year-old, and emmetropia for older ages. The SRK/T formula was used as recommended in a recent infant aphakia treatment study.<sup>15</sup>

All of the surgeries were performed under general anesthesia by one of the authors (E.D.B., O.U., or S.K.). The operative method involved two 1.1-mm side port incisions, anterior microcapsulorrhexis, hydrodissection, phacoaspiration, an additional 3.2-mm corneal incision, and in-the-bag hydrophilic acrylic IOL implantation. If the patient was younger than 5 years old, had mental retardation, or cooperated poorly, a routine posterior capsulorrhexis combined with anterior vitrectomy was performed. In the other cases, the posterior capsule was left intact. Posterior capsulotomy combined with anterior vitrectomy was not performed in 4 children <5 years old who were cooperative enough to undergo Nd:YAG laser capsulotomy. The incisions were closed with 10-0 nylon sutures.

Prescriptions for postoperative topical tobramycin and dexamethasone sodium phosphate every two hours, and cyclopentolate hydrochloride three times each day were tapered during the first postoperative month. All of the patients were

routinely examined 1 day and 5 days after surgery, then once a week for 1 month, every 1-3 months during the first year, then every 6 months during the postoperative follow-up period. The extra visits and routine follow-up visit intervals were arranged for each patient individually. Amblyopia therapy was carried out as needed. During every postoperative visit, a comprehensive ophthalmologic examination was repeated, including BCVA, refractive assessment, evaluation of ocular deviation, IOL measurement, and slit-lamp and fundus examinations.

For the analysis, the patients were divided into 3 groups according to their age at surgery: 2 to 5 years old, 5 to 8 years old, and 8 to 16 years old. All of the refractive data represented the spherical equivalent refraction (sphere plus one-half of the cylinder). Moreover, the eyes with unilateral cataracts were compared with the normal fellow eyes according to the mean refractive changes during the follow-up period.

### Statistical Analysis

Statistical analysis was performed with SPSS for Windows version 18.0 (SPSS Inc., Chicago, IL, USA). All of the data were reported as the average ± standard deviation. Statistical comparisons were performed with the Mann-Whitney U and Student's t-tests, and a p value of <0.05 was considered to be statistically significant.

The research protocol adhered to the Declaration of Helsinki for research involving human subjects. All of the parents or guardians of the children studied provided written consent to the screening and follow-up assessments.

### Results

A total of 101 eyes of 65 patients were included in this study; 36 patients had bilateral cataract surgery. The average age at the time of surgery was 76±40 months (range 25-192 months) and the average follow-up time was 44±30 months (range 6-174 months). Both the pre- and postoperative visual acuities (Snellen chart) could be evaluated in 78 eyes of 52 patients. BCVA improved by ≥2 lines in 61 eyes (78.2%), and improved by 1 line in 6 eyes at the last follow-up when compared with their preoperative measurements. Six of the eyes showed no changes in visual acuity. At the last follow-up, 71 eyes of 47 patients had visual acuities of ≥0.5.

The visual acuity improvements were also analyzed according to laterality (Table 1). Among those patients who had unilateral cataract surgery, visual acuity improvement could be assessed in

**Table 1. Best corrected visual acuity improvements according to laterality**

	BCVA improvement			
	No change	1 line	2 lines	>2 lines
All (78 eyes)	6 (7.7%)	6 (7.7%)	5 (6.4%)	61 (78.2%)
Unilateral (26 eyes)	5 (19.2%)	2 (7.7%)	3 (11.5%)	16 (61.6%)
Bilateral (52 eyes)	1 (1.9%)	4 (7.7%)	2 (3.9%)	45 (86.5%)

BCVA: Best corrected visual acuity

26 eyes. BCVA improved by  $\geq 2$  lines in 19 eyes (73.1%) and by 1 line in 2 eyes at the last follow-up when compared with their preoperative measurements; however, 5 eyes showed no changes in visual acuity. The visual acuity improvement could be evaluated in 52 eyes of 26 patients among the 36 patients who had bilateral cataract surgery. The BCVA improved by  $\geq 2$  lines in 47 eyes (90.4%), and improved by 1 line in 4 eyes at the last follow-up when compared with preoperative measurements. One eye showed no change in visual acuity.

Ten patients had monocular sensory strabismus preoperatively. The visual acuity improvement could be assessed in 7 of the 10 patients with monocular strabismus. In 6 eyes (85.7%), BCVA improved by  $\geq 2$  lines. Three patients had nystagmus preoperatively. One of them had an improvement of  $\geq 2$  lines in both eyes.

Among 42 children (64.6%) that were prescribed occlusion therapy after surgery, 36 could be evaluated during the follow-up period with regard to their visual acuity improvement; 18 (50%) showed  $\geq 2$  lines of improvement in response to the occlusion therapy.

The patients were divided into 3 groups according to their ages at time of surgery: 43 eyes of 25 patients 2 to 5 years old in the first group, 28 eyes of 18 patients 5 to 8 years old in the second group, and 30 eyes of 22 patients 8 to 16 years old in the third group. Refractive changes were analyzed according to these

age groups (Table 2). The mean refractive change and refractive change per year of follow-up were calculated among only the cases with myopic shift. Although these values were observed to be greatest in the younger age groups, only the difference in the mean refractive change between the 2-5 years old and 8-16 years old age groups were found to be statistically significant ( $p=0.009$ ). However, the mean refractive change per year was not significant between the 2-5 years old and 8-16 years old age groups ( $p=0.335$ ).

In the unilateral cases, the operated eye showed a greater mean refractive change and greater mean refractive change per year. However, there was no significant difference between the operated and nonoperated eyes regarding the mean of these values (mean refractive change  $-1.05 \pm 1.64$  vs.  $-0.58 \pm 0.66$ , mean refractive change per year  $-0.36 \pm 0.87$  vs.  $-0.22 \pm 0.53$ ;  $p$  values 0.18 and 0.48, respectively).

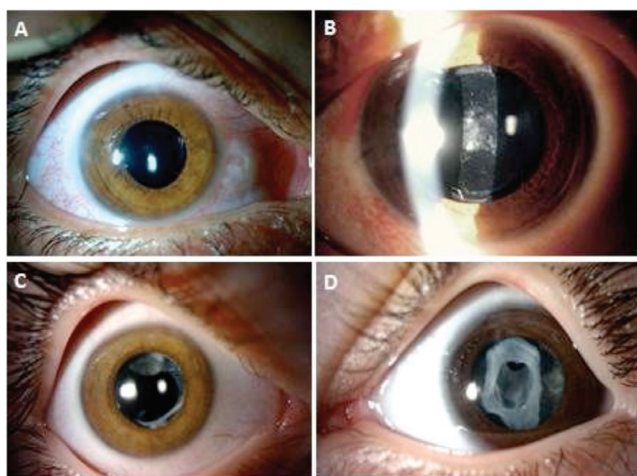
No intraoperative complications were observed. In 52 of 101 eyes, at least one postoperative complication was observed during the follow-up period. The most common ocular complication was visual axis opacity, which was observed in 49 eyes, including posterior capsule opacification (PCO) in 23 eyes (22.8%), secondary membrane or lens reformation in 15 eyes, and capsular phimosis in 11 eyes.

Posterior capsulotomy and anterior vitrectomy were performed in 67 eyes. Visual axis opacification (PCO in 11 eyes, secondary membrane or lens reformation in 4 eyes, and capsular phimosis in 8 eyes) was seen in 23 of those 67 eyes (34.3%) and 15 of them required additional intervention (22.3%). Among 34 eyes without primary posterior capsulotomy, visual axis opacification (PCO in 22 eyes, secondary membrane or lens reformation in 1 eye, and capsular phimosis in 3 eyes) was observed in 26 eyes (76.4%) and 22 of them required further intervention (64.7%) (Figure 1).

Pediatric pseudophakic glaucoma was observed in 2 eyes (1.98%), and medical antiglaucomatous treatment was effective in both cases.

## Discussion

In this study, we reported good visual outcomes after cataract surgery with primary IOL implantation in pediatric patients between 2 and 16 years of age. We were able to assess the visual acuity changes after surgery in 78 eyes, and of those, 72 eyes (92.3%) showed improvements in visual acuity. In a study by Kleinman et al.<sup>1</sup>, the authors reported that over 80% of the eyes had improvements in visual acuity, and more than 50% of the



**Figure 1.** Postoperative images of patients with A) no complication; B) posterior capsular opacification; C) capsular phimosis and lens reformation; and D) secondary membrane formation

Age at surgery (years)	n (eye)	Myopic shift	Mean refractive change (D)	Mean follow-up time (years)	Mean refractive change (D) per year
2-5	43	38/43 (88.4%)	$-2.6 \pm 2.4$ (-8.63 to -0.12)	$4.3 \pm 3.0$ (13-174 months)	$-0.69 \pm 0.55$
5-8	28	21/28 (75%)	$-1.45 \pm 0.97$ (-3.87 to -0.12)	$3.4 \pm 2.3$ (6-87 months)	$-0.57 \pm 0.45$
8-16	30	16/30 (53.3%)	$-1.37 \pm 1.13$ (-5.12 to -0.12)	$2.9 \pm 1.5$ (9-65 months)	$-0.51 \pm 0.48$

eyes achieved visual acuities of  $\geq 20/40$  at the last follow-up. In another study by Crouch et al.<sup>2</sup>, out of 52 pediatric pseudophakic eyes, 85% had 20/40 vision or better. Inatomi et al.<sup>16</sup> observed visual acuities of 20/40 or better in 79% of the operated eyes in their study of 15 unilateral cases. We observed 2 lines or more of visual acuity improvement in 78.2% of our patients, while 91% of the patients had visual acuities of 20/40 or better at the last follow-up, in concordance with the literature.

Myopic shifts following pediatric cataract surgery and IOL implantation have been reported in the literature to varying degrees.<sup>8,9,10,11,13,17</sup> In our study, we found myopic shifts in all of the age groups; however, the differences in the mean refractive change and mean refractive change per year, especially in the 2-5 years old age group, were found to be much greater, which was statistically significant. Plager et al.<sup>17</sup> reported refractive changes in 38 eyes that underwent primary IOL implantation and were followed for an average of 6 years. They stated that the rate of myopic shift decreased with age, and the variability among individuals decreased with age. Crouch et al.<sup>2</sup> observed a myopic shift that continued even until early adolescence following cataract surgery in their long-term study, with an average follow-up of 5.45 years. Although in previous reports the myopic shift in pseudophakic eyes has been attributed to excessive axial elongation by amblyopia and visual deprivation,<sup>18,19</sup> Enyedi et al.<sup>9</sup> reported that they did not believe that the trend of myopia in pseudophakia was the result of excessive elongation, but rather of normal eye growth with a fixed IOL power. They suggested that the myopic shift that they and other authors have observed is consistent with this growth pattern.<sup>9</sup> Dahan and Drusedau<sup>10</sup> also reported that pseudophakic eyes showed the most axial elongation during the first 2 years, and continued to grow more slowly up to the age of 8 years old, as in normal phakic eyes.

In 15 unilateral cases, long-term (4 to 15 years) changes in refraction, axial length, and refractive power of the cornea were evaluated and compared with nonoperated eyes, and no significant differences in the axial length or refractive power of the cornea between the operated and nonoperated eyes were detected, although there was significant myopic change in the operated eyes.<sup>16</sup> Enyedi and other authors (like Crouch) explained that this was because the IOL power was stable in the operated eye, while the normal phakic lens retained accommodation and compensated for developmental elongation.<sup>2,9</sup> In developing phakic eyes, it was reported that the progressive flattening of the crystalline lens decreased the refractive consequences of axial elongation.<sup>20</sup> McClathey et al.<sup>21</sup> inferred that the myopic shift of an operated eye was an optical phenomenon; as the eye grows, the IOL moves farther and farther from the retina. Analogous to the effects of the vertex distance with high-power lenses, the anterior movement of the IOL as the child grows induces a myopic shift by itself.<sup>21</sup> When we evaluated our unilateral cases and compared the operated eyes with the fellow eyes, we found a higher myopic shift in the operated eyes than the nonoperated fellow eyes, in concordance with these studies, but the difference was not statistically significant. However, since we did not measure axial length in the follow-up visits, we could not

discuss how axial elongation influenced the refractive state in the pseudophakic eyes during the children's development. This is a major limitation of our research.

Postoperative complications were another focus of our study. We determined that the most common ocular complication was visual axis opacity, including PCO, secondary membrane or lens re-proliferation, and capsular phimosis, as previously reported.<sup>1,14</sup> The prevalence of PCO has been reported to range between 14% and 72% in different studies with different age groups, surgical techniques, and IOL types.<sup>1,2,22</sup> We observed PCO in 22.8% of our cases, secondary membrane or lens re-proliferation in 14.9%, and capsular phimosis in 10.9%. However, all of these complications were successfully treated using appropriate interventions. The preventive measures for visual axis opacification following pediatric cataract surgery include a primary posterior capsulectomy with or without anterior vitrectomy.<sup>23</sup> In our clinic, we routinely perform a posterior capsulotomy with an anterior vitrectomy post-IOL implantation in children under 5 years old. In patients older than this, we leave the posterior capsule intact because, in most of those cases, it is easier to treat PCO with Nd:YAG laser. In our study, all of the eyes in patients older than 5 years with significant PCO were successfully treated with Nd:YAG laser.

Glaucoma is one of the most important and common complications of congenital cataract surgery. It is reported that the incidence of glaucoma in cases of aphakia ranges from 0.9% to 32%, which is less common than in pseudophakic patients.<sup>24,25</sup> In a recent study among pediatric patients, glaucoma incidence was reported as 33.3% in aphakia and 34.8% in patients with secondary IOL implantation, whereas no glaucoma was detected in patients with primary IOL implantation.<sup>26</sup> Our glaucoma incidence was 1.98%, in concordance with the literature.

## Conclusion

In conclusion, this study demonstrated that good visual outcomes can be achieved after pediatric cataract surgery with IOL implantation, even in patients with monocular sensorial strabismus and nystagmus. Occlusion therapy can play a great role in the improvement of visual acuity. Refractive changes after pediatric cataract surgery are inevitable, and predicting a future myopic shift remains difficult. Physicians must be aware of the variability of refractive changes, and must adjust for this with appropriate spectacles. Surgeons should also be aware of the possible postoperative complications after pediatric cataract surgery, and must pay close attention. Careful long-term follow-up and informing parents of any possible complications are essential for the care of these patients.

## Ethics

**Ethics Committee Approval:** Ege University, Clinical Research Ethics Committee (approval no: 17-11.1/76).

**Informed Consent:** The research protocol adhered to the Declaration of Helsinki for research involving human subjects. All of the parents or guardians of the children studied provided written consent to the screening and follow up assessments.

**Peer-review:** Externally peer-reviewed.

#### Authorship Contributions

Surgical and Medical Practices: Elif Demirkılınç Biler, Önder Üretmen, Süheyla Köse, Concept: Elif Demirkılınç Biler, Design: Elif Demirkılınç Biler, Önder Üretmen, Data Collection or Processing: Şeyda Yıldırım, Elif Demirkılınç Biler, Analysis or Interpretation: Elif Demirkılınç Biler, Önder Üretmen, Süheyla Köse, Literature Search: Şeyda Yıldırım, Elif Demirkılınç Biler, Writing: Elif Demirkılınç Biler, Öner Üretmen, Şeyda Yıldırım.

**Conflict of Interest:** No conflict of interest was declared by the authors.

**Financial Disclosure:** The authors declared that this study received no financial support.

#### References

- Kleinman G, Zaugg B, Apple DJ, Bleik J. Pediatric cataract surgery with hydrophilic acrylic intraocular lens. *J AAPOS*. 2013;17:367-370.
- Crouch ER, Crouch ER Jr, Pressman SH. Prospective analysis of pediatric pseudophakia: myopic shift and postoperative outcomes. *J AAPOS*. 2002;6:277-282.
- Plager DA, Yang S, Neely D, Sprunger D, Sondhi N. Complications in the first year following cataract surgery with and without IOL in infants and older children. *J AAPOS*. 2002;6:9-14.
- Brady KM, Atkinson CS, Kilty LA, Hiles DA. Cataract surgery and intraocular lens implantation in children. *Am J Ophthalmol*. 1995;120:1-9.
- Rosenbaum AL, Masket S. Intraocular lens implantation in children. *Am J Ophthalmol*. 1995;120:105-107.
- Wilson ME Jr, Bartholomew LR, Trivedi RH. Pediatric cataract surgery and intraocular lens implantation: Practice styles and preferences of the 2001 ASCRS and AAPOS memberships. *J Cataract Refract Surg*. 2003;29:1811-1820.
- Infant Aphakia Treatment Study Group, Lambert SR, Buckley EG, Drews-Botsch C, DuBois L, Hartmann E, Lynn MJ, Plager DA, Wilson ME. The infant aphakia treatment study: design and clinical measures at enrollment. *Arch Ophthalmol*. 2010;128:21-27.
- Kora Y, Shimizu K, Inatomi M, Fukado Y, Ozawa T. Eye growth after cataract extraction and intraocular lens implantation in children. *Ophthalmic Surg*. 1993;24:467-475.
- Enyedi LB, Peterseim MW, Freedman SF, Buckley EG. Refractive changes after pediatric intraocular lens implantation. *Am J Ophthalmol*. 1998;126:772-781.
- Dahan E, Drusedau MU. Choice of lens and dioptric power in pediatric pseudophakia. *J Cataract Refract Surg*. 1997;23(Suppl 1):618-623.
- Ben Ezra D. Cataract surgery and intraocular lens implantation in children. *Am J Ophthalmol*. 1996;121:224-226.
- Gimbel HV, Ferensowicz M, Raanan M, DeLuca M. Implantation in children. *J Pediatr Ophthalmol Strabismus*. 1993;30:69-79.
- Hutchinson AK, Drews-Botsch C, Lambert SR. Myopic shift after intraocular lens implantation during childhood. *Ophthalmology*. 1997;104:1752-1757.
- Medsing A, Nischal KK. Pediatric cataract: challenges and future directions. *Clin Ophthalmol*. 2015;9:77-90.
- Vanderveen DK, Trivedi RH, Nizam A, Lynn MJ, Lambert SR; Infant Aphakia Treatment Study Group. Predictability of intraocular lens power calculation formulae in infantile eyes with unilateral congenital cataract: results from the Infant Aphakia Treatment Study. *Am J Ophthalmol*. 2013;156:1252-1260.
- Inatomi M, Kora Y, Kinohira Y, Yaguchi S. Long-term follow-up of eye growth in pediatric patients after unilateral cataract surgery with intraocular lens implantation. *J AAPOS*. 2004;8:50-55.
- Plager DA, Kipfer H, Sprunger DT, Sondhi N, Neely DE. Refractive change in pediatric pseudophakia: 6-year follow-up. *J Cataract Refract Surg*. 2002;28:810-815.
- Wiesel TN, Raviola E. Increase in axial length of the macaque monkey eye after corneal opacification. *Invest Ophthalmol Vis Sci*. 1979;18:1232-1236.
- Tigges M, Tigges J, Fernandes A, Eggers HM, Gammon JA. Postnatal axial eye elongation in normal and visually deprived rhesus monkey. *Invest Ophthalmol Vis Sci*. 1990;31:1035-1046.
- Gordon RA, Donzis PB. Refractive development of the human eye. *Arch Ophthalmol*. 1985;103:785-789.
- McClathrey SK, Dahan E, Maselli E, Gimbel HV, Wilson ME, Lambert SR, Buckley EG, Freedman SF, Plager DA, Parks MM. A comparison of the rate of refractive growth in pediatric aphakic and pseudophakic eyes. *Ophthalmology*. 2000;107:118-122.
- Batur M, Gul A, Seven E, Can E, Yaşar T. Posterior Capsular Opacification in Preschool- and School-Age Patients after Pediatric Cataract Surgery without Posterior Capsulotomy. *Turk J Ophthalmol*. 2016;46:205-208.
- Jafarinasab MR, Rabbanikhah Z, Karimian F, Javadi MA. Lensectomy and PCIOL Implantation with versus without Posterior Capsulotomy and Anterior Vitrectomy for Pediatric Cataracts. *J Ophthalmic Vis Res*. 2008;3:37-41.
- Rabiah PK. Frequency and predictors of glaucoma after pediatric cataract surgery. *Am J Ophthalmol*. 2004;137:30-37.
- Mills MD, Robb RM. Glaucoma following childhood cataract surgery. *J Pediatr Ophthalmol Strabismus*. 1994;31:355-360.
- Solmaz NU, Onder F, Koca GE. Development of Secondary Glaucoma After Congenital Cataract Surgery and the Underlying Risk Factors. *Turk J Ophthalmol*. 2011;41:358-363.



# Visual Results Following Implantation of a Refractive Multifocal Intraocular Lens in One Eye and a Diffractive in the Contralateral Eye

© Revan Yıldırım Karabağ\*, © Üzeyir Güneç\*\*, © Rukiye Aydın\*\*\*, © Gül Arıkan\*\*, © Hüseyin Aslankara\*\*\*\*

\*Manisa State Hospital, Ophthalmology Clinic, Manisa, Turkey

\*\*Dokuz Eylül University Faculty of Medicine, Department of Ophthalmology, İzmir, Turkey

\*\*\*Medipol University Faculty of Medicine, Department of Ophthalmology, İstanbul, Turkey

\*\*\*\*Private Gözakademi Hospital, Ophthalmology Clinic, Denizli, Turkey

## Abstract

**Objectives:** To assess the visual outcomes in patients who underwent cataract surgery with multifocal intraocular lens (IOL) implantation using a “mix and match” approach.

**Materials and Methods:** Twenty patients (40 eyes) were involved in this prospective, nonrandomized study. Refractive multifocal IOLs (ReZoom NXG1) were implanted in patients’ dominant eyes and diffractive multifocal IOLs (Tecnis ZMA00) were implanted in their non-dominant eyes. Monocular and binocular uncorrected distance, intermediate and near visual acuity (logMAR), and contrast sensitivity levels were measured at 1, 3, and 6 months after cataract surgery. Defocus curves, reading speeds, patient satisfaction, spectacle dependence, and halo and glare symptoms were also evaluated at 6 months after the surgery. Postoperative quality of life was assessed with the Turkish version of National Eye Institute Visual Function Questionnaire-25.

**Results:** The study group comprised 8 females and 12 males with a mean age of  $69.45 \pm 10.76$  years (range, 31-86 years). The uncorrected distance and intermediate visual acuity levels were significantly better in the ReZoom-implanted eyes at postoperative 6 months ( $p=0.026$  and  $p=0.037$ , respectively). There was no statistically significant difference in uncorrected near visual acuity ( $p>0.05$ ). There was no statistically significant difference in contrast sensitivity, reading speed, halos, or glare between the groups ( $p<0.05$ ). Mild glare/halo was reported by 40% of the subjects. The mean patient satisfaction was 95% and all patients were spectacle independent.

**Conclusion:** Mixing and matching multifocal IOLs in selected cataract patients provides excellent visual outcome, a high level of patient satisfaction, and spectacle independency.

**Keywords:** Mix and match, multifocal intraocular lenses, cataract

## Introduction

Presbyopia is still one of the most challenging optical problems in cataract and refractive surgery, and spectacle independence is one of the major demands of the patients. Various presbyopic intraocular lenses (IOL) have been implanted to treat presbyopia during cataract surgery.<sup>1,2,3</sup>

Multifocal IOLs have good clinical results with careful patient selection.<sup>4,5,6,7</sup> Clinically, there are two types of multifocal

optics in IOLs: diffractive and refractive. Refractive multifocal IOLs provide very good visual results for intermediate and distance vision, but offer limited near vision.<sup>8,9,10,11,12</sup> Diffractive multifocal IOLs provide very good results at near vision, but may not function effectively at intermediate distances.<sup>8,9,10,11,12,13,14</sup>

The ReZoom NXG1 multifocal IOL (Abbott Medical Optics, Santa Ana, CA, USA) is a three-piece, refractive, hydrophobic acrylic, aspheric IOL with UV blocking and an OptiEdge design that is claimed to minimize edge glare and

**Address for Correspondence:** Rukiye Aydın MD, Medipol University Faculty of Medicine, Department of Ophthalmology, İstanbul, Turkey  
Phone: +90 212 460 77 77 E-mail: drrukiyeaydin@gmail.com ORCID-ID: orcid.org/0000-0003-0668-3749

**Received:** 17.03.2017 **Accepted:** 03.07.2017

©Copyright 2018 by Turkish Ophthalmological Association  
Turkish Journal of Ophthalmology, published by Galenos Publishing House.

reduce posterior capsular opacification. The refractive surface has 5 optical zones (zones 1, 3, and 5 are distance-dominant, whereas zones 2 and 4 are near-dominant). An aspheric transition between the zones is designed to provide balanced intermediate vision. It is designed to allow 100% light transmission in order to provide the full range of vision.<sup>15</sup>

The Tecnis ZMA00 multifocal IOL (Abbott Medical Optics, Santa Ana, CA, US) is a three-piece foldable, diffractive, aspheric, UV-blocking, hydrophobic acrylic optic with OptiEdge design. The modified, prolate anterior surface is designed to reduce spherical aberrations. The diffractive zones are located on the posterior surface. The diffractive pattern is 32 concentric circles with a +4 diopters (D) near addition that evenly splits the light entering the eye into two focal planes regardless of pupil size: one for distance and one for near.<sup>16</sup>

As with all multifocal IOL technologies, each of these unique designs has its limitations. With the aim of increasing patient satisfaction and spectacle independence after cataract surgery, a “mix and match” method involving implantation of a refractive multifocal IOL in one eye and a diffractive multifocal IOL in the contralateral eye, was first described by Gunenc in 2000. Preliminary findings with this approach were published in 2004 and long-term results in 2008.<sup>17,18</sup> The aim of this method is to extend depth of focus and quality of vision as well as decrease photic symptoms, increase spectacle independence rates, and improve distance, intermediate, and near visual acuity.

In this study, we evaluated visual results and patient satisfaction after using a “mix and match” approach of implanting new-generation refractive multifocal IOLs (ReZoom NXG1) in dominant eyes and diffractive multifocal IOLs (Tecnis ZMA00) in the nondominant eyes.

## Materials and Methods

Forty eyes of 20 patients (8 females and 12 males) who were examined at our clinic and had bilateral cataract were prospectively enrolled in this study. Using the “mix and match” approach, all patients received the ReZoom NXG1 refractive multifocal IOL in their dominant eye, followed by implantation of the Tecnis ZMA00 diffractive multifocal IOL in their nondominant eye two weeks later. The dominant eye was determined via a pinhole test. All patients were adequately informed and signed an informed consent form. The study was performed in accordance with the Declaration of Helsinki and was approved by the Dokuz Eylül University local ethics committee.

Bilateral cataract patients who did not want to wear glasses or contact lenses after surgery and had realistic expectations were included the study. The exclusion criteria were previous ocular surgery, ocular disease other than cataract, corneal astigmatism greater than 1.00 D, axial length (AL) less than 21.0 mm or more than 26.0 mm, myopia and hypermetropia greater than 5.00 D, pupil width less than 3 mm under dim light, and intraoperative complications.

Intraocular lens power calculation was made by using each patient’s keratometry, AL, and the A-constant of the IOL using

both A-scan ultrasound (A-scan Nidek 3000, NIDEK Co., Japan) and laser interference biometry (the IOLMaster Version V2.02, Carl Zeiss Meditec AG, Germany). Biometry was done by the same doctor (R.Y.K.). Targeted refraction was emmetropia in all eyes. After considering both measurements and each patient’s AL, keratometric values, and anterior chamber depth, the SRK-T formula was used to determine the power of multifocal IOL to be implanted.

## Surgical Technique

All operations were performed by the same surgeon (U.G.). After the application of topical anesthesia (proparacaine hydrochloride 0.5%), 2.8 mm clear corneal incisions were made in the superior or temporal quadrants, at the steep corneal axis. After filling the anterior chamber with viscoelastic substance, a continuous curvilinear capsulorhexis was created with a diameter of approximately 5 mm. After creating two side ports, hydrodissection was performed. The nucleus and epinucleus were aspirated by phacoemulsification, and cortical cleaning was accomplished by bimanual irrigation/aspiration. The capsular bag and anterior chamber were filled with viscoelastic substance. Both IOLs were inserted using the UNFOLDER<sup>®</sup> Emerald XL delivery system (Abbott Medical Optics, Santa Ana, CA, USA). The viscoelastic substance was aspirated by bimanual irrigation/aspiration, and the operation was completed with stromal hydration and intracameral 1% cefuroxime injection. There were no intraoperative or postoperative complications. After surgery, patients received prednisolone acetate 1% and ofloxacin 0.3% eye drops 6 times per day for the first postoperative week. Ofloxacin was stopped at the end of the first week and patients were advised to continue prednisolone acetate 4 times per day for 3 weeks.

## Outcome Measurements

Patients were examined for anterior segment findings at 1 and 7 days following surgery. Patients were evaluated at 1, 3, and 6 months postoperatively. At every follow-up visit, spherical equivalent values, keratometry, monocular and binocular uncorrected distance visual acuity (UDVA) at 4 meters using Early Treatment of Diabetic Retinopathy Study (ETDRS) chart, monocular and binocular uncorrected near visual acuity (UNVA) using ETDRS Near LogMAR Chart 2000 (Precision Vision, LaSalle, IL) at 40 cm, and monocular and binocular uncorrected intermediate visual acuity (UIVA) with ETDRS Near LogMAR Chart 2000 at 100 cm were assessed. Results were evaluated using logMAR visual acuities.<sup>19</sup> Monocular and binocular contrast sensitivity under photopic (85 cd/m<sup>2</sup>) and mesopic (3 cd/m<sup>2</sup>) conditions was measured using the Functional Acuity Contrast Test Chart of the Optec 6500 vision tester (Stereo Optical, Chicago, Illinois, USA).

At 6 months after surgery, defocus curve and focus depth (NIDEK RT-5100 Foropter, NIDEK CO., LTD.), and monocular and binocular reading speed under the same conditions using Turkish version of MNREAD (Minnesota Low Vision Reading Test) cards<sup>20</sup> were measured. Every sentence of MNREAD card consists of 3 lines and 60 characters. Chart 1 and 2 include 19

logarithmic sentences in the logMAR range of -0.5 to 1.3 with 0.1 logarithmic intervals. Patients were asked to read a sentence as fast and accurately as possible while the sentences below were covered with a piece of paper. Patients reading speed was evaluated from the beginning until the critical print size, which was the smallest print size the patient could read at maximum reading speed. Reading time was measured with a stopwatch. Reading time and number of errors were recorded for each sentence. Patients' right eyes were evaluated with chart 1 and left eyes with chart 2. Then binocular reading speed was measured with chart 1. Reading speed was calculated using the following formula: reading speed (words/min)=60 × (10 - number of errors)/time (s).

Quality of life, halo, glare phenomena, spectacle independence, adaptation time to photic phenomena, and eye preference were also evaluated at 6 months after surgery. The Turkish version of the National Eye Institute Visual Functioning Questionnaire-25 (NEI VFQ-25) was used to evaluate the patients' quality of life.<sup>21</sup> Patients who had halo and glare were asked to grade phenomena on a scale of mild, moderate, or severe. The patients were also asked whether they would suggest the "mix and match" approach to other patients. For all measurements, monocular examinations (first right eyes, then left eyes) were done before binocular examinations.

**Statistical Analysis**

Data were evaluated using SPSS version 15.0 software. For complementary analysis, mean values, standard deviation, and percentage values were used. Visual acuity values were converted to logMAR equivalents for statistical analysis.<sup>19</sup> Visual functions of the refractive and diffractive groups were compared using the Mann-Whitney U test. Friedman test was applied to compare visual acuities and spherical equivalent values at 1, 3, and 6 months postoperatively. Spearman correlation analysis was used to determine whether there is a correlation between the patient satisfaction and postoperative results at 6 months. A p value less than 0.05 was considered statistically significant.

**Results**

The study group consisted of 40 eyes of 20 patients, including 8 females (40%) and 12 males (60%). The mean age of the patients was 69.45±10.76 years (range, 31-86 years). The mean preoperative corrected distance visual acuity (CDVA) was 0.33±0.22 logMAR.

**Spherical Equivalent Values**

At postoperative 6 months, the mean spherical equivalent was -0.04±0.12 D in ReZoom-implanted eyes and -0.11±0.2 D in Tecnis-implanted eyes. There was no statistically significant difference in spherical equivalent values between refractive and diffractive groups at 1, 3, or 6 months postoperatively (p>0.05).

**Visual Acuity Outcomes**

Visual acuity outcomes were not significantly different at 1, 3, or 6 months postoperatively, therefore only the 6-month results are presented.

**Monocular Distance Visual Acuity**

All eyes achieved UDVA of 0.2 logMAR or better in the refractive group, compared with 90% of the eyes in the diffractive group. Mean UDVA was 0.00±0.09 logMAR in the refractive group and 0.09±0.13 logMAR in the diffractive group. UDVA was significantly better in the refractive group than the diffractive group (p=0.026) (Table 1).

**Monocular Near Visual Acuity**

Sixty-five percent of the eyes in the refractive group achieved a UNVA of 0.2 logMAR or better, compared with 80% of the eyes in the diffractive group. Mean UNVA was 0.24±0.14 logMAR in the refractive group and 0.16±0.1 logMAR in the diffractive group. No statistically significant difference was noted between the groups (p>0.05) (Table 2).

At postoperative 6 months, the patients were asked to hold the near chart where they could best read it. Mean patient-preferred reading distance was 32.1±3.0 cm in the diffractive eyes and 35.85±6.05 cm in the refractive eyes. The patients' best binocular reading distance was 33.75±3.55 cm. Patient-preferred reading distance was statistically significant closer in diffractive eyes (p=0.034).

**Monocular Intermediate Visual Acuity**

All eyes achieved UIVA of 0.2 logMAR or better in the refractive group, compared with 80% of the eyes in the diffractive group. Mean UIVA was 0.14±0.22 logMAR in the refractive group and 0.19±0.13 logMAR in the diffractive

**Table 1. Monocular uncorrected distance visual acuity at postoperative 6 months**

LogMAR	Refractive eyes n (%)	Diffractive eyes n (%)
-0.2	1 (5)	0
-0.1	5 (25)	0
0	8 (40)	11 (55)
0.1	5 (25)	3 (15)
0.2	1 (5)	4 (20)
0.4	0	2 (10)

\*Uncorrected distance visual acuity was significantly better in the refractive group (p=0.026)

**Table 2. Monocular uncorrected near visual acuity at postoperative 6 months**

LogMAR	Refractive eyes n (%)	Diffractive eyes n (%)
0	1 (5)	3 (15)
0.1	4 (20)	6 (30)
0.2	8 (40)	7 (35)
0.3	3 (15)	4 (20)
0.4	2 (10)	0
0.5	2 (10)	0

\*There was no statistically significant difference between groups (p>0.05)



group. The refractive group had significant better intermediate vision ( $p=0.037$ ) (Table 3).

Figure 1 shows monocular and binocular UDVA, UIVA, and UNVA values at 1 month, 3 months, and 6 months postoperatively.

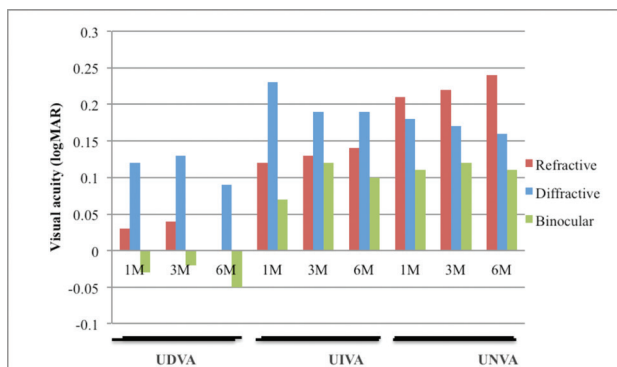
**Binocular Visual Acuity**

The patients' mean binocular UDVA, UIVA, and UNVA levels at postoperative 1, 3, and 6 months are shown in Table 4. At the 6-month postoperative visit, all patients achieved an UDVA of 0.1 logMAR or better. Fifteen patients (75%) achieved an UNVA of 0.1 logMAR or better and 18 patients (90%) achieved an UIVA of 0.1 logMAR or better.

Figure 1 shows the monocular and binocular UDVA, UIVA, and UNVA at 1, 3, and 6 months postoperatively. Binocular visual acuity results were better than monocular results at all distances throughout the follow-up.

**Contrast Sensitivity**

Contrast sensitivity levels of the all binocular, refractive, and diffractive groups were within normal limits both under photopic and mesopic conditions throughout follow-up. No statistically



**Figure 1.** Monocular and binocular uncorrected distance visual acuity, uncorrected intermediate visual acuity and uncorrected near visual acuity at 1 month, 3 months, and 6 months postoperatively

UDVA: Uncorrected distance visual acuity, UIVA: Uncorrected intermediate visual acuity, UNVA: Uncorrected near visual acuity

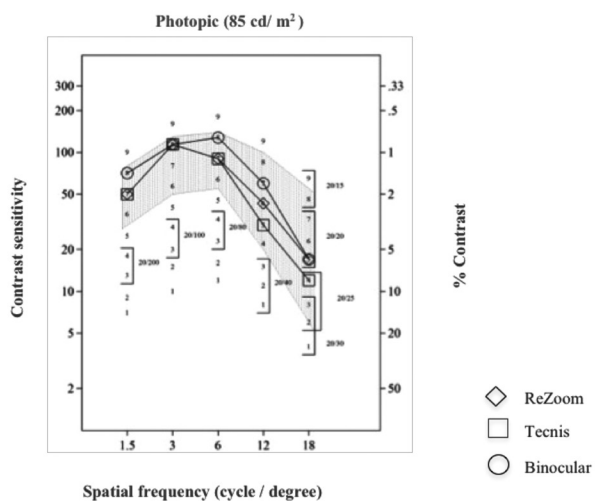
LogMAR	Refractive eyes n (%)	Diffractive eyes n (%)
-0.1	1 (5)	1 (5)
0	7 (35)	1 (5)
0.1	5 (25)	4 (20)
0.2	7 (35)	10 (50)
0.3	0	2 (10)
0.4	0	1 (5)
0.5	0	1 (5)

\*Uncorrected intermediate visual acuity was significantly better in the refractive group ( $p=0.037$ )

significant difference was noted between the refractive and diffractive groups at any spatial frequencies under photopic or mesopic conditions at 1, 3, or 6 months postoperatively ( $p>0.05$ ). Figures 2 and 3 shows the contrast sensitivity curves of the binocular, refractive, and diffractive eyes in photopic and mesopic conditions at 6 months postoperatively.

**Defocus Curve**

The diffractive eyes were significantly better than the refractive eyes between +4.00 and +3.00 D ( $p<0.05$ ) and between -3.00 D and -5.00 D ( $p<0.05$ ). The refractive eyes were significantly better than the diffractive eyes at +0.5 D ( $p=0.038$ ). There was



**Figure 2.** Contrast sensitivity curves of all groups under photopic conditions at postoperative 6 months

	Mean	SD	Median	Minimum	Maximum
<b>1<sup>st</sup> month</b>					
UDVA	-0.03	±0.10	0.0	0.20	-0.20
UIVA	0.07	±0.08	0.10	0.20	-0.10
UNVA	0.12	±0.09	0.10	0.30	0.0
<b>3<sup>th</sup> month</b>					
UDVA	-0.02	±0.10	0.0	0.20	-0.20
UIVA	0.12	±0.23	0.10	1.00	-0.10
UNVA	0.12	±0.08	0.10	0.30	0.0
<b>6<sup>th</sup> month</b>					
UDVA	-0.05	±0.09	-0.10	0.10	-0.20
UIVA	0.09	±0.23	0.05	1.00	-0.10
UNVA	0.11	±0.09	0.10	0.30	0.0

UDVA: Uncorrected distance visual acuity, UIVA: Uncorrected intermediate visual acuity, UNVA: Uncorrected near visual acuity

no statistically significant difference between diffractive and refractive eyes with regards to intermediate distance.

Binocular vision achieved the best results at all distances in the defocus curve. The binocular vision results were significantly better than those of diffractive eyes between +1.50 and -2.00 D ( $p < 0.05$ ) and those of refractive eyes between +4.00 and +1.50 D ( $p < 0.05$ ) and between -2.50 and -5.00 D ( $p < 0.05$ ).

Mean depth of focus of the refractive, diffractive, and binocular group were 5.0 D, 5.5 D, and 6.0 D, respectively. Figure 4 shows the defocus curves of all groups at 6 months postoperatively.

**Spectacle Independence**

All patients had satisfactory spectacle-free visual function in their daily life during the follow-up period.

**Subjective Symptoms and Patient Satisfaction**

According to NEI VFQ-25 questionnaire results, patient satisfaction was 90% or above with regards to distance and near activities, social functions, and driving. Ninety-five percent of the patients stated that they would suggest multifocal IOL implantation with the “mix and match” approach to other patients. When asked whether there was any difference between each eye’s visual acuity and visual quality, 5 patients (25%)

preferred the vision in their refractive eye and 2 patients (10%) preferred the vision in their diffractive eye, while 13 patients (65%) reported no difference between the two eyes.

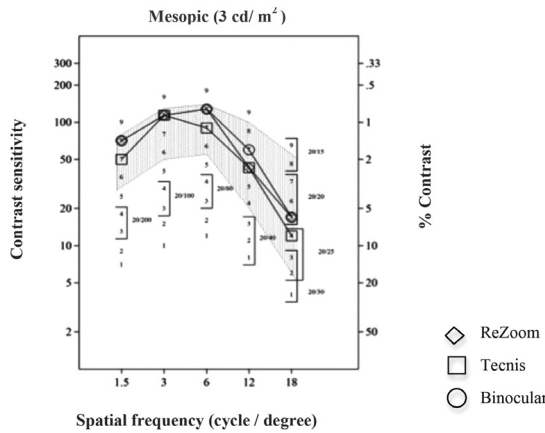
In terms of photic phenomena such as halo and glare, 11 patients (55%) reported mild and 5 patients (25%) reported moderate symptoms at postoperative 3 months. Eight patients (40%) reported mild and 2 patients (10%) reported moderate symptoms at postoperative 6 months. One patient reported symptoms in the diffractive eye only, while the other patients reported equal symptoms in both eyes. Only one patient in the early postoperative period reported watching TV with sunglasses due to severe glare. The severity of the symptom decreased at the end of the second postoperative month. At postoperative 6 months, one patient had complaints of mild glare. However, it did not cause any difficulty in the patient’s daily life. When the patients were asked how long it took to get used to photic phenomena, the average time needed to adapt was  $28.4 \pm 37.1$  days (0-120 days). Ninety-five percent of the patients reported their distance, intermediate, and near visual acuity as “perfect or very good”.

**Reading Speed**

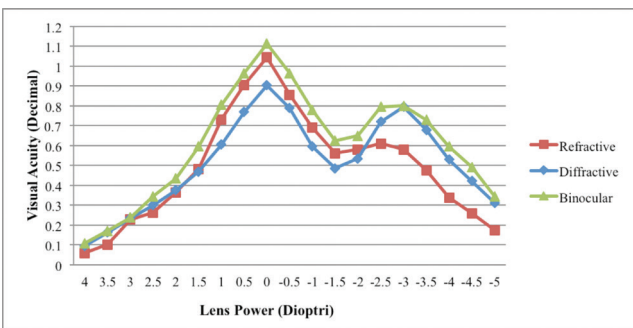
Patients’ mean reading speed in both refractive and diffractive eyes was the same, at 166 words/min. Binocular mean reading speed was 177 words/min. None of the patients had posterior capsular opacification or IOL dislocation during the follow-up period.

**Discussion**

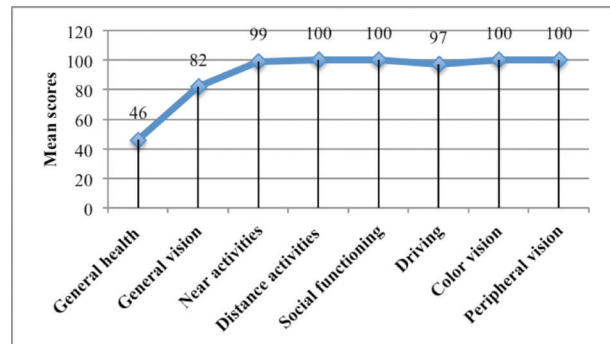
Several surgical techniques have been developed for the correction of pseudophakic presbyopia, including monovision,<sup>21,22</sup> multifocal IOLs,<sup>6</sup> accommodative IOLs,<sup>23</sup> toric multifocal IOLs,<sup>24</sup> and trifocal IOLs.<sup>25</sup> The concept of mixing and matching refractive and diffractive multifocal IOLs was first described by Gunenc and Celik.<sup>17,18</sup> It is known that refractive multifocal IOLs provide good UDVA and UIVA,<sup>26,27</sup> while diffractive multifocal IOLs provide good UDVA and UNVA.<sup>27,28,29,30</sup> Mixing and matching different IOLs could allow the surgeon to combine the advantages of both refractive and diffractive lens designs.



**Figure 3.** Contrast sensitivity curves of all groups under mesopic conditions at postoperative 6 months



**Figure 4.** Defocus curves of all groups at postoperative 6 months



**Figure 5.** National Eye Institute Visual Functioning Questionnaire-25 questionnaire results

In Gunenc's initial study,<sup>18</sup> 10 patients received the diffractive multifocal IOL (811E CeeOn-diffractive group) in 1 eye, another 10 patients received the refractive multifocal IOL (Array SA40N-refractive group) in 1 eye, and the other 10 patients underwent bilateral implantation with the refractive multifocal IOL in one eye and diffractive multifocal IOL in the other eye ("mix and match" group). The results demonstrated that 100% of the patients in the "mix and match" group, 90% of the patients in the refractive group, and 80% of the patients in the diffractive group had UDVA of 20/25 or better. In addition, 90% of the patients from the "mix and match" group were able to live without spectacles, compared to 60% in the other groups. All patients were satisfied with their visual functions over long-term follow-up.

Currently available second-generation multifocal IOLs have overcome some of the drawbacks of the first-generation models. The results of the "mix and match" approach have been reported in a number of studies. Goes,<sup>31</sup> Hütz et al.,<sup>32</sup> and Lubiński et al.<sup>33</sup> reported the results of 20 patients who received ReZoom in their dominant eye and Tecnis ZM900 in their nondominant eye. Similarly, in the current study 20 patients received ReZoom in their dominant eye, but hydrophobic acrylic Tecnis ZMA00 in their nondominant eye (Table 5). In all four of these studies, patients' binocular UDVA, UIVA, and UNVA were within satisfactory levels and levels of spectacle independence were quite high.

In the current study, UDVA in the ReZoom-implanted eyes was significantly better than in the Tecnis-implanted eyes. At 6 months after implantation, UDVA was 0.1 logMAR or better in the 95% of the ReZoom-implanted eyes versus 70% of the Tecnis ZMA00-implanted eyes. Binocular UDVA was 0.1 logMAR or better in all of the patients (20/20). Hütz et al.<sup>32</sup> reported UDVA of 0.1 logMAR or better in the 80% of the ReZoom-implanted eyes but only 20% of the Tecnis ZM900-implanted eyes at postoperative 3 months. Binocular UDVA was 0.1 logMAR or better in 85% of the patients. In both studies, monocular UDVA results in the ReZoom-implanted eyes were significantly better than in the Tecnis-implanted eyes. In this study, 65% of the ReZoom-implanted eyes achieved an UIVA of 0.1 logMAR or better,

compared with 30% of the Tecnis ZMA00-implanted eyes at postoperative 6 months. Monocular UIVA results in the ReZoom-implanted eyes were significantly better than the Tecnis-implanted eyes. Ninety percent of the patients (18/20) achieved a binocular UIVA of 0.1 logMAR or better. Lubiński et al.<sup>33</sup> reported that 90% of their patients achieved a binocular UIVA of 0.0 logMAR at 6 months postoperatively. However, they evaluated UIVA at 60 cm in their study, whereas it was evaluated at 100 cm in our study.

In Hütz et al.<sup>32</sup> study, none of the ReZoom-implanted eyes achieved a UNVA of 0.1 logMAR or better, compared with 60% of the Tecnis ZM900-implanted eyes at postoperative 3 months. Sixty percent of the patients achieved a binocular UNVA of 0.1 logMAR or better. In our study, 25% of the ReZoom-implanted eyes achieved an UNVA of 0.1 logMAR or better, compared with 45% of the Tecnis ZMA00-implanted eyes at 6 months postoperatively. Seventy-five percent of the patients achieved a binocular UNVA of 0.1 logMAR or better. In both studies, UNVA results in the Tecnis eyes were better than in the ReZoom-implanted eyes; however, the difference was statistically significant only in Hütz et al.<sup>32</sup> study.

When the "mix and match" approach is used, it is usually recommended to implant the refractive multifocal IOL in the dominant eye.<sup>34</sup> However, Yoon et al.<sup>35</sup> suggest implanting the diffractive multifocal IOL in the dominant eye if the patient frequently performs near-distance work, and recommend implanting the refractive ReZoom in the dominant eye if the patient frequently performs intermediate-distance work. Implantation of the diffractive multifocal IOL to the dominant eye may be an option in special conditions.

In the present study, best patient-preferred reading distance was significantly closer in the Tecnis eyes. Reading speed can provide useful information regarding a patient's functional visual performance. In the current study, no statistically significant difference was found between the ReZoom- and Tecnis-implanted eyes in terms of reading speed. As expected, mean binocular reading speed was higher than monocular reading speed due to binocular summation. Chen et al.<sup>36</sup> and Hütz et al.<sup>32</sup> also reported that "mix and match" eyes achieved satisfactory reading speed and reading acuity under both low

**Table 5. The "mix and match" results of similar studies**

Study	Multifocal IOL	Follow-up time (months)	Mean age (years)	Binocular UDVA	Binocular UIVA	Binocular UNVA	Spectacle independency (%)
Current study	ReZoom-Tecnis ZMA00	6	69.45 (31-86)	-0.05±0.09	0.1±0.05	0.1±0.05	100
Goes <sup>31x</sup>	ReZoom-Tecnis ZM900	2	58 (44-78)	0.0±0.2	0.3±0.05	-0.05±0.4	100
Hütz et al. <sup>32</sup>	ReZoom-Tecnis ZM900	3	72.1 (59-83)	0.08±0.07	∅	0.14±0.07	84-93
Lubiński et al. <sup>33</sup>	ReZoom-Tecnis ZM900	6	60.95 (42-70)	-0.18±0.08	0.01±0.03	0.0	100

<sup>x</sup>In the original study, results are given in decimal, UDVA: Uncorrected distance visual acuity, UIVA: Uncorrected intermediate visual acuity, UNVA: Uncorrected near visual acuity

and high illumination levels.

Buckhurst et al.<sup>37</sup> compared the defocus curves of 4 groups of 15 patients implanted with bilateral Softec monofocal IOL, bilateral ReZoom multifocal IOL, bilateral Tecnis ZM900 multifocal IOL, or “mix and match” with ReZoom implanted in the right eye and Tecnis ZM900 in the left eye. Best distance corrected intermediate visual acuity was significantly better in the ReZoom group when compared with the monofocal and Tecnis ZM900 groups, while there was no significant difference between the ReZoom group and the “mix and match” group. Best distance corrected near visual acuity was significantly better in the Tecnis group compared to the monofocal and ReZoom groups, whereas no significant difference was observed between the Tecnis group and the “mix and match” group. The “mix and match” group showed similar results to both the ReZoom and Tecnis groups. In the present study, we found a statistically significant superiority of the ReZoom eyes at -0.5 D (distance vision) whereas the Tecnis ZMA00 eyes were statistically better between -3.0 and -5.0 D (near vision). No statistically significant difference in intermediate vision was observed between the ReZoom- and Tecnis-implanted eyes. Binocular vision significantly outperformed the ReZoom-implanted eyes for near vision (-2.5 to -5.0 D) and the Tecnis-implanted eyes for distance and intermediate vision (+1.5 to -2.0 D). These results suggest that the “mix and match” approach provides the advantages of the both designs and enhances visual performance.

Multifocal IOL implantation can cause reduced contrast sensitivity, but this reduction does not appear to differ between diffractive and refractive multifocal IOLs.<sup>38</sup> However, Terwee et al.<sup>39</sup> showed that although the Tecnis ZM900 and ZMA00 models were not affected by pupil diameter, ReZoom NXG1 was affected by pupil diameter, and pupil dilation in low light resulted in decreased contrast sensitivity in ReZoom MIOL-implanted eyes. On the other hand, Yoon et al.<sup>35</sup> reported that there was no statistically significant difference between ReZoom NXG1 and Tecnis ZM900 multifocal IOLs under both photopic and mesopic conditions, and the contrast sensitivity levels were good both in low and high frequencies. In the present study, photopic and mesopic contrast sensitivity levels at all spatial frequencies were within normal limits in the ReZoom NXG1 and Tecnis ZMA00 eyes throughout follow-up. We observed that binocular contrast sensitivity levels were higher than those in ReZoom and Tecnis eyes, but the difference was not statistically significant. In Lubiński et al.'s study,<sup>33</sup> binocular distance photopic and mesopic and binocular near photopic contrast sensitivity levels were in normal limits even at high frequency. In addition, they stated that the binocular contrast sensitivity results were better at postoperative 6 months compared to results at 3 months.

Photic phenomena such as glare and halo occur as a result of multiple unfocused images.<sup>40</sup> In Goes's<sup>31</sup> series, 12 of 20 patients reported photic symptoms and only one patient reported severe photic phenomena. Lubiński et al.<sup>33</sup>

reported that none of the patients had severe halo or glare symptoms; however, 75% of the patients had some glare and halo phenomena, especially in low-light conditions. Hütz et al.<sup>32</sup> also indicated that mild halos and severe glare were observed in 47% and 40% of their patients, respectively. Yoon et al.<sup>35</sup> reported that photic phenomena persisted in the unilateral groups, while the symptoms decreased over time in the bilateral “mix and match” group. They suggested that the lack of these photic phenomena in the phakic eyes of the unilateral group may have prevented their neuroadaptation to the new visual disturbances. In present study, 2 patients (10%) reported moderate, and 8 patients (40%) reported mild halo and glare symptoms at 6 months postoperatively. The patients expressed that the photic symptoms did not disturb them in their daily lives. The success of the multifocal IOL depends on the brain's neuroadaptation time.<sup>41</sup> The long phase of neuroadaptation takes 3-12 months. Before final assessment of visual performance and patient satisfaction, it is important to allow sufficient time for neuroadaptation. None of our patients required explanation of multifocal IOL during follow-up.

In the current study, patient satisfaction was over 90% in terms of distance and near vision and social functions according to NEI VFQ-25 survey results. Satisfaction during driving was 97% among the patients who drove daily (n=10). Yamauchi et al.<sup>42</sup> presented a visual performance comparison between bilateral implantation of the Tecnis monofocal IOL and Tecnis multifocal IOL (ZMA00/ZMB00). When the NEI VFQ-25 scores were evaluated, only nighttime driving score was significantly worse in the multifocal group than the monofocal group. In our study, 95% of the patients reported that their satisfaction from visual performances was “perfect or very good” and 95% stated that they would recommend this method to other patients. All of the studies using the “mix and match” approach have yielded high levels of patient satisfaction and spectacle independency.<sup>18,31,32,33</sup> The “mix and match” approach can provide satisfactory results in selected patients who have realistic expectations and high motivation for a wide range of spectacle-free visual functions.

#### Study Limitation

A limitation of the present study is the lack of a control group of patients implanted with bilateral refractive and bilateral diffractive multifocal IOLs. Prospective, randomized, double-blind studies assessing bilateral refractive, bilateral diffractive, bilateral trifocal, and “mix and match” multifocal IOL implantation are needed.

#### Conclusion

In conclusion, the “mix and match” implantation of multifocal IOLs in conjunction with proper patient selection can be considered a good option for the correction of pseudophakic presbyopia. This approach can provide satisfactory visual acuity levels at all distances, high patient satisfaction, and

spectacle independence. The most important factors for high patient satisfaction are appropriate patient selection, correct IOL power calculation, and uneventful surgery.

#### Ethics

**Ethics Committee Approval:** Dokuz Eylül University Faculty of Medicine, Clinical and Laboratory Research Ethics Committee (confirmation number: B.30.2.DEÜ.0.01.00.00/9995).

**Informed Consent:** Available.

**Peer-review:** Externally peer-reviewed.

#### Authorship Contributions

**Surgical and Medical Practices:** Üzeyir Güneç, Revan Yıldırım Karabağ, **Concept:** Üzeyir Güneç, Hüseyin Aslankara, **Design:** Üzeyir Güneç, Hüseyin Aslankara, **Data Collection or Processing:** Revan Yıldırım Karabağ, **Analysis or Interpretation:** Üzeyir Güneç, Gül Arıkan, Revan Yıldırım Karabağ, **Literature Search:** Revan Yıldırım Karabağ, Rukiye Aydın, **Writing:** Revan Yıldırım Karabağ, Rukiye Aydın, Gül Arıkan.

**Conflict of Interest:** No conflict of interest was declared by the authors.

**Financial Disclosure:** This study received financial support for the purchasing multifocal intraocular lenses by the Dokuz Eylül University Rectorate, Scientific Research Project Coordination Unit (Project no: 2009.KB.SAG.089, 2009187).

#### References

- Gooi P, Ahmed IK. Review of presbyopic IOLs: multifocal and accommodating IOLs. *Int Ophthalmol Clin.* 2012;52:41-50.
- Agresta B, Knorz MC, Kohnen T, Donati C, Jackson D. Distance and Near Visual Acuity Improvement After Implantation of Multifocal Intraocular Lenses in Cataract Patients With Presbyopia: A Systematic Review. *J Refract Surg.* 2012;28:426-435.
- Lichtinger A, Rootman DS. Intraocular lenses for presbyopia correction. *Curr Opin Ophthalmol.* 2012;23:40-46.
- Lacmanović-Loncar V, Pavčić-Astalos J, Petric-Vicković I, Mandić Z. Multifocal intraocular "mix and match" lenses. *Acta Clin Croat.* 2008;47:217-220.
- Bellucci R. Multifocal intraocular lenses. *Curr Opin Ophthalmol.* 2005;16:33-37.
- De Vries NE, Nuijts RM. Multifocal intraocular lenses in cataract surgery: Literature review of benefits and side effects. *J Cataract Refract Surg.* 2013;39:268-278.
- Lane SS, Morris M, Nordan L, Packer M, Tarantino N, Wallace RB 3 rd. Multifocal intraocular lenses. *Ophthalmol Clin North Am.* 2006;19:89-105.
- Chiam PJ, Chan JH, Haider SI, Karia N, Kasaby H, Aggarwal RK. Functional vision with bilateral ReZoom and ReSTOR intraocular lenses 6 months after cataract surgery. *J Cataract Refract Surg.* 2007;33:2057-2061.
- Alió JL, Grabner G, Plaza-Puche AB, Rasp M, Piñero DP, Seyeddain O, Rodríguez-Prats JL, Ayala MJ, Moreu R, Hohensinn M, Riha W, Dextl A. Postoperative bilateral reading performance with 4 intraocular lens models: Six-month results. *J Cataract Refract Surg.* 2011;37:842-852.
- Van Der Linden JW, Van Velthoven M, Van Der Meulen I, Nieuwendael C, Mourits M, Lapid-Gortzak R. Comparison of a new-generation sectorial addition multifocal intraocular lens and a diffractive apodized multifocal intraocular lens. *J Cataract Refract Surg.* 2012;38:68-73.
- Alió JL, Plaza-Puche AB, Javaloy J, Ayala MJ. Comparison of the Visual and Intraocular Optical Performance of a Refractive Multifocal IOL With Rotational Asymmetry and an Apodized Diffractive Multifocal IOL. *J Refract Surg.* 2012;28:100-105.
- Cillino S, Casuccio A, Di Pace F, Morreale R, Pillitteri F, Cillino G, Lodato G. One-Year Outcomes with New-Generation Multifocal Intraocular Lenses. *Ophthalmology.* 2008;115:1508-1516.
- Blaylock JE, Si Z, Vickers C. Visual and refractive status at different focal distances after implantation of the ReSTOR multifocal intraocular lens. *J Cataract Refract Surg.* 2006;32:1464-1473.
- Kohnen T, Allen D, Boureau C, Dublneau P, Hartmann C, Mehdorn E, Rozot P, Tassinari G. European Multicenter Study of the AcrySof ReSTOR Apodized Diffractive Intraocular Lens. *Ophthalmology.* 2006;113:584.
- Product Insert. Abbott Medical Optics, Santa Ana, CA, USA. 2010
- Product Insert. Abbott Medical Optics, Santa Ana, CA, USA. 2011
- Gunenc U, Celik L. Multifocal intraocular lenses: clinical evaluation of diffractive versus refractive designs. *Med Netw Ophthalmol.* 2004;11:4-11.
- Gunenc U, Celik L. Long-term experience with mixing and matching refractive array and diffractive CeeOn multifocal intraocular lenses. *J Refract Surg.* 2008;24:233-242.
- Holladay JT. Proper method for calculating average visual acuity. *J Refract Surg.* 1997;13:388-391.
- İdil Ş, Çalişkan D, İdil N. Development and validation of the Turkish version of the MNREAD visual acuity charts. *Turk J Med Sci.* 2011;41:565-570.
- Jain S, Arora I, Azar DT. Success of monovision in presbyopes: review of the literature and potential applications to refractive surgery. *Surv Ophthalmol.* 1996;40:491-499.
- Greenbaum S. Monovision pseudophakia. *J Cataract Refract Surg.* 2002;28:1439-1443.
- Cumming JS, Colvard DM, Dell SJ, Doane J, Fine IH, Hoffman RS, Packer M, Slade SG. Clinical evaluation of the Crystalens AT-45 accommodating intraocular lens: results of the U.S. Food and Drug Administration clinical trial. *J Cataract Refract Surg.* 2006;32:812-825.
- Visser N, Nuijts RM, de Vries NE, Bauer NJ. Visual outcomes and patient satisfaction after cataract surgery with toric multifocal intraocular lens implantation. *J Cataract Refract Surg.* 2011;37:2034-2042.
- Shen Z, Lin Y, Zhu Y, Liu X, Yan J, Yao K. Clinical comparison of patient outcomes following implantation of trifocal or bifocal intraocular lenses: a systematic review and meta-analysis. *Sci Rep.* 2017;7:45337.
- Forte R, Ursolo P. The ReZoom multifocal intraocular lens: 2-year follow-up. *Eur J Ophthalmol.* 2009;19:380-383.
- C. Mesci, Y. Karakurt, N. Aydın, Z. Aslan, H. Acar HE. Diffraktif (Restor) ve Refraktif (Rezoom) Multifokal Göz İçeri Lenslerle Katarakt Ameliyatları Sonrası Görme Fonksiyonlarının Karşılaştırılması. *Glo-Kat.* 2009;4:183-188.
- Pepose JS, Qazi MA, Davies J, Doane JE, Loden JC, Sivalingham V, Mahmoud AM. Visual Performance of Patients with Bilateral vs Combination Crystalens, ReZoom, and ReSTOR Intraocular Lens Implants. *Am J Ophthalmol.* 2007;144:347-357.
- Akaishi L, Vaz R, Vilella G, Garcez RC, Tzelikis PE. Visual Performance of Tecnis ZM900 Diffractive Multifocal IOL after 2500 Implants: A 3-Year Followup. *J Ophthalmol.* 2010;2010.
- Pieh S, Marvan P, Lackner B, Hanselmayer G, Schmidinger G, Leitgeb R, Sticker M, Hitzenberger CK, Fercher AF, Skorpik C. Quantitative performance of bifocal and multifocal intraocular lenses in a model eye: point spread function in multifocal intraocular lenses. *Arch Ophthalmol.* 2002;120:23-28.
- Goes FJ. Visual results following implantation of a refractive multifocal IOL in one eye and a diffractive multifocal IOL in the contralateral eye. *J Refract Surg.* 2008;24:300-305.
- Hütz WW, Bahner K, Röhrig B, Hengerer F. The combination of diffractive and refractive multifocal intraocular lenses to provide full visual function after cataract surgery. *Eur J Ophthalmol.* 2010;20:370-375.
- Lubiński W, Podboraczyńska-Jodko K, Gronkowska-Serafin J, Karczewicz D. Visual outcomes three and six months after implantation of diffractive and refractive multifocal IOL combinations. *Klin Oczna.* 2011;113:209-215.
- Knorz MC. Multifocal intraocular lenses: overview of their capabilities,

- limitations, and clinical benefits. *J Refract Surg.* 2008;24:215-217.
35. Yoon SY, Song IS, Kim JY, Kim MJ, Tchah H. Bilateral mix-and-match versus unilateral multifocal intraocular lens implantation: Long-term comparison. *J Cataract Refract Surg.* 2013;39:1682-1690.
  36. Chen W, Meng Q, Ye H, Liu Y. Reading ability and stereoacuity with combined implantation of refractive and diffractive multifocal intraocular lenses. *Acta Ophthalmol.* 2011;89:376-381.
  37. Buckhurst PJ, Wolffsohn JS, Naroo SA, Davies LN, Bhogal GK, Kipioti A, Shah S. Multifocal Intraocular Lens Differentiation Using Defocus Curves. *Investig Ophthalmology Vis Sci.* 2012;53:3920-3926.
  38. Ravalico G, Baccara F, Rinaldi G. Contrast sensitivity in multifocal intraocular lenses. *J Cataract Refract Surg.* 1993;19:22-25.
  39. Terwee T, Weeber H, van der Mooren M, Piers P. Visualization of the retinal image in an eye model with spherical and aspheric, diffractive, and refractive multifocal intraocular lenses. *J Refract Surg.* 2008;24:223-232.
  40. Dick HB, Krummenauer F, Schwenn O, Krist R, Pfeiffer N. Objective and subjective evaluation of photic phenomena after monofocal and multifocal intraocular lens implantation. *Ophthalmology.* 1999;106:1878-1886.
  41. Aslan BS, Akyol N. Katarakt Cerrahisinde Multifokal Göziçi Lensleri ve Nöroadaptasyon. *Glo-Kat.* 2008;3:1-4.
  42. Yamauchi T, Tabuchi H, Takase K, Ohsugi H, Ohara Z, Kiuchi Y. Comparison of visual performance of multifocal intraocular lenses with same material monofocal intraocular lenses. *PLoS One.* 2013;8:e68236.



# Amniotic Membrane Transplantation in Surgical Treatment of Conjunctival Melanoma: Long-term Results

© Melis Palamar\*, © Banu Yaman\*\*, © Taner Akalın\*\*, © Ayşe Yağcı\*

\*Ege University Faculty of Medicine, Department of Ophthalmology, İzmir, Turkey

\*\*Ege University Faculty of Medicine, Department of Pathology, İzmir, Turkey

## Abstract

**Objectives:** To investigate the long-term efficacy and results of surgical management of conjunctival melanoma reconstructed with amniotic membrane transplantation.

**Materials and Methods:** Conjunctival melanoma in 10 patients (5 female, 5 male) was totally excised with adjunctive cryotherapy to the surgical margins, corneal epitheliectomy with absolute alcohol in cases of corneal involvement, lamellar sclerectomy in cases with episcleral involvement, and ocular surface grafting with cryopreserved amniotic membrane. Complications and tumor control rates were evaluated.

**Results:** The mean age of the patients was  $57.4 \pm 15.2$  (range, 37-84) years. The mean diameter of the tumors was  $15.5 \pm 4.9$  (range, 10-25) mm and histopathologically confirmed complete excision was performed in all cases. Mild limbal stem cell deficiency (2 eyes) and subclinical symblepharon (3 eyes) were observed as long-term complications. In a mean follow-up of  $56.7 \pm 40.4$  (range, 30-132) months, only one local tumor recurrence was detected. Despite retreatment, exenteration was performed in this patient due to re-recurrence. One patient died due to disseminated metastasis despite the absence of local recurrence.

**Conclusion:** In large conjunctival melanomas, reconstruction of the ocular surface is usually very challenging. The use of cryopreserved amniotic membrane for conjunctival defect repair is safe and effective with mild complications, and allows the excision of wider margins around the tumor.

**Keywords:** Amniotic membrane, conjunctiva, cryotherapy, melanoma, tumor

## Introduction

Although conjunctival melanoma is rare, it is the most malignant tumor of the ocular surface. It can arise from primary acquired melanosis (PAM), preexisting conjunctival nevus, or de novo.<sup>1,2,3</sup> It manifests with a painless melanotic or amelanotic mass on the ocular surface and is usually accompanied by a persistent dilated feeder blood vessel.<sup>1,2,3</sup> It can originate from all three parts of conjunctiva (bulbar, fornical, tarsal), or from the caruncle.<sup>1</sup>

In the treatment of conjunctival melanoma, total tumor resection is essential for avoiding local invasion, recurrence, and metastasis. Surgical management of conjunctival melanoma includes tumor resection using no-touch technique and

achieving tumor free margins, partial lamellar sclerectomy, double freeze thaw cryotherapy, and corneal epitheliectomy with alcohol for tumors located at the limbal region. Conjunctival defect might be closed either primarily or with conjunctival flap, a graft from the opposite conjunctiva, oral mucosa, or amniotic membrane (AM), depending on the defect size.<sup>1,2,3</sup> All these methods have both advantages and disadvantages.<sup>4</sup>

De Roth<sup>5</sup> described the use of fetal membrane allografts for ophthalmic purposes. Tseng et al.<sup>6,7</sup> later reported using AM transplantation (AMT) for the surgical treatment of pterygia, corneal defects, symblepharon, and neoplasia. The structural and biochemical composition of AM induces epithelisation by acting as a substrate for epithelial cell growth

**Address for Correspondence:** Melis Palamar MD, Ege University Faculty of Medicine, Department of Ophthalmology, İzmir, Turkey  
Phone: +90 530 408 50 51 E-mail: melispalamar@hotmail.com **ORCID-ID:** orcid.org/0000-0002-2494-0131

**Received:** 09.03.2017 **Accepted:** 07.06.2017

©Copyright 2018 by Turkish Ophthalmological Association  
Turkish Journal of Ophthalmology, published by Galenos Publishing House.

and also works as an antiangiogenic, antiinflammatory, and antifibrotic agent.<sup>7,8</sup> The use of AM is safe if the preparation is done according to the standard protocol.<sup>6,7,8</sup>

There are various reports on the use of AMT for ocular surface reconstruction in conjunctival melanoma. However, the long-term results of this method (in four patients) are reported in only one article.<sup>9</sup> Herein, we report the long-term success (over 30 months, up to 132 months) and outcomes of conjunctival melanoma surgical management, reconstructed with cryopreserved AM.

## Materials and Methods

Ten patients (10 eyes) who underwent resection of conjunctival melanoma and reconstruction with AMT between January 2005 and September 2013 were included in the study. All operations were performed by the same surgeons. Anterior segment slit-lamp examination and ocular surface staining with fluorescein were performed at every follow-up visit. Any problems regarding ocular surface homeostasis and any signs of complications or recurrences were noted. The patients' findings, ocular surface photographs, histopathologic slides, and any possible extension of melanoma into surrounding tissues such as the eyelid, lacrimal sac, or orbit were retrospectively analysed. Every tumor was staged using American Joint Committee on Cancer (AJCC) classification.<sup>10</sup> Success was defined as complete epithelisation of the wound with no significant accompanying complications or recurrence of the tumor. All patients underwent head-neck examination and soft tissue ultrasonography in order to detect any regional or lymphatic involvement, and systemic evaluation was performed in order to detect any metastasis. None of the patients had any detectable metastatic disease prior to excision.

All surgeries were performed under local anesthesia. All melanomas were excised using "no touch" technique with at least 2 mm safe margins (clinically normal conjunctiva).<sup>11,12</sup> All resected specimens were sent for histopathological evaluation. In order to destroy any residual tumor cells, double freeze-thaw cryotherapy was applied to the conjunctival margins. In cases with corneal involvement, absolute alcohol corneal epitheliectomy was performed prior to tumor excision. In cases with scleral involvement, lamellar sclerectomy was performed and absolute alcohol was applied for 30 seconds to the excised tumor area. The conjunctival defects were repaired with cryopreserved single-layer AM placed stromal side down and fixed with 8/0 vicryl sutures. Largest AM diameter varied between 14 and 28 mm according to defect size. A pressure bandage was applied for 3 days. Topical antibiotic and corticosteroid eye drops were used 4 times a day for 1 month. No additional topical treatment, including interferon alpha-2b or mitomycin C, was used. Postoperative examinations were performed at 2 weeks, 4 weeks, 3 months, and every 6 months thereafter in order to detect any complications or local recurrences. Limbal stem cell deficiency was diagnosed in the

presence of findings of superficial corneal vascularisation with whorled epithelium at the excision area.

Informed consent was obtained from all subjects participating in the study. This retrospective study was conducted in accordance with the Declaration of Helsinki of 1975 (as revised in Tokyo in 2004). Ege University Ethics Committee.

## Results

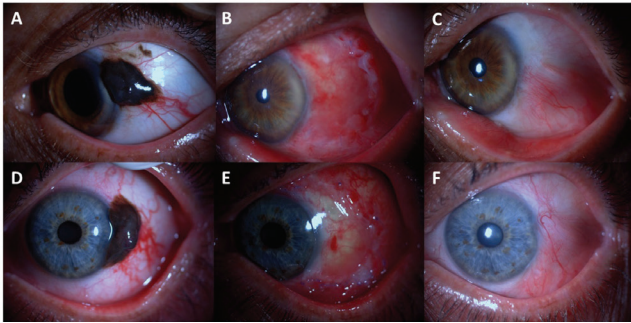
The mean age of the 10 patients (5 female, 5 male) was  $57.4 \pm 15.2$  (range, 37-84) years. The right eye was affected in 4 patients and the left in 6 patients. According to the AJCC 8<sup>th</sup> edition classification for conjunctival melanoma, 3 of the tumors were T1c (>2 but <3 quadrants), 4 were T1d (>3 quadrants), and 3 were T2b (noncaruncular and  $\geq 1$  quadrant nonbulbar conjunctiva).<sup>10</sup> No local invasions to the surrounding tissues or orbit, or lymph node metastases were present prior to surgery. However, 2 patients had history of incomplete excision elsewhere.

Histopathologically confirmed complete tumor excision was achieved in all eyes (100%). The mean diameter of the tumors was  $15.5 \pm 4.9$  (range, 10-25) mm. In 3 cases, the fornical conjunctiva was involved. The limbal area was invaded in 8 cases (80%). The mean limbal involvement was  $4 \pm 2.5$  (range, 2-8) clock hours. The tumor invaded the cornea in 6 cases (60%) and corneal epitheliectomy was required. In 5 cases (50%), lamellar sclerectomy and absolute alcohol to the tumor base were also performed due to scleral involvement. Histopathologic types of the tumors were epitheloid in 1 eye and mixed in 9 eyes. Primary pathological tumor diagnosis according to AJCC 8<sup>th</sup> edition was T1a for 5 tumors (50%), T1b for 2 (20%), T2a for 2 (20%), T2b for 1 (10%) tumor. Mean tumor thickness was  $1.82 \pm 0.70$  (range, 1.13-3.00) mm.

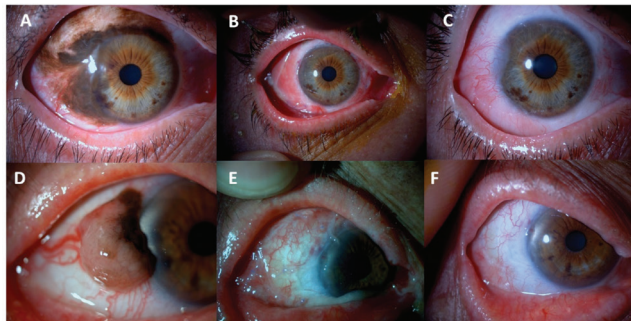
No intraoperative complications were observed. The AM covered the surgical defect in all cases. Ocular surface irritation and mild lacrimation resolved in 2-3 weeks. In a mean follow-up of  $56.7 \pm 40.4$  (range, 30-132) months, one local recurrence was detected. Exenteration was performed in this patient, who had undergone two surgeries elsewhere prior to our surgical treatment. She is still alive after 20 months with no metastasis. One patient died due to disseminated metastasis although no recurrence was evident in the eye.

No recurrence was observed in the remaining 8 patients in a follow-up time of  $58.78 \pm 44.4$  (range, 30-132) months. The patients reported no signs or symptoms related to the ocular surface and all were satisfied with their cosmetic appearance. All exhibited a healthy ocular surface with no inflammation or dry eye symptoms (Figure 1A-F). Mild limbal stem cell deficiency with no ocular vision disturbance was detected in 3 eyes with tumors invading more than 180 degrees of the limbus (Figure 2A-C). Symblepharon which did not interfere with eye movements was diagnosed in 2 eyes. All ocular surfaces except the two with symblepharon were smooth (Figure 2D-F).





**Figure 1.** A) Preoperative picture of a 58-year-old male with conjunctival melanoma involving the temporal conjunctiva arising from primary acquired melanosis. B) Early postoperative picture showing the amniotic membrane. C) Late postoperative (22 months) appearance of the eye. D) Preoperative picture of a 55-year-old male with conjunctival melanoma involving the temporal conjunctiva arising from a nevus. E) Early postoperative picture showing the ocular surface and amniotic membrane. F) Late postoperative (32 months) appearance of the eye



**Figure 2.** A) Preoperative picture of a 50-year-old male with extensive conjunctival melanoma arising from primary acquired melanosis. B) Early postoperative picture showing the ocular surface. C) Late postoperative (20 months) appearance of the eye with evident superotemporal limbal stem cell deficiency; D) Preoperative picture of an 84-year-old female with conjunctival melanoma. E) Early postoperative picture showing the amniotic membrane. F) Late postoperative (30 months) appearance of the eye

## Discussion

Conjunctival melanoma demonstrates many clinical variabilities. Shields et al.<sup>2</sup>, reported the mean age at presentation to be 61 years in 382 conjunctival melanoma patients (48% male, 52% female). Most of the melanomas had originated from PAM (76%), followed by nevus (6%) and de novo (17%).<sup>2</sup> In the present study, the male-female ratio was 1:1, and 70% of the tumors arose from PAM, 20% were de novo, and 10% originated from nevus.

Conjunctival melanoma can develop on any part of the conjunctiva (bulbar, forniceal or tarsal) or in the caruncle. In an analysis of 382 conjunctival melanomas, the AJCC classification distribution was T1: 57%, T2: 32%, and T3: 11%.<sup>13</sup> Invasion of the melanoma was observed in the corneal epithelium (40%), corneal stroma (3%), sclera (3%), eyelid (1%), orbit (2%), and canaliculus/lacrimal sac (1%).<sup>13</sup> Twenty percent of the tumors were nonpigmented, 59% were pigmented, and 21% were mixed.<sup>13</sup> In the present study, the

mean diameter of the tumors was  $15.5 \pm 4.9$  (range, 10-25) mm. The corneal stroma was invaded in 6 eyes (60%) and the sclera in 5 eyes (50%). Forniceal conjunctiva was involved in 3 cases (30%). No eyelid, orbit, canaliculus or lacrimal sac involvement was observed. The tumor was pigmented in 8 (80%) and mixed in 2 (20%) cases.

The successful treatment of conjunctival melanoma depends on the extension of the tumor. Important rules of conjunctival melanoma surgery are to use the no-touch technique and to let the ocular surface dry until the tumor is completely removed so as to not seed the malignancy.<sup>1,2</sup> For larger tumors involving the forniceal area, excision should be more generous and tumor-free margins should be ascertained. Conjunctival flaps, contralateral eye conjunctival grafts, buccal mucosa, or AMT might be used for reconstruction of these defects.<sup>1,2</sup> However, the main disadvantage of autologous grafts and flaps is the insufficiency of the utilisable tissue.<sup>14</sup> Furthermore, excising large enough conjunctival autografts might cause donor site morbidity.<sup>15</sup> Besides, many patients are not eager to have their healthy eye manipulated. Moreover, thick mucosal grafts usually cause unsatisfactory cosmetic results and also inhibit visualisation of the underlying structures for early recurrence detection.<sup>15</sup> Thus, AM is a nearly perfect reconstruction material for large conjunctival tumors.

The good success and efficacy of AM for ocular surface reconstruction are due to enhanced epithelisation, antiinflammatory, antifibrotic, and antiangiogenic effects.<sup>16</sup> Epithelisation is promoted by the basement membrane of the AM, which inhibits epithelial apoptosis and serves as a substrate for normal migration, differentiation, and adhesion of epithelial cells.<sup>17</sup> On the other hand, the stromal portion promotes ocular surface healing by producing various growth factors such as epidermal growth factor, hepatocyte growth factor, basic fibroblast growth factor, and keratinocyte growth factor.<sup>18</sup> The antiinflammatory activity of AM may be attributed to the presence of receptor antagonists of inflammatory mediators.<sup>19</sup> The downregulation of transforming growth factor  $\beta$  signaling and the suppression of fibroblast differentiation to myofibroblasts are responsible for the anti-scarring effect.<sup>20</sup>

The antiangiogenic effects of AM are a result of the expression of tissue metalloproteinase and endostatin inhibitors, as well as proteins which stimulate corneal epithelial proliferation and suppress vascular endothelial cell growth.<sup>21</sup> Moreover, AM has been proven to not only reduce inflammation but also enable goblet and non-goblet cell repopulation.<sup>22,23</sup>

Metastatic disease and local recurrence of conjunctival melanoma are usually detected in eyes with tumors located in the forniceal, caruncular, or tarsal regions and those with histopathologically tumor-positive margins.<sup>2</sup> Even with total microscopic excision of the lesion, further disease is reported to develop from associated PAM in 26% of patients in 5 years and

65% of patients in 15-year follow-up.<sup>2</sup> Numerous recurrences require orbital exenteration. Neighbouring (preauricular or submandibular) lymph nodes, lung, brain, and liver are the most common sites of metastasis. In our series, a patient who underwent two inadequate operations elsewhere (T1d AJCC stage) developed recurrence at 20 months and exenteration was performed. One patient (T1c AJCC stage) died due to disseminated metastasis (preauricular lymph node, lung, brain) although the eye was apparently normal for 37 months. No recurrence or metastasis were observed in the remaining 8 patients in a follow-up time of  $58.78 \pm 44.4$  months. At the last follow-up, no surgery-related problems were reported and all patients were happy with the cosmetic appearance, similar to the results of Dalla Pozza et al.<sup>9</sup>

## Conclusion

In conclusion, although AMT itself is not directly related to outcome in terms of local tumor control, it provides a more generous amount of tissue for conjunctival reconstruction in especially extensive conjunctival melanoma and promises a healthy ocular surface. In most cases, complete homeostasis of the ocular surface with no complications can be achieved.

## Ethics

**Ethics Committee Approval:** Ege University Ethics Committee (13 March 2017 17-2/16).

**Informed Consent:** It was taken.

**Peer-review:** Externally and internally peer-reviewed.

## Authorship Contributions

Concept: Melis Palamar, Ayşe Yağcı, Design: Melis Palamar, Ayşe Yağcı, Data Collection or Processing: Melis Palamar, Banu Yaman, Analysis or Interpretation: Melis Palamar, Banu Yaman, Taner Akalın, Ayşe Yağcı, Literature Search: Melis Palamar, Writing: Melis Palamar, Banu Yaman.

**Conflict of Interest:** No conflict of interest was declared by the authors.

**Financial Disclosure:** The authors declared that this study received no financial support.

## References

- Shields JA, Shields CL. Eyelid, Conjunctival, and Orbital Tumors. An Atlas and Textbook. 2nd ed. Philadelphia: Lippincott Williams and Wilkins; 2008.
- Shields CL, Markowitz JS, Belinsky I, Schwartzstein H, George NS, Lally SE, Mashayehi A, Shields JA. Conjunctival melanoma. Outcomes based on tumor origin in 382 consecutive cases. *Ophthalmology*. 2011;118:389-395.
- Shields CL, Kels JG, Shields JA. Melanoma of the eye: Revealing hidden secrets, one at a time. *Clin Dermatol*. 2015;33:183-196.
- Asoklis RS, Damijonaityte A, Butkiene L, Makselis A, Petroska D, Pajaujisi M, Juodkaite G. Ocular surface reconstruction using amniotic membrane following excision of conjunctival and limbal tumors. *Eur J Ophthalmol*. 2011;21:552-558.
- De Roth A. Plastic repair of conjunctival defects with fetal membrane. *Arch Ophthalmol*. 1940;23:522-525.
- Prabhasawat P, Barton K, Burkett G, Tseng SC. Comparison of conjunctival autografts, amniotic membrane grafts, and primary closure for pterygium excision. *Ophthalmology*. 1997;104:974-985.
- Tseng SC, Prabhasawat P, Lee SH. Amniotic membrane transplantation for conjunctival surface reconstruction. *Am J Ophthalmol*. 1997;124:765-774.
- Dua HS, Azuara-Blanco A. Amniotic membrane transplantation. *Br J Ophthalmol*. 1999;83:748-752.
- Dalla Pozza G, Ghirlando A, Busato F, Midena E. Reconstruction of conjunctiva with amniotic membrane after excision of large conjunctival melanoma: a long-term study. *Eur J Ophthalmol*. 2005;15:446-450.
- AJCC Cancer Staging Manual (8th ed). Switzerland; Springer; 2017:795-803.
- Azuara-Blanco A, Pillai CT, Dua HS. Amniotic membrane transplantation for ocular surface reconstruction. *Br J Ophthalmol*. 1999;83:399-402.
- Shields JA, Shields CL, De Potter P. Surgical management of conjunctival tumors. The 1994 Lynn B. McMahan Lecture. *Arch Ophthalmol*. 1997;115:808-815.
- Shields CL, Kaliki S, Al-Daamash SA, Lally SE, Shields JA. American Joint Committee on Cancer (AJCC) Clinical Classification Predicts Conjunctival Melanoma Outcomes. *Ophthalm Plast Reconstr Surg*. 2012;5:313-323.
- Palamar M, Kaya E, Egrilmez S, Akalin T, Yagci A. Amniotic membrane transplantation in surgical management of ocular surface squamous neoplasias: long-term results. *Eye (Lond)*. 2014;28:1131-1135.
- Gündüz K, Ucakhan OO, Kanpolat A, Gunalp I. Nonpreserved human amniotic membrane transplantation for conjunctival reconstruction of extensive ocular surface neoplasias. *Eye (Lond)*. 2006;20:351-357.
- Dua HS, Gomes JA, Kinnig AJ, Maharajan VS. The amniotic membrane in ophthalmology. *Surv Ophthalmol*. 2004;49:51-77.
- Grueterich M, Tseng SCG. Human limbal progenitor cells expanded on intact amniotic membrane ex-vivo. *Arch Ophthalmol*. 2002;120:783-790.
- Koizumi NJ, Inatomi TJ, Sorozono CJ, Fullwood NJ, Quantock AJ, Kinoshita S. Growth factor mRNA and protein in preserved human amniotic membrane. *Curr Eye Res*. 2000;20:173-177.
- Lee SB, Li DQ, Tan DT, Meller DC, Tseng SC. Suppression of TGF signalling in both normal conjunctival fibroblasts and pterygial body fibroblasts by amniotic membrane. *Curr Eye Res*. 2000;20:325-334.
- Tseng SC, Li DQ, Max X. Suppression of transforming growth factor-beta isoforms, TGF- receptor II, and myofibroblast differentiation in cultured human corneal and limbal fibroblasts by amniotic membrane matrix. *J Cell Physiol*. 1999;179:325-335.
- Hao Y, Ma DH, Hwang DG, Kim WS, Zhang F. Identification of antiangiogenic and antiinflammatory proteins in human amniotic membrane. *Cornea*. 2000;19:348-352.
- Barabino S, Rolando M. Amniotic membrane transplantation elicits goblet cell repopulation after conjunctival reconstruction in a case of severe ocular cicatricial pemphigoid. *Acta Ophthalmol Scand*. 2003;81:68-71.
- Meller D, Dabul V, Tseng SC. Expansion of conjunctival epithelial progenitor cells on amniotic membrane. *Exp Eye Res*. 2002;74:537-545.



# The Profile and Management of Glaucoma in Adult Aphakic Patients Following Complicated Cataract Surgery

Ümit Ekşioğlu\*, Mehmet Yakın\*, Özgür Balta\*\*, Evin Şingar-Özdemir\*, Hande Hüsnüye Telek\*,  
Firdevs Örnek\*, Ilgaz Yalvaç\*\*\*

\*University of Health Sciences, Ankara Training and Research Hospital, Ophthalmology Clinic, Ankara, Turkey

\*\*Dr. Nafiz Korez Hospital, Ophthalmology Clinic, Ankara, Turkey

\*\*\*Yeditepe University Faculty of Medicine, Department of Ophthalmology, İstanbul, Turkey

## Abstract

**Objectives:** To determine the profile and clinical course of glaucoma in adult aphakic patients following complicated cataract surgery.

**Materials and Methods:** Retrospective chart review of 22 adult aphakic patients (29 eyes) with glaucoma.

**Results:** Mean age was 57.69±14.18 years when aphakia occurred. Mean age at time of presentation to our glaucoma clinic was 62.57±12.47 years. Mean follow-up time was 42.83±57.04 months. Changes between the first and last follow-up visits were as follows: mean intraocular pressure decreased from 26.21±13.86 mmHg to 18.14±9.63 mmHg (p=0.003); mean number of glaucoma medications used increased from 1.41±1.27 to 2.07±1.04 (p=0.005); and mean vertical cup/disc ratio increased from 0.69±0.25 to 0.78±0.24 (p=0.024). Glaucoma was managed using medications in 26 eyes (89.7%), whereas 3 eyes underwent surgical treatment. However, surgery alone was not sufficient to control intraocular pressure and additional glaucoma medications were needed.

**Conclusion:** Prevention of glaucomatous optic neuropathy in aphakic patients is challenging both medically and surgically. Although a significant decrease in intraocular pressure can be achieved with glaucoma medications, glaucomatous disc changes may progress.

**Keywords:** Aphakia, glaucoma, secondary glaucoma, complicated cataract surgery

## Introduction

The success rate of cataract surgery has improved along with advances in microsurgical techniques. The aim of modern cataract surgery, in most cases, is to implant an artificial lens in the capsular bag. Rarely, cataract surgery results in aphakia due to intraoperative complications. However, in some cases aphakia is preoperatively planned, including cases with congenital cataract, high myopia, traumatic cataract, and aphakia in the fellow eye.

Aphakia causes complex mechanical and biochemical changes in the vitreous and anterior segment structures and the precise mechanism of glaucoma in aphakia is not fully understood.<sup>1,2,3,4</sup> Aphakic glaucoma is a rare secondary glaucoma associated with poor control of intraocular pressure (IOP) using ocular hypotensive agents; glaucoma surgery in such patients is less successful than in those with primary glaucomas.<sup>5,6,7,8,9</sup>

The aim of the present study was to determine the profile and clinical course of glaucoma in adult aphakic patients following complicated cataract surgery.

## Materials and Methods

This study was conducted at Ankara Training and Research Hospital, Ophthalmology Clinic, Glaucoma Clinic in Ankara, Turkey. The study was approved by the review board of the hospital and performed in accordance with the principles of the Declaration of Helsinki. The study included 29 eyes of 22 adult aphakic patients who presented between 1990 and 2011 due to glaucoma following complicated cataract surgery. Patients' data were retrospectively reviewed. Glaucoma specialists performed detailed ophthalmological examination of each patient, including assessment of best corrected distance visual acuity (BCVA) via

**Address for Correspondence:** Mehmet Yakın MD, University of Health Sciences, Ankara Training and Research Hospital, Ophthalmology Clinic, Ankara, Turkey  
Phone: +90 505 649 71 26 E-mail: yakinmehmet@hotmail.com **ORCID-ID:** orcid.org/0000-0002-3470-4124

**Received:** 11.05.2017 **Accepted:** 28.07.2017

©Copyright 2018 by Turkish Ophthalmological Association  
Turkish Journal of Ophthalmology, published by Galenos Publishing House.

Snellen chart, IOP measurement via Goldmann applanation tonometer, and anterior segment examination via slit-lamp biomicroscopy. Gonioscopy and fundoscopic examination was performed whenever possible. The visual acuities were expressed in decimal notation. Visual field testing could not be performed because of poor visual acuity in most of the eyes. Demographic data and the number of glaucoma medications used were recorded for each patient. Glaucoma was diagnosed based on chronic elevation of IOP with glaucomatous optic disc changes. Clinical changes from presentation to the last follow-up visit were compared.

**Statistical Analysis**

Data were analyzed using SPSS v.17.0 for Windows (SPSS, Inc., Chicago, IL, USA). Quantitative variables are shown as mean ± standard deviation (range), and categorical data are shown as numbers and percentages. Fisher’s exact test was used to determine differences between categorical data. The Wilcoxon signed-rank test was used to compare two dependent variables. The level of statistical significance was set at p<0.05 (two-tailed distribution).

**Results**

The study included 29 eyes (58.6% right eyes and 41.4% left eyes) of 22 patients (54.6% male and 45.5% female). Mean age of the patients when aphakia occurred was 57.69±14.18 years (median 60 years, range 30-80 years). In all, 3 patients (1 eye each) had a history of glaucoma, 1 of which underwent trabeculectomy prior to aphakia. In the remaining 26 eyes, mean time from occurrence of aphakia to diagnosis of glaucoma was 89.00±134.17 months (median 8 months, range 0-300 months). Mean age at presentation to the glaucoma clinic was 62.57±12.47 years (median 64 years, range 30-81 years).

Mean duration of follow-up was 42.83±57.04 months (range 1-192 months). Glaucoma was managed using topical anti-glaucomatous medications in 26 eyes (89.7%). In total, 3 eyes of 3 patients underwent surgical treatment for elevated IOP despite meticulous use of glaucoma medications. Fundoscopy could not be performed because of corneal edema and/or corneal opacities in 6 of 26 eyes treated medically and in 1 of the 3 eyes treated surgically. The ocular findings of all eyes at time of admission are summarized in Table 1. Thirteen eyes (44.8%) had peripheral anterior synechia while 5 eyes (17.3%) had vitreous in the anterior chamber, which may clarify the glaucoma mechanism (Table 1).

The mean IOP of all eyes included in the study was 26.21±13.86 mmHg (range, 6-65 mmHg) at presentation, versus 18.14±9.63 mmHg (range, 8-50 mmHg) at last follow-up visit (p=0.003). Twenty eyes (69%) were being treated with antiglaucoma medications at time of presentation, versus all eyes (100%) at last follow-up visit. Mean number of glaucoma medications used was 1.41±1.27 (range: 0-4) at presentation and 2.07±1.04 (range: 1-4) at last follow-up visit (p=0.005). Mean vertical cup/disc (C/D) ratio was 0.69±0.25 (range: 0.3-1) at presentation versus 0.78±0.24 (range: 0.3-1) at last follow-up

visit (p=0.024). Vertical C/D ratio was ≥0.7 in 9 eyes (45%) at presentation and in 11 eyes (55%) at last follow-up visit (p=0.002).

Among the medically treated eyes, BCVA improved in 2 eyes during follow-up because of improvement in comorbid diabetic macular edema, whereas ocular comorbidities other than progression of glaucoma (dry-type age-related macular degeneration in one eye and wet-type age-related macular degeneration in the other) caused a reduction in BCVA in 2 eyes. In the remaining 22 medically treated eyes, mean BCVA was 0.23±0.31 (0-1) at presentation, versus 0.18±0.29 (0-1) at last follow-up visit (p=0.624). Table 2 shows the clinical changes from presentation to last follow-up visit in medically treated eyes.

Findings of the eyes which were treated surgically are shown in Table 3. In one of these eyes, Molteno aqueous shunt implantation was performed at another clinic and the associated findings were not available in the patient’s chart. At presentation, this eye had corneal edema, corneal leukoma, vitreous in the

**Table 1. Ocular findings of patients at admission**

	Medically treated eyes n=26 (89.7%)		Surgically treated eyes n=3 (10.3%)	
	n	%	n	%
Anterior segment findings				
Corneal edema and/or opacities	9	34.6	1	33.3
Peripheral anterior synechia	13	50.0	0	0
Vitreous in the anterior chamber	3	11.5	2	66.7
Posterior segment findings				
Could not be evaluated	6	23.1	1	33.3
Cup/disc ratio ≥0.7	9	45.0*	2	100*
Other comorbidities				
Diabetic retinopathy	3	15.0*	0	0*
Age-related maculopathy	1	5.0*	0	0*
Degenerative myopia	1	5.0*	0	0*

\*Percentage of eyes in which fundoscopic examination could be performed

**Table 2. Clinical changes from presentation to the last follow-up visit in the medically treated eyes**

	At presentation mean (range)	At last follow-up visit mean (range)	p
BCVA*	0.065 (0-1)	0.02 (0-1)	0.624
IOP (mmHg)	22.5 (6-65)	15 (8-50)	0.003
Medication (n)	1 (0-4)	2 (1-4)	0.005
C/D ratio**	0.7 (0.3-1)	0.8 (0.3-1)	0.014

\*BCVA was assessed in 22 eyes. \*\*C/D ratio was assessed in 20 eyes.  
BCVA: Best corrected distance visual acuity, IOP: Intraocular pressure, C/D ratio: Cup/disc ratio

**Table 3. Findings before and after surgery in eyes treated surgically.**

	Eye 1 (Molteno implant)		Eye 2 (Trab with MMC)		Eye 3 (Trab with MMC)	
	Before surgery	After surgery	Before surgery	After surgery	Before surgery	After surgery
BCVA	N/A	NLP	0.2	0.1	0.01	0.01
IOP (mmHg)	N/A	20	50	20	31	18
Medication (n)	N/A	2	3	1	3	3
Anterior segment	N/A	Corneal edema and leukoma, vitreous in the anterior chamber	No extra pathological finding	No extra pathological finding	Vitreous in the anterior chamber	Vitreous in the anterior chamber
C/D ratio	N/A	N/A	0.9	1	1	1
Follow-up (mo)	N/A	75	1	4	0	6

BCVA: Best corrected visual acuity, IOP: Intraocular pressure, C/D ratio: Cup/disc ratio, Trab: Trabeculectomy, MMC: Mitomycin-C, NLP: No light perception, N/A: Not available

anterior chamber, and no light perception. Fundus examination could not be performed because of corneal edema and leukoma. The patient was followed for 75 months and IOP was controlled with 2 medications during follow-up. The other two surgically treated eyes underwent trabeculectomy with adjunctive use of mitomycin C at our clinic. Surgery alone was not sufficient to control IOP and additional medications were required. No surgery-related complications were encountered.

## Discussion

Glaucoma in aphakic patients was among the most common causes of secondary glaucoma prior to advances in modern cataract surgery, which resulted in a significant decline in the incidence of post-surgical aphakia.<sup>5,10</sup> Recent studies of aphakic glaucoma have mostly focused on pediatric cases following congenital cataract surgery, whereas the literature concerning aphakic glaucoma in adults is relatively outdated.

Some ocular comorbidities, including corneal opacities, dense cataract, glaucoma, high myopia, previous vitrectomy, and traumatic cataract, may increase the risk of aphakia during cataract surgery in adults.<sup>11</sup> It has been shown that glaucoma together with dense cataract presents the highest risk for aphakia during cataract surgery.<sup>11</sup> In the present study, three patients had a history of glaucoma and one patient had degenerative myopia prior to cataract surgery.

Several mechanisms have been implicated in aphakic glaucoma, including pupillary block glaucoma, malignant glaucoma, ghost cell glaucoma, vitreous in the anterior chamber, epithelial ingrowth, and protracted inflammation; however, these are not present in a significant number of patients.<sup>4,9,12,13</sup> In some studies, synechial closure of the angle was reported as the most common finding in aphakic glaucomatous eyes, as in our study (Table 1).<sup>9,14</sup> In the present study, none of the previously described mechanisms were observed in 11 (37.9%) eyes. Some researchers have posited theories suggesting that exposure of the anterior chamber to the posterior chamber is associated with certain chemical factors that alter angle structure and function, but none has yet been proven.<sup>1</sup>

IOP control and prevention of optic nerve damage with ocular hypotensive agents are often more difficult than in cases

with primary glaucomas. It is thought that a 30% reduction in IOP is required for preventing glaucomatous optic neuropathy in a significant number of glaucoma patients.<sup>6</sup> In the present study, although a 33% decrease in IOP was achieved in the medically treated eyes, there was a significant increase in C/D ratio and a slight decrease in visual acuity (although nonsignificant). This may be because of most of the patients referred to our clinic had advanced glaucomatous optic neuropathy, and a lower target IOP level should be considered in these patients.

Because surgical management of glaucoma in aphakia is difficult, numerous surgical procedures have been used to control glaucoma progression.<sup>6,8,13,15,16,17,18</sup> The success rate of trabeculectomy in aphakic glaucoma varies by study. Some studies reported trabeculectomy as a successful option, while others did not.<sup>6,8,15,16,19</sup> In the present study, trabeculectomy was performed in two eyes, but in both cases the procedure was not sufficient to control IOP and additional medications were required.

Glaucoma drainage devices (GDDs) have been used successfully in cases of aphakic glaucoma.<sup>20,21,22,23,24</sup> Tube occlusion due to vitreous incarceration is an important cause of failure of GDDs in aphakic eyes.<sup>20,21,25</sup> In the present study, Molteno implantation was performed in one eye at another clinic and despite the presence of vitreous in the anterior chamber, IOP was controlled with two medications during follow-up.

The long average interval between glaucoma diagnosis and presentation to our glaucoma clinic was notable in our study. Most of the patients diagnosed and referred to our glaucoma clinic had late-stage disease and most of the eyes had poor visual acuity at presentation.

## Conclusion

Most of the patients in our study presented with poor vision and advanced-stage glaucomatous changes. As it is difficult to detect peripheral narrowing of the visual field in aphakic patients, IOP and optic disc changes should be assessed regularly to detect glaucoma early. Although a favorable decrease in IOP can be achieved using glaucoma medications, glaucomatous disc changes can progress in aphakia, especially in patients with late-stage disease. Because the management of glaucoma in aphakic

patients can be more difficult than that of primary glaucomas, early referral to a glaucoma specialist should be considered in all cases of suspected glaucoma.

#### Ethics

**Ethics Committee Approval:** University of Health Sciences, Ankara Training and Research Hospital (11.20.2016 approval number: 5232).

**Informed Consent:** Retrospective study.

**Peer-review:** Externally peer-reviewed.

#### Authorship Contributions

**Concept:** Ümit Ekşioğlu, Mehmet Yakın, Özgür Balta, Evin Şingar-Özdemir, Hande Hüsnüye Telek, Firdevs Örnek, İlgez Yalvaç, **Design:** Ümit Ekşioğlu, Mehmet Yakın, Özgür Balta, Evin Şingar-Özdemir, Hande Hüsnüye Telek, Firdevs Örnek, İlgez Yalvaç, **Data Collection or Processing:** Mehmet Yakın, **Analysis or Interpretation:** Mehmet Yakın, Ümit Ekşioğlu, **Literature Search:** Mehmet Yakın, **Writing:** Mehmet Yakın, Ümit Ekşioğlu.

**Conflict of Interest:** No conflict of interest was declared by the authors.

**Financial Disclosure:** The authors declared that this study received no financial support.

#### References

- Levin AV. Aphakic glaucoma: a never-ending story. *Br J Ophthalmol.* 2007;91:1574-1575.
- Michaelides M, Bunce C, Adams GG. Glaucoma following congenital cataract surgery-the role of early surgery and posterior capsulotomy. *BMC Ophthalmol.* 2007;7:13.
- Chen TC, Bhatia LS, Halpern EF, Walton DS. Risk factors for the development of aphakic glaucoma after congenital cataract surgery. *J Pediatr Ophthalmol Strabismus.* 2006;43:274-280.
- Buzney SM, Thomas JV. Effect of aphakia upon the vitreous. *Bull Soc Belge Ophthalmol.* 1987;223:197-210.
- Gadia R, Sihota R, Dada T, Gupta V. Current profile of secondary glaucomas. *Indian J Ophthalmol.* 2008;56:285-289.
- Gross RL, Feldman RM, Spaeth GL, Steinmann WC, Spiegel D, Katz LJ, Wilson RP, Varma R, Moster MR, Marks S. Surgical therapy of chronic glaucoma in aphakia and pseudophakia. *Ophthalmology.* 1988;95:1195-1201.
- Herschler J. Management of glaucoma in the aphakic eye. *Int Ophthalmol Clin.* 1984;24:43-48.
- Melamed S, Neumann D, Blumenthal M. Trabeculectomy with anterior vitrectomy in aphakic and pseudophakic glaucoma. *Int Ophthalmol.* 1991;15:157-162.
- Tomey KE, Traverso CE. The glaucomas in aphakia and pseudophakia. *Surv Ophthalmol.* 1991;36:79-112.
- Agarwal HC, Sood NN, Kalra BR, Ghosh B. Secondary Glaucoma. *Indian J Ophthalmol.* 1982;30:121-124.
- Lundström M, Brege KG, Florén I, Lundh B, Stenevi U, Thorburn W. Postoperative aphakia in modern cataract surgery: part 1: analysis of incidence and risks based on 5-year data from the Swedish National Cataract Register. *J Cataract Refract Surg.* 2004;30:2105-2110.
- Chandler PA. Glaucoma from pupillary block in aphakia. *Trans Am Ophthalmol Soc.* 1961;59:96-105.
- Thomas R, Alexander TA, Thomas S. Aphakic malignant glaucoma. *Indian J Ophthalmol.* 1985;33:281-283.
- Agarwal HC, Sood NN, Dayal Y. Aphakic glaucoma. *Indian J Ophthalmol.* 1981;29:221-225.
- Singh D, Singh M. Pretrabecular filtration in aphakic glaucoma. *Indian J Ophthalmol.* 1978;26:17-21.
- Sharma SL, Singh T. Clinical evaluation of trabeculectomy operation in aphakic glaucoma. *Indian J Ophthalmol.* 1981;29:227-228.
- Hitchings RA. Acute aphakic pupil block glaucoma: an alternative surgical approach. *Br J Ophthalmol.* 1979;63:31-37.
- Schlote T, Grüb M, Kynigopoulos M. Long-term results after transscleral diode laser cyclophotocoagulation in refractory posttraumatic glaucoma and glaucoma in aphakia. *Graefes Arch Clin Exp Ophthalmol.* 2008;246:405-410.
- Heuer DK, Gressel MG, Parrish RK 2nd, Anderson DR, Hodapp E, Palmberg PF. Trabeculectomy in aphakic eyes. *Ophthalmology.* 1984;91:1045-1051.
- Scott IU, Alexandrakis G, Flynn HW Jr, Smiddy WE, Murray TG, Schiffman J, Gedde SJ, Budenz DL, Fantes F, Parrish RK. Combined pars plana vitrectomy and glaucoma drainage implant placement for refractory glaucoma. *Am J Ophthalmol.* 2000;129:334-341.
- Eslami Y, Mohammadi M, Fakhraie G, Zarei R, Moghimi S. Ahmed glaucoma valve implantation with tube insertion through the ciliary sulcus in pseudophakic/aphakic eyes. *J Glaucoma.* 2014;23:115-118.
- Varma R, Heuer DK, Lundy DC, Baerveldt G, Lee PP, Minckler DS. Pars plana Baerveldt tube insertion with vitrectomy in glaucomas associated with pseudophakia and aphakia. *Am J Ophthalmol.* 1995;119:401-407.
- Lloyd MA, Sedlak T, Heuer DK, Minckler DS, Baerveldt G, Lee MB, Martone JF. Clinical experience with the single-plate Molteno implant in complicated glaucomas. Update of a pilot study. *Ophthalmology.* 1992;99:679-687.
- Heuer DK, Lloyd MA, Abrams DA, Baerveldt G, Minckler DS, Lee MB, Martone JF. Which is better? One or two? A randomized clinical trial of single-plate versus double-plate Molteno implantation for glaucomas in aphakia and pseudophakia. *Ophthalmology.* 1992;99:1512-1519.
- Ang GS, Goh YW, Azuara-Blanco A. Recurrent vitreous occlusion of glaucoma drainage device tube in a patient with glaucoma in aphakia: a case report. *Cases J.* 2010;3:55.



# Characteristics of Anisometropic Patients with and without Strabismus

Reşat Duman\*, Huban Atilla\*\*, Emine Çatak\*\*\*

\*Afyon Kocatepe University Faculty of Medicine, Department of Ophthalmology, Afyonkarahisar, Turkey

\*\*Ankara University Faculty of Medicine, Department of Ophthalmology Ankara, Turkey

\*\*\*Eskişehir Eye Health and Disease Center, Ophthalmology Clinic, Eskişehir, Turkey

## Abstract

**Objectives:** To evaluate the risk factors for strabismus in patients with anisometropia by comparing degree of anisometropia, depth of amblyopia, and binocular visual function in anisometropic patients with and without strabismus.

**Materials and Methods:** Sixty-five anisometropic patients older than 5 years with amblyopia in one eye who were followed in the Ankara University Faculty of Medicine, Department of Ophthalmology, Pediatric Ophthalmology and Strabismus Unit between May 2009 and April 2010 were included in this study. There were 27 cases of strabismus. The depth of amblyopia, degree of anisometropia, and binocular visual function were assessed in anisometropic cases with and without strabismus.

**Results:** The 65 patients with anisometropia were divided into two groups: 27 patients with strabismus (group 1) and 38 patients without (group 2). Depth of amblyopia was greater in patients with strabismus compared to those without ( $p=0.006$ ). In patients with strabismus, there was no correlation between angle of deviation and depth of amblyopia ( $p=0.453$ ). In anisometropic amblyopia patients without strabismus, there was a positive correlation between depth of anisometropia and depth of amblyopia ( $p=0.35$ , Pearson's correlation coefficient= $0.343$ ). Comparison in terms of anisometropia showed that patients with strabismus had significantly larger spherical difference between the two eyes than in patients without strabismus ( $p=0.000$ , Mann-Whitney U test). There was no significant difference in terms of cylindrical values ( $p=0.146$ , Mann-Whitney U test). There was no statistically significant difference in the presence of fusion between anisometropic patients with and without strabismus.

**Conclusion:** The risk of developing strabismus increased as degree of anisometropia increased in anisometropic cases. In addition, depth of amblyopia was greater in anisometropic patients with strabismus.

**Keywords:** Anisometropia, strabismus, amblyopia

## Introduction

Anisometropia is a difference in refractive power between the two eyes, and is one of the main causes of amblyopia. This inconsistency between the eyes leads to differences in the size and quality of the images that fall on the fovea. Amblyopia can develop as a result of chronic blurriness in an eye with considerable refractive error.<sup>1</sup> Unilateral refractive error of  $\geq 1$  diopter (D) for hypermetropia,  $\geq \pm 2$  D for astigmatism, and  $\geq 3$  D for myopia presents a risk for amblyopia. The risk of amblyopia increases with greater difference in refractive power between the two eyes.<sup>2</sup>

Anisometropic amblyopia may occur together with strabismus amblyopia, and it is difficult to determine whether the amblyopia is primary (due to anisometropia), secondary (due to strabismus), or a combination of both. Not every anisometropic patient has strabismus. The presence of strabismus in anisometropic patients and associated risk factors have yet to be fully explained. The aim of this study is to compare depth of amblyopia, degree of anisometropia, and binocular visual function in anisometropic patients with and without strabismus, and to determine risk factors for the development of strabismus in this patient group.

**Address for Correspondence:** Reşat Duman MD, Afyon Kocatepe University Faculty of Medicine, Department of Ophthalmology, Afyonkarahisar, Turkey  
Phone: +90 506 835 10 06 E-mail: resatduman@gmail.com **ORCID-ID:** orcid.org/0000-0002-8079-6250

**Received:** 23.02.2017 **Accepted:** 23.08.2017

*\*Presented as an oral presentation at the Turkish Ophthalmology Association's 43<sup>rd</sup> National Congress.*

## Materials and Methods

Sixty-five patients over 5 years of age who were diagnosed with anisometropia and unilateral amblyopia in the Ankara University Department of Ophthalmology, Pediatric Ophthalmology and Strabismus Unit between May 2009 and April 2010 (with 12 months of follow-up) were retrospectively included in the study. These 65 anisometric patients were divided into two groups, those with strabismus (group 1, n=27) and those without (group 2, n=38). Of the 27 patients with strabismus, 13 had esotropia and 14 had exotropia. All patients' best corrected visual acuity (BCVA) and deviation test (near and far alternate prism cover test), Worth 4-dot test (near and far), Titmus stereo test, cycloplegic retinoscopy, and fundus examination results were recorded from their files. The study inclusion criterion for anisometropia was a  $\geq 1$  D difference in the spherical or cylindrical refractive error values of the two eyes. The absolute differences of spherical and cylindrical values were obtained separately when calculating degree of anisometropia. The criteria for amblyopia were BCVA of  $\leq 0.8$  or  $\geq 2$  rows of difference in visual acuity on the Snellen chart between the eyes. The logMAR visual acuity difference was used when calculating depth of amblyopia.

Patients with previous ocular surgery and those with any comorbid diseases were excluded from the study.

## Results

Of the 65 patients, 23 were female and 42 were male; the mean age was 12.5 years (5-34 years). Mean age was  $13.1 \pm 3.75$  years (7-23 years) in group 1 and  $12.2 \pm 3.55$  years (5-34 years) in group 2. There were no statistically significant differences between the groups in terms of age (Mann-Whitney U test,  $p=0.339$ ) or sex (Pearson chi-square,  $p=0.814$ ).

Mean BCVA in the patients' amblyopic eyes at time of diagnosis was  $0.67 \pm 0.39$  logMAR in group 1 and  $0.37 \pm 0.30$

logMAR in group 2. There was a significant difference between the two groups in the depth of amblyopia ( $p=0.006$ ).

Among the patients with strabismus (group 1), 13 were diagnosed with esotropia and 14 with exotropia. The mean amount of deviation for distance was 12 PD (10-20 PD). No correlation was found between angle of deviation and depth of amblyopia in patients with strabismus ( $p=0.453$ ,  $r=0.23$ ; Pearson correlation analysis).

The degree of anisometropia according to spherical difference was between 1.5-4 D in 18 patients (66.6%) and over 4 D in 9 patients (33.3%) in group 1, and between 1.5-4 D in 23 patients (61%) and over 4 D in 15 patients (39%) in group 2. In terms of depth of anisometropia, the spherical difference between the two eyes was statistically greater in patients with strabismus compared to those without (Mann-Whitney U test,  $p=0.04$ ), while there was no statistically significant difference between the groups in cylindrical difference (Mann-Whitney U test,  $p=0.146$ ). There was a positive correlation between degree of anisometropia and depth of amblyopia in patients without strabismus ( $p=0.35$ , Pearson correlation coefficient=0.343). There was no statistically significant difference between the groups in terms of the ratio of patients with hypermetropia/myopia (Fisher's exact test) (Table 1).

In terms of binocularity, comparison of Worth 4-dot test and near and distant fusion test results showed that fusion was present in 15 (55.6%) patients with strabismus and 24 (63.2%) patients without strabismus, but the difference was statistically nonsignificant (chi-square test,  $p=0.538$ ). When the values of the Titmus test for stereopsis were compared, there was no statistically significant difference between the two groups (group 1 median: 200 sec arc, group 2 median: 140 sec arc) (Mann-Whitney U test,  $p=0.295$ ) (Table 2).

**Table 1. Properties of the refractive errors of the patient groups**

Depth of anisometropia	Strabismus (+)	Strabismus (-)	All patients	p
Patient number (n)	27	38	65	-
Spherical difference (D) (absolute difference)	2	1.2	1.6	$p=0.04$
Cylindrical difference (D) (absolute difference)	0.38	0.5	-	$p=0.146$
Hypermetropia	25 (92.6%)	35 (92.1%)	60 (92.3%)	-
Myopia	2 (7.4%)	3 (7.9%)	5 (7.7%)	-
D: Diopter				

**Table 2. Fusion and stereopsis results of the patient groups**

	Strabismus (+)	Strabismus (-)	All patients	p
Patient number (n)	27	38	65	-
Suppression/fusion	12/15	14/24	26/39	$p=0.538$
Titmus, median (sec arc)	200 (40-800)	140 (40-800)	200 (40-800)	$p=0.295$



## Discussion

Amblyopia is a term used to describe low vision caused by abnormal visual development in the critical period of childhood. The depth of amblyopia can range from missing a few letters on the 10/10 row of the Snellen chart, to the level of hand movements. While many factors can influence the pathogenesis of amblyopia, anisometropia and strabismus are two of the most common causes in the population, and these conditions can coexist in some patients.<sup>3</sup> Anisometropic amblyopia and strabismic amblyopia develop due to different neuronal mechanisms. In anisometropic amblyopia, visual development is impaired because unequal refractive power causes the image projected onto one or both of the retinas to be unclear. In strabismic amblyopia, the deviant eye cannot focus images on the fovea, resulting in suppression of visual stimuli from that eye.<sup>4,5</sup>

It has not been established whether amblyopia is a result of anisometropia or strabismus in patients with both conditions. A study conducted by Kiorpes and Wallman<sup>6</sup> on monkeys revealed a significant relationship between anisometropia and strabismus. Various other studies have shown that while strabismus is convergent in anisometropic patients, it usually occurs together with anisohypermetropia.<sup>7,8,9,10,11</sup> Philipps<sup>8</sup> have claimed that esotropia arises in cases of hypermetropic anisometropia over 4 D and emphasized that anisometropia and esotropia can co-occur.

In terms of demographic characteristics, in one of the largest series in the literature, Woodruff et al.<sup>12</sup> compared 961 patients diagnosed with anisometropic amblyopia, strabismic amblyopia, and strabismic + anisometropic amblyopia and found the groups similar in terms of sex and age, similar to our study.

When we compared the two groups in our study in terms of depth of amblyopia, patients with strabismus had greater depth of amblyopia than patients without strabismus. Similarly, Tolun et al.<sup>13</sup> and Çalık et al.<sup>14</sup> reported that visual acuity was better in anisometropic amblyopia compared to strabismic amblyopia, while Öztürk et al.<sup>15</sup> observed similar degrees of visual acuity and amblyopia between the strabismic amblyopia group (44 patients) and the anisometropic amblyopia group (45 patients). However, in the studies comparing strabismic and anisometropic amblyopia, the degree of anisometropia in the patients with strabismus was not stated.

In the present study, there was no correlation between angle of deviation and depth of amblyopia in anisometropic patients with strabismus, but depth of amblyopia was positively correlated with degree of anisometropia in patients without strabismus. Helveston<sup>16</sup> reported that degree of anisometropia affects the depth of amblyopia in anisometropic patients with or without strabismus. Çalık et al.<sup>14</sup> observed a positive correlation between amounts of deviation and amblyopia in strabismic patients and a positive correlation between degree of amblyopia and depth of anisometropia in the anisometropia group. Studies by Weakly<sup>2</sup>, Sen<sup>17</sup>, Townshend et al.<sup>18</sup> and Sapkota<sup>19</sup> have also shown that that degree of anisometropia affects depth of amblyopia.

Various studies have yielded different results regarding the distribution of refractive errors in cases of exodeviations. While early studies suggested that the rate of high myopia was 70%,<sup>20</sup> more recent studies have determined that the distribution of refractive errors does not differ from that of the normal population.<sup>21,22</sup>

Burian<sup>23</sup> suggested that refraction is the key factor keeping convergence and divergence mechanisms in balance, whereas von Noorden<sup>20</sup> emphasized that patients with convergence insufficiency may not have exodeviation. Our findings of low myopia rate (7%) despite esotropia in 13 and exotropia in 14 of the strabismic patients supports the study by von Noorden<sup>20</sup> and underline the complex relationship between anisometropia and strabismus.

In our study, the mean amount of deviation for distance was 12 PD (10-20 PD). The lower mean deviation values observed in our study compared to those in other studies in the literature may be explained by the fact that patients with no previous ocular surgery were selected for our study.

While our findings of greater anisometropia in strabismic patients support the existence of a relationship between degree of anisometropia and strabismus, the trigger factor underlying this link remains unclear.

In addition to visual acuity, binocular visual functions such as fusion and stereopsis are also negatively affected in amblyopia.<sup>24</sup> Öztürk et al.<sup>15</sup> determined that patients with anisometropic amblyopia (n=44) had a higher rate of fusion and stereopsis compared to patients with strabismic amblyopia (n=45). However, the same study showed no significant difference in stereopsis when compared with patients with <10 PD deviation. Çalık et al.<sup>14</sup> determined that stereopsis was significantly more common among anisometropic patients than strabismic patients, and that fusion was significantly more common in cases of anisometropic amblyopia compared to cases of strabismic amblyopia. Chen et al.<sup>25</sup> reported that higher magnitude anisometropia was significantly associated with poorer contrast sensitivity, fusion, and stereopsis functions. When fusion and stereopsis were compared in terms of binocularity, no significant difference was found between the two groups in the present study. This may be attributed to the relatively small degrees of deviation in the group of patients with strabismus.

The limitations of our study are that it is a retrospective study and that the data were collected via medical record review. Strengths of our study were that the groups were well matched in terms of size and patient characteristics and we analyzed data from a long time period.

## Conclusion

Our study demonstrates that increasing degree of anisometropia is associated with higher risk of developing strabismus, and patients with concomitant anisometropia and strabismus exhibit deeper amblyopia. In particular, we believe patients with a large degree of anisometropia should be followed more carefully with respect to strabismus. Studies involving a

larger patient numbers and long-term prospective follow-ups are needed in order to improve our understanding of the relationship between strabismus and degree of anisometropia, and to explain the underlying trigger factor.

#### Ethics

**Ethics Committee Approval:** Ankara University Faculty of Medicine Clinical Research Ethics Committee (154-4973).

**Informed Consent:** A retrospective study was planned.

**Peer-review:** Externally and internally peer-reviewed.

#### Authorship Contributions

**Surgical and Medical Practices:** Huban Atilla, Reşat Duman, Emine Çatak, **Concept:** Reşat Duman, **Design:** Huban Atilla, **Data Collection or Processing:** Reşat Duman, Emine Çatak, **Analysis or Interpretation:** Huban Atilla, Reşat Duman, **Literature Search:** Reşat Duman, Emine Çatak, **Writing:** Reşat Duman.

**Conflict of Interest:** No conflict of interest was declared by the authors.

**Financial Disclosure:** The authors declared that this study received no financial support.

#### References

1. von Noorden GK. Amblyopia: a multidisciplinary approach. Proctor lecture. Invest Ophthalmol Vis Sci. 1985;26:1704-1716.
2. Weakly DR Jr. The association between nonstrabismic anisometropia, amblyopia, and subnormal binocularity. Ophthalmology. 2001;108:163-171.
3. Duman R, Atilla H. Farklı ambliyopi tiplerinde klinik seyir ve tedavi. Turk J Ophthalmol. 2013;43:326-334.
4. Weakly DR. The association between anisometropia, amblyopia in the absence of strabismus. Trans Am Ophthalmol Soc. 1999;97:987-1021.
5. Laws D, Noonan CP, Ward A, Chandna A. Binocular fixation pattern and visual acuity in children with strabismic amblyopia. J Pediatr Ophthalmol Strabismus. 2000;37:24-28.
6. Kiorpes L, Wallman J. Does experimentally-induced amblyopia cause hyperopia in monkeys? Vision Res. 1995;35:1289-1297.
7. J de Vries J. Anisometropia in children: analysis of a hospital population. Br J Ophthalmol. 1985;69:504-507.
8. Phillips CI. Strabismus, anisometropia, and amblyopia. Br J Ophthalmol. 1959;43:449-460.
9. Aurell E, Norrsell K. A longitudinal study of children with a family history of strabismus: factors determining the incidence of strabismus. Br J Ophthalmol. 1990;74:589-594.
10. Otsuka J, Sato Y. Comparison of refraction in orthophoric hyperopic eyes and accommodative esotropic eyes. Nippon Ganka Gakkai Zasshi. 1984;88:58-64.
11. Abrahamsson M, Fabian G, Sjostrand J. Refraction changes in children developing convergent or divergent strabismus. Br J Ophthalmol. 1992;76:723-727.
12. Woodruff G, Hiscox F, Thompson JR, Smith LK. The presentation of children with amblyopia. Eye (Lond). 1994;8:623-626.
13. Tolun H, Arslan OS, Devranoglu K ve ark. Anizometropik ambliyopide klinik özellikler. TOD XXVII Ulusal Kongre Bülteni. Yeniyl Matbaası İzmir;1994:92-98.
14. Çalık G, Arda KG, Suphi A. Anizometropik ambliyopi ve şaşılık ambliyopisinde füzyon ve stereopsis. Türkiye Klinikleri J Ophth. 2004;13:117-123
15. Öztürk F, Kurt E, Emiroğlu L. Strabismik ve anizometropik ambliyopide füzyon ve stereopsis karşılaştırılması. MN Oftalmoloji. 1999;63:69-71.
16. Helveston EM. Relationship between degree of anisometropia and depth of amblyopia. Am J Ophthalmol. 1966;62:757-759.
17. Sen DK. Anisometropic amblyopia. J Pediatric Ophthalmol Strabismus. 1980;17:180-184.
18. Townshend AM, Holmes JM, Evans LS. Depth of anisometropic amblyopia and difference in refraction. Am J Ophthalmol. 1993;116:431-436.
19. Sapkota K. A retrospective analysis of children with anisometropic amblyopia in Nepal. Strabismus. 2014;22:47-51.
20. von Noorden GK. Binoküler vision and ocular motility; Theory and management of strabismus. St. Louis; Mosby; 1996:341-354.
21. Schlossman A, Boruchoff SA. Correlation between physiologic and clinical aspects of exotropia. Am J Ophthalmol. 1965;40:53-64.
22. Cooper J, Medow N. Major review: Intermitent Exotropia, Basic and Divergence Excess Type. Binocular Vision. 1993;8:185-216.
23. Burian HM. Pathophysiology of exodeviations. In Manley DR, ed. Symposium on Horizontal Ocular Deviations. St Louis, Mosby; Year Book; 1971:119.
24. Levi DM, Knill DC, Bavelier D. Stereopsis and amblyopia: A mini-review. Vision Res. 2015;114:17-30.
25. Chen BB, Song FW, Sun ZH, Yang Y. Anisometropia magnitude and visual deficits in previously untreated anisometropic amblyopia. Int J Ophthalmol. 2013;18:6:606-610.



# Direct Treatment Costs of Neovascular Age-related Macular Degeneration and Comparison of Gained and/or Preserved Vision with Expenditure

Şeyda Yıldırım, Cezmi Akkın, Zafer Öztaş, Serhad Nalçacı, Filiz Afrashi, Jale Menteş  
Ege University Faculty of Medicine, Department of Ophthalmology, İzmir, Turkey

## Abstract

**Objectives:** The aim was to quantify the direct medical cost of neovascular age-related macular degeneration (AMD) versus gained or preserved vision.

**Materials and Methods:** Data of patients treated for neovascular AMD between January 2009 to January 2014 were reviewed. Patients with complete follow-up for two years, treated with only intravitreal ranibizumab injections and with no intraocular surgery were included. Demographics, diagnostic investigations, the number of visits and injections, changes in visual acuity (VA) at one year and two years from baseline were noted. Total cost was calculated for the first and second years, and the cost of improving or preserving initial vision level was determined with subgroup analysis.

**Results:** Two-hundred eyes of 175 patients (86 male and 89 female) with a mean age of  $72.3 \pm 7.8$  years were included. Mean VA was 0.67 logMAR at baseline, 0.60 logMAR at the end of the first year, and 0.67 logMAR at the end of the second year. At the end of the 2 years, VA increased in 82 eyes (41%), remained the same in 42 eyes (21%), and decreased in 76 eyes (38%). The mean number of visits in the first and second years were 6.56 (3-12) and 5.74 (3-10), respectively. An average of 4.42 (1-8) injections were performed in the first year and 2.25 (0-7) in the second. The total direct medical cost for AMD was 9,628 TL (Turkish Lira) per patient for 2 years, which consisted of 529 TL in visit costs, 115 TL in fluorescein and indocyanine angiography costs, 611 TL in injection procedure costs, and 8,371 TL in drug costs. The cost of one line of VA gain was 11,911 TL in the first year.

**Conclusion:** This study showed that treatment increased or stabilized vision in a reasonable proportion of patients, that cost of management decreases in the second year, and that drug expenses are the leading item in reimbursement.

**Keywords:** Age-related macular degeneration, direct medical cost, ranibizumab

## Introduction

Age-related macular degeneration (AMD) is a chronic progressive disease of the macula which is usually bilateral and seen in individuals over 50 years of age. It is among the main causes of blindness in populations aged 65 years and older in developed countries.<sup>1</sup> There are two types of AMD, dry and wet (exudative), with the exudative type responsible for 90% of blindness associated with AMD.<sup>2</sup> Without treatment, the visual prognosis of exudative AMD is poor, and quality of life is severely impaired.<sup>3</sup>

Many treatment alternatives have been developed for the treatment of AMD and were shown in numerous studies to

significantly improve visual acuity (VA). However, there are insufficient data regarding the costs of treatment and the economic burden AMD imposes on patients and society.<sup>4</sup>

Health-related costs are classified into three main categories with respect to expenditures made to treat disease and to solve the problems patients experience in their daily life due to disease. These are medical, non-medical, and indirect expenditures.<sup>5</sup> Medical expenditures include medical consumables, drugs, and staff expenses which arise during the treatment process and are paid by the patient or through reimbursement systems. Non-medical expenditures are those made personally by the

**Address for Correspondence:** Şeyda Yıldırım MD, Ege University Faculty of Medicine, Department of Ophthalmology, İzmir, Turkey  
Phone: +90 536 817 81 67 E-mail: seydayildirim@hotmail.com **ORCID-ID:** orcid.org/0000-0003-1473-9001

**Received:** 03.04.2017 **Accepted:** 14.08.2017

©Copyright 2018 by Turkish Ophthalmological Association  
Turkish Journal of Ophthalmology, published by Galenos Publishing House.

patient due to disease (such as travel and food costs). Indirect expenditures are defined as the collective cost of labor loss due to illness, disability, or premature death. The monetary value of these costs is difficult to measure.<sup>6</sup>

The aim of this study was to calculate the medical expenses incurred during the first two years of treatment with ranibizumab, an anti-vascular endothelial growth factor (anti-VEGF) agent commonly used to manage exudative AMD, and to compare restored/preserved vision with treatment cost.

## Materials and Methods

After receiving approval from the Ege University Ethics Committee (15-9.1/14), 200 eyes of 175 patients aged 50 years and older (mean age  $72.3 \pm 7.8$  years; 89 female and 86 male) who started intravitreal ranibizumab therapy for exudative AMD at the Ege University Medical Faculty Retina Unit between January 2009 and January 2014 were included in the study. The patients were all followed regularly and data from their first two years of treatment were retrospectively analyzed. Treatment was administered based on a PRN (pro re nata) regimen in most of the patients; intravitreal injections were given monthly for the first three months, followed by injections as needed. The study population also included a small number of patients who were not given the three-month loading dose based on individual evaluation.

In order to derive a standard cost of treatment, we excluded patients who underwent any treatment other than intravitreal ranibizumab injection (laser photocoagulation, photodynamic therapy, or other anti-VEGF agent injections), patients who underwent cataract surgery or any other similar ocular surgery during the period in which they were included in the study (due to possible effects on VA), and patients with ocular diseases other than AMD. Furthermore, in order to be able to express degree of VA change during follow-up in the form of rows on a decimal system scale, patients with VA less than 0.05 were also excluded.

From the patients' medical records we recorded their sex, age at start of treatment, VA at 1 and 2 years after start of treatment (decimal), and the number of examinations, fundus fluorescein angiographies (FFA), indocyanine green angiographies (ICGA), and intravitreal ranibizumab injections performed during 2 years of follow-up. The VA values measured on a decimal scale were converted to logMAR and Early Treatment Diabetic Retinopathy Study (ETDRS) as corresponding letters.

To calculate medical expenditures, the annual number of examinations, FFA, ICGA, and intravitreal injection services were determined for each patient. These numbers were then multiplied by the current prices pertaining to the relevant health service (based on the Health Practices Statement [HPS] updated 18 January 2016) and the results were summed to yield annual service expense per eye in Turkish liras (TL). In order to rule out factors such as inflation and price changes, current service fees and drug prices were used as the basis for calculating medical treatment expenses.

According to HPS Appendix 2A (Outpatient Treatment Payment List) published on 18 January 2016, payments of 43 TL for an examination, 89.20 TL for FFA, 161.20 TL for ICGA+FFA, and 91.80 TL for an intravitreal injection are made to the Social Security Institution (SSI). Optical coherence tomography (OCT) is included in the examination package by the SSI and there is no reimbursement fee for OCT in addition to the examination fee.

The public price of a dose of injectable ranibizumab (Lucentis; Genentech, South San Francisco, California, CA, USA) was derived by applying the public discount stated in the HPS to the retail price determined by the Turkish Pharmaceuticals and Medical Devices Agency. We used the most recent (updated on 22 February 2016) public price for Lucentis of 1,256.09 TL in our study.

The eyes included in the study were grouped in two different ways: Firstly, we grouped the eyes based on change in VA from baseline to the end of the second year of treatment as eyes with increased VA, preserved VA, and decreased VA. Secondly, the eyes were divided into those with VA of  $\geq 0.5$  and those with VA  $< 0.5$  at the start of treatment.

Based on the recorded data, we calculated the exudative AMD-related costs for the SSI per eye in the first and second years of treatment and compared these costs to amount of change in VA for all eyes and the subgroups described above.

## Results

The study included 200 eyes of 175 patients (89 female, 86 male) with a mean age of  $72.3 \pm 7.8$  years.

The average numbers of examinations, FFA and ICGA procedures, and intravitreal ranibizumab injections during the first and second years of treatment are presented in Table 1. Over the 2 years of treatment, the patients were examined approximately 12 times on average and had received an average of 7 intravitreal ranibizumab injections. When the costs of examinations, testing, drugs, and drug administration were added, it was found that the total average medical expenditure per eye at the end of 2 years was about 9,600 TL, with an average of 6,312 TL in the first year and 3,315 TL in the second year. Table 2 shows the average annual expenses for each expenditure item and the total annual expenditure. We determined that the cost of the drug accounted for 88% of the total expenditure in

**Table 1. Mean annual number of medical health expenditure items**

	Number in year 1 $\pm$ SD (range)	Number in year 2 $\pm$ SD (range)
Examinations	6.56 $\pm$ 1.45 (3-12)	5.74 $\pm$ 1.64 (3-10)
FFA	0.71 $\pm$ 0.51 (0-2)	0.09 $\pm$ 0.31 (0-2)
ICGA	0.06 $\pm$ 0.25 (0-2)	0.21 $\pm$ 0.42 (0-2)
Intravitreal injections	4.42 $\pm$ 1.51 (1-8)	2.25 $\pm$ 1.92 (0-7)

SD: Standard deviation, FFA: Fundus fluorescein angiography, ICGA: Indocyanine green angiography

the first year and 85% in the second year. In contrast, the cost of the surgical procedure of intraocular administration of this costly drug represented only 6% of the total medical expenditure (Table 2).

The annual number of injections (Table 3) and the total annual cost (Table 4) were similar among the subgroups based on VA change (increased/preserved/decreased) and initial VA (<0.5 and ≥0.5).

Mean VA (decimal) was 0.292±0.21 at the start of treatment, 0.338±0.23 at the end of the first year, and 0.299±0.23 at the end of the second year. Based on these values, VA increased by a mean of 0.53±2.33 lines in the first year of treatment and decreased by 0.45±1.88 lines in the second year. Therefore, there was a net increase of 0.08±2.67 lines after 2 years of treatment; essentially, mean VA was preserved. When the eyes were grouped based on change from initial VA, final VA was increased in 82 eyes (41%), preserved in 42 eyes (21%), and decreased in 76 eyes (38%) at the end of 2 years. When VA change was analyzed by year, we noted that the mean VA had increased during both the first and second year in the group with increased VA (n=82). VA had increased in the first year but decreased in the second year in the group with preserved VA (n=42), thus returning to the initial level. In the group with decreased VA (n=76), VA had continued to decrease during both years. At the start of treatment, VA was <0.5 in 157 eyes and ≥0.5 in 43 eyes. In the group with initial VA <0.5, VA increased in the first year and decreased slightly in the second year, for an overall increase in VA. In the group with initial VA ≥0.5, VA decreased in both years. The changes in VA in all eyes and subgroups during the first 2 years of treatment are presented in Table 5.

In this study, we calculated the cost of 1 line of VA gain by

dividing the total cost by increase in lines. Based on this, the average cost of one line of VA gain for all eyes during the first year was 11,911 TL. Because the mean VA of all eyes did not increase in the second year, this figure could not be calculated. In the subgroup with increased VA at the end of 2 years, the average cost of one line of VA gain was calculated as 2,999 TL for the first year and 3,636 TL for the second year. The total average cost of preserving VA for 2 years was 9,337 TL in the subgroup of eyes with preserved VA. In this group, VA increased in the first year and the average cost of 1 line VA gain was 8,477 TL. However, as there was no improvement in VA in the second year, this figure could not be calculated for the second year. Despite an average expenditure of 10,092 TL over 2 years, VA decreased in both years in the group with decreased VA. Therefore, the cost of 1 line of VA gain could not be calculated. In the group with initial VA <0.5, the cost of one line of VA gain was 6,692TL for the first

**Table 4. Mean annual cost of medical health expenditure items in the patient subgroups**

	Year 1, TL ± SD	Year 2, TL ± SD
All eyes (n=200)	6,313±2,061	3,315±2,634
VA Increased (n=82)	6,298±2,257	3,047±2,761
VA Preserved (n=42)	6,188±2,071	3,149±2,435
VA Decreased (n=76)	6,397±1,846	3,695±2,587
Initial VA <0.5 (n=157)	6,290±2,040	3,186±2,610
Initial VA ≥0.5 (n=43)	6,393±2,159	3,786±2,697

TL: Turkish lira, SD: Standard deviation, VA: Visual acuity

**Table 5. Visual acuity at baseline, 1 year, and 2 years**

		Initial VA	VA at 1 year	VA at 2 years
All eyes (n=200)	Decimal	0.29	0.34	0.29
	logMAR	0.67	0.60	0.67
	ETDRS	51.5	54.9	51.7
VA increased (n=82)	Decimal	0.21	0.39	0.42
	logMAR	0.81	0.52	0.45
	ETDRS	44.64	58.8	65.5
VA preserved (n=42)	Decimal	0.21	0.28	0.21
	logMAR	0.81	0.71	0.81
	ETDRS	44.3	49.5	44.3
VA decreased (n=76)	Decimal	0.41	0.31	0.21
	logMAR	0.44	0.62	0.82
	ETDRS	62.8	53.7	44.1
Initial VA <0.5 (n=157)	Decimal	0.20	0.28	0.25
	logMAR	0.79	0.66	0.71
	ETDRS	45.4	51.6	49.0
Initial VA ≥0.5 (n=43)	Decimal	0.61	0.52	0.45
	logMAR	0.22	0.35	0.46
	ETDRS	73.6	67.2	61.5

VA: Visual acuity, ETDRS: Early Treatment Diabetic Retinopathy Study

**Table 2. Mean annual cost of medical health expenditure items**

	Year 1, TL ± SD (%)	Year 2, TL ± SD (%)
Drug	5,552±1,903 (88)	2,820±2,414 (85.1)
Surgical procedure	405±139 (6.4)	206±176 (6.2)
Examination	282±62 (4.5)	247±70 (7.4)
FFA+ICGA	73±53 (1.1)	42±73 (1.3)
Total cost	6,313±2,061 (100)	3,315±2,634 (100)

TL: Turkish lira, SD: Standard deviation, FFA: Fundus fluorescein angiography, ICGA: Indocyanine green angiography

**Table 3. Mean annual number of injections in the patient subgroups**

	Year 1, number ± SD	Year 2, number ± SD
All eyes (n=200)	4.42±1.51	2.25±1.92
VA increased (n=82)	4.41±1.65	2.06±2.02
VA preserved (n=42)	4.33±1.52	2.11±1.78
VA decreased (n=76)	4.47±1.36	2.51±1.87
Initial VA <0.5 (n=157)	4.40±1.50	2.15±1.90
Initial VA ≥0.5 (n=43)	4.46±1.57	2.58±1.95

SD: Standard deviation, VA: Visual acuity

**Table 6. Visual acuity change from year 1 to year 2 (lines), annual cost, and cost per 1 line of visual gain**

	VA change(Lines)	Total cost (TL)	Cost of 1 line visual gain (TL)	
All eyes n=200	+0.53	6,312	11,911	Year 1
	-0.45	3,315	-	Year 2
VA Increased (n=82)	+2.10	6,298	2,999	Year 1
	+0.46	3,047	6,625	Year 2
VA Preserved (n=42)	+0.73	6,188	8,477	Year 1
	-0.73	3,149	-	Year 2
VA Decreased (n=76)	-1.28	6,397	-	Year 1
	-1.27	3,695	-	Year 2
VA <0.5 (n=157)	+0.94	6,290	6,692	Year 1
	-0.34	3,186	-	Year 2
VA ≥0.5 (n=43)	-0.97	6,393	-	Year 1
	-0.83	3,786	-	Year 2

VA: Visual acuity, TL: Turkish lira

**Table 7. Total visual acuity change after 2 years, total cost, and total cost of 1 line gain in visual acuity**

	VA (lines)	Total cost (TL)	Cost of 1 line VA gain (TL)
All eyes (n=200)	+0.08	9,628	-
VA Increased (n=82)	+2.57	9,346	3,636
VA Preserved (n=42)	0	9,337	-
VA Decreased (n=76)	-2.56	10,092	-
Initial VA <0.5 (n=157)	+0.59	9,477	16,062
Initial VA ≥0.5 (n=43)	-1.81	10,179	-

VA: Visual acuity, TL: Turkish lira

year, but could not be calculated for the second year due to an overall decrease in VA. In the group with initial VA ≥0.5, there was a decrease in VA in both years despite a total expenditure of 10,179 TL over 2 years. The average change in VA (lines) in the first and second years of treatment, total average medical expenses, and the cost of 1 line of VA gain (when applicable) for all eyes and subgroups are shown in Table 6. Table 7 shows the total change in VA at the end of 2 years and the total cost, together with the cost of increasing VA by one line.

## Discussion

The clinical efficacy and reliability of ranibizumab in various retinal diseases including AMD has been demonstrated in randomized, controlled clinical trials involving over 1.7 million patient-years and including over 12,500 patients.<sup>7,8</sup> However, relatively few studies address the financial aspect of treatment, and the cost of treating AMD with intravitreal anti-VEGF agents is quite high. Moreover, as the population aged 65 years and older continues to grow, health spending related to AMD has also increased and the economic burden is expected to increase further in the coming years.<sup>9</sup>

Currently, intravitreal anti-VEGF agents are mainly used to treat exudative AMD, but they are an extremely costly option. In the present study, we determined based on real-life data that a patient with AMD receives an average of about 4.4 injections within the first year and about 2.2 in the second year. We also found that in Turkey, the cost of the drug used for these injections accounted for nearly 90% of the related health expenditures. This cost is an average of 9,628 TL for 2 years, with VA being preserved, though not significantly improved, at the end of this period. The average cost of one line of VA gain for one AMD patient was calculated to be 11,911 TL for the first year, but because VA returned to initial levels at the end of the second year, this calculation could only be done for the subgroup with increased VA.

The issue of concern is how to provide uninterrupted treatment with intravitreal anti-VEGF therapy, which is necessary for AMD, a disease with high prevalence in advanced age, but is also costly. The question of how to provide the best healthcare within a limited budget has increased the importance of health economics research. In the ANCHOR and MARINA trials, which were the first studies to investigate the clinical efficacy of intravitreal ranibizumab therapy for the treatment of neovascular AMD, injections were administered monthly.<sup>10,11</sup> Although favorable clinical outcomes were achieved in these studies, such a treatment scheme does not seem feasible considering the limited human, technical, and financial resources in real-life clinical practice. For this reason, attempts have been made to develop alternative treatment schemes for intravitreal therapeutic applications in order to reduce follow-ups, testing, and costs.

In the LUMINOUS study, which examined the outcomes of ranibizumab therapy applied in routine clinical practice, the one-year data of a total of 4,444 patients with wet AMD who received ranibizumab injections in Germany, the Netherlands, Belgium, and Sweden were evaluated.<sup>12</sup> According to the results

of the LUMINOUS study, the number of injections done in the first year varies between 4.3 and 5.7 in different countries. Similarly, we determined that the average number of injections during the first year of treatment in our study was within this range (4.4 on average).

In terms of visual improvement, mean letter gains at the end of 1 year of treatment in the countries in the LUMINOUS study were as follows: -0.8 letters in Germany, +5.6 letters in the Netherlands, +2.5 letters in Belgium, and +1 letter in Sweden. In the present study, there was an average gain of 3.4 letters at the end of the first year. However, this was offset by an average loss of 3.2 letters in the second year, resulting in an overall gain of 0.2 letters at the end of 2 years compared to the start of treatment. Therefore, initial VA was more or less preserved. These results are similar to the LUMINOUS study, which was based on real-life data, but lagged behind the gains reported in the ANCHOR (10.7 letters in 2 years) and MARINA (6.6 letters in 2 years), in which injections were given monthly.<sup>10,11</sup> This difference may be attributable to the lower average number of injections in the clinical setting, especially in the second year of treatment.

In their study assessing the results of the CATT study, Ying et al.<sup>13</sup> reported that initial VA of 0.5 or greater is a poor prognostic marker for VA improvement. We also observed in our study that treatment was less effective in patients with an initial VA of 0.5 or higher. This group had a mean loss of  $12.0 \pm 17.8$  letters at the end of 2 years, whereas the group with an initial VA below 0.5 had a mean gain of  $3.5 \pm 18.6$  letters in 2 years. Moreover, the two groups had similar numbers of intravitreal injections and total treatment costs, meaning that a more successful clinical result was obtained at the same cost in the group with low VA. However, explaining why the subgroups showed different responses is beyond the scope of this study.

Comparing studies conducted in different countries in terms of cost is problematic. This can be partially attributed to international variations in currencies and unit prices for health procedures and services, treatment regimens applied, and reimbursement agency tariffs. The fact that the analyses were done in different years is another factor that precludes comparison.

Although the present study focused on the treatment costs of wet AMD, it is important to remember that treatment of AMD is not limited to the wet type. Approximately 90% of AMD patients have the non-exudative form, and the cost of supportive treatment for these patients should also not be underestimated. Patients with dry AMD also require regular ophthalmology visits. For treatment, nutritional supplements are recommended to prevent the dry form from progressing to the wet form. These supplements are not covered by the reimbursement system in our country and the expense is directly paid for by the patient. In addition to available nutritional supplements, studies are ongoing into new intravitreal drugs that reduce the growth of geographic atrophy, targeting inflammasomes, developing drugs that affect the photoreceptor pigment cycle, neuron protection,

and stem cell transplantation.<sup>14,15,16,17,18</sup> With newly developed drugs, cost will also become an important issue in the treatment of dry AMD in the coming years.

In addition to assessing the clinical effectiveness of AMD treatment, our study also examines its cost and compares patient expenditures with clinical outcomes. This makes it a pioneering study in Turkey. However, another issue that needs to be emphasized is the importance of investigating how treatments affect patients' quality of life, aside from their clinical efficacy. Assessing the benefit of treatment based solely on VA is inadequate, and the quality of health services cannot be improved without knowing about objective patient satisfaction. Patients with AMD can face serious problems with activities of daily living, such as driving, reading, face recognition, shopping, cleaning, home repairs, taking medication, cooking, paying bills, and maintaining personal hygiene, and these problems increase in proportion to reduction in VA.<sup>19</sup> Investigating the adverse effects of AMD on quality of life will help to better understand the value of treatment.

A limitation of this study is the fact that we calculated expenditures associated with the medical treatment only. Total cost, which includes myriad expenses such as personal nonmedical AMD-related expenditures made by the patient, staffing costs, hospital stationary expenses, and expenses associated with providing the physical environment where devices are located, could not be ascertained. These costs are difficult to quantify monetarily, which in turn makes it difficult to determine the necessary amount of reimbursement from the state. Another limitation is that VA levels were recorded according to a decimal system, which required these values to be converted to Snellen and ETDRS letter equivalents in order to compare our data with the international literature. Although the literature was taken as an example, small changes in the data during these conversions are unavoidable. Finally, this research was conducted in a single center with data from a limited number of patients, which limits the generalization of our results. However, it allows us to shed some light on the situation in Turkey. Multicenter studies with large patient numbers are needed to enable the calculation of national medical expenditures associated with the treatment of exudative AMD.

## Conclusion

This study revealed that individuals incurred an average of 9,628 TL of medical expenses for 2 years of AMD treatment, that VA was preserved at the end of 2 years compared to initial levels, and that patients who improved with treatment in the first year spent less in the second year. In particular, we noted that the number of injections in the second year and the amount of VA gain with 2 years of treatment were lower in our study compared to the literature. Increasing the frequency of treatment applications may result in better visual outcomes. We believe that our study offers potentially useful information regarding treatment costs in AMD, especially for our country.

### Ethics

**Ethics Committee Approval:** Ege University Faculty of Medicine Clinical Research Ethics Committee (15-9.1/14).

**Informed Consent:** Retrospective study.

**Peer-review:** Externally peer-reviewed.

### Authorship Contributions

**Surgical and Medical Practices:** Şeyda Yıldırım, Cezmi Akkın, Zafer Öztaş, Serhad Nalçacı, Filiz Afrashi, Jale Menteş, **Concept:** Şeyda Yıldırım, Cezmi Akkın, Filiz Afrashi, Jale Menteş, **Design:** Şeyda Yıldırım, Cezmi Akkın, Filiz Afrashi, Jale Menteş, **Data Collection or Processing:** Şeyda Yıldırım, **Analysis or Interpretation:** Şeyda Yıldırım, Cezmi Akkın, Zafer Öztaş, Serhad Nalçacı, **Literature Search:** Şeyda Yıldırım, Zafer Öztaş, Cezmi Akkın, Serhad Nalçacı, **Writing:** Şeyda Yıldırım, Zafer Öztaş, Cezmi Akkın, Serhad Nalçacı.

**Conflict of Interest:** No conflict of interest was declared by the authors.

**Financial Disclosure:** The authors declared that this study received no financial support.

### References

- Resnikoff S, Pascolini D, Etya'ale D, Kocur I, Pararajasegaram R, Pokharel GP, Mariotti SP. Global data on visual impairment in the year 2002. *Bull World Health Organ.* 2004;82:844-851.
- Ferris FL 3rd, Fine SL, Hyman L. Age-related macular degeneration and blindness due to neovascular maculopathy. *Arch Ophthalmol.* 1984;102:1640-1642.
- Brown MM, Brown GC, Sharma S, Stein JD, Roth Z, Campanella J, Beauchamp GR. The burden of age-related macular degeneration: a value-based analysis. *Curr Opin Ophthalmol.* 2006;17:257-266.
- Brown MM, Brown GC, Brown H. Value-based medicine and interventions for macular degeneration. *Curr Opin Ophthalmol.* 2007;18:194-200.
- Brown MM, Sharma S, Landy J. Evidence-based to value-based medicine. Chicago; AMA Press; 2005:1-327.
- Ke KM. The direct, indirect and intangible costs of visual impairment caused by neovascular age-related macular degeneration. *Eur J Health Econ.* 2010;11:525-531.
- Brown DM, Kaiser PK, Michels M, Soubrane G, Heier JS, Kim RY, Sy JP, Schneider S; ANCHOR Study Group. Ranibizumab versus verteporfin for neovascular age-related macular degeneration. *N Engl J Med.* 2006;355:1432-1444.
- Holz FG, Amoaku W, Donate J, Guymer RH, Kellner U, Schlingemann RO, Weichselberger A, Staurengi G; SUSTAIN Study Group. Safety and efficacy of a flexible dosing regimen of ranibizumab in neovascular age-related macular degeneration: the SUSTAIN study. *Ophthalmology.* 2011;118:663-671.
- Soubrane G, Cruess A, Lotery A, Pauleikhoff D, Monès J, Xu X, Zlateva G, Buggage R, Conlon J, Goss TF. Burden and health care resource utilization in neovascular age-related macular degeneration: findings of a multicountry study. *Arch Ophthalmol.* 2007;125:1249-1254.
- Brown DM, Kaiser PK, Michels M, Soubrane G, Heier JS, Kim RY, Sy JP, Schneider S; ANCHOR Study Group. Ranibizumab versus verteporfin for neovascular age-related macular degeneration. *N Engl J Med.* 2006;355:1432-1444.
- Rosenfeld PJ, Brown DM, Heier JS, Boyer DS, Kaiser PK, Chung CY, Kim RY; MARINA Study Group. Ranibizumab for neovascular age-related macular degeneration. *N Engl J Med.* 2006;355:1419-1431.
- Holz FG, Bandello F, Gillies M, Mitchell P, Osborne A, Sheidow T, Souied E, Figueroa MS; LUMINOUS Steering Committee. Safety of ranibizumab in routine clinical practice: 1-year retrospective pooled analysis of four European neovascular AMD registries within the LUMINOUS programme. *Br J Ophthalmol.* 2013;97:1161-1167.
- Ying GS, Maguire MG, Daniel E, Ferris FL, Jaffe GJ, Grunwald JE, Toth CA, Huang J, Martin DF; Comparison of Age-Related Macular Degeneration Treatments Trials (CATT) Research Group. Association of Baseline Characteristics and Early Vision Response with 2-Year Vision Outcomes in the Comparison of AMD Treatments Trials (CATT). *Ophthalmology.* 2015;122:2523-2531.
- Regillo CD. Lampalizumab (anti-factor D) in patients with geography atrophy: The mahalo phase 2 results; Proceedings of the 2013 Annual Meeting of the American Academy of Ophthalmology 2013. New Orleans; LA, USA; 2013:16-19.
- Tarallo V, Hirano Y, Gelfand BD, Dridi S, Kerur N, Kim Y, Cho WG, Kaneko H, Fowler BJ, Bogdanovich S, Albuquerque RJ, Hauswirth WW, Chiodo VA, Kugel JF, Goodrich JA, Ponicsan SL, Chaudhuri G, Murphy MP, Dunaief JL, Ambati BK, Ogura Y, Yoo JW, Lee DK, Provost P, Hinton DR, Núñez G, Baffi JZ, Kleinman ME, Ambati J. DICER1 loss and Alu RNA induce age-related macular degeneration via the NLRP3 inflammasome and MyD88. *Cell.* 2012;149:847-859.
- Kubota R, Boman NL, David R, Mallikarjun S, Patil S, Birch D. Safety and effect on rod function of ACU-4429, a novel small-molecule visual cycle modulator. *Retina.* 2012;32:183-188.
- Zhang K, Hopkins JJ, Heier JS, Birch DG, Halperin LS, Albin TA, Brown DM, Jaffe GJ, Tao W, Williams GA. Ciliary neurotrophic factor delivered by encapsulated cell intraocular implants for treatment of geographic atrophy in age-related macular degeneration. *Proc Natl Acad Sci U S A.* 2011;108:6241-6245.
- Schwartz SD, Hubschman JP, Heilwell G, Franco-Cardenas V, Pan CK, Ostrick RM, Mickunas E, Gay R, Klimanskaya I, Lanza R. Embryonic stem cell trials for macular degeneration: a preliminary report. *Lancet.* 2012;379:713-720.
- Schmier JK, Halpern MT, Covert D, Delgado J, Sharma S. Impact of visual impairment on use of caregiving by individuals with age-related macular degeneration. *Retina.* 2006;26:1056-1062.





# Stem Cell Treatment in Retinal Diseases: Recent Developments

© Ayşe Öner

Erciyes University Faculty of Medicine, Department of Ophthalmology, Kayseri, Turkey

## Abstract

Stem cells are undifferentiated cells which have the ability to self-renew and differentiate into mature cells. They are highly proliferative, implying that an unlimited number of mature cells can be generated from a given stem cell source. On this basis, stem cell replacement therapy has been evaluated in recent years as an alternative for various pathologies. Degenerative retinal diseases cause progressive visual decline which originates from continuing loss of photoreceptor cells and outer nuclear layers. Theoretically, this therapy will enable the generation of new retinal cells from stem cells to replace the damaged cells in the diseased retina. In addition, stem cells are able to perform multiple functions, such as immunoregulation, anti-apoptosis of neurons, and neurotrophin secretion. With recent progress in experimental stem cell applications, phase I/II clinical trials have been approved. These latest stem cell transplantation studies showed that this therapy is a promising approach to restore visual function in eyes with degenerative retinal diseases such as retinitis pigmentosa, Stargardts' macular dystrophy, and age-related macular degeneration. This review focuses on new developments in stem cell therapy for degenerative retinal diseases.

**Keywords:** Stem cell, retinal diseases, recent developments

## Introduction

Degenerative retinal diseases are among the main causes of irreversible vision loss. In recent years, stem cell transplant studies aiming to restore visual function in these diseases have gained momentum. In this review, we discuss general information about stem cells and evaluate the results of recent experimental and clinical studies concerning the treatment of retinal diseases.

### What is a Stem Cell

Stem cells are functionally undifferentiated, immature cells with a complex structure. These cells are capable of differentiating into other cell types of the body. When stem cells are introduced into an area, they can settle in a suitable environment where they proliferate and either propagate their own population or differentiate into various types of cells and generate cell populations of that type. They also have

the potential to repair tissue and restore function after injury. Because of this potential, it is believed that they may be able to either replace or repair damaged cells in the retina. Their unique properties have led to the investigation of stem cells as a treatment option for many diseases.<sup>1,2,3,4</sup>

### Properties of Stem Cells

**Proliferation:** Stem cells are able to divide and multiply for extended periods of time.

**Self-renewal:** After division, the resulting cell can continue as a stem cell, like the parent stem cell.

**Differentiation:** Stem cells are unspecialized and can give rise to specialized cells. Both internal and external stimuli are important in this process. Internal stimuli are controlled by the cell's genetic material. External stimuli are regulated by chemical factors secreted by other cells in the environment, by physical contact with neighboring cells, and by other molecules in the environment.<sup>1,2,3,4</sup>

**Address for Correspondence:** Ayşe Öner MD, Erciyes University Faculty of Medicine, Department of Ophthalmology, Kayseri, Turkey

Phone: +90 530 283 16 11 E-mail: aoner@erciyes.edu.tr **ORCID-ID:** orcid.org/0000-0002-8583-1836

**Received:** 29.01.2017 **Accepted:** 07.06.2017

©Copyright 2018 by Turkish Ophthalmological Association  
Turkish Journal of Ophthalmology, published by Galenos Publishing House.

### History of Stem Cells ESCs

Embryonic stem cells (ESCs) were first obtained from a mouse embryo in 1981. ESCs were first obtained from a human embryo in 1998 under laboratory conditions. In 2006, adult stem cells were reprogrammed to behave like ESCs, giving rise to “induced pluripotent stem cells” (iPSCs). The first Food and Drug Administration (FDA)-approved human trial was initiated in 2009 and used human ESCs for spinal cord injury. Stem cell research for retinal diseases started in 2010.<sup>3,4</sup>

### Stem Cell Types and Procurement

#### 1. ESCs

ESCs are produced in vitro from the inner cell mass of an embryo (blastocyst) removed in the first 3-5 days of early embryonic development. These cells are pluripotent because they have the ability to differentiate into any cell of the body derived from the ectoderm, mesoderm, and endoderm. It is also possible to remove these cells without destroying the embryo.<sup>1,6</sup>

#### 2. Adult Stem Cells

- Mesenchymal Stem Cells (MSCs): These are found in many adult tissues, such as the blood, blood vessels, skeletal muscles, skin, teeth, bone marrow, fat, and cartilage, and are isolated from these tissues in vitro. MSCs derived from fat and bone marrow are most commonly used. These cells are considered multipotent because they can differentiate into many types of specialized cells in the body.

- iPSCs: These are derived by conferring ESC properties to cells obtained from adults through in vitro genetic reprogramming. Like ESCs, they are pluripotent.<sup>7</sup>

#### 3. Cord Blood Stem Cells

These are isolated in vitro from cells obtained from cord blood following delivery.<sup>1</sup>

#### 4. Amniotic Fluid Stem Cells

These are isolated in vitro from cells obtained from amniotic fluid.<sup>1</sup>

### Mechanisms of Action

1. Cell replacement: Healthy stem cells can replace unhealthy or lost stem cells.<sup>1,5,8</sup>

2. Nutritional support: Healthy stem cells increase support to surrounding cells by secreting growth factors.<sup>1,5,8</sup>

3. Anti-apoptosis: Stem cells can regulate the degeneration of retinal cells and vessels by inhibiting apoptosis.<sup>1,5,8</sup>

4. Synapse formation: They can create new synaptic connections.<sup>1,2,3,4,5,8</sup>

### Stem Cell Studies For Retinal Diseases

There are numerous advantages of stem cell therapy in the eye. The amount of stem cells required is low, which is important in terms of cost. The surgical approach is quite easy, and the transplanted cells can be easily monitored with

the imaging methods currently used in clinical practice. The fellow eye can be used as a control. Furthermore, long-term immunosuppressive treatment is not required due to the immune privilege of the eye.<sup>9</sup>

In experimental studies, the application of healthy stem cells in the place of degenerated retinal cells has promoted cell regeneration, creation of new intercellular connections, and improvement of visual function. Stem cells have the potential to differentiate into many cells in their environment, including the retinal neural cells and photoreceptors. Earlier experimental studies have shown that stem cells are very compatible with retinas and are able to adapt to Müller, amacrine, bipolar, horizontal, and glial cells, and photoreceptors.<sup>8,9</sup>

ESCs, iPSCs, and MSCs (of bone marrow and adipose tissue origin) are used in stem cell therapy for retinal diseases.<sup>1,2,3,4,5,8,9</sup>

### Studies on the Use of ESCs

ESCs obtained from mouse embryos were shown to be capable of expressing neural markers when induced by retinoic acid. These cells were able to migrate into the retina when applied intravitreally, and although their differentiation to photoreceptors was limited, they enhanced photoreceptor viability in a retinal degeneration model.<sup>10,11</sup> Similarly, in another study where ESC-derived neural cells were applied subretinally and intravitreally in rats, the cells showed good retinal integration and a neuroprotective effect despite limited differentiation into photoreceptors.<sup>12</sup>

The results obtained with ESC-derived RPE cell transplantation are quite successful. Improvements in photoreceptor function and increased visual performance were observed in studies using a rat MERTK-defective retinal degeneration model.<sup>13,14,15</sup> Lu et al.<sup>16</sup> observed improvement in computerized assessments of visual function and visual field after the use of human ESC-derived RPE cells in rats, and showed with post-enucleation histological examinations that the cells survived for 200 days.

Following promising results from experimental studies, the US FDA approved the launch of phase I/II stem cell clinical trials for retinal diseases in humans in 2010. Human ESC-derived RPE (MA09-hRPE) cells were used in this study, which was conducted in centers across Europe and America and was supported by Advanced Cell Technology (now called Ocata Therapeutics). Schwartz et al.<sup>17</sup> published the first results of this study in 2012. In the preliminary report, no signs of negative proliferation, tumor formation, ectopic tissue development, or rejection were observed in 4 months of follow-up after subretinal application in one patient with Stargardt macular dystrophy and one patient with dry-type age-related macular degeneration (AMD).

Later, the 22-month follow-up results of 9 AMD patients and 9 Stargardt macular dystrophy patients were presented. Best corrected visual acuity (BCVA) increased in 10 cases while it remained stable in 7 cases and deteriorated by more than 10

letters in 1 case. There was no improvement in the patients' untreated fellow eyes. Vision-related quality of life scoring at the end of one year increased by 25 points in cases of AMD and by 20 points in cases of Stargardt macular dystrophy. This is the first study to report the medium/long-term results of stem cell application in degenerative retinal diseases.<sup>18</sup>

Another recent report publishes the findings of a clinical trial in which ESC-derived RPE cells (MA09-hRPE) were applied to the subretinal space in a total of four cases, two with dry AMD and two with Stargardt macular dystrophy. No adverse side effects were observed in one year of follow-up. In terms of safety, there were no adverse outcomes such as uncontrolled proliferation, tumor formation, and ectopic tissue development during the 1-year follow-up period. Visual acuity improved by 9-19 letters in 3 of the patients and remained stable in the other. These findings support the safety of ESC-derived RPE cells.<sup>19</sup>

These initial human studies have opened the door for further research and encouraged the inclusion of patients with better visual acuity in future trials.

Advances in stem cell therapy will continue in future studies using different RPE transplant methods in different retinal disease groups.<sup>20</sup>

#### Studies on the Use of iPSCs

The reprogramming of adult somatic fibroblast cells into iPSCs possessing ESC-like properties is accomplished *in vitro* by directly transferring cell nuclei or using retroviruses or lentiviruses to express transcription factors.<sup>21,22,23</sup>

Although iPSCs are also pluripotent like ESCs, they differ from ESCs in some respects. Because iPSCs are autologous, there is less risk of rejection and therefore, less need for immunosuppression. However, some iPSCs may trigger the T cell-mediated immune response due to their abnormal genetic composition.<sup>24</sup> Furthermore, the many passages made during the production of both iPSCs and ESCs gives rise to certain risks. Stimulation of X-linked oncogenes, suppression of tumor suppressor genes, and the high *in vitro* growth rate all increase the risk of tumor formation.<sup>25,26</sup> Tumor formation is believed to result from incompletely differentiated iPSCs. It is reported in preclinical models that if tumor growth occurs, it does so within the first 3-6 months.<sup>27,28</sup>

Studies using iPSCs in rats have reported improvement in retinal functions assessed with electroretinogram (ERG).<sup>29,30</sup> In an experimental study, Li et al.<sup>31</sup> found that human iPSCs could differentiate into RPE cells and increase retinal functions in rats. The iPSC-derived RPE cells expressed RPE cell markers, the rats showed improved ERG responses compared to the control group. This demonstrated that the cells were both morphologically and functionally RPE-like and safe. No tumors developed in any of the 34 rats used in the experiment.<sup>31</sup>

Human clinical trials were planned after obtaining encouraging results in experimental studies. A study was initiated in Japan investigating autologous use of iPSCs derived from a patient's epithelial cells.<sup>32</sup> Epithelial cells collected from the patient were transformed into RPE cells *in vitro* and transplanted subretinally to the same patient. This procedure was conducted on only one patient. The study was discontinued in March 2015 before repeating the procedure with a second patient. Two reasons were stated for this: 1) The regenerative medicine laws that were newly introduced in Japan prevented the continuation of the study, and 2) a genetic mutation which was not present in the original cells was detected in the iPSCs of the second patient. This was believed to be a result of mutations occurring during the induction and reprogramming process.<sup>33</sup>

#### Studies on the Use of MSCs

MSCs have a high proliferative capacity and can differentiate into cells of mesodermal, ectodermal, and endodermal origin. MSCs can be obtained from many tissues such as cord blood, peripheral blood, teeth, the central nervous system, liver, and especially bone marrow and adipose tissue. Adipose tissue is easily obtained under local anesthesia and the number of MSCs in this tissue is quite high. The acquired cells can be easily expanded in culture medium and maintain their stemness properties even after many passages. These features make adipose tissue a desirable source of stem cells.<sup>34,35,36</sup>

Many studies have shown that MSCs can differentiate into neuron-like cells. In addition, MSCs can repair damaged cells through their paracrine action. These cells secrete growth factors such as neurotrophic factors, repair synaptic connections, and promote the formation of functional connections.<sup>37,38</sup> In an experimental ocular hypertension rat model, MSCs were found to have a neuroprotective effect after intravitreal application.<sup>39</sup> Furthermore, MSCs have a strong immunosuppressive effect and inhibit the release of proinflammatory cytokines. For this reason, both allogenic and autologous transplantation are possible. In addition, they do not cause tumor formation and there is no ethical debate regarding their use.<sup>40</sup> Due to these advantages, MSCs were first applied experimentally, after which clinical trials were initiated for different disease groups in humans.

Subretinal application of MSCs repaired degenerating retinas in retinal degeneration models in rats.<sup>41,42,43</sup> An experimental study showed that rat MSCs obtained from culture activate Müller cell differentiation and exerted a paracrine effect by secreting growth factors. It was also reported in experimental studies that factors secreted from human MSCs prevent light-induced retinal damage.<sup>43,44</sup>

Studies have shown that MSCs can differentiate into different retinal cell types. Huang et al.<sup>45</sup> reported that MSCs differentiated into RPE-like cells with similar morphological features. Their study also demonstrated that they could

replace damaged cells when applied to damaged retinas. In an experimental study by Castanheira et al.<sup>46</sup>, MSCs were injected into the vitreous chamber in a model of laser-induced retinal damage. After 8 weeks, they found that most of the MSCs had migrated to the ganglion cell layer and inner and outer nuclear layers, and that they expressed photoreceptor, bipolar cell, amacrine cell, and Müller glial cell markers.<sup>46</sup> In addition, based on findings that MSCs survive for 90 days in rat vitreous and for 6 months in other retinal tissues, these cells are considered a promising option for the treatment of degenerative retinal diseases.<sup>47</sup>

The positive results of experimental studies have encouraged the planning of clinical trials. In a prospective phase I study, a single dose of intravitreal autologous bone marrow-derived MSCs was applied to 3 patients with retinitis pigmentosa (RP) and 2 with cone-rod dystrophy, and no significant structural or functional toxicity was observed in the retinas in 10 months of follow-up. In the study, conducted by Siqueira et al.<sup>48</sup>, four of the patients had an increase of 1 row in BCVA at 1 week after injection and this increase was preserved in follow-up. In a continuation of this study, MSCs were applied intravitreally to 20 patients who were followed for 1 year. The authors reported a statistically significant improvement in the patients' vision-related quality of life scores at 3 months, though the scores had returned to initial levels at 12 months. Therefore, the improvement seems to disappear over time.<sup>49</sup>

In another study by Park et al.<sup>50</sup>, 3.4 million bone marrow-derived MSCs were injected intravitreally into 6 eyes with irreversible vision loss (retinal vascular diseases, hereditary or non-exudative AMD, RP). This treatment was well tolerated, with no intraocular inflammation or proliferation, and no decline in ERG and BCVA results after 6 months of follow-up.

No systemic side effects were observed in a reliability study of adipose-derived MSCs. Of the 14 case series, epiretinal membrane formation over the injection site extending to the macula was observed in 5 patients. Localized tractional detachment occurred due to membrane development on the peripheral retina, and the patients required repeat vitrectomy. One patient developed a choroidal neovascular membrane which was treated with a single dose of anti-vascular endothelial growth factor agent.<sup>51</sup>

As MSC applications increase in number, so do reports of ocular complications related to this treatment. Kuriyan et al.<sup>52</sup> described three patients with elevated intraocular pressure, hemorrhagic retinopathy, and vitreous hemorrhage after intravitreal application of autologous adipose tissue-derived MSCs. They reported that the patients developed combined tractional and rhegmatogenous retinal detachment during follow-up and lost their vision. In another case report, autologous bone marrow-derived MSCs led to improved visual acuity in 2 of 3 patients with advanced RP; however, starting in the second week, the other patient developed preretinal and vitreal fibrous tissue, shallowing of the anterior chamber, and

cyclitic membrane formation resulting in ocular hypotonia. This patient developed total tractional retinal detachment and subsequently lost their vision within 3 months.<sup>53</sup>

The suprachoroidal application described by Limoli et al.<sup>54</sup> may prevent the vitreoretinal complications reported after intravitreal and subretinal applications. No complications were observed and visual function improved in 36 eyes of 25 patients with dry AMD at 6 months after adipose-derived MSCs were applied under a deep scleral flap in the suprachoroidal area.

## Conclusion

The results reported for phase I/II trials of stem cell applications are quite successful. No systemic side effects were observed in any of the studies. In addition, serious ocular side effects such as tumor formation and uncontrolled proliferation have not been observed. The reported improvements in visual function are encouraging and promising. However, it should not be forgotten that sight-threatening vitreoretinal complications can develop after intravitreal and subretinal applications. Larger studies with longer follow-up periods are needed to determine the place that this treatment will hold in the future. There are currently many studies in progress regarding the use of stem cells in different retinal diseases, and the results are highly anticipated.

## Ethics

**Peer-review:** Externally and internally peer-reviewed.

**Financial Disclosure:** The authors declared that this study received no financial support.

## References

- Zarbin M. Cell-Based Therapy for Degenerative Retinal Disease. *Trends Mol Med.* 2016;22:115-134.
- Siqueira RC. Stem cell therapy for retinal diseases: update. *Stem Cell Res Ther.* 2011;2:50.
- Shintani K, Shechtman DL, Gurwood AS. Review and update: Current treatment trends for patients with retinitis pigmentosa. *Optometry.* 2009;80:384-401.
- Bennicelli JL, Bennett J. Stem cells set their sights on retinitis pigmentosa. *ELife.* 2013;2:e01291.
- Uy HS, Chan PS, Cruz FM. Stem Cell Therapy: a Novel Approach for Vision Restoration in Retinitis Pigmentosa. *Med Hypothesis Discov Innov Ophthalmol.* 2013;2:52-55.
- Chung Y, Klimanskaya I, Becker S, Li T, Maserati M, Lu SJ, Zdravkovic T, Illic D, Genbacev O, Fisher S, Krtolica A, Lanza R. Human embryonic stem cell lines generated without embryo destruction. *Cell Stem Cell.* 2008;2:113-117.
- Yu J, Vodyanik MA, Smuga-Otto K, Antosiewicz-Bourget J, Frane JL, Tian S, Nie J, Jonsdottir GA, Ruotti V, Stewart R, Slukvin II, Thomson JA. Induced pluripotent stem cell lines derived from human somatic cells. *Science.* 2007;318:1917-1920.
- Tucker BA, Mullins RF, Stone EM. Stem cells for investigation and treatment of inherited retinal disease. *Human Mol Genet.* 2014;23:9-16.
- Whiting P, Kerby J, Coffey P, da Cruz L, McKernan R. Progressing a human embryonic stem-cell-based regenerative medicine therapy towards the clinic. *Philos Trans R Soc Lond B Biol Sci.* 2015;370:20140375.

10. Meyer JS, Katz ML, Maruniak JA, Kirk MD. Neural differentiation of mouse embryonic stem cells in vitro and after transplantation into eyes of mutant mice with rapid retinal degeneration. *Brain Res.* 2004;1014:131-144.
11. Meyer JS, Katz ML, Maruniak JA, Kirk MD. Embryonic stem cell-derived neural progenitors incorporate into degenerating retina and enhance survival of host photoreceptors. *Stem Cells.* 2006;24:274-283.
12. Banin E, Obolensky A, Idelson M, Hemo I, Reinhardt E, Pikarsky E, Ben-Hur T, Reubinoff B. Retinal incorporation and differentiation of neural precursors derived from human embryonic stem cells. *Stem Cells.* 2006;24:246-257.
13. Idelson M, Alper R, Obolensky A, Ben-Shushan E, Hemo I, Yachimovich-Cohen N, Khaner H, Smith Y, Wisner O, Gropp M, Cohen MA, Even-Ram S, Berman-Zaken Y, Matzrafi L, Rechavi G, Banin E, Reubinoff B. Directed differentiation of human embryonic stem cells into functional retinal pigment epithelium cells. *Cell Stem Cell.* 2009;5:396-408.
14. Lund RD, Wang S, Klimanskaya I, Holmes T, Ramos-Kelsey R, Lu B, Girman S, Bischoff N, Sauve Y, Lanza R. Human embryonic stem cell-derived cells rescue visual function in dystrophic RCS rats. *Cloning Stem Cells.* 2006;8:189-199.
15. Vugler A, Carr AJ, Lawrence J, Chen LL, Burrell K, Wright A, Lundh P, Semo M, Ahmado A, Gias C, da Cruz L, Moore H, Andrews P, Walsh J, Coffey P. Elucidating the phenomenon of HESC-derived RPE: anatomy of cell genesis, expansion and retinal transplantation. *Exp Neurol.* 2008;214:347-361.
16. Lu B, Malcuit C, Wang S, Girman S, Francis P, Lemieux L, Lanza R, Lund R. Long-term safety and function of RPE from human embryonic stem cells in preclinical models of macular degeneration. *Stem Cells.* 2009;27:2126-2135.
17. Schwartz SD, Hubschman JP, Heilwell G, Franco-Cardenas V, Pan CK, Ostrick RM, Mickunas E, Gay R, Klimanskaya I, Lanza R. Embryonic stem cell trials for macular degeneration: a preliminary report. *Lancet.* 2012;379:713-20.
18. Schwartz SD, Regillo CD, Lam BL, Elliott D, Rosenfeld PJ, Gregori NZ, Hubschman JP, Davis JL, Heilwell G, Spirn M, Maguire J, Gay R, Bateman J, Ostrick RM, Morris D, Vincent M, Anglade E, Del Priore LV, Lanza R. Human embryonic stem cell-derived retinal pigment epithelium in patients with age-related macular degeneration and Stargardt's macular dystrophy: follow-up of two open-label phase 1/2 studies. *Lancet.* 2015;385:509-516.
19. Song WK, Park KM, Kim HJ, Lee JH, Choi J, Chong SY, Shim SH, Del Priore LV, Lanza R. Treatment of macular degeneration using embryonic stem cell-derived retinal pigment epithelium: preliminary results in Asian patients. *Stem Cell Reports.* 2015;4:860-872.
20. Schwartz SD, Tan G, Hosseini H, Nagiel A. Subretinal Transplantation of Embryonic Stem Cell-Derived Retinal Pigment Epithelium for the Treatment of Macular Degeneration: An Assessment at 4 Years. *Invest Ophthalmol Vis Sci.* 2016;57:ORSF1-9.
21. Takahashi K, Yamanaka S. Induction of pluripotent stem cells from mouse embryonic and adult fibroblast cultures by defined factors. *Cell.* 2006;126:663-676.
22. Takahashi K, Tanabe K, Ohnuki M, Narita M, Ichisaka T, Tomoda K, Yamanaka S. Induction of pluripotent stem cells from adult human fibroblasts by defined factors. *Cell.* 2007;131:861-872.
23. Takahashi K, Okita K, Nakagawa M, Yamanaka S. Induction of pluripotent stem cells from fibroblast cultures. *Nat Protoc.* 2007;2:3081-3089.
24. Zhao T, Zhang ZN, Rong Z, Xu Y. Immunogenicity of induced pluripotent stem cells. *Nature.* 2011;13:474:212-215.
25. Chin MH, Mason MJ, Xie W, Volinia S, Singer M, Peterson C, Ambartsumyan G, Aimiwu O, Richter L, Zhang J, Khvorostov I, Ott V, Grunstein M, Lavon N, Benvenisty N, Croce CM, Clark AT, Baxter T, Pyle AD, Teitell MA, Pelegrini M, Plath K, Lowry WE. Induced pluripotent stem cells and embryonic stem cells are distinguished by gene expression signatures. *Cell Stem Cell.* 2009;5:111-123.
26. Stadtfeld M, Apostolou E, Akutsu H, Fukuda A, Follett P, Natesan S, Kono T, Shioda T, Hochedlinger K. Aberrant silencing of imprinted genes on chromosome 12qF1 in mouse induced pluripotent stem cells. *Nature.* 2010;465:175-181.
27. Lister R, Pelizzola M, Kida YS, Hawkins RD, Nery JR, Hon G, Antosiewicz-Bourget J, O'Malley R, Castanon R, Klugman S, Downes M, Yu R, Stewart R, Ren B, Thomson JA, Evans RM, Ecker JR. Hotspots of aberrant epigenomic reprogramming in human induced pluripotent stem cells. *Nature.* 2011;471:68-73.
28. Zhao T, Xu Y. p53 and stem cells: new developments and new concerns. *Trends Cell Biol.* 2010;20:170-175.
29. Carr AJ, Vugler AA, Hikita ST, Lawrence JM, Gias C, Chen LL, Buchholz DE, Ahmado A, Semo M, Smart MJ, Hasan S, da Cruz L, Johnson LV, Clegg DO, Coffey PJ. Protective effects of human iPS-derived retinal pigment epithelium cell transplantation in the retinal dystrophic rat. *PLoS One.* 2009;4:8152.
30. Tucker BA, Park IH, Qi SD, Klassen HJ, Jiang C, Yao J, Redenti S, Daley GQ, Young MJ. Transplantation of adult mouse iPS cell-derived photoreceptor precursors restores retinal structure and function in degenerative mice. *PLoS One.* 2011;6:18992.
31. Li Y, Tsai YT, Hsu CW, Erol D, Yang J, Wu WH, Davis RJ, Egli D, Tsang SH. Long-term safety and efficacy of human-induced pluripotent stem cell (iPS) grafts in a preclinical model of retinitis pigmentosa. *Mol Med.* 2012;18:1312-1319.
32. Garber K. RIKEN suspends first clinical trial involving induced pluripotent stem cells. *Nat Biotechnol.* 2015;33:890-891.
33. Pera MF. Stem cells: The dark side of induced pluripotency. *Nature.* 2011;471:46-47.
34. He Y, Zhang Y, Liu X, Ghazaryan E, Li Y, Xie J, Su G. Recent Advances of Stem Cell Therapy for Retinitis Pigmentosa. *Int J Mol Sci.* 2014;15:14456-14474.
35. Bharti K, Rao M, Hull SC, Stroncek D, Brooks BP, Feigl E, van Meurs JC, Huang CA, Miller SS. Developing cellular therapies for retinal degenerative diseases. *Invest Ophthalmol Vis Sci.* 2014;55:1191-1202.
36. Harasymiak-Krzyanowska I, Niedojadło A, Karwat J, Kotuła L, Gil-Kulik P, Sawiuk M, Kocki J. Adipose tissue-derived stem cells show considerable promise for regenerative medicine applications. *Cell Mol Biol Lett.* 2013;18:479-493.
37. Huo DM, Dong FT, Yu WH, Gao F. Differentiation of mesenchymal stem cell in the microenvironment of retinitis pigmentosa. *Int J Ophthalmol.* 2010;3:216-219.
38. Konno M, Hamabe A, Hasegawa S, Ogawa H, Fukusumi T, Nishikawa S, Ohta K, Kano Y, Ozaki M, Noguchi Y, Sakai D, Kudoh T, Kawamoto K, Eguchi H, Satoh T, Tanemura M, Nagano H, Doki Y, Mori M, Ishii H. Adipose-derived mesenchymal stem cells and regenerative medicine. *Dev Growth Differ.* 2013;55:309-318.
39. Emre E, Yüksel N, Duruksu G, Pirhan D, Subaşı C, Erman G, Karaöz E. Neuroprotective effects of intravitreally transplanted adipose tissue and bone marrow-derived mesenchymal stem cells in an experimental ocular hypertension model. *Cytotherapy.* 2015;17:543-559.
40. Chen PM, Yen ML, Liu KJ, Sytwu HK, Yen BL. Immunomodulatory properties of human adult and fetal multipotent mesenchymal stem cells. *J Biomed Sci.* 2011;18:49.
41. Sugitani S, Tsuruma K, Ohno Y, Kuse Y, Yamauchi M, Egashira Y, Yoshimura S, Shimazawa M, Iwama T, Hara H. The potential neuroprotective effect of human adipose stem cells conditioned medium against light-induced retinal damage. *Exp Eye Res.* 2013;116:254-264.
42. Guan Y, Cui L, Qu Z, Lu L, Wang F, Wu Y, Zhang J, Gao F, Tian H, Xu L, Xu G, Li W, Jin Y, Xu GT. Subretinal transplantation of rat MSCs and erythropoietin gene modified rat MSCs for protecting and rescuing degenerative retina in rats. *Curr Mol Med.* 2013;13:1419-1431.
43. Jian Q, Li Y, Yin ZQ. Rat BMSCs initiate retinal endogenous repair through NGF/TrkA signaling. *Exp Eye Res.* 2015;132:34-47.
44. Tsuruma K, Yamauchi M, Sugitani S, Otsuka T, Ohno Y, Nagahara Y, Ikegame Y, Shimazawa M, Yoshimura S, Iwama T, Hara H. Progranulin, a major secreted protein of mouse adipose-derived stem cells, inhibits light-induced retinal degeneration. *Stem Cells Transl Med.* 2014;3:42-53.
45. Huang C, Zhang J, Ao M, Li Y, Zhang C, Xu Y, Li X, Wang W. Combination of retinal pigment epithelium cell-conditioned medium and photoreceptor outer segments stimulate mesenchymal stem cell differentiation toward a functional retinal pigment epithelium cell phenotype. *J Cell Biochem.* 2012;113:590-598.

46. Castanheira P, Torquetti L, Nehemy MB, Goes AM. Retinal incorporation and differentiation of mesenchymal stem cells intravitreally injected in the injured retina of rats. *Arq Bras Oftalmol.* 2008;71:644-650.
47. Haddad-Mashadrizeh A, Bahrami AR, Matin MM, Edalatmanesh MA, Zomorodipour A, Gardaneh M, Farshchian M, Momeni-Moghaddam M. Human adipose-derived mesenchymal stem cells can survive and integrate into the adult rat eye following xenotransplantation. *Xenotransplantation.* 2013;20:165-176.
48. Siqueira RC, Messias A, Voltarelli JC, Scott IU, Jorge R. Intravitreal injection of autologous bone marrow-derived mononuclear cells for hereditary retinal dystrophy: a phase I trial. *Retina.* 2011;31:1207-1214.
49. Siqueira RC, Messias A, Messias K, Arcieri RS, Ruiz MA, Souza NF, Martins LC, Jorge R. Quality of life in patients with retinitis pigmentosa submitted to intravitreal use of bone marrow-derived stem cells (Reticell -clinical trial) *Stem Cell Res Ther.* 2015; 6:29.
50. Park SS, Bauer G, Abedi M, Pontow S, Panorgias A, Jonnal R, Zawadzki RJ, Werner JS, Nolta J. Intravitreal autologous bone marrow CD34+ cell therapy for ischemic and degenerative retinal disorders: preliminary phase 1 clinical trial findings. *Invest Ophthalmol Vis Sci.* 2014;56:81-89.
51. Oner A, Gonen ZB, Sinim N, Cetin M, Ozkul Y. Subretinal adipose tissue-derived mesenchymal stem cell implantation in advanced stage retinitis pigmentosa: a phase I clinical safety study. *Stem Cell Res Ther.* 2016;7:178.
52. Kuriyan AE, Albin TA, Townsend JH, Rodriguez M, Pandya HK, Leonard RE 2nd, Parrot MB, Rosenfeld PJ, Flynn HW Jr, Goldberg JL. Vision Loss after Intravitreal Injection of Autologous "Stem Cells" for AMD. *N Engl J Med.* 2017;376:1047-1053.
53. Satarian L, Nourinia R, Safi S, Kanavi MR, Jarughi N, Daftarian N, Arab L, Aghdami N, Ahmadi H, Baharvand H. Intravitreal Injection of Bone Marrow Mesenchymal Stem Cells in Patients with Advanced Retinitis Pigmentosa; a Safety Study. *J Ophthalmic Vis Res.* 2017;12:58-64.
54. Limoli PG, Limoli C, Vingolo EM, Scalinci SZ, Nebbioso M. Cell surgery and growth factors in dry age-related macular degeneration: visual prognosis and morphological study. *Oncotarget.* 2016;7:46913-46923.



## Primary Conjunctival Tuberculosis

Nilgün Solmaz\*, Feyza Önder\*, Nedime Demir\*, Özlem Altuntaş Aydın\*\*

\*University of Health Sciences, Haseki Training and Research Hospital, Ophthalmology Clinic, İstanbul, Turkey

\*\*University of Health Sciences, Dr. Sadi Konuk Training and Research Hospital, Infectious Disease and Clinical Microbiology Clinic, İstanbul, Turkey

### Abstract

A 12-year-old girl was referred to our clinic because of unilateral conjunctivitis not responding to treatment. In the left eye, lower bulbar and tarsal conjunctiva had a polypoidal appearance due to micronodules and there was a subconjunctival nodular mass in the inferior fornix. Systemic examination was unremarkable except for a left preauricular lymphadenopathy. Excision biopsy of the subconjunctival mass revealed a granulomatous inflammation with caseation necrosis, but acid-fast bacilli (AFB) was negative. Fine needle-aspiration biopsy of the preauricular lymph node was performed. In microbiological examination, both AFB and mycobacterial culture were positive. The isolated mycobacteria strains were identified as *Mycobacterium tuberculosis* complex and full remission was achieved with 6 months of anti-tuberculosis treatment. Although primary tuberculous conjunctivitis is a very rare condition, it should be considered in the differential diagnosis of treatment-resistant unilateral conjunctivitis. For definitive diagnosis, microbiological and histopathological examinations should be performed both in conjunctiva and regional lymph node.

**Keywords:** Conjunctival tuberculosis, tuberculous conjunctivitis, tuberculosis

### Introduction

Conjunctival tuberculosis is a rare condition. The first definitive conjunctival tuberculosis case was recorded by Koaster in 1873 and numerous cases were reported until the early part of the 20<sup>th</sup> century.<sup>1</sup> In 1912, Eyre<sup>1</sup> reviewed a total of 206 cases with their 24 cases and described the characteristics of conjunctival tuberculosis in detail. Since then, conjunctival involvement has gradually decreased due to advances in the treatment of pulmonary tuberculosis.<sup>2</sup> In recent decades, only isolated case reports of conjunctival tuberculosis have been published.<sup>3,4,5,6,7,8,9</sup> Conjunctival involvement is usually through direct inoculation of the organism to the conjunctiva or with contagious spread.<sup>1,2</sup> Conjunctival lesions are generally accompanied by regional lymphadenopathy, but the association with pulmonary tuberculosis is rare.<sup>1</sup> For definitive diagnosis, *Mycobacterium tuberculosis* organisms must be identified in conjunctival biopsy specimens by direct microscopy or culture.<sup>9</sup>

Histopathological examination and molecular techniques such as polymerase chain reaction (PCR) are also helpful in diagnosis.<sup>3,4</sup>

### Case Report

A 12-year-old girl was referred to our clinic in July 2011 with treatment-resistant unilateral conjunctivitis. Conjunctival culture had been done several times, but no pathogen had been detected. She had been diagnosed with adenoviral conjunctivitis and treated with various topical antibiotics and corticosteroids for 4 months; however, the symptoms had progressed gradually despite treatment. On examination, her uncorrected visual acuity was 20/20 in both eyes. Examination of the right eye was unremarkable. In the left eye, the conjunctiva was hyperemic and the lower eyelid was slightly edematous (Figure 1a). There was a subconjunctival nodular mass in the inferior fornix. Biomicroscopic examination showed that the lower bulbar and tarsal conjunctiva had a polypoidal appearance due to multiple micronodules and mucopurulent discharge (Figure 1b). The rest

**Address for Correspondence:** Nilgün Solmaz MD, University of Health Sciences, Haseki Training and Research Hospital, Ophthalmology Clinic, İstanbul, Turkey  
Phone: +90 216 533 03 01 E-mail: nilgünsolmaz@hotmail.com **ORCID-ID:** orcid.org/0000-0003-2173-3951

**Received:** 13.05.2017 **Accepted:** 17.08.2017

©Copyright 2018 by Turkish Ophthalmological Association  
Turkish Journal of Ophthalmology, published by Galenos Publishing House.

of the ocular examination was normal. Systemic examination was unremarkable except for an enlarged left preauricular lymph node. Since previous conjunctival cultures were negative, we initially suspected a non-infectious granulomatous disease and ordered laboratory tests. Hematologic and biochemical parameters including hemoglobin, white cell count and differential, erythrocyte sedimentation rate, liver function tests, electrolytes, urea, creatinine, glucose, C-reactive protein, angiotensin-converting enzyme and antineutrophilic cytoplasmic antibodies levels were normal. Human immunodeficiency virus testing and syphilis serology were negative. Chest radiography findings were normal, and there were no enlarged hilar lymph nodes. A computed tomography scan of the orbits showed preseptal thickening of the left eyelid and a cystic lesion 1.5 cm in diameter under the skin in the left preauricular region.

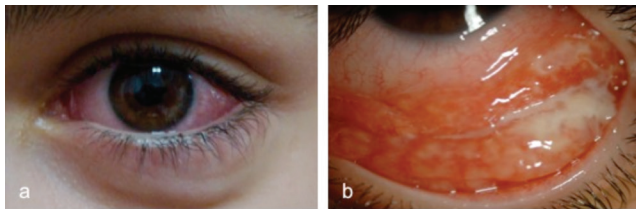The subconjunctival mass was excised totally. Histopathological examination revealed a granulomatous inflammation with extensive caseous necrosis, but Ziehl Neelsen staining for acid-fast bacilli (AFB) was negative. Meanwhile, the preauricular lymph node enlarged and became fluctuant (Figure 2a). Fine-needle aspiration biopsy of the preauricular

lymph node was performed. In microbiological examination, both AFB (Figure 2b) and mycobacterial culture (MGIT 960, Becton Dickinson) were positive. The isolated mycobacteria strains were identified as *Mycobacterium tuberculosis* complex by MGIT TBc identification test (MGIT 960, Becton, Dickinson and Company Sparks, USA) and determined sensitive to first-line antituberculosis drugs using the MGIT 960 system (Becton Dickinson, USA). Systemic examination and investigations were repeated for systemic tuberculosis. Sputum, gastric aspirate and urine showed no AFB, and cultures were negative. Her family screening for tuberculosis was also negative. As there was no evidence for systemic tuberculosis in other parts of the body, her diagnosis was considered primary conjunctival tuberculosis. A 4-drug antituberculosis treatment regimen was initiated with isoniazid 10 mg/kg, rifampicin 10 mg/kg, pyrazinamide 20 mg/kg, and streptomycin 1 g/day. A month later, the dose of streptomycin was reduced to 2 g/week. At the end of the second month, pyrazinamide and streptomycin were stopped, isoniazid and rifampicin were continued for 6 months. The conjunctival lesions showed significant improvement in the third month and completely resolved by the end of treatment (Figure 3a, b). The lymph node abscess burst spontaneously and healed with scarring. No recurrence was observed in a 2-year follow-up period.

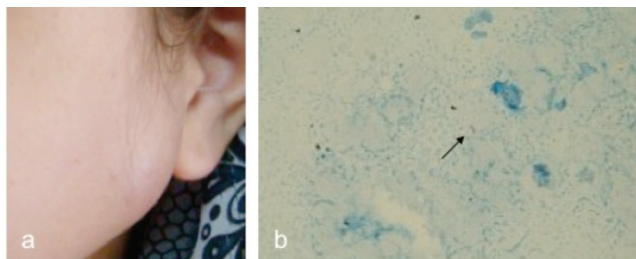
## Discussion

Tuberculosis is still an important global health problem. According to the World Health Organization (WHO), in 2011, there were an estimated 8.7 million new cases of tuberculosis globally, equivalent to 125 cases per 100,000 population. About 60% of cases are in the South-East Asia and Western Pacific regions. The African region has 24% of the world's cases.<sup>10</sup> Although tuberculosis is widespread worldwide, conjunctival involvement is very rare. Most of the cases reported in recent decades have come from endemic regions;<sup>3,4</sup> however, there have been a few case reports from developed countries.<sup>5,6,7,8,9</sup>

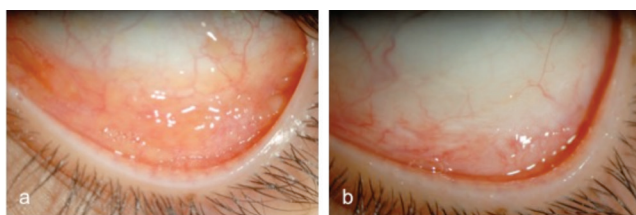
Turkey is in the WHO European region and has a relatively high tuberculosis incidence rate, 28 cases per 100,000 population.<sup>10</sup> In Turkey, a few cases of primary ocular and orbital tuberculosis were published previously,<sup>11,12,13</sup> but to our knowledge, no cases of primary conjunctival tuberculosis have been reported. Moreover, only 4 cases of conjunctival tuberculosis have been reported from the WHO European region in last 5 decades.<sup>5,6,7,8</sup> Three of the cases were diagnosed with primary conjunctival tuberculosis. Interestingly, these three cases were health professionals (general practitioner, microbiologist, and radiologist) who often encountered *Mycobacterium tuberculosis* and it was thought that the conjunctival lesions were probably due to direct inoculation of mycobacteria to the conjunctiva.<sup>6,7,8</sup> Our patient was a 12-year-old student and her family screening for tuberculosis is negative. It could not be determined where she came into contact with tuberculosis and how the conjunctival inoculation occurred.



**Figure 1.** a) Conjunctivitis and lid edema due to subconjunctival nodular mass in the lower fornix. b) The lower bulbar and tarsal conjunctiva were congested and had a polypoidal appearance due to multiple micro nodules. There were mucopurulent secretion and fibrinous membranes over the ulcerated areas



**Figure 2.** a) The enlarged and fluctuant preauricular lymph node. b) Acid-fast bacillus in the fine needle aspiration biopsy of the enlarged preauricular lymph node



**Figure 3.** a) In the third month of treatment, there was marked reduction in the conjunctival lesions. b) The conjunctival lesions were completely resolved at the end of treatment



Today, it is very unlikely that tuberculosis would come to mind as a cause of conjunctivitis, even in endemic areas.<sup>4</sup> Furthermore, variations in the clinical picture complicate the diagnosis. Eyre<sup>1</sup> classified the conjunctival lesions as ulcerative, nodular, hypertrophic granulomatous and pedunculated masses based on the morphological characteristics. In our case, the morphological features of conjunctival lesions resembled nodular and hypertrophic granulomatous types. However, a diagnosis cannot be established on the basis of the lesions' morphological features. We initially suspected a systemic granulomatous disease such as sarcoidosis, due to the chronic and refractory symptoms. The possibility of tuberculosis conjunctivitis was considered when histopathological examination of the subconjunctival nodule revealed granulomatous inflammation with caseous necrosis.

The definitive diagnosis of conjunctival tuberculosis requires identification of mycobacterium organisms in biopsy specimens by direct microscopy or culture. However, detection of mycobacteria may not be possible in small biopsy samples. In cases in which AFB and culture are negative, PCR amplification of mycobacterial DNA fragments in the tissue or biopsy specimens can be useful in the diagnosis.<sup>4,13,14</sup> In our case, the conjunctival biopsy was negative for AFB. Fortunately, the preauricular lymph node was fluctuant and microbiological examination of lymph node biopsy confirmed the diagnosis of conjunctival tuberculosis.

Although primary tuberculous conjunctivitis is now a very rare entity, it should be considered in the differential diagnosis of unilateral chronic conjunctivitis not responding to treatment. For definitive diagnosis, microbiological and histopathological examinations should be performed both in the conjunctiva and regional lymph nodes.

#### Ethics

**Informed Consent:** It was taken.

**Peer-review:** Externally and internally peer-reviewed.

#### Authorship Contributions

Surgical and Medical Practices: Nilgün Solmaz, Feyza Önder, Nedime Demir, Özlem Altuntaş Aydın, Concept: Nilgün Solmaz,

Design: Nilgün Solmaz, Data Collection or Processing: Nilgün Solmaz, Analysis or Interpretation: Nilgün Solmaz, Feyza Önder, Özlem Altuntaş Aydın, Literature Search: Nilgün Solmaz, Writing: Nilgün Solmaz.

**Conflict of Interest:** No conflict of interest was declared by the authors.

**Financial Disclosure:** The authors declared that this study received no financial support.

#### References

1. Eyre JWH. Tuberculosis of the conjunctiva: Its etiology, pathology and diagnosis. *Lancet*. 1912;18:1319-1329.
2. Sollom AW. Primary conjunctival tuberculosis. *Br J Ophthalmol*. 1967;51:685-687.
3. Biswas J, Kumar SK, Rupauliha P, Misra S, Bharadwaj I, Therese L. Detection of Mycobacterium Tuberculosis by nested polymerase chain reaction in a case of subconjunctival tuberculosis. *Cornea*. 2002;21:123-125.
4. Chaurasia S, Ramappa M, Murthy SI, Vemuganti GK, Fernandes M, Sharma S, Sangwan V. Chronic conjunctivitis due to Mycobacterium tuberculosis. *Int Ophthalmol*. 2014;34:655-660.
5. Pommier S, Chazalon E, Morand JJ, Meyer F. Chronic cicatrizing conjunctivitis in a patient with hemifacial cutaneous tuberculosis. *Br J Ophthalmol*. 2008;92:616:712-713.
6. Salas D, Murthy S, Champ C, Hawksworth N. Primary tuberculosis of the conjunctiva. *Eye (Lond)*. 2001;15:674-676.
7. Alcolea A, Suarez MJ, Lizasoain M, Tejada P, Chaves E, Palenque E. Conjunctivitis with regional lymphadenopathy in a trainee microbiologist. *J Clin Microbiol*. 2009;47:3043-3044.
8. Psathakis K, Mermigkis Ch, Vlachaki E, Pavlopoulos G, Skagias L, Skiadas V, Kokkonouzis I, Tsintiris K. Tuberculous conjunctivitis in a doctor. *Int J Tuberc Lung Dis*. 2008;12:228.
9. Jennings A, Bilous M, Asimakis P, Maloof AJ. Mycobacterium tuberculosis presenting as chronic red eye. *Cornea*. 2006;25:1118-1120.
10. WHO Global Tuberculosis Report 2012. Available at: [http://apps.who.int/iris/bitstream/10665/75938/1/9789241564502\\_eng.pdf](http://apps.who.int/iris/bitstream/10665/75938/1/9789241564502_eng.pdf)
11. Eser İ, Uçan G, Yazıcı B, Adım ŞB. Tuberculosis of the sclera. *Turkish J Ophthalmol*. 2008;38:350-352.
12. Yazıcı B, Aygül F, Yılmaz E. Orbital Tuberculosis: Two patients. *Turkish J Ophthalmol*. 2005;35:527-531.
13. Bayraktutar BN, Uçakhan-Gündüz Ö. Ocular Tuberculosis with Progressive Unilateral Corneal Melting. *Case Rep Ophthalmol*. 2015;6:293-297.
14. Dalvin LA, Smith WM. Orbital and external ocular manifestation of Mycobacterium tuberculosis: A review of the literature. *Journal of Clinical Tuberculosis and Other Mycobacterial Diseases*. 2016;4:50-57.



# Orbital Apex Syndrome Secondary to Herpes Zoster Ophthalmicus

© Gamze Kocaoğlu\*, © Canan Aslı Utine\*, © Aylin Yaman\*, © Süleyman Men\*\*

\*Dokuz Eylül University Faculty of Medicine, Department of Ophthalmology, İzmir, Turkey

\*\*Dokuz Eylül University Faculty of Medicine, Department of Radiology, İzmir, Turkey

## Abstract

Orbital apex syndrome is a rare complication of herpes zoster ophthalmicus. A patient being followed in our clinic for herpes zoster ophthalmicus developed orbital apex syndrome in the second week of treatment. Clinical diagnosis was supported by magnetic resonance imaging. Treatment with systemic steroid and antiviral therapy resulted in total regression of ophthalmoplegia at 2 months. However, optic neuropathy-induced vision loss was permanent. This case report examines orbital apex syndrome secondary to herpes zoster ophthalmicus, which has rarely been documented in the ophthalmic literature.

**Keywords:** Herpes zoster ophthalmicus, orbital apex syndrome, total ophthalmoplegia

## Introduction

Herpes zoster ophthalmicus (HZO) occurs due to reactivation of latent varicella zoster virus (VZV) infection in the trigeminal ganglion, which contains the ophthalmic branch of the trigeminal nerve. Ocular complications are seen in 20-70% of patients with HZO.<sup>1</sup> These complications can include blepharitis, keratoconjunctivitis, iritis, scleritis, and acute retinal necrosis. Neurologic complications are less common compared to ocular complications. Some of the neurological complications reported include ophthalmoplegia, optic neuritis, ptosis, and less frequently orbital apex syndrome (OAS).<sup>2</sup> OAS can lead to dysfunction of the ophthalmic branch of the trigeminal nerve (cranial nerve V1), oculomotor nerve (cranial nerve III), trochlear nerve (cranial nerve IV), abducens nerve (cranial nerve VI), and optic nerve (cranial nerve II). In this case report, we discuss our treatment and management of complications in a patient with HZO-related OAS.

## Case Report

A 67-year-old male patient presented to our clinic with rash and redness on the right upper eyelid and forehead.

He also complained of redness and pain in the right eye. On ophthalmologic examination, his best corrected visual acuity (BCVA) on Snellen chart was 0.2 in the right eye and 0.8 in the left eye. Direct and indirect light reflexes were intact bilaterally and there were no signs of relative afferent pupillary defect. In addition to the erythema and herpetiform vesicular desquamation observed on the right upper eyelid and frontal region, slit-lamp examination revealed corneal epithelial keratitis, 2+ cells in the anterior chamber, and keratic precipitates. The patient's systemic medical history was unremarkable except for diabetes mellitus (controlled with oral antidiabetic therapy for 10 years) and hypertension. The patient was diagnosed with HZO and treatment was initiated with oral valacyclovir (1000 mg 3 times daily), topical ganciclovir (5 times daily), ofloxacin drops (2 times daily), cyclopentolate drops (3 times daily), prednisolone acetate drops (6 times daily), and oral nonsteroid anti-inflammatory tablet (dexketoprofen trometamol, 25 mg, 2 times daily). At 2-week follow-up examination, the patient had no light reflex in his right eye with fixed, dilated pupil. He exhibited anisocoria with right and left pupil diameters of 6 mm and 3 mm, respectively. He also had relative afferent pupillary defect, total ptosis (Figure

**Address for Correspondence:** Canan Aslı Utine MD, Dokuz Eylül University Faculty of Medicine, Department of Ophthalmology, İzmir, Turkey

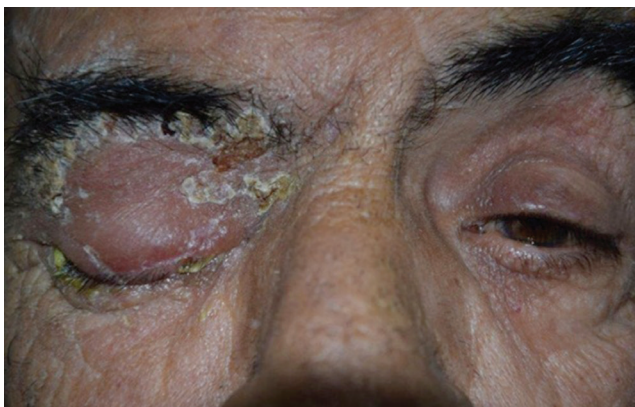Phone: +90 232 412 30 67 E-mail: cananutine@gmail.com **ORCID-ID:** orcid.org/0000-0002-4131-2532

**Received:** 04.02.2017 **Accepted:** 06.07.2017

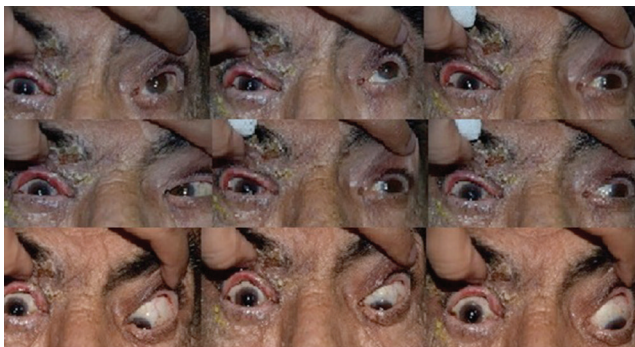©Copyright 2018 by Turkish Ophthalmological Association  
Turkish Journal of Ophthalmology, published by Galenos Publishing House.

1), and total ophthalmoplegia (Figure 2) in the right eye. BCVA was 0.2 on the right. Color vision score was 1/21 in the right and 21/21 in the left eye. Slit-lamp examination revealed persistent herpetic keratouveitis in the right eye. Papillary stasis was not observed on fundoscopic examination. However, fundus structures were pale due to choroidal ischemia when compared with the left eye (Figure 3). The macula appeared normal in both eyes on optical coherence tomography. Orbital magnetic resonance imaging (MRI) revealed non-mass enhancement in the right orbital apex (Figure 4a-e). On cranial magnetic resonance venography, venous thrombosis was detected in the left transverse sinus (Figure 5). In light of these findings, the patient was admitted to the Neurology inpatient unit with a diagnosis

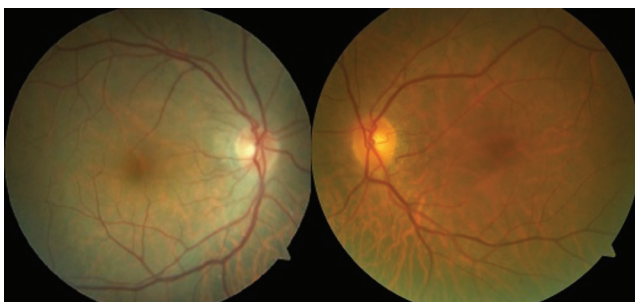
of OAS. He received pulse prednisolone treatment (500 mg/day), anticoagulant therapy (warfarin), and fixed combination dorzolamide/timolol (2 times daily) and brimonidine drops (2 times daily) to mitigate the retinal and choroidal hypoperfusion. After 5 days of pulse prednisolone therapy, the patient continued to receive oral prednisolone (100 mg/day) and maintenance dose of valacyclovir (1000 mg/day). Two months after the OAS diagnosis, the patient's BCVA in the right eye improved to 0.4, and the ptosis and extraocular muscle paralysis regressed (Figure 6). Fundoscopic examination at 2 months showed that the pallor persisted in the temporal aspect of the optic disc, but



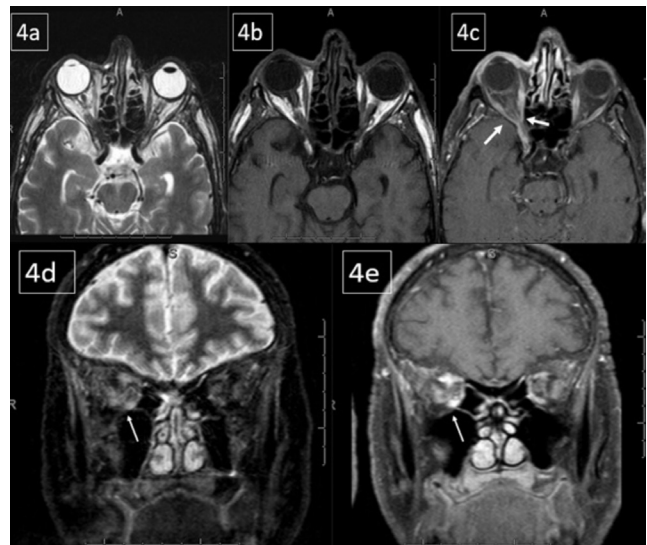
**Figure 1.** Total ptosis and ophthalmoplegia of the patient's right eye



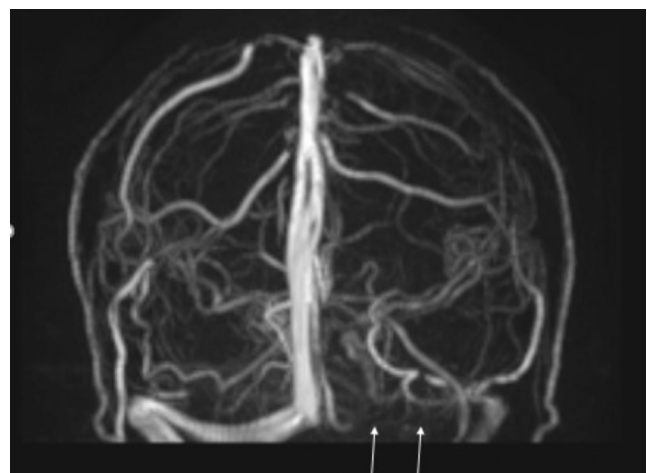
**Figure 2.** Right eye movements were restricted in all 9 positions of gaze



**Figure 3.** Fundus images of the right and left eyes: retinal pallor was observed in the right eye due to choroidal ischemia

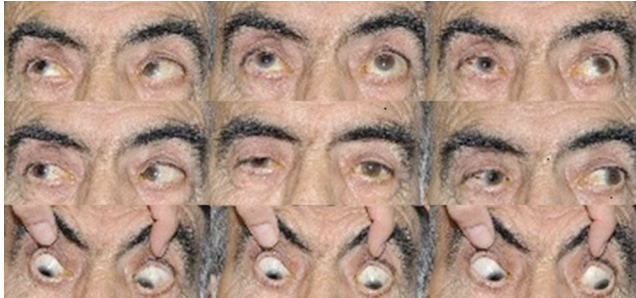

**Figure 4.** Orbital magnetic resonance imaging: The right orbital apex appeared overcrowded on axial T2-weighted (a), precontrast axial (b) and postcontrast (c) T1-weighted, coronal fat-suppressed T2-weighted (d), and postcontrast coronal fat-suppressed T1-weighted (e) images, and was especially pronounced in the postcontrast fat-suppressed axial and coronal T1-weighted sections (c and e). This appearance was caused by edematous thickening of the optic nerve sheath, contrast enhancement, and streaking in the fatty tissue

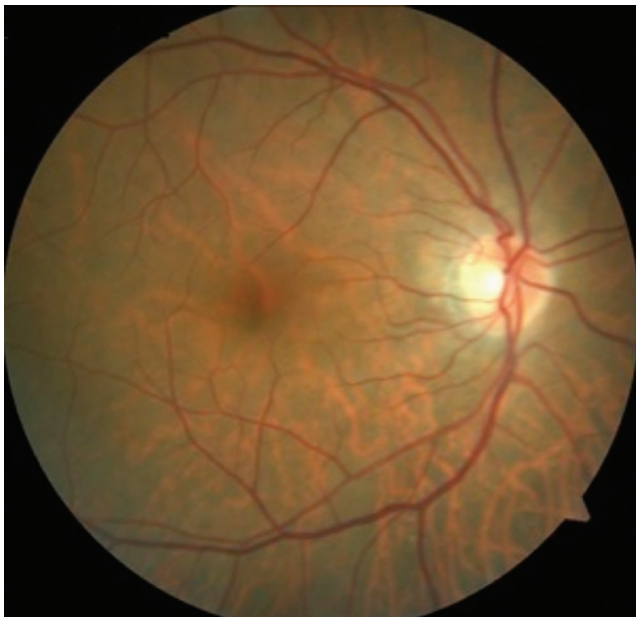

**Figure 5.** Brain magnetic resonance venography: no flow was observed in left transverse sinus (arrows)

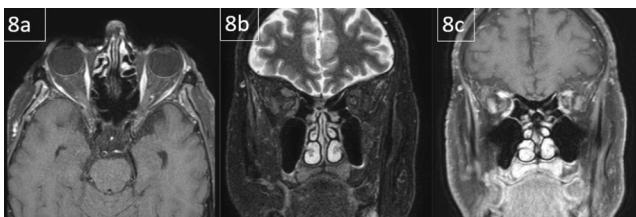
had diminished in the retinal tissue (Figure 7). The patient's right eye regained light reflex, although mild mydriasis was observed. The right eye still showed relative afferent pupillary defect. BCVA remained at 0.4, likely due to optic neuropathy. Follow-up MRI at 3 months demonstrated recanalization of the left transverse sinus and regression of the right orbital apex



**Figure 6.** Ptosis regressed and extraocular muscle paralysis fully resolved after 2 months



**Figure 7.** Fundus image of the patient at 2 months: retinal pallor was improved but persisted in the temporal aspect of the optic disc



**Figure 8.** Magnetic resonance imaging at 3-month follow-up: Inflammation in the right orbital apex was attenuated in the axial fat-suppressed poststrate T1-weighted (a), coronal fat-suppressed T2-weighted (b), and postcontrast coronal fat-suppressed T2-weighted sections (c). The overcrowded appearance was resolved and the optic nerve and surrounding structures could be clearly distinguished

inflammation. The optic nerve and surrounding structures were clearly discernible (Figures 8a-c). Anticoagulant therapy was discontinued at 3 months and oral steroid therapy was tapered and discontinued at 4 months.

## Discussion

Herpes zoster infection affects the sensory nerves of the thoracic dermatomes most often, followed by the cranial nerves.<sup>3,4,5</sup> The incidence and severity of the disease increase substantially after age 60.<sup>6,7</sup> HZO is seen in 10-15% of herpes zoster infections. The most common ocular complications of HZO include blepharoconjunctivitis, keratitis, and uveitis. Neurological complications such as ophthalmoplegia or optic neuritis are rare and known to respond to antiviral or steroid treatment. The prevalence of ophthalmoplegia was reported as 3.5-10.1% in the two large HZO case series in the literature.<sup>8,9</sup> The most frequently involved cranial nerve is the oculomotor nerve, followed by abducens nerve.<sup>10,11</sup>

OAS is characterized by paralysis of cranial nerves II, III, IV, and VI and the ophthalmic branch of the cranial nerve V, caused by inflammatory, infectious, neoplastic, traumatic, vascular, and sometimes iatrogenic causes along the ophthalmic canal.<sup>12</sup> The most common infectious causes of OAS are mucormycosis and aspergillosis. These should be considered in patients with predisposing conditions such as diabetes mellitus, alcoholism, hematological malignancy and immunosuppression. Primary infection occurs in the paranasal sinuses with invasion of the orbital space.<sup>13</sup> The diagnosis of these infections is relatively straightforward due to the clinical findings, host factors, and radiological findings. Reactivation of latent VZV infection is an uncommon cause of OAS. There are a total of about 20 case reports describing the development of OAS due to HZO in the ophthalmic literature.<sup>7,14,15,16,17</sup>

As in our case, the patients in previously reported HZO-related OAS cases were usually over 60 years of age.<sup>7,18,19,20,21</sup> The youngest documented patient was a 29-year-old woman who had severe, undiagnosed acquired immunodeficiency syndrome (AIDS).<sup>14</sup> Young patients presenting with HZO and associated complications should raise suspicion of human immunodeficiency virus (HIV)/AIDS and should be tested accordingly.

In addition to the peripheral nervous system, HZO can also manifest with central nervous system involvement. Xiao et al.<sup>22</sup> observed lesions in the occipital lobe, cerebellum, and dura mater on MRI examination in a case of HZO-related OAS and meningoencephalitis. An interesting aspect of our case was the presence of thrombosis in the cranial venous system, which has not been previously described in association with OAS. MRI performed due to clinical suspicion allowed us to establish a diagnosis before the development of papillary stasis and to initiate anticoagulation therapy early.

The treatment regimen for OAS secondary to herpes zoster includes 4000 mg/day acyclovir (800 mg, 5 times daily) or 3000

mg/day valacyclovir (1000 mg, 3 times daily) and systemic steroids.<sup>2,23</sup> The clinical course of the disease depends on how rapidly treatment is initiated. Beginning treatment within the first 72 hours is recommended.<sup>24</sup>

The recovery time for HZO-related ophthalmoplegia is reported to be 4.4 months on average, with a range of 2 weeks to 1.5 years. Rates of complete recovery from ophthalmoplegia and optic neuropathy have been reported as 76.5% and 75%, respectively.<sup>2</sup> In our case, ophthalmoplegia resolved in 2 months without sequelae. However, visual acuity remained at 0.4 due to optic neuropathy.

The pathological mechanisms of ophthalmoplegia in cases of HZO have not been clearly determined. Histopathological studies have shown perivascular and perineural inflammation in various ocular tissues, including the optic nerve, cavernous sinus, superior orbital fissure, and retina.<sup>25</sup> Extraocular muscle involvement may be caused by the cytopathic effect of the virus in neural tissues, occlusive vasculitis occurring as a direct result of inflammation, or host immune response to the viral infection.<sup>26</sup> Using cadaver eyes affected by HZO, Naumann et al.<sup>27</sup> demonstrated that infiltrative cells reached the orbital apex along the long posterior ciliary vessels and nerves, and that neuropathy was caused by vascular occlusion. In our case, thrombosis of the left transverse sinus is believed to have resulted from virus-related vasculitis.

AS is a rare but serious complication of HZO. Therefore, patients with a history of HZO should be evaluated for optic nerve, extraocular muscle, and eyelid function at every follow-up examination. MRI and MR venography are useful imaging techniques for the characterization of occlusive vasculitic lesions.

#### Ethics

**Informed Consent:** It was taken.

**Peer-review:** Externally and internally peer-reviewed.

#### Authorship Contributions

**Surgical and Medical Practices:** Canan Aslı Utine, **Concept:** Gamze Kocaoğlu, Canan Aslı Utine, Aylin Yaman, Süleyman Men, **Design:** Gamze Kocaoğlu, Canan Aslı Utine, Aylin Yaman, Süleyman Men, **Data Collection or Processing:** Gamze Kocaoğlu, Canan Aslı Utine, Aylin Yaman, Süleyman Men, **Analysis or Interpretation:** Gamze Kocaoğlu, Canan Aslı Utine, Aylin Yaman, Süleyman Men, **Literature Search:** Gamze Kocaoğlu, Canan Aslı Utine, **Writing:** Gamze Kocaoğlu, Canan Aslı Utine, Aylin Yaman, Süleyman Men.

**Conflict of Interest:** No conflict of interest was declared by the authors.

**Financial Disclosure:** The authors declared that this study received no financial support.

#### References

- Liesegang TJ. Herpes zoster ophthalmicus: natural history, risk factors, clinical presentation, and morbidity. *Ophthalmology*. 2008;115(2Suppl):3-12.

- Sanjay S, Chan EW, Gopal L, Hegde SR, Chang BC. Complete unilateral ophthalmoplegia in herpes zoster ophthalmicus. *J Neuroophthalmol*. 2009;29:325-337.
- Marsh RJ, Dulley B, Kelly V. External ocular motor palsies in ophthalmic zoster: a review. *Br J Ophthalmol*. 1977;61:677-682.
- Edgerton AE. Herpes Zoster Ophthalmicus; report of cases and review of literature. *Arch Ophthalmol*. 1945;34:40-62.
- Archambault P, Wise JS, Rosen J, Polomeno RC, Auger N. Herpes Zoster Ophthalmoplegia, Report of Six Cases. *J Clin Neuroophthalmol*. 1988;8:185-193.
- Oxman MN, Levin MJ, Johnson GR, Schmader KE, Straus SE, Gelb LD, Arbeit RD, Simberkoff MS, Gershon AA, Davis LE, Weinberg A, Boardman KD, Williams HM, Zhang JH, Peduzzi PN, Beisel CE, Morrison VA, Guatelli JC, Brooks PA, Kauffman CA, Pachucki CT, Neuzil KM, Betts RF, Wright PE, Griffin MR, Brunell P, Soto NE, Marques AR, Keay SK, Goodman RP, Cotton DJ, Gnann JW Jr, Loutit J, Holodniy M, Keitel WA, Crawford GE, Yeh SS, Lobo Z, Toney JF, Greenberg RN, Keller PM, Harbecke R, Hayward AR, Irwin MR, Kyriakides TC, Chan CY, Chan IS, Wang WW, Annunziato PW, Silber JL; Shingles Prevention Study Group. A vaccine to prevent herpes zoster and postherpetic neuralgia in older adults. *N Engl J Med*. 2005;352:2271-2284.
- Arda H, Mirza E, Gümüş K, Oner A, Karakucuk S, Sırakaya E. Orbital apex syndrome in herpes zoster ophthalmicus. *Case Rep Ophthalmol Med*. 2012;2012:854503.
- Womack LW, Liesegang TJ. Complications of herpes zoster ophthalmicus. *Arch Ophthalmol*. 1983;101:42-45.
- Marsh RJ, Cooper M. Ophthalmic herpes zoster. *Eye (Lond)*. 1993;7:350-370.
- Edgerton AE. Herpes zoster ophthalmicus: report of cases and a review of the literature. *Trans Am Ophthalmol Soc*. 1942;40:390-439.
- Marsh RJ, Dulley B, Kelly V. External ocular motor palsies in ophthalmic zoster: a review. *Br J Ophthalmol*. 1977;61:677-682.
- Yeh S, Foroozan R. Orbital apex syndrome. *Curr Opin Ophthalmol*. 2004;15:490-498.
- Marlene LD. Periocular Infections. In: Gerald LM, John EB, Raphael D, eds. *Mandell, Douglas, and Bennett's Principles and Practice of Infectious Diseases*. Philadelphia; Churchill Livingstone; 2010:1569-1575.
- Saxena R, Phuljhele S, Aalok L, Sinha A, Menon V, Sharma P, Mohan A. A rare case of orbital apex syndrome with herpes zoster ophthalmicus in a human immunodeficiency virus-positive patient. *Indian J Ophthalmol*. 2010;58:527-530.
- Merino-Iglesias A, Montero JA, Calabuig-Goena M, Giraldo-Agudelo LE. Orbital apex syndrome secondary to herpes zoster virus infection. *BMJ Case Rep*. 2014;2014.
- Kurimoto T, Tonari M, Ishizaki N, Monta M, Hirata S, Oku H, Sugawara J, Ikeda T. Orbital apex syndrome associated with herpes zoster ophthalmicus. *Clin Ophthalmol*. 2011;5:1603-1608.
- Wakida K, Sakurai T, Nishida H. Varicella zoster virus-induced meningoencephalitis complicated with orbital apex syndrome: a case report. *Brain Nerve*. 2014;66:1103-1108.
- Ramsell TG. Complications of herpes zoster ophthalmicus. *Am J Ophthalmol*. 1967;63:1796-1798.
- Dhingra S, Williams G, Pearson A. Severe, permanent orbital disease in herpes zoster ophthalmicus. *Orbit*. 2008;27:325-327.
- Kurimoto T, Tonari M, Ishizaki N, Monta M, Hirata S, Oku H, Sugawara J, Ikeda T. Orbital apex syndrome associated with herpes zoster ophthalmicus. *Clin Ophthalmol*. 2011;5:1603-1608.
- Shirato S, Oshitari T, Hanawa K, Adachi-Usami E. Magnetic resonance imaging in case of cortical apex syndrome caused by varicella zoster virus. *Open Ophthalmol J*. 2008;2:109-111.
- Xiao Z, Lu Z, Pan S, Liang J, Liu Z. Orbital apex syndrome and meningoencephalitis: a rare complication of herpes zoster. *Int J Clin Exp Med*. 2015;8:14260-14263.

23. Shin HM, Lew H, Yun YS. A case of complete ophthalmoplegia in herpes zoster ophthalmicus. *Korean J Ophthalmol.* 2005;19:302-304.
24. Chang-Godinich A, Lee AG, Brazis PW, Liesegang TJ, Jones DB. Complete ophthalmoplegia after zoster ophthalmicus. *J Neuroophthalmol.* 1997;17:262-265.
25. Lexa EJ, Galetta SL, Yousem DM, Farber M, Oberholtzer JC, Atlas SW. Herpes zoster ophthalmicus with orbital pseudotumor syndrome complicated by optic nerve infarction and cerebral granulomatous angiitis: MR-pathologic correlation. *AJNR Am J Neuroradiol.* 1993;14:185-190.
26. Im M, Kim BJ, Seo YJ, Park JK, Lee JH. Complete ophthalmoplegia after herpes zoster. *Clin Exp Dermatol.* 2007;32:162-164.
27. Naumann G, Gass JD, Font RL. Histopathology of herpes zoster ophthalmicus. *Am J Ophthalmol.* 1968;65:533-541.



## Goldmann-Favre Syndrome: Case Series

© Serdar Özateş\*, © Kemal Tekin\*\*, © Mehmet Yasin Teke\*\*\*

\*University of Health Sciences, Dr. Sami Ulus Maternity and Children Training and Research Hospital, Ophthalmology Clinic, Ankara, Turkey

\*\*Kars Harakani State Hospital, Ophthalmology Clinic, Kars, Turkey

\*\*\*University of Health Sciences, Ulucanlar Eye Training and Research Hospital, Ophthalmology Clinic, Ankara, Turkey

### Abstract

Goldmann-Favre syndrome, which is caused by mutation of the *NR2E3* gene, is a retinal degenerative disease with a wide spectrum of phenotypic properties. Variations in clinical presentation result in difficulties in differential diagnosis. In this article, Goldmann-Favre syndrome cases with different clinical findings are presented. Clinical characteristics of our cases were reviewed and discussed in light of the literature.

**Keywords:** Goldmann-Favre syndrome, retina, optic coherence tomography

### Introduction

Goldmann-Favre syndrome (GFS) is a progressive retinal degeneration that develops due to a mutation in the *NR2E3* gene, which has a role in the regulation of cone cell differentiation, and has an autosomal recessive inheritance pattern.<sup>1,2</sup> GFS and enhanced S-cone syndrome represent two distinct entities on a spectrum of retinal degenerative disease caused by mutations in the same gene.<sup>3</sup> The fact that these two conditions manifest with very different clinical phenotypes make it difficult to distinguish them from other diseases on the retinal degenerative disease spectrum such as retinitis pigmentosa, congenital retinoschisis, and secondary pigmentary retinopathy.<sup>2,4,5</sup>

In this report, the varying examination findings and clinical characteristics of patients treated in our clinic for GFS are discussed in the context of the literature.

### Case Reports

#### Case 1

A 36-year-old woman presented to our clinic with a complaint of progressive vision loss. She reported that her low

vision had been present since childhood and that her mother had completely lost her vision due to a similar history. In addition, the one male child (Case 2) and one female child (Case 3) of the patient had similar complaints. When asked about her family tree, it was learned that her parents were in a consanguineous marriage and that her spouse was also a second degree relative. Her best corrected visual acuity (BCVA) was 0.4 in the right eye and at the level of hand movements in the left eye. Anterior segment examination revealed bilateral posterior subcapsular cataract which was denser in the left eye. Fundus examination revealed widespread clumps of retinal pigment epithelium (RPE) hyperplasia surrounding the optic disc and macula of the right eye (Figure 1). There was no involvement of the macula and peripapillary area. Due to dense cataract, the posterior segment of the left eye could not be clearly evaluated. Optic coherence tomography (OCT) sections showed no pathology in the macula of the right eye. Images could not be obtained during fundus fluorescein angiography (FFA) because the patient experienced syncope.

#### Case 2

The 16-year-old son of the patient in Case 1 presented to our clinic with the complaint of low vision. His visual impairment

**Address for Correspondence:** Serdar Özateş MD, University of Health Sciences, Dr. Sami Ulus Maternity and Children Training and Research Hospital, Ophthalmology Clinic, Ankara, Turkey Phone: +90 537 717 91 10 E-mail: serdarozates@gmail.com **ORCID-ID:** orcid.org/0000-0002-0365-8786

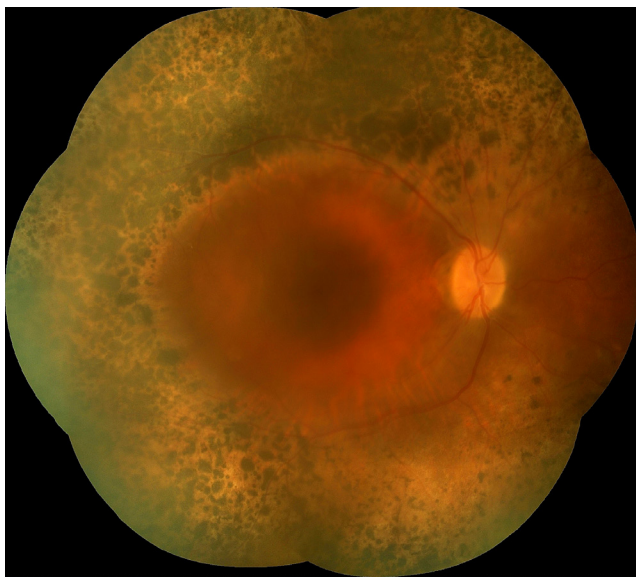
**Received:** 16.03.2017 **Accepted:** 20.09.2017

©Copyright 2018 by Turkish Ophthalmological Association  
Turkish Journal of Ophthalmology, published by Galenos Publishing House.

had started at the age of 10, and his BCVA was 0.7 in both eyes with myopic correction. Anterior segment examination was normal in both eyes. Fundus examination revealed hyperplastic RPE clumps starting from the temporal retina, following the retinal vascular arcades, and extending toward the optic disc in both eyes. In addition, there were nummular lesions with atrophic centers and hyperpigmented borders in the peripheral regions of the annular lesion formed by the hyperplastic RPE clumps and the normal retina (Figures 2a, b). Fundus autofluorescence (FAF) imaging revealed punctate hyperautofluorescent lesions in the parafoveal region, nasal of the optic disc, and along the vascular arcades, and some lesions were also located in the apparently healthy retina (Figures 2c, d). OCT revealed areas of retinoschisis in the parafoveal area in both eyes despite the normal appearance of the fovea (Figures 2e, f). FFA showed hyperfluorescent window defect in areas with RPE atrophy and fluorescein blockage in hyperpigmented areas (Figures 2g, h).

### Case 3

A 12-year-old female patient presented to our clinic due to low vision. Her mother (Case 1) and brother (Case 2) had similar complaints. BCVA was 0.6 in the right eye and 0.4 in the left eye with myopic correction. Eye movements, direct and indirect light reflexes, color vision, and anterior segment examination were normal on ophthalmological examination. Fundus examination revealed hyperplastic RPE clumps and areas of chorioretinal atrophy with hyperpigmented borders around the retinal vascular arcades in both eyes (Figures 3a, b). Cystoid changes and a flower-petal appearance were observed in the macula. The optic discs were raised and edematous bilaterally. No cells or haze were observed in the vitreous humor. OCT sections showed cystoid degenerative changes in the fovea and

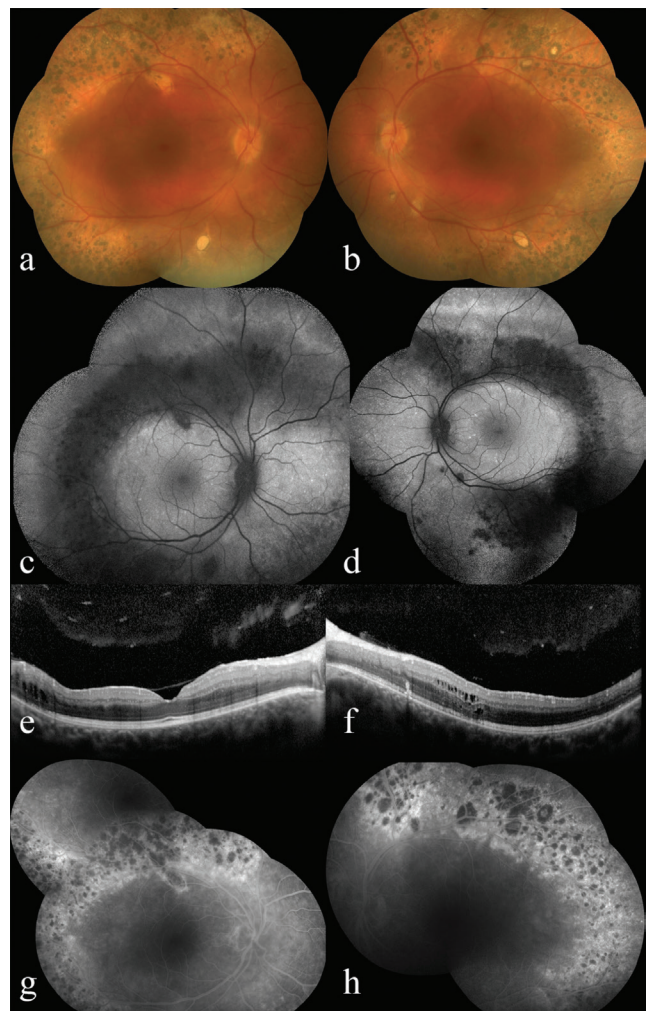


**Figure 1.** Case 1: Widespread retinal pigment epithelium hyperplasia around the vascular arcades

parafoveal region in both eyes (Figures 3c, d). FFA revealed extensive leakage in the optic disc and at the border between the annular area containing the lesions and the apparently healthy macular region. Widespread hyperfluorescent punctate areas of leakage were observed around the fovea and temporal of the macula in the late phase (Figures 3e, f).

### Case 4

A 31-year-old woman presented to our clinic due to poor night vision. She reported a 20-year history of low vision and restricted visual field. No one else in her family had similar complaints. She had also been followed previously for retinitis pigmentosa. On ophthalmological examination, her BCVA was 0.6 in the right eye and 0.5 in the left eye. No signs of pathology were detected in anterior segment examination. Fundus examination revealed a ring of hyperplastic RPE lesions



**Figure 2.** Case 2: Fundus photographs show nummular lesions with atrophic centers and hyperpigmented borders (a, b); fundus autofluorescence images show hyperautofluorescent spots in the apparently healthy retina (c, d); optic coherence tomography reveals areas of parafoveal retinoschisis (e, f); fundus fluorescein angiography images (g, h)



and areas of chorioretinal atrophy surrounding the optic disc and macula in both eyes (Figures 4a, b). Although there were no lesions within the retinal vascular arcades, cystoid changes were noted in the fovea. FAF revealed widespread hyperautofluorescent punctate lesions in the macula and around the arcades (Figures 4c, d). OCT showed retinoschisis at the fovea. In addition, loss of the photoreceptor layer was noted in the combined OCT sections passing through the lesion area (Figures 4e, f). FFA revealed blocked fluorescence and widespread hyperfluorescent window defect around the retinal vascular arcades, but no leakage was detected in the macula in the late phase (Figures 4g, h).

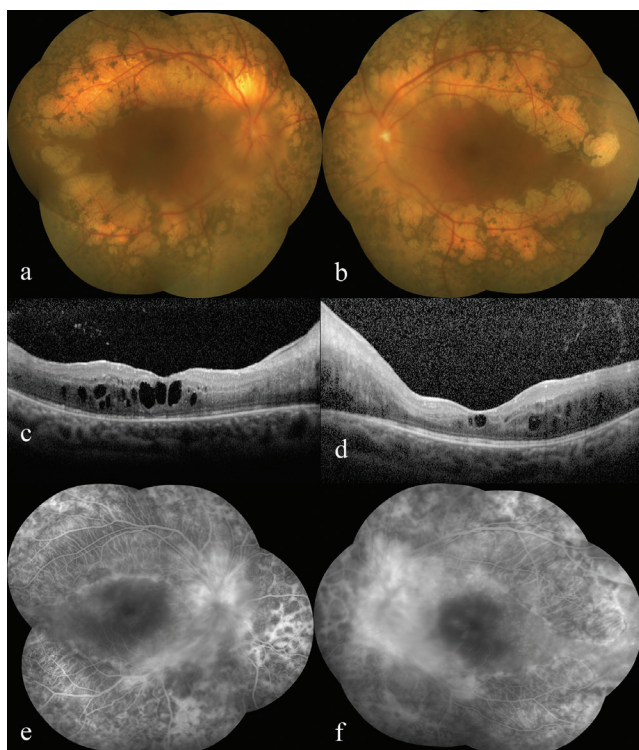
### Case 5

A 12-year-old female patient with otherwise unremarkable history presented with complaints of low vision. BCVA was 0.5 in the right eye and 0.6 in the left eye. No pathology was detected in anterior segment examination. Fundus examination revealed tortuosity of the retinal vascular structures, clumped RPE hyperplasia surrounding the optic disc and macula, and widespread, yellow punctate lesions in both eyes (Figures 5a, b). Nummular lesions with atrophic centers and hyperpigmented borders were observed, particularly around the upper retinal vascular arcade. FAF imaging revealed hyperautofluorescent punctate lesions in the macula, within the annular region of

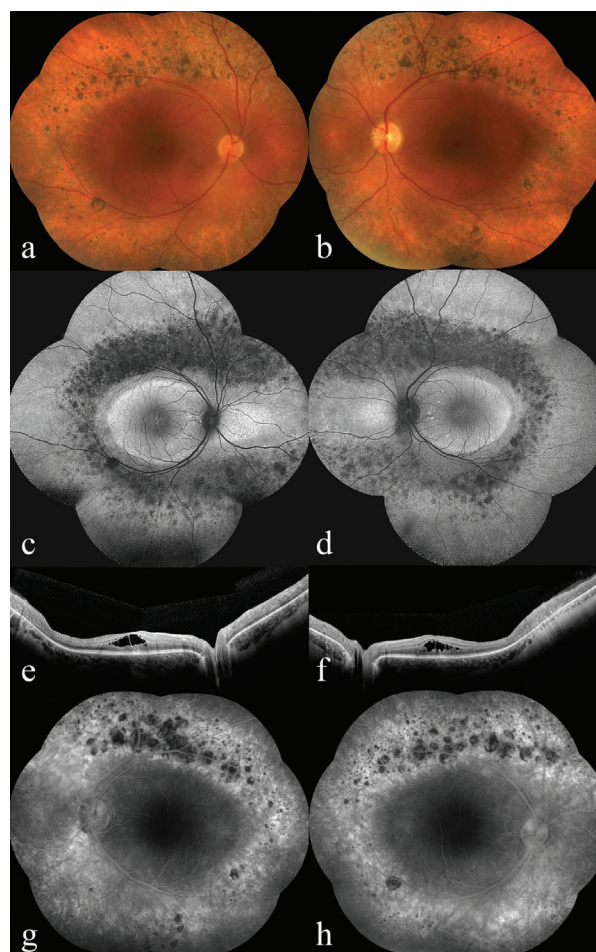
affected retina, and in the periphery of the apparently healthy retina (Figures 5c, d). No pathology was observed on OCT in either eye (Figures 5e, f). The lesions could not be evaluated angiographically because the patient's parents did not consent to FFA examination.

### Discussion

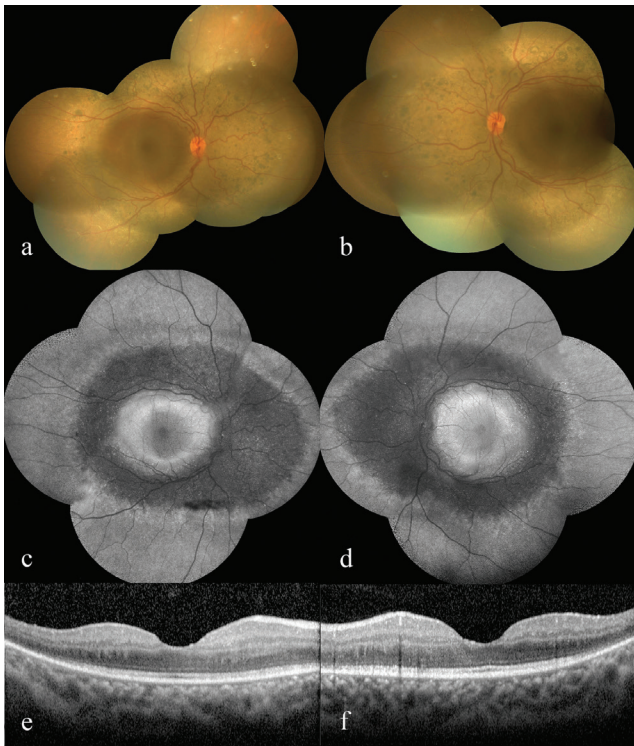GFS was first described by Favre<sup>6</sup> in two brothers, and Ricci<sup>7</sup> reported that GFS follows an autosomal recessive inheritance pattern. Genetic studies have revealed that GFS occurs due to a mutation in the *NR2E3* gene, which is located on the short arm of chromosome 15.<sup>2,5,8</sup> The *NR2E3* gene encodes a retinal nuclear receptor involved in transcription.<sup>9</sup> This gene regulates the expression of cone-specific genes found in the rods and controls the differentiation of photoreceptors.<sup>9,10</sup>



**Figure 3.** Case 3: Fundus photographs show widespread chorioretinal atrophy and nummular lesions with hyperpigmented borders (a, b); optic coherence tomography shows cystoid macular edema (c, d); fundus fluorescein angiography images reveal widespread leakage from the optic disc and borders of the apparently healthy retina as well as macular leakage due to cystoid macular edema (e, f)



**Figure 4.** Case 4: Fundus photographs show nummular lesions with atrophic centers and hyperpigmented borders and RPE hyperplasia around the vascular arcades (a, b); Fundus autofluorescence images show widespread hyperautofluorescent spots (c, d); Optic coherence tomography reveals central retinoschisis and loss of the photoreceptor layer, sudden increase in retinal thickness, and loss of the retinal laminar structure in the affected peripheral retina (e, f); Fundus fluorescein angiography images (g, h)



**Figure 5.** Case 5: Fundus photographs show yellow punctate lesions and clumps of retinal pigment epithelium hyperplasia around the vascular arcades (a, b); fundus autofluorescence images show widespread hyperautofluorescent spots (c, d); optic coherence tomography sections (e, f)

Homozygous mutations in the *NR2E3* gene result in increased and uncontrolled cone photoreceptor differentiation (especially S-cone) and a reduced number of rod photoreceptor cells during retinal development.<sup>9,10,11</sup>

There are case series demonstrating familial inheritance in the literature.<sup>12,13</sup> Familial inheritance is clearly observed in our first three cases. When taking the family history of the patient in Case 1, we learned that her mother had also had vision problems throughout her life. In addition, there was consanguinity both between the patient's parents and between the patient and her spouse. This explains how both of her children could have GFS when her spouse did not. It is reported that the phenotype of this disease may vary, despite the presence of similar mutations.<sup>5,8,14</sup> There was also individual variation in the nature and severity of the clinical findings and the complications experienced during follow-up in our first three cases. Studies investigating the causes of this phenotypic variability have been inconclusive.

GFS manifests as night blindness or a progressive decrease in visual acuity during the first decade of life.<sup>4,12</sup> It is typically characterized by hyperpigmented RPE clumps that form along the retinal vascular arcades, areas of chorioretinal atrophy, cystoid or schisis-like changes in the fovea, central or peripheral retinoschisis, vitreous degeneration, and cataract.<sup>1,4</sup> In addition, abnormal dark adaptation and electroretinogram results, progressive visual field loss, and color vision disorders are other accompanying symptoms.<sup>4,12</sup> Nummular lesions with

atrophic centers and hyperpigmented borders, called "torpedo-like lesions", were first described in GFS by Yzer et al.<sup>2</sup> They reported that these lesions were located in the healthier areas of the retina. We also observed similar lesions in Cases 2, 3, 4, and 5 in our series. The lesions were located at the border of the apparently healthy retina in Cases 3 and 4, but were in the affected retina in Cases 2 and 5. In addition, lesions were especially prominent around the upper retinal vascular arcade in Cases 4 and 5. In GFS, rod photoreceptors are essentially replaced by S-cone photoreceptors.<sup>12,14</sup> There is also a reduction in the number of L- and M-cone cells due to phagocytosis of cone cells by RPE cells and as a result of the *NR2E3* gene mutation.<sup>15</sup> Histopathological studies have shown an increase in S-cone cells in both the perimacular area and the peripheral retina.<sup>10</sup> In a postmortem examination, a complete absence of rod cells and twice the normal number of cone cells was observed in the retina, with S-cone cells comprising 92% of all the cone receptors.<sup>15</sup> However, in experimental animal models it has been reported that the cone photoreceptors replacing the rod photoreceptors do not show a diffuse histological distribution, but are concentrated in certain regions.<sup>16</sup> These areas of concentration appear as pseudorosettes in histopathological examination, which may explain the round shape of these degenerative lesions.<sup>2,16,17</sup>

Retinoschisis is another distinctive finding of GFS.<sup>4</sup> Although peripheral retinoschisis is more common in GFS, central retinoschisis may also occur.<sup>4</sup> In our series, Case 2 had both central and peripheral retinoschisis, while Case 4 exhibited only central retinoschisis. Leakage is not seen on FFA in the area of central schisis.<sup>4,12</sup> However, we noted that the areas of perifoveal leakage observed on FFA in Case 3 were generally consistent with the schisis-like areas observed on OCT. Considering the widespread leakage in the optic disc and at the border of the apparently healthy retina, we believed that the lesions were caused by cystoid macular edema. Leakage is rarely observed in GFS and has been reported in a limited number of cases in the literature. Fishman et al.<sup>12</sup> reported three GFS cases with similar widespread leakage in the posterior pole. The leakage from both the retinal vascular arcades and the optic disc reported in those cases is consistent with the findings in our patient. GFS should be considered in the differential diagnosis of patients with a fundus appearance and leakage on FFA similar to those described.

The patients in Cases 2, 4 and 5 of our series exhibited spots that appeared yellow in color on fundus images and showed hyperautofluorescence on FAF. Similar to findings reported by Yzer et al.<sup>2</sup>, they were located at the borderline between the affected retina and apparently healthy retina. These spots may appear as a result of phagocytosed material found in macrophages.<sup>18</sup>

Deterioration of the laminar organization of the retina and retinal thickening on OCT have been reported in the affected retinal area.<sup>19</sup> Composite OCT images from the affected retinal area in Case 4 showed loss of the photoreceptor layer at the boundary of the affected retina, followed by disruption of the laminar structure of the retina and a sudden increase in retinal

thickness. The increase in thickness and deterioration of the anatomical structure may be due to the fact that S-cone cells, which are larger than rods, are situated where the rods should be.<sup>19</sup> The relative decrease in choroidal thickness in the area of increased retinal thickness in the patient's left eye was an interesting finding.

The high phenotypic variability of GFS makes it difficult to distinguish from diseases such as retinitis pigmentosa, congenital retinoschisis, and secondary pigmentary retinopathy. The less common findings reported in our case series may assist in the differential diagnosis of GFS and improve our understanding the underlying pathophysiological processes.

#### Ethics

**Informed Consent:** It was taken.

**Peer review:** Externally and internally peer-reviewed.

#### Authorship Contributions

**Surgical and Medical Practices:** Mehmet Yasin Teke, **Concept:** Serdar Özateş, **Design:** Serdar Özateş, **Data Collection or Processing:** Mehmet Yasin Teke, Kemal Tekin, **Analysis or Interpretation:** Mehmet Yasin Teke, **Literature Search:** Kemal Tekin, Serdar Özateş, **Writing:** Serdar Özateş.

**Conflict of Interest:** No conflict of interest was declared by the authors.

**Financial Disclosure:** The authors declared that this study received no financial support.

#### References

- Rinaldi C, Vitale L, Pachydaki S, Yannuzzi LA. Spontaneous resolution of macular schisis in goldmann favre syndrome. *Retin Cases Brief Rep.* 2011;5:84-86.
- Yzer S, Barbazetto I, Allikmets R, van Schooneveld MJ, Bergen A, Tsang SH, Jacobson SG, Yannuzzi LA. Expanded clinical spectrum of enhanced S-cone syndrome. *JAMA ophthalmol.* 2013;131:1324-1330.
- Pachydaki SI, Bhatnagar PA, Barbazetto IA, Klaver CC, Freund BK, Yannuzzi LA. Long-term follow-up in enhanced S-cone syndrome. *Retin Cases Brief Rep.* 2009;3:118-120.
- Batioglu F. Goldmann-Favre vitreoretinal degeneration. *Eur J Ophthalmol.* 2003;13:307-310.
- Sharon D, Sandberg MA, Caruso RC, Berson EL, Dryja TP. Shared mutations in NR2E3 in enhanced S-cone syndrome, Goldmann-Favre syndrome, and many cases of clumped pigmentary retinal degeneration. *Arch Ophthalmol.* 2003;121:1316-1323.
- Favre M. Two cases of hyaloid-retinal degeneration. *Ophthalmologica.* 1958;135:604-609.
- Ricci A. Clinique et transmission génétique des différentes formes de dégénérescences vitreo-rétiniennes. *Ophthalmologica.* 1960;139:338-343.
- Haider NB, Mollema N, Gaule M, Yuan Y, Sachs AJ, Nystuen AM, Nishina PM, Naggert JK, Nishina PM. Nr2e3-directed transcriptional regulation of genes involved in photoreceptor development and cell-type specific phototransduction. *Exp Eye Res.* 2009;89:365-372.
- Gelman R, Greenberg JP, Duncker T, Nguyen HV, Yannuzzi LA, Tsang SH. Hyperautofluorescent Macular Ring in a Series of Patients With Enhanced S-Cone Syndrome. *Ophthalmic Surg Lasers Imaging Retina.* 2014;45:592-595.
- Bonilha VL, Fishman GA, Rayborn ME, Hollyfield JG. Retinal pathology of a patient with Goldmann-Favre syndrome. *Ophthalmic Genet.* 2009;30:172-180.
- Sohn EH, Chen FK, Rubin GS, Moore AT, Webster AR, MacLaren RE. Macular function assessed by microperimetry in patients with enhanced S-cone syndrome. *Ophthalmology.* 2010;117:1199-1206.
- Fishman GA, Jampol LM, Goldberg ME. Diagnostic features of the Favre-Goldmann syndrome. *Br J Ophthalmol.* 1976;60:345-353.
- Chavala SH, Sari A, Lewis H, Pauer GJ, Simpson E, Hagstrom SA, Traboulsi EI. An Arg311Gln NR2E3 mutation in a family with classic Goldmann-Favre syndrome. *Br J Ophthalmol.* 2005;89:1065-1066.
- Pachydaki SI, Klaver CC, Barbazetto IA, Roy MS, Gouras P, Allikmets R, Yannuzzi LA. Phenotypic features of patients with NR2E3 mutations. *Arch Ophthalmol.* 2009;127:71-75.
- Milam AH, Rose L, Cideciyan AV, Barakat MR, Tang WX, Gupta N, Jacobson SG. The nuclear receptor NR2E3 plays a role in human retinal photoreceptor differentiation and degeneration. *Proc Natl Acad Sci U S A.* 2002;99:473-478.
- Haider NB, Demarco P, Nystuen AM, Huang X, Smith RS, McCall MA, Naggert JK, Nishina PM. The transcription factor Nr2e3 functions in retinal progenitors to suppress cone cell generation. *Vis Neurosci.* 2006;23:917-929.
- Mustafi D, Kevany BM, Genoud C, Okano K, Cideciyan AV, Sumaroka A, Palczewski K. Defective photoreceptor phagocytosis in a mouse model of enhanced S-cone syndrome causes progressive retinal degeneration. *FASEB J.* 2011;25:3157-3176.
- Wang NK, Fine HF, Chang S, Chou CL, Cella W, Tosi J, Tsang SH. Cellular origin of fundus autofluorescence in patients and mice with a defective NR2E3 gene. *Br J Ophthalmol.* 2009;93:1234-1240.
- Jacobson SG, Sumaroka A, Aleman TS, Cideciyan AV, Schwartz SB, Roman AJ, Wright AF. Nuclear receptor NR2E3 gene mutations distort human retinal laminar architecture and cause an unusual degeneration. *Hum Mol Genet.* 2004;13:1893-1902.



# Three Cases of Congenital Retinal MacrovesSEL, One Coexisting with Cilioretinal Artery

© Bayram Gülpamuk, © Pınar Kaya, © Mehmet Yasin Teke  
Ulucanlar Eye Training and Research Hospital, Ophthalmology Clinic, Ankara, Turkey

## Abstract

In this report, we describe three cases of retinal macrovesSEL. Two of the three patients presented to our clinic for annual eye exam and had no visual complaints. The third patient presented because of vision loss in the left eye. Two patients had 20/20 best corrected visual acuity in both eyes and the third patient had 20/20 in the right eye, 20/25 in the left eye. Pupillary exams were normal. Slit-lamp examinations of the anterior segment were unremarkable. Fundus examination revealed macrovesSels in the left eyes of two patients and in the right eye of one patient. The patients underwent complete ophthalmological examinations including color fundus photography for all three patients and optic coherence tomography, fundus autofluorescence, and fundus fluorescein angiography for two of the patients. Cilioretinal artery coexisting with macrovesSEL was seen angiography in one case. Congenital retinal macrovesSEL is a rare vascular condition. It is often unilateral and the vessel is an aberrantly large branch of the retinal arteries or veins. They may cross the fovea and their visual impact is minimal. The coexistence of congenital retinal macrovesSEL and cilioretinal artery is very rare. Visual impairment may occur in congenital retinal macrovesSEL due to retinal cavernous hemangioma, foveal cysts, central serous retinopathy, and other retinal vascular abnormalities.

**Keywords:** Congenital retinal macrovesSEL, aberrant retinal vessels, cilioretinal artery

## Introduction

Mauthner<sup>1</sup> first reported a large aberrant retinal vessel crossing the macula in 1869. In 1982, Brown et al.<sup>2</sup> described the clinical and fluorescein angiographic features of congenital retinal macrovesSEL (CRM) in seven patients. Impairment of vision in the involved eye is uncommon and is characterized by foveal cyst, macular hemorrhage, serous macular detachment, branch retinal artery occlusion or other vascular abnormalities.<sup>3</sup> CRM occurs mainly in veins but more rarely may stem from an artery or artery and vein together.<sup>4</sup> Beatty et al.<sup>5</sup> in this case report we present a cilioretinal artery connecting with a CRM, suggesting that such patients are at increased risk of retinal vascular decompensation. Herein, we present three cases showing no vision loss in routine ophthalmological examination, and interestingly, one patient had both CRM and cilioretinal artery.

## Case Reports

**Case 1:** An 8-year-old healthy female patient applied to our ophthalmology department for routine ophthalmic evaluation. Her personal and family medical histories were unremarkable. On ophthalmic examination, her best-corrected visual acuity was 20/20 in both eyes. Anterior segment examination of both eyes was normal. Intraocular pressures were within normal limits. Fundus examination was normal in the left eye but revealed a large macrovesSEL crossing the horizontal raphe adjacent to the fovea in the right eye (Figure 1). The patient was evaluated only with fundus photography because the patient's family did not consent to fundus fluorescein angiography (FFA) and optical coherence tomography (OCT).

**Case 2:** A 6-year-old female patient was brought to us due to reduced vision in the right eye. In our ophthalmic examination, we detected astigmatism in the right eye but best-corrected

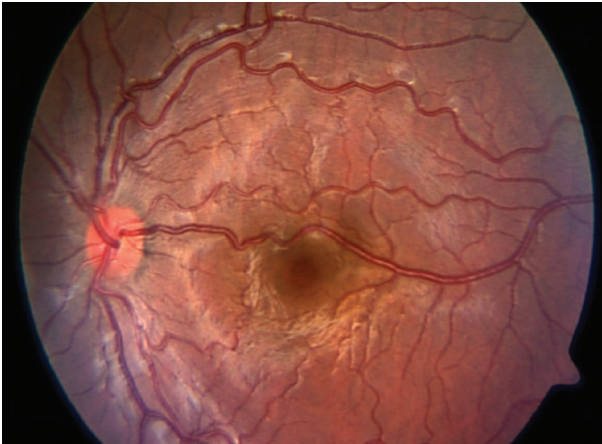**Address for Correspondence:** Pınar Kaya MD, Ulucanlar Eye Training and Research Hospital, Ophthalmology Clinic, Ankara, Turkey  
Phone: +90 506 538 71 59 E-mail: drpnrcck@gmail.com **ORCID-ID:** orcid.org/0000-0001-9243-6124

**Received:** 13.02.2017 **Accepted:** 23.05.2017

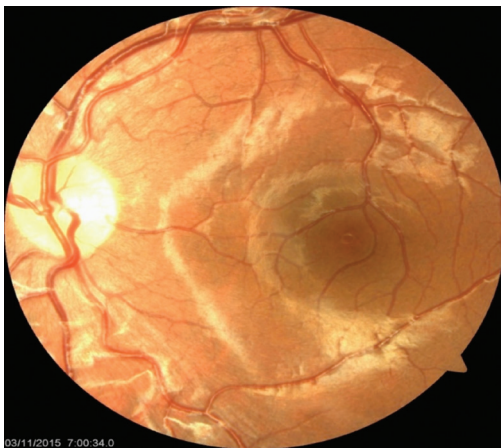©Copyright 2018 by Turkish Ophthalmological Association  
Turkish Journal of Ophthalmology, published by Galenos Publishing House.

visual acuity (BCVA) was 20/20 in both eyes using a Snellen chart. Anterior segment and funduscopic examination of the right eye were unremarkable. Examination of the macula of the left eye revealed a large superior macrovessel crossing the horizontal raphe with several tributaries adjacent to the fovea. Furthermore, the abnormal vein was accompanied by a cilioretinal artery (Figure 2a). The patient was evaluated with fundus photograph, FFA, fundus autofluorescence (Figure 2b), and spectral domain (SD)-OCT. FFA showed early filling of the venous macrovessel, accompanied by a cilioretinal artery, crossing the macula and having three tributaries which are surrounding the foveal area (Figure 2c). SD-OCT (Heidelberg Engineering, Heidelberg, Germany) showed normal foveal contour and vessel shadowing at five points (Figure 2d).

**Case 3:** A 16-year-old male patient was referred to us with a history of blurred vision in the left eye. His BCVA was 20/20 in the right eye and 20/25 in the left eye on Snellen chart. Relative afferent pupillary defects and anisocoria were not present.



**Figure 1.** Case 1: fundus photograph at presentation showed a large macrovessel is passing superior to the fovea extending along the papillomacular bundle and showing tortuosity of the vessels

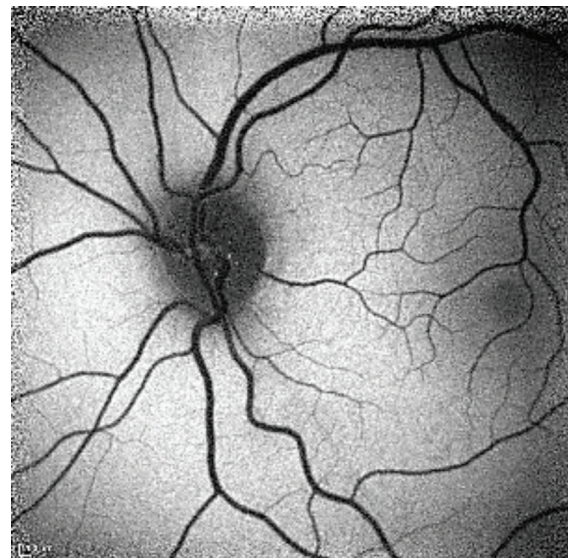

**Figure 2a.** Case 2: fundus photograph at presentation showed retinal macrovessel was a branch of the superotemporal vein reaching up to the fovea with three tributaries accompanied by a cilioretinal artery

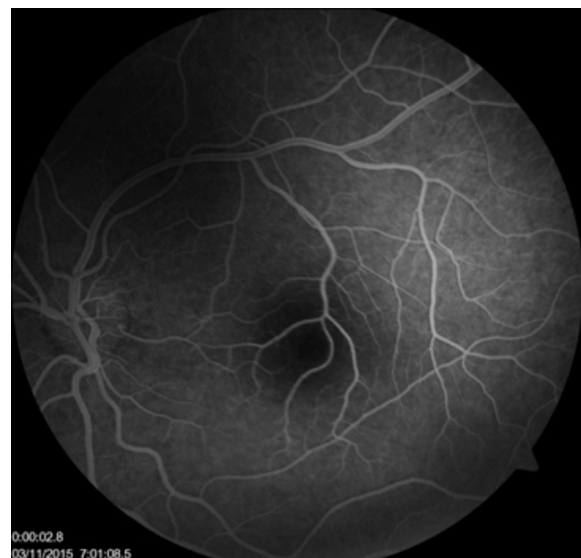Intraocular pressures were within normal limits. Slit-lamp examinations of the anterior segments of both eyes were normal. On fundus examination of the left eye, an anomalous large vessel was seen passing through the fovea separated in the optic disc from the inferotemporal vein. The patient was evaluated with colored fundus photograph (Figure 3a), SD-OCT (Figure 3b), FFA (Figure 3c) and fundus autofluorescence (Figure 3d).

## Discussion

Congenital retinal macrovessel is a rare finding and is usually discovered incidentally. CRM are mesenchymal in origin and develop around the first weeks of the second trimester when



**Figure 2b.** Case 2: fundus autofluorescence at presentation



**Figure 2c.** Case 2: early filling of the aberrant retinal macrovein was observed on fundus fluorescein angiography

differentiation of arteries and veins occurs.<sup>6</sup> They are generally asymptomatic, and vision is not affected in most cases. Archer et al.<sup>7</sup> classified congenital retinal arteriovenous communications into three groups. Group 1 arteriovenous communications are the mildest variant, and clinically, can be very subtle. Group 2 are larger than those of group 1. Our case 2 was compatible with group 1 and our cases 1 and 3 were compatible with group 2 of the Archer classification. To our knowledge, a congenital retinal venous macrovessel that communicates with a cilioretinal

artery is very rare. This condition was first described by Beatty et al.<sup>5</sup> Most of the cases of CRM that have been documented to date exhibited normal visual acuity.<sup>2</sup> When macrovessel is associated with reduced vision, one of the rare conditions should be considered: foveal cyst, macular hemorrhage or serous detachment, macular ischemia, branch retinal artery occlusion, and Valsalva retinopathy.<sup>8</sup> For this reason, clinicians should be vigilant and follow these patients regularly.

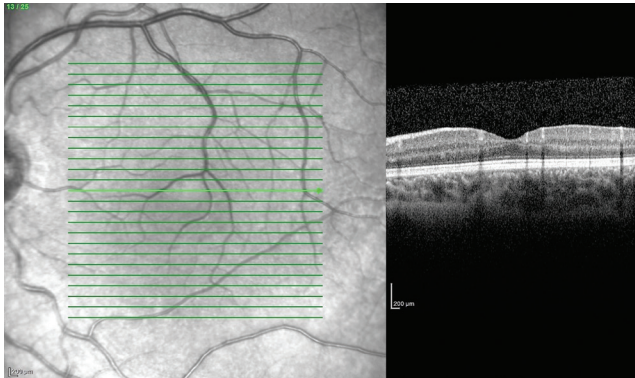
**Ethics**

**Informed Consent:** It was taken.

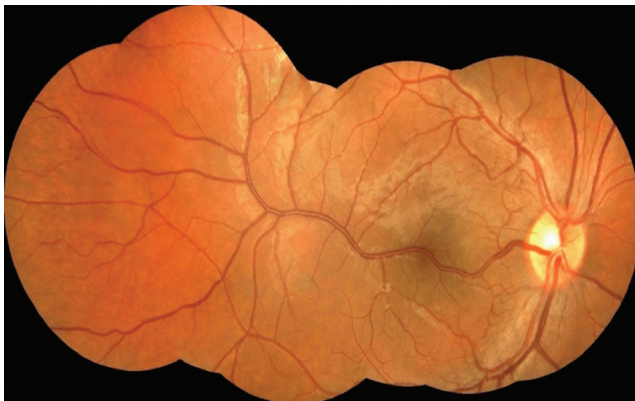
**Peer-review:** Externally and internally peer-reviewed.

**Authorship Contributions**

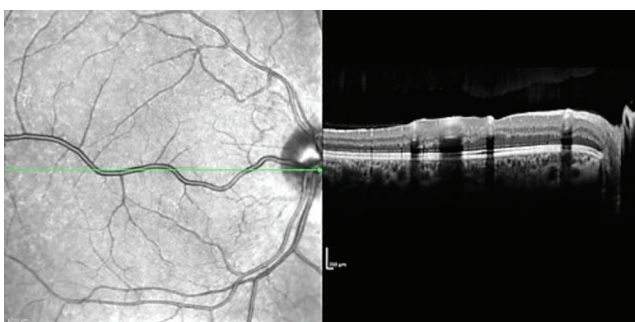
Surgical and Medical Practices: Mehmet Yasin Teke, Concept: Bayram Gülpamuk, Design: Bayram Gülpamuk,



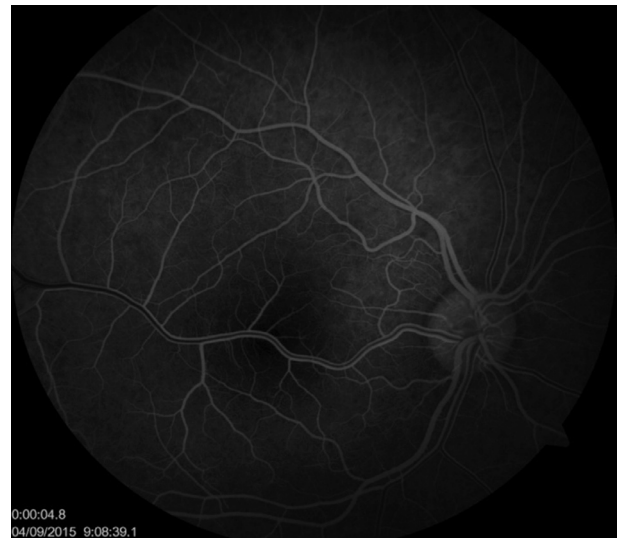**Figure 2d.** Case 2: spectral domain optical coherence tomography showing normal foveal contour and vascular shadowing at five points (arrows)



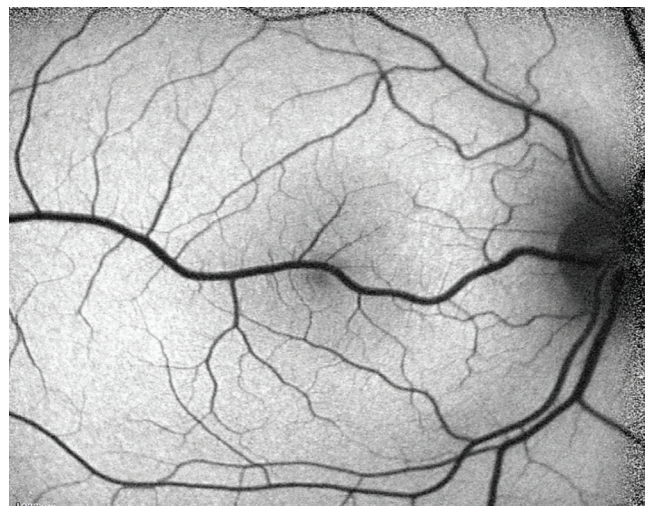**Figure 3a.** Case 3: montage colored fundus image showing a congenital retinal macrovessel crossing the macula horizontally in the left eye and separating branches of the vein peripherally



**Figure 3b.** Case 3: spectral domain ocular coherence tomography at presentation in the left eye with horizontal section passing through the macrovessel



**Figure 3c.** Case 3: fundus fluorescein angiography at presentation showed late filling of macrovessel simultaneously with inferotemporal vein



**Figure 3d.** Case 3: left eye fundus autofluorescence image

Data Collection or Processing: Bayram Gülpamuk, Pınar Kaya, Analysis or Interpretation: Bayram Gülpamuk, Pınar Kaya, Literature Search: Bayram Gülpamuk, Pınar Kaya, Writing: Bayram Gülpamuk, Pınar Kaya.

**Conflict of Interest:** No conflict of interest was declared by the authors.

**Financial Disclosure:** The authors declared that this study received no financial support.

## References

1. Mauthner L. Lehrbuch der ophthalmoscopie. Tendler; Vienna;1869:249.
2. Brown GC, Donoso LA, Magargal LE, Goldberg RE, Sarin LK. Congenital retinal macrovessels. Arch Ophthalmol. 1982;100:1430-1436.
3. de Crecchio G, Alfieri MC, Cennamo G, Forte R. Congenital macular macrovessels. Graefes Arch Clin Exp Ophthalmol. 2006;244:1183-1187.
4. Sanfilippo CJ, Sarraf D. Congenital macrovessel associated with cystoid macular edema and an ipsilateral intracranial venous malformation. Retin Cases Brief Rep. 2015;9:357-359.
5. Beatty S, Goodall K, Radford R, Lavin MJ. Decompensation of a congenital retinal macrovessel with arteriovenous communications induced by repetitive rollercoaster rides. Am J Ophthalmol. 2000;130:527-528.
6. Bhatia HK, Sharma S, Laxminarayana P. Congenital Retinal MacrovesSEL with Normal Visual Acuity: A Case Report. Int J Ophthalmol Clin Res 2015;2:2-4.
7. Archer DB, Deutman A, Ernest JT, Krill AE. Arteriovenous communications of the retina. Am J Ophthalmol. 1973;75:224-241.
8. Goel N, Kumar V, Seth A, Ghosh B. Branch retinal artery occlusion associated with congenital retinal macrovesSEL. Oman J Ophthalmol. 2014;7:96-97.

Hilal Nalcı, Figen Şermet, Sibel Demirel, Emin Özmert (2017). Optic Coherence Angiography Findings in Type-2 Macular Telangiectasia. Turk J Ophthalmol 47(5):279-284. Doi: 10.4274/tjo.68335

The title of the article has been corrected as following:

**Optical Coherence Tomography Angiography Findings in Type-2 Macular Telangiectasia.**



## 2018 INTERNATIONAL CONGRESSES

### **American Association for Pediatric Ophthalmology and Strabismus (AAPOS)**

AAPOS / Pediatric Ophthalmology and Strabismus  
Mar 18 - 22, 2018, Washington, DC, USA  
<https://aaapos.org/>

### **ASCRS 2018**

Apr 13 - 17, 2018, Washington, DC, USA

### **ARVO 2018**

Apr 29 - May 3, 2018, Honolulu, Hawaii, USA  
[www.arvo.com](http://www.arvo.com)

### **EGS Congress**

May 19 - 22, 2018, Florence, Italy

### **TROS-Uzbekistan Cataract and Refractive Surgery Course**

May 25 - 27, 2018, Taşkent, Uzbekistan

### **XIII<sup>th</sup> International Congress of ISOT**

Jun 3 - 8, 2018, Portoroz, Slovenia  
<http://www.isot2018.si/>

### **WOC 2018: World Congress of Ophthalmology**

Jun 16 - 20, 2018, Barcelona, Spain  
[www.icoph.org/refocusing\\_education/world\\_ophthalmology\\_congress/future\\_congresses.html](http://www.icoph.org/refocusing_education/world_ophthalmology_congress/future_congresses.html)

### **EURETINA 2018**

Sep 20 - 23, 2018, Vienna, Austria  
[www.euretina.org](http://www.euretina.org)

### **ESCRS 2018**

Sep 22 - 26, 2018, Vienna, Austria  
[www.es CRS.org](http://www.es CRS.org)

### **AAO 2018**

Oct 27 - 30, 2018, Chicago, USA  
[www.aao.org](http://www.aao.org)

## 2018 NATIONAL CONGRESSES

### **TOA 39<sup>th</sup> Winter Symposium: Ocular Inflammation**

Jan 19 - 21, 2018, Antalya, Turkey

### **TOA 15<sup>th</sup> March Symposium: Basic Imaging Methods in Ophthalmology**

Mar 16 - 18, 2018, Adana, Turkey

### **April Course: Uveal Diseases**

Apr 6 - 8, 2018, Ankara, Turkey

### **18<sup>th</sup> Esat Işık Course**

Apr 28 - 29, 2018, Ankara, Turkey

### **TOA Spring Symposium: Geriatric Ophthalmology**

May 11 - 13, 2018, İstanbul, Turkey

### **TOA 2<sup>nd</sup> Live Surgery Symposium**

Jun 29 - Jul 1, 2018, İstanbul, Turkey

### **TOA 52<sup>nd</sup> National Congress**

Nov 14 - 18, 2018, Antalya, Turkey

# TURKISH JOURNAL OF OPHTHALMOLOGY

TJO



Avrupa Konutları Kale, Maltepe Mah. Yedikule Çırpıcı Yolu Sk.9.Blok No:2 Kat.1 Ofis:1 Zeytinburnu-İstanbul-Turkey  
Phone: +90 212 801 44 36 -37 Fax: +90 212 801 44 39 E-mail: dergi@oftalmoloji.org

## Copyright Transfer Form

Corresponding author:.....

Registered number:.....

Title of Article:.....

We, the undersigned authors, accept that the Turkish Journal of Ophthalmology bears no responsibility for the manuscript concerned prior to its acceptance to the Journal. We guarantee that the submitted paper is original, has not previously been published in any other journal, and that, in the event that it is accepted for publication, in whole or in part, the Turkish Journal of Ophthalmology has obtained all permission necessary for publication, and the original copyright form has been submitted to the responsible directorship of publication of the Turkish Journal of Ophthalmology. By signing this form, we transfer copyright of the manuscript to the Turkish Journal of Ophthalmology.

The Turkish Journal of Ophthalmology follows the criteria defined by the International Committee of Medical Journal Editors for authorship of scientific articles; we hereby acknowledge the requirement that each and every person listed in this work should have made a considerable contribution during the creation of this work (such as study design; gathering, analyzing and interpreting the data; or in the writing and scientific review of the article). By signing the Copyright Transfer Form, we hereby declare that all persons identified within the list of authors below have fulfilled the above-mentioned criteria. The authors reserve the following rights.

**Note:** When used as stated above, a complete reference should be given indicating that the manuscript has been published in the Turkish Journal of Ophthalmology.

1. All proprietary rights, apart from copyright, such as patent rights, etc.
2. The right to use the manuscript in whole or in part in any future work such as books and lectures, free of charge.
3. The right to copy the manuscript for personal use, provided it is not offered for sale.

All authors sign as follows

Name - Surname.....Signature..... Date .....

Name - Surname.....Signature..... Date .....

Name - Surname.....Signature..... Date .....

Name - Surname.....Signature..... Date .....

Name - Surname.....Signature..... Date .....

Name - Surname.....Signature..... Date .....

Name - Surname.....Signature..... Date .....

Name - Surname.....Signature..... Date .....

Address for Correspondence:

Phone:

Fax:

E-mail:

This form should be filled out completely, including original signatures, scanned and submitted electronically together with your manuscript. If you are unable to upload the file, e-mail it as an attachment to dergi@oftalmoloji.org within three days of manuscript submission.

## Distance Visual Acuity Measurements Equivalency Table

ETDRS Standard Line Number						Spatial Frequency
	Qualitative Measurements	Decimal	Snellen	LogMAR	Angle of Resolution	Cycle per Degree
-3		2.00	20/10	-0.30	0.5	60.00
-2		1.60	20/12.5	-0.20	0.625	48.00
-1		1.25	20/16	-0.10	0.8	37.50
0		1.00	20/20	0.00	1	30.00
		0.90		0.05		27.00
1		0.80	20/25	0.10	1.25	24.00
		0.70		0.15		21.00
2		0.63	20/32	0.20	1.6	18.75
		0.60		0.22		18.00
3		0.50	20/40	0.30	2	15.00
4		0.40	20/50	0.40	2.5	12.00
		0.30		0.52		9.00
5		0.32	20/63	0.50	3.15	9.52
6		0.25	20/80	0.60	4	7.50
7		0.20	20/100	0.70	5	6.00
8		0.16	20/125	0.80	6.25	4.80
9		0.13	20/160	0.90	8	3.75
10	CF from 6 m	0.10	20/200	1.00	10	3.00
11	CF from 5 m	0.08	20/250	1.10	12.5	2.40
12	CF from 4 m	0.06	20/320	1.20	16	1.88
13	CF from 3 m	0.05	20/400	1.30	20	1.50
14		0.04	20/500	1.40	25	1.20
15	CF from 2 m	0.03	20/640	1.51	32	0.94
16		0.025	20/800	1.60	40	0.75
17		0.020	20/1000	1.70	50	0.60
18	CF from 1 m	0.016	20/1250	1.80	62.5	0.48
21	CF from 50 cm	0.008	20/2500	2.10	125	0.24
31	HM from 50 cm	0.0008	20/25000	3.10	1250	0.02

**Abbreviations:**

CF: Counting fingers, HM: Perception of hand motions, m= meter, cm= centimeter

**Equations of conversions for Microsoft Excel:**

- Log10 (Decimal Acuity)= LogMAR Equivalent

Power (10; -Logmar Equivalent)= Decimal Acuity (for English version of Microsoft Excel)

Kuvvet (10; -Logmar Equivalent)= Decimal Acuity (for Turkish version of Microsoft Excel)

**Reference**

Eğrilmez S, Akkın C, Erakgün T, Yağcı A. Standardization in evaluation of visual acuity and a comprehensive table of equivalent. Turk J Ophthalmol. 2002;32:132-136.

**Near Visual Acuity Measurements Related Equivalency Table\***

<b>Snellen</b>	<b>20/400</b>	<b>20/320</b>	<b>20/250</b>	<b>20/200</b>	<b>20/160</b>	<b>20/125</b>	<b>20/100</b>	<b>20/80</b>	<b>20/63</b>	<b>20/50</b>	<b>20/40</b>	<b>20/32</b>	<b>20/25</b>	<b>20/20</b>
Decimal	0.05	0.063	0.08	0.10	0.125	0.16	0.20	0.25	0.32	0.40	0.50	0.63	0.80	1.00
Jaeger	J19	J18	J17	J16	J15	J14	J13	J11	J9	J7	J5	J3	J2	J1
Times New Roman Point	60	48	36	30	24	18	14	12	10	8	6	5	4	3
LogMAR	1.3	1.2	1.1	1.0	0.9	0.8	0.7	0.6	0.5	0.4	0.3	0.2	0.1	0.0

\* Adapted from Rabbets RB: Visual acuity and contrast sensitivity. In: Rabbets RB, editor. Clinical visual optics. Edinburgh: Butterworth-Heinemann, 1998:19-61.