



www.ofthalmoloji.org

ISSN 2149-8695

# TURKISH JOURNAL OF OPHTHALMOLOGY

**TJO**

## Original Articles

*Comparison of Outcomes in Patients Who Underwent Deep Anterior Lamellar Keratoplasty and Those Converted to Penetrating Keratoplasty*  
Yusuf Koçluk et al; Adana, Ankara, Turkey

*Comparison of Biofilm Formation Capacities of Two Clinical Isolates of Staphylococcus Epidermidis with and without icaA and icaD Genes on Intraocular Lenses*

Sertaç Argun Kıvanç et al; Bursa, Eskişehir, Darıca, Turkey

*Contrast Sensitivity in Microtropic and Anisometropic Eyes of Successfully Treated Amblyopes*  
Özlem Öner et al; Aydın, Ankara, Turkey

*Factors Affecting Contrast Sensitivity in Healthy Individuals: A Pilot Study*

Arzu Seyhan Karatepe et al; Kayseri, İzmir, Turkey

*The Relationship between Serum Carbonic Anhydrase I-II Autoantibody Levels and Diabetic Retinopathy in Type 1 Diabetes Patients*  
Adem Türk et al; Trabzon, Turkey

*Treatment Results in Serpiginous Choroiditis and Multifocal Serpiginoid Choroiditis Associated with Latent Tuberculosis*  
Merih Oray et al; İstanbul, Turkey

## Review

*Thyroid-associated Ophthalmopathy*

Esra Şahlı and Kaan Gündüz; Ankara, Turkey

## Case Reports

*Spontaneous Late Intraocular Lens and Capsule Tension Ring Dislocation*

Ayşe Gül Koçak Altıntaş et al; Ankara, Turkey

*Rare Clinical Sign of Hodgkin's Lymphoma: Ocular Involvement*

Ziya Ayhan et al; İzmir, Manisa, Turkey

*Giant Hydrocystoma of the Orbit Presenting with Inversion and Ptosis of the Upper Eyelid*

Melis Palamar et al; İzmir, Turkey

*Multiple Intravitreal Ranibizumab Injections for Persistent Choroidal Neovascularization Associated with Presumed Ocular Histoplasmosis Syndrome*

Turgut Yılmaz et al; Malatya, Turkey

*Three-dimensional Optical Coherence Tomography Imaging and Treatment of Glaucomatous Optic Nerve Head Defects Associated with Schisis-like Maculopathy*

Zafer Öztaş et al; İzmir, Turkey

## Letter to the Editor

*Intravitreal Bevacizumab in Vitreous Hemorrhage and Diabetes Mellitus*

Beuy Joob and Viroj Wiwanitkit, Bangkok, Thailand, China

# TURKISH JOURNAL OF OPHTHALMOLOGY



www.ofthalmoloji.org

TJO

## Editor-in-Chief

### Murat İRKEÇ, MD

Hacettepe University Faculty of Medicine, Department of Ophthalmology, Ankara, Turkey  
Areas of Interest: Cornea and Ocular Surface Disease, Glaucoma, Allergy and Immunology  
E-mail: mirkec@hacettepe.edu.tr

## Associate Editors

### Tomris ŞENGÖR, MD

İstanbul Bilim University Faculty of Medicine, Department of Ophthalmology, İstanbul, Turkey  
Areas of Interest: Cornea and Ocular Surface Disease, Contact Lens  
E-mail: tomris.sengor@gmail.com

### Sait EĞRİLMEZ, MD

Ege University Faculty of Medicine, Department of Ophthalmology, İzmir, Turkey  
Areas of Interest: Cornea and Ocular Surface Disease, Contact Lens, Refraction, Cataract and Refractive Surgery  
E-mail: saitegrilmez@gmail.com

### Özlem YILDIRIM, MD

Mersin University Faculty of Medicine, Department of Ophthalmology, Mersin, Turkey  
Areas of Interest: Uveitis, Medical Retina, Glaucoma  
E-mail: dryildirimoz@hotmail.com

### Banu BOZKURT, MD, FEBO

Selçuk University Faculty of Medicine, Department of Ophthalmology, Konya, Turkey  
Areas of Interest: Cornea and Ocular Surface Disease, Glaucoma, Allergy and Immunology  
E-mail: drbanubozkurt@yahoo.com

## Statistical Board

### Ahmet DİRİCAN

İstanbul University İstanbul Faculty of Medicine, Department of Biostatistics and Medical Informatics, İstanbul, Turkey

## Language Editor

Jacqueline Renee GUTENKUNST, Maryland, USA



## Publishing House

Molla Gürani Mah. Kaçamak Sokak No: 21,  
34093 Fındıkzade-İstanbul-Türkiye  
Phone: +90 212 621 99 25 Fax: +90 212 621 99 27  
E-mail: info@galenos.com.tr

Printed at: Doğa Basım İleri Matbaacılık San. ve Tic. Ltd. Şti.

İ.O.S.B. Turgut Özal Cd. Çelik Yenil İş Mrk.

No:117/2A-2B İkitelli- İstanbul- Turkey

Phone: +90 212 407 09 00 Fax: +90 212 407 09 02

Date of printing: March 2017

International scientific journal published bimonthly.

ISSN: 2149-8695

E-ISSN: 2149-8709

## Advisory Board

### Yonca Aydın Akova,

Bayındır Kavaklıdere Hospital, Ophthalmology Clinic, Ankara, Turkey

### Gürsoy Alagöz,

Sakarya University Faculty of Medicine, Department of Ophthalmology, Sakarya, Turkey

### Mehmet Baykara,

Uludağ University Faculty of Medicine, Department of Ophthalmology, Bursa, Turkey

### Jose M. Benitez-del-Castillo,

Universidad Complutense de Madrid, Hospital Clinico San Carlos, Department of Ophthalmology, Madrid, Spain

### Özlem Budakoğlu,

Ulucanlar Eye Research and Training Hospital, Department of Ophthalmology, Ankara, Turkey

### Güngör Sobacı,

Hacettepe University Faculty of Medicine, Department of Ophthalmology, Ankara, Turkey

### Bülent Gürlü,

Fatih University Faculty of Medicine, Department of Ophthalmology, İstanbul, Turkey

### Murat Doğru,

Keio University Faculty of Medicine, Department of Ophthalmology, Tokyo, Japan

### Kadircan Keskinbora,

Ophthalmology, Independent Practitioner, İstanbul, Turkey

### Anastasio G.P. Konstas,

Aristotle University of Thessaloniki, Department of Ophthalmology, Thessaloniki, Greece

### Anat Loewenstein,

Tel Aviv University Sackler Faculty of Medicine, Department of Ophthalmology, Tel Aviv, Israel

### Ahmet Maden,

Dokuz Eylül University Faculty of Medicine, Department of Ophthalmology, İzmir, Turkey

### Jale Menteş,

Ege University Faculty of Medicine, Department of Ophthalmology, İzmir, Turkey

## The Turkish Journal of Ophthalmology is an official journal of the Turkish Ophthalmological Association.

On Behalf of Turkish Ophthalmological Association Owner

### T. Reha Ersöz,

Çukurova University Faculty of Medicine, Department of Ophthalmology, Adana, Turkey

# TURKISH JOURNAL OF OPHTHALMOLOGY



www.ofthalmoloji.org

TJO

## ABOUT US

The Turkish Journal of Ophthalmology (TJO) is the only scientific periodical publication of the Turkish Ophthalmological Association and has been published since January 1929. In its early years, the journal was published in Turkish and French. Although there were temporary interruptions in the publication of the journal due to various challenges, the Turkish Journal of Ophthalmology has been published continually from 1971 to the present.

The Turkish Journal of Ophthalmology is currently published in Turkish and English languages. TJO is an independent international periodical journal based on single-blind peer-review principle. TJO is regularly published six times a year and special issues are occasionally released. The aim of TJO is to publish original research papers of the highest scientific and clinical value at an international level. Furthermore, review articles, case reports, editorial comments, letters to the editor, educational contributions and congress/meeting announcements are released.

The target audience includes specialists and physicians in training in ophthalmology in all relevant disciplines.

The editorial policies are based on the "Recommendations for the Conduct, Reporting, Editing, and Publication of Scholarly Work in Medical Journals (ICMJE Recommendations)" by the International Committee of Medical Journal Editors (2013, archived at <http://www.icmje.org/>) rules.

The Turkish Journal of Ophthalmology is indexed in the **PubMed Central (PMC)**, **Web of Science-Emerging Sources Citation Index (ESCI)**, **Directory of Open Access Journals (DOAJ)**, **Gale/Cengage Learning**, **Index Copernicus**, **EBSCO Database**, **Scopus**, **Turkish Medline-National Citation Index**, **Turk Medline**, **Cinahl**, **Proquest**, **TUBITAK/ULAKBIM** and **Turkish Citation Index** databases.

### Open Access Policy

This journal provides immediate open access to its content on the principle that making research freely available to the public supports a greater global exchange of knowledge.

Open Access Policy is based on the rules of the Budapest Open Access Initiative (BOAI) <http://www.budapestopenaccessinitiative.org/>. By "open access" to peer-reviewed research literature, we mean its free availability on the public internet, permitting any users to read, download, copy, distribute, print, search, or link to the full texts of these articles, crawl them for indexing, pass them as data to software, or use them for any other lawful purpose, without financial, legal, or technical barriers other than those inseparable from gaining access to the internet itself. The only constraint on reproduction and distribution, and the only role for copyright in this domain, should be to give authors control over the integrity of their work and the right to be properly acknowledged and cited.

### Subscription Information

TJO is sent free of charge to subscribers. Address changes should be immediately reported to the affiliates and to the managing editor. Subscribers who do not receive the journal in the relevant time period should contact the managing editor. All published volumes in full text can be reached free of charge through the website [www.ofthalmoloji.org](http://www.ofthalmoloji.org). Requests for subscription should be addressed to the Turkish Ophthalmological Association.

Manuscripts can only be submitted electronically through the Journal Agent website (<http://journalagent.com/tjo/>) after creating an account. This system allows online submission and review.

### Membership Procedures

#### Turkish Ophthalmological Association

Bank Account: Yapı Kredi Bankası, Şehremini Şubesi 65774842

IBAN: TR10 0006 7010 0000 0065 7748 42

Annual Subscription: Domestic: 100.-TL (Tax Incl)

Abroad: 100 USD (Tax Incl.)

#### Correspondence Address

Editor-in-Chief, Murat İrkeç, MD, Professor in Ophthalmology  
Hacettepe University Faculty of Medicine, Department of Ophthalmology  
06100 Sıhhiye-Ankara-Turkey

**Phone:** +90 212 801 44 36/37 Fax: +90 212 801 44 39

**E-mail:** [mirkec@hacettepe.edu.tr](mailto:mirkec@hacettepe.edu.tr)

#### Secretary, Arzu Sevdasız

**E-mail:** [dergi@ofthalmoloji.org](mailto:dergi@ofthalmoloji.org) - [sekreter@ofthalmoloji.org](mailto:sekreter@ofthalmoloji.org)

**Address:** Avrupa Konutları Kale, Maltepe Mah. Yedikule Çırpıcı Yolu Sk.

9. Blok No: 2 Kat:1 Ofis:1 Zeytinburnu-Istanbul-Turkey

**Phone:** +90 212 801 44 36/37 Fax: +90 212 801 44 39

**Web Page:** [www.ofthalmoloji.org](http://www.ofthalmoloji.org)

#### Permissions

Requests for permission to reproduce published material should be sent to the editorial office.

**Editor-in-Chief:** Murat İrkeç, MD, Professor in Ophthalmology

**Address:** Avrupa Konutları Kale, Maltepe Mah. Yedikule Çırpıcı Yolu Sk.

9. Blok No: 2 Kat:1 Ofis:1 Zeytinburnu-Istanbul-Turkey

**Phone:** +90 212 801 44 36/37 Fax: +90 212 801 44 39

**Web Page:** [www.ofthalmoloji.org](http://www.ofthalmoloji.org)

**E-mail:** [dergi@ofthalmoloji.org](mailto:dergi@ofthalmoloji.org) - [sekreter@ofthalmoloji.org](mailto:sekreter@ofthalmoloji.org)

#### Advertisement

Applications for advertisement should be addressed to the editorial office.

**Address:** Avrupa Konutları Kale, Maltepe Mah. Yedikule Çırpıcı Yolu Sk.

9. Blok No: 2 Kat:1 Ofis:1 Zeytinburnu-Istanbul-Turkey

**Phone:** +90 212 801 44 36/37 Fax: +90 212 801 44 39

**Web Page:** [www.ofthalmoloji.org](http://www.ofthalmoloji.org)

**E-mail:** [dergi@ofthalmoloji.org](mailto:dergi@ofthalmoloji.org) - [sekreter@ofthalmoloji.org](mailto:sekreter@ofthalmoloji.org)

#### Publisher Corresponding Address

**Publisher:** Erkan Mor

Galenos Yayınevi Tic. Ltd. Şti.

**Address:** Molla Gürani Mah. Kaçamak Sk. No: 21, 34093

Fındıkzade-Istanbul-Turkey

**Phone:** +90 212 621 99 25 Fax: +90 212 621 99 27

**E-mail:** [info@galenos.com.tr](mailto:info@galenos.com.tr)

#### Instructions for Authors

Instructions for authors are published in the journal and on the website [www.ofthalmoloji.org](http://www.ofthalmoloji.org)

#### Material Disclaimer

The author(s) is (are) responsible for the articles published in the Turkish Journal of Ophthalmology.

The editor, editorial board and publisher do not accept any responsibility for the articles.

The journal is printed on acid-free paper.

## INSTRUCTIONS TO AUTHORS

The Turkish Journal of Ophthalmology is an official peer-reviewed publication of the Turkish Ophthalmological Association. Accepted manuscripts are published in both Turkish and English languages.

Manuscripts written in Turkish should be in accordance with the Turkish Dictionary and Writing Guide ("Türkçe Sözlüğü ve Yazım Kılavuzu") of the Turkish Language Association. Turkish forms of ophthalmology-related terms should be checked in the TODNET Dictionary ("TODNET Sözlüğü" <http://www.todnet.org/v3/sozluk/default.asp>) and used accordingly.

The Turkish Journal of Ophthalmology does not charge any article submission or processing charges.

A manuscript will be considered only with the understanding that it is an original contribution that has not been published elsewhere.

Reviewed and accepted manuscripts are translated either from Turkish to English or from English to Turkish by the Journal through a professional translation service. Prior to printing, the translations are submitted to the authors for approval or correction requests, to be returned within 7 days. If no response is received from the corresponding author within this period, the translation is checked and approved by the editorial board. The abbreviation of the Turkish Journal of Ophthalmology is TJO, however, it should be denoted as Turk J Ophthalmol when referenced. In the international index and database, the name of the journal has been registered as Turkish Journal of Ophthalmology and abbreviated as Turk J Ophthalmol.

The scientific and ethical liability of the manuscripts belongs to the authors and the copyright of the manuscripts belongs to the Turkish Journal of Ophthalmology. Authors are responsible for the contents of the manuscript and accuracy of the references. All manuscripts submitted for publication must be accompanied by the Copyright Transfer Form [copyright transfer]. Once this form, signed by all the authors, has been submitted, it is understood that neither the manuscript nor the data it contains have been submitted elsewhere or previously published and authors declare the statement of scientific contributions and responsibilities of all authors.

All manuscripts submitted to the Turkish Journal of Ophthalmology are screened for plagiarism using the 'iThenticate' software. Results indicating plagiarism may result in manuscripts being returned or rejected.

Experimental, clinical and drug studies requiring approval by an ethics committee must be submitted to the Turkish Journal of Ophthalmology with an ethics committee approval report confirming that the study was conducted in accordance with international agreements and the Declaration of Helsinki (revised 2008) (<http://www.wma.net/en/30publications/10policies/b3/>). The approval of the ethics committee and the fact that informed consent was given by the patients should be indicated in the Materials and Methods section. In experimental animal studies, the authors should indicate that the procedures followed were in accordance with animal rights as per the Guide for the Care and Use of Laboratory Animals (<http://oacu.od.nih.gov/regs/guide/guide.pdf>) and they should obtain animal ethics committee approval. Authors must provide disclosure/acknowledgment of financial or material support, if any was received, for the current study. If the article includes any direct or indirect commercial links or if any institution provided material support to the study, authors

must state in the cover letter that they have no relationship with the commercial product, drug, pharmaceutical company, etc. concerned; or specify the type of relationship (consultant, other agreements), if any.

Authors must provide a statement on the absence of conflicts of interest among the authors and provide authorship contributions.

The Turkish Journal of Ophthalmology is an independent international journal based on single-blind peer-review principles. The manuscript is assigned to the Editor-in-Chief, who reviews the manuscript and makes an initial decision based on manuscript quality and editorial priorities. Manuscripts that pass initial evaluation are sent for external peer review, and the Editor-in-Chief assigns an Associate Editor. The Associate Editor sends the manuscript to three reviewers (internal and/or external reviewers). The reviewers must review the manuscript within 21 days. The Associate Editor recommends a decision based on the reviewers' recommendations and returns the manuscript to the Editor-in-Chief. The Editor-in-Chief makes a final decision based on editorial priorities, manuscript quality, and reviewer recommendations. If there are any conflicting recommendations from reviewers, the Editor-in-Chief can assign a new reviewer.

The scientific board guiding the selection of the papers to be published in the Journal consists of elected experts of the Journal and if necessary, selected from national and international authorities. The Editor-in-Chief, Associate Editors, biostatistics expert and English language consultant may make minor corrections to accepted manuscripts that do not change the main text of the paper.

In case of any suspicion or claim regarding scientific shortcomings or ethical infringement, the Journal reserves the right to submit the manuscript to the supporting institutions or other authorities for investigation. The Journal accepts the responsibility of initiating action but does not undertake any responsibility for an actual investigation or any power of decision.

The Editorial Policies and General Guidelines for manuscript preparation specified below are based on "Recommendations for the Conduct, Reporting, Editing, and Publication of Scholarly Work in Medical Journals (ICMJE Recommendations)" by the International Committee of Medical Journal Editors (2013, archived at <http://www.icmje.org/>).

Preparation of research articles, systematic reviews and meta-analyses must comply with study design guidelines:

CONSORT statement for randomized controlled trials (Moher D, Schulz KF, Altman D, for the CONSORT Group. The CONSORT statement revised recommendations for improving the quality of reports of parallel group randomized trials. *JAMA* 2001; 285: 1987-91) (<http://www.consort-statement.org/>);

PRISMA statement of preferred reporting items for systematic reviews and meta-analyses (Moher D, Liberati A, Tetzlaff J, Altman DG, The PRISMA Group. Preferred Reporting Items for Systematic Reviews and Meta-Analyses: The PRISMA Statement. *PLoS Med* 2009; 6(7): e1000097.) (<http://www.prisma-statement.org/>);

STARD checklist for the reporting of studies of diagnostic accuracy (Bossuyt PM, Reitsma JB, Bruns DE, Gatsonis CA, Glasziou PP, Irwig LM, et al., for the STARD Group. Towards complete and accurate reporting of studies of diagnostic

accuracy: the STARD initiative. *Ann Intern Med* 2003;138:40-4.) (<http://www.stard-statement.org/>);

STROBE statement, a checklist of items that should be included in reports of observational studies (<http://www.strobe-statement.org/>);

MOOSE guidelines for meta-analysis and systemic reviews of observational studies (Stroup DF, Berlin JA, Morton SC, et al. Meta-analysis of observational studies in epidemiology: a proposal for reporting Meta-analysis of observational Studies in Epidemiology (MOOSE) group. *JAMA* 2000; 283: 2008-12).

### GENERAL GUIDELINES

Manuscripts can only be submitted electronically through the Journal Agent website (<http://journalagent.com/tjo/>) after creating an account. This system allows online submission and review.

The manuscripts are archived according to ICMJE, Index Medicus (Medline/PubMed) and Ulakbim-Turkish Medicine Index Rules.

Format: Manuscripts should be prepared using Microsoft Word, size A4 with 2.5 cm margins on all sides, 12 pt Arial font and 1.5 line spacing.

**Abbreviations:** Abbreviations should be defined at first mention and used consistently thereafter. Internationally accepted abbreviations should be used; refer to scientific writing guides as necessary.

**Cover letter:** The cover letter should include statements about manuscript type, single-journal submission affirmation, conflict of interest statement, sources of outside funding, equipment (if applicable), approval of language for articles in English and approval of statistical analysis for original research articles.

### REFERENCES

Authors are solely responsible for the accuracy of all references.

**In-text citations:** References should be indicated as a superscript immediately after the period/full stop of the relevant sentence. If the author(s) of a reference is/are indicated at the beginning of the sentence, this reference should be written as a superscript immediately after the author's name. If relevant research has been conducted in Turkey or by Turkish investigators, these studies should be given priority while citing the literature.

Presentations presented in congresses, unpublished manuscripts, theses, Internet addresses, and personal interviews or experiences should not be indicated as references. If such references are used, they should be indicated in parentheses at the end of the relevant sentence in the text, without reference number and written in full, in order to clarify their nature.

**References section:** References should be numbered consecutively in the order in which they are first mentioned in the text. All authors should be listed regardless of number. The titles of journals should be abbreviated according to the style used in the Index Medicus.

### Reference Format

**Journal:** Last name(s) of the author(s) and initials, article title, publication title and its original abbreviation, publication date, volume, the inclusive page numbers. Example: Collin JR, Rathbun JE. Involitional entropion: a review with evaluation of a procedure. *Arch Ophthalmol*. 1978;96:1058-1064.

## INSTRUCTIONS TO AUTHORS

**Book:** Last name(s) of the author(s) and initials, chapter title, book editors, book title, edition, place of publication, date of publication and inclusive page numbers of the extract cited.

**Example:** Herbert L. The Infectious Diseases (1st ed). Philadelphia; Mosby Harcourt; 1999:11;1-8.

**Book Chapter:** Last name(s) of the author(s) and initials, chapter title, book editors, book title, edition, place of publication, date of publication and inclusive page numbers of the cited piece.

**Example:** O'Brien TP, Green WR. Periocular Infections. In: Feigin RD, Cherry JD, eds. Textbook of Pediatric Infectious Diseases (4th ed). Philadelphia; W.B. Saunders Company; 1998:1273-1278.

**Books in which the editor and author are the same person:** Last name(s) of the author(s) and initials, chapter title, book editors, book title, edition, place of publication, date of publication and inclusive page numbers of the cited piece.

**Example:** Solcia E, Capella C, Kloppel G. Tumors of the exocrine pancreas. In: Solcia E, Capella C, Kloppel G, eds. Tumors of the Pancreas. 2nd ed. Washington: Armed Forces Institute of Pathology; 1997:145-210.

### TABLES, GRAPHICS, FIGURES, AND IMAGES

All visual materials together with their legends should be located on separate pages that follow the main text.

**Images:** Images (pictures) should be numbered and include a brief title. Permission to reproduce pictures that were published elsewhere must be included. All pictures should be of the highest quality possible, in

JPEG format, and at a minimum resolution of 300 dpi.

**Tables, Graphics, Figures:** All tables, graphics or figures should be enumerated according to their sequence within the text and a brief descriptive caption should be written. Any abbreviations used should be defined in the accompanying legend. Tables in particular should be explanatory and facilitate readers' understanding of the manuscript, and should not repeat data presented in the main text.

### BIOSTATISTICS

To ensure controllability of the research findings, the study design, study sample, and the methodological approaches and applications should be explained and their sources should be presented.

The "P" value defined as the limit of significance along with appropriate indicators of measurement error and uncertainty (confidence interval, etc.) should be specified. Statistical terms, abbreviations and symbols used in the article should be described and the software used should be defined. Statistical terminology (random, significant, correlation, etc.) should not be used in non-statistical contexts.

All results of data and analysis should be presented in the Results section as tables, figures and graphics; biostatistical methods used and application details should be presented in the Materials and Methods section or under a separate title.

### MANUSCRIPT TYPES

#### Original Articles

Clinical research should comprise clinical observation, new techniques or laboratories studies. Original research articles should include title, structured abstract, keywords relevant to the content of the article, introduction, materials and methods,

results, discussion, study limitations, conclusion, references, tables/figures/images and acknowledgement sections. Title, abstract and key words should be written in both Turkish and English. The manuscript should be formatted in accordance with the above-mentioned guidelines and should not exceed sixteen A4 pages.

**Title Page:** This page should include the title of the manuscript, short title, name(s) of the authors and author information. The following descriptions should be stated in the given order:

1. Title of the manuscript (Turkish and English), as concise and explanatory as possible, including no abbreviations, up to 135 characters
2. Short title (Turkish and English), up to 60 characters
3. Name(s) and surname(s) of the author(s) (without abbreviations and academic titles) and affiliations
4. Name, address, e-mail, phone and fax number of the corresponding author
5. The place and date of scientific meeting in which the manuscript was presented and its abstract published in the abstract book, if applicable

**Abstract:** A summary of the manuscript should be written in both Turkish and English. References should not be cited in the abstract. Use of abbreviations should be avoided as much as possible; if any abbreviations are used, they must be taken into consideration independently of the abbreviations used in the text. For original articles, the structured abstract should include the following sub-headings:

**Objectives:** The aim of the study should be clearly stated.

**Materials and Methods:** The study and standard criteria used should be defined; it should also be indicated whether the study is randomized or not, whether it is retrospective or prospective, and the statistical methods applied should be indicated, if applicable.

**Results:** The detailed results of the study should be given and the statistical significance level should be indicated.

**Conclusion:** Should summarize the results of the study, the clinical applicability of the results should be defined, and the favorable and unfavorable aspects should be declared.

**Keywords:** A list of minimum 3, but no more than 5 key words must follow the abstract. Key words in English should be consistent with "Medical Subject Headings (MESH)" ([www.nlm.nih.gov/mesh/MBrowser.html](http://www.nlm.nih.gov/mesh/MBrowser.html)). Turkish key words should be direct translations of the terms in MESH.

#### Original research articles should have the following sections:

**Introduction:** Should consist of a brief explanation of the topic and indicate the objective of the study, supported by information from the literature.

**Materials and Methods:** The study plan should be clearly described, indicating whether the study is randomized or not, whether it is retrospective or prospective, the number of trials, the characteristics, and the statistical methods used.

**Results:** The results of the study should be stated, with tables/figures given in numerical order; the results should be evaluated according to the statistical analysis methods applied. See General Guidelines for details about the preparation of visual material.

**Discussion:** The study results should be discussed in terms of their favorable and unfavorable aspects and they should be compared with the literature. The conclusion of the study should be highlighted.

**Study Limitations:** Limitations of the study should be discussed. In addition, an evaluation of the implications of the obtained findings/results for future research should be outlined.

**Conclusion:** The conclusion of the study should be highlighted.

**Acknowledgements:** Any technical or financial support or editorial contributions (statistical analysis, English/Turkish evaluation) towards the study should appear at the end of the article.

**References:** Authors are responsible for the accuracy of the references. See General Guidelines for details about the usage and formatting required.

#### Case Reports

Case reports should present cases which are rarely seen, feature novelty in diagnosis and treatment, and contribute to our current knowledge. The first page should include the title in Turkish and English, an unstructured summary not exceeding 150 words, and key words. The main text should consist of introduction, case report, discussion and references. The entire text should not exceed 5 pages (A4, formatted as specified above).

#### Review Articles

Review articles can address any aspect of clinical or laboratory ophthalmology. Review articles must provide critical analyses of contemporary evidence and provide directions of or future research. Most review articles are commissioned, but other review submissions are also welcome. Before sending a review, discussion with the editor is recommended.

Reviews articles analyze topics in depth, independently and objectively. The first chapter should include the title in Turkish and English, an unstructured summary and key words. Source of all citations should be indicated. The entire text should not exceed 25 pages (A4, formatted as specified above).

#### Letters to the Editor

Letters to the Editor should be short commentaries related to current developments in ophthalmology and their scientific and social aspects, or may be submitted to ask questions or offer further contributions in response to work that has been published in the Journal. Letters do not include a title or an abstract; they should not exceed 1,000 words and can have up to 5 references.

#### CORRESPONDENCE

All correspondence should be directed to the TJO editorial board:

**Post:** Turkish Ophthalmological Association  
Adress: Avrupa Konutları Kale, Maltepe Mah. Yedikule Çırpıcı Yolu Sk. 9. Blok No: 2 Kat:1 Ofis:1 Zeytinburnu-İstanbul-Turkey

**Phone:** +90 212 801 44 36/37 Fax: +90 212 801 44 39

**Web Page:** [www.ofthalmoloji.org](http://www.ofthalmoloji.org)

**E-mail:** [dergi@ofthalmoloji.org](mailto:dergi@ofthalmoloji.org) / [sekreter@ofthalmoloji.org](mailto:sekreter@ofthalmoloji.org)

# TURKISH JOURNAL OF OPHTHALMOLOGY



www.offalmoloji.org

TJO

## CONTENTS

### Original Articles

- 63 Comparison of Outcomes in Patients Who Underwent Deep Anterior Lamellar Keratoplasty and Those Converted to Penetrating Keratoplasty  
Yusuf Koçluk, Emine Alyamaç Sukgen, Ayşe Burcu
- 68 Comparison of Biofilm Formation Capacities of Two Clinical Isolates of *Staphylococcus Epidermidis* with and without *icaA* and *icaD* Genes on Intraocular Lenses  
Sertaç Argun Kıvanç, Merih Kıvanç, Volkan Kılıç, Gülay Güllülü, Ahmet Tuncer Özmen
- 74 Contrast Sensitivity in Microtropic and Anisometropic Eyes of Successfully Treated Amblyopes  
Özlem Öner, Sezin Akça Bayar, Sibel Oto, Onur Gökmen, Mustafa Agah Tekindal
- 80 Factors Affecting Contrast Sensitivity in Healthy Individuals: A Pilot Study  
Arzu Seyhan Karatepe, Süheyla Köse, Sait Eğrilmez
- 85 The Relationship between Serum Carbonic Anhydrase III Autoantibody Levels and Diabetic Retinopathy in Type 1 Diabetes Patients  
Adem Türk, Süleyman Mollamehmetoğlu, Ahmet Alver, Ahmet Menteşe, İrfan Nuhoğlu, Cihangir Erem, Halil İbrahim İmamoğlu
- 89 Treatment Results in Serpiginous Choroiditis and Multifocal Serpiginoid Choroiditis Associated with Latent Tuberculosis  
Merih Oray, Zaur Zakiev, Tülin Çağatay, İlknur Tuğal-Tutkun

### Review

- 94 Thyroid-associated Ophthalmopathy  
Esra Şahli, Kaan Gündüz

### Case Reports

- 106 Spontaneous Late Intraocular Lens and Capsule Tension Ring Dislocation  
Ayşe Gül Koçak Altıntaş, Aslıhan Esra Omay, Selda Çelik
- 110 Rare Clinical Sign of Hodgkin's Lymphoma: Ocular Involvement  
Ziya Ayhan, Revan Yıldırım Karabağ, İnci Alacacıoğlu, Süleyman Kaynak, Nilüfer Koçak
- 113 Giant Hidrocystoma of the Orbit Presenting with Inversion and Ptosis of the Upper Eyelid  
Melis Palamar, Banu Yaman, Taner Akalın, Ayşe Yağcı
- 115 Multiple Intravitreal Ranibizumab Injections for Persistent Choroidal Neovascularization Associated with Presumed Ocular Histoplasmosis Syndrome  
Turgut Yılmaz, Seyhan Dikci, Oğuzhan Genç, Kayhan Mutlu
- 119 Three-dimensional Optical Coherence Tomography Imaging and Treatment of Glaucomatous Optic Nerve Head Defects Associated with Schisis-like Maculopathy  
Zafer Öztaş, Jale Menteş, Halil Ateş, Serhad Nalçacı

### Letter to the Editor

- 123 Intravitreal Bevacizumab in Vitreous Hemorrhage and Diabetes Mellitus  
Beuy Joob, Viroj Wiwanitkit

## EDITORIAL

### 2017 issue 2 at a glance:

From among the many worthy submissions to our journal, for this issue we have selected six original articles, one review, five case reports, and a letter to the editor which we believe will contribute to the scientific literature.

Koçluk et al. compared outcomes of patients who underwent deep anterior lamellar keratoplasty with those of patients for whom the same procedure was converted to penetrating keratoplasty due to intraoperative macroperforation of Descemet's membrane. The authors were unable to detect any statistically significant differences between the two surgical procedures in terms of corrected visual acuity, astigmatism, pachymetry, and postoperative complication rates (see pages 63-67).

Kıvanç et al. compared biofilm production by *Staphylococcus epidermidis* KA 15.8, a known biofilm-producer positive for icaA, icaD, and bap genes, and *S. epidermidis* KA 14.5, considered a non-biofilm-producer negative for the icaA, icaD and bap genes, on four different intraocular lenses (2 foldable acrylic and 2 PMMA). Evaluation of the IOL-adherent biofilms by bacterial enumeration and optical density (OD) measurement showed that the hydrophilic acrylic lens with hydrophobic properties had the least biofilm production (see pages 68-73).

Öner et al. compared contrast sensitivity in the rehabilitated (with occlusion therapy) amblyopic eyes and normal fellow eyes of patients with amblyopia due to microtropia or anisometropia. They found that the microtropic eyes had significantly reduced contrast sensitivity at spatial frequencies of 3, 12, and 18 cpd, while the anisometropic eyes only showed a significant difference at 12 cpd. The authors emphasized that contrast sensitivity is an important parameter to assess in addition to visual acuity when deciding when to discontinue occlusion therapy (see pages 74-79).

In their pilot study investigating factors affecting contrast sensitivity levels in individuals with refractive errors less than 1 diopter, Karatepe et al. observed that contrast sensitivity at medium and high spatial frequencies decreases with increasing age, binocular values were higher than monocular values, and contrast sensitivity was higher in scotopic compared to photopic conditions (see pages 80-84).

The literature contains reports that autoantibodies to carbonic anhydrase (CA) isoenzymes are associated with certain autoimmune diseases. Türk et al. analyzed CA autoantibody levels in healthy individuals and type 1 diabetes patients with and without diabetic retinopathy and demonstrated that although CA-II autoantibody levels were substantially higher in patients with diabetic retinopathy, they were not related to macular edema (see pages 85-88).

Oray et al. compared the outcomes of treatment with antituberculous therapy (ATT) and immunomodulatory therapy (IMT) in patients with serpinginous choroiditis (SC) and multifocal serpinginoid choroiditis (MSC) associated with latent tuberculosis. Though a statistical difference between the two treatment methods could not be detected due to the small number of patients, the authors determined that ATT may be an appropriate primary therapy for MSC associated with latent tuberculosis, and may be used to treat SC refractory to IMT (see pages 89-93).

For this issue, Şahlı and Gündüz present a comprehensive review examining the epidemiology, pathogenesis, clinical signs, and current therapeutic approaches to thyroid-associated ophthalmopathy, the most common extrathyroidal

manifestation of Graves' disease. In mild cases, signs and symptoms can be controlled with supportive therapies, whereas severe cases may require systemic steroids, immunosuppressive agents, plasmapheresis, intravenous immunoglobulin, radiotherapy, and orbital decompression surgery (see pages 94-105).

In pseudoexfoliation syndrome, the lens zonules are more fragile and have diminished elasticity, and spontaneous intraocular lens dislocation may occur due to capsular fibrosis. Intraoperative use of a capsule tension ring reduces the risk of zonular rupture but is no guarantee against intraocular lens dislocation in the long term. In a case report from Koçak Altıntaş et al. discussing 3 cases of spontaneous dislocation of the intraocular lens and capsule tension ring 2.5-8 years after uncomplicated phacoemulsification surgery, the authors report observing no complications after removing the capsular bag containing the intraocular lens and capsule tension ring and implanting an anterior chamber intraocular lens (see pages 106-109).

Ayhan et al. present the case of a 19-year-old female patient who presented with bilateral non-granulomatous anterior uveitis and vitritis and macular edema in the left eye. A full-body computed tomography scan revealed a pathologic mediastinal lymph node and biopsy results indicated nodular sclerosing and mixed cellularity Hodgkin's lymphoma. All signs of uveitis resolved after chemotherapy. Ocular involvement is usually observed after diagnosis of Hodgkin's lymphoma, but may rarely be an initial sign (see pages 110-112).

Hidrocystomas are benign adnexal tumors of eccrine or apocrine origin. In a case report by Palamar et al., magnetic resonance imaging of a female patient presenting with severe pain in the upper eyelid, tearing, ptosis, and corneal erosion revealed a large cystic intraorbital/extraconal lesion located in the superior aspect of the orbit. The mass was excised and determined in histopathologic analysis to be consistent with an eccrine hidrocystoma (see pages 113-114).

Yılmaz et al. share the case of a myopic patient with persistent juxtafoveal CNV secondary to presumed ocular histoplasmosis who was treated with a total of 5 ranibizumab injections during 1.5 years of follow-up. Initial best corrected visual acuity was 0.6; after treatment, subretinal scar formed and the patient's visual acuity was 0.3 (see pages 115-118).

In glaucoma, acquired optic disc pits form due to localized depressions in the lamina cribrosa resulting from neuroretinal rim loss. Macular schisis and serous retinal detachment may also develop in acquired optic disc pits and can result in serious vision loss. The case report from Öztas et al. concerns a male patient who underwent bilateral trabeculectomy 6 years earlier for primary closed-angle glaucoma. Using 3D spectral domain optical coherence tomography, the authors detected prelaminar and laminar defects of various sizes, shapes, and depths in the outer walls of the optic nerve canal, and demonstrated that these defects were adjacent and connected to the retinal layers (see pages 119-122).

Finally, you can find a Letter to the Editor written in response to an article entitled "The Efficacy of Intravitreal Bevacizumab in Vitreous Hemorrhage of Diabetic Subjects" published in a previous issue, as well as a response from the authors of that study (see pages 123-124).

Respectfully on behalf of the Editorial Board,

Banu Bozkurt, MD



# Comparison of Outcomes in Patients Who Underwent Deep Anterior Lamellar Keratoplasty and Those Converted to Penetrating Keratoplasty

Yusuf Koçluk\*, Emine Alyamaç Sukgen\*, Ayşe Burcu\*\*

\*Adana Numune Training and Research Hospital, Ophthalmology Clinic, Adana, Turkey

\*\*Ankara Training and Research Hospital, Ophthalmology Clinic, Ankara, Turkey

## Abstract

**Objectives:** To compare clinical outcomes of cases who underwent deep anterior lamellar keratoplasty (DALK) and cases who were converted to penetrating keratoplasty (PKP) from DALK surgery.

**Materials and Methods:** The records of 54 patients for whom DALK surgery was planned and were operated for different diagnoses between March 2013 and June 2015 were retrospectively analyzed. Patients were divided into two groups: group 1 (PKP group) consisted of 23 cases who were converted to PKP due to Descemet's membrane perforation at any stage of surgery; group 2 (DALK group) consisted of 31 patients whose surgery could be completed as DALK. Preoperative and postoperative follow-up results were evaluated in each group.

**Results:** Corrected distance visual acuity (CDVA) increased in the postoperative period according to baseline in both groups. However, there was no statistically significant difference in the rates of CDVA increase between the groups ( $p=0.142$ ). The mean astigmatism measured by corneal topography at final examination was  $5.8\pm 2.3$  diopters in group 1 and  $5.4\pm 1.8$  diopters in group 2. The difference between groups was not statistically significant ( $p=0.430$ ). The groups were not statistically different regarding postoperative pachymetry ( $p=0.453$ ). The grafts in all 54 patients (100%) were clear at final postoperative examination. There were no statistically significant differences between the groups in terms of postoperative complications.

**Conclusion:** Similar clinical outcomes were obtained in our study for patients who underwent DALK and those whose procedure was converted from DALK to PKP.

**Keywords:** Deep anterior lamellar keratoplasty, penetrating keratoplasty, Descemet's membrane

## Introduction

Penetrating keratoplasty (PKP) has been used as a standard technique in the treatment of corneal stromal pathologies and yields acceptable optical and visual results, as presented in previous studies.<sup>1,2,3</sup> However, graft failure problems may occur in about 18-34% of cases.<sup>2,3</sup> Approximately half of graft failures are the result of endothelial rejection.<sup>4</sup>

Deep anterior lamellar keratoplasty (DALK) has been used as an alternative to PKP in the last 15 years in cases with intact endothelium, such as stromal scar, stromal dystrophies, and keratoconus.<sup>5</sup> This surgical technique conserves the patient's own endothelial cells. Minimal endothelial cell damage results in longer graft survival postoperatively.<sup>5</sup> The lower reported

intraoperative and postoperative complication rates with lamellar keratoplasty is another reason to prefer DALK.<sup>6</sup> However, intraoperative complication rates may be slightly higher in the early stages of the DALK procedure. Furthermore, the procedure has a long learning curve, is laborious, and has a longer surgery duration.

The aim of this study was to compare the clinical outcomes in patients who underwent DALK and those whose DALK was converted to PKP intraoperatively.

## Materials and Methods

The medical records of 54 patients for whom DALK surgery was planned and who were operated for different diagnoses in our ophthalmology clinic between March 2013 and June 2015

**Address for Correspondence:** Yusuf Koçluk MD, Adana Numune Training and Research Hospital, Ophthalmology Clinic, Adana, Turkey  
Phone: +90 506 645 90 40 E-mail: koçluk99@gmail.com **Received:** 05.02.2016 **Accepted:** 11.06.2016



were retrospectively analyzed. The patients were divided into 2 groups. The 23 patients whose DALK was converted to PKP due to Descemet's membrane (DM) perforation at any stage of the surgery comprised group 1 (PKP group); the 31 patients whose surgery was completed as DALK comprised group 2 (DALK group). The study was approved by the local ethics committee and was conducted in accordance with the principles of the Declaration of Helsinki.

Patients scheduled for DALK whose endothelium was intact and had keratoconus, stroma corneal dystrophy, or stromal scar were included in the study. Patients with additional ocular pathology in the preoperative period and those followed for less than 6 months were excluded. For patients in both groups, preoperative and postoperative 1 day, 1 month, and final follow-up examination data including slit-lamp examination findings (graft transparency, DM attachment, ocular surface and suture problems), intraoperative complications (DM rupture and other problems), and postoperative outcomes (visual acuity, intraocular pressure [IOP], graft status, astigmatism value, corneal thickness values), and postoperative complications (glaucoma, cataract, synechia, rejection reaction, epithelial problems, suture problems, keratitis and interface problems) were obtained from medical records and surgery videos. Corrected distance visual acuity (CDVA) was measured using Snellen chart (in decimal) and IOP was measured using Goldmann applanation tonometry. Astigmatism and corneal thickness values were measured using corneal topography (Pentacam, Oculus, Wetzlar, Germany).

### Surgical Technique

All procedures were performed by the same surgeon (Y.K.) under general or local anesthesia. All patients were initially planned as DALK; cases with intraoperative DM macroperforation as a complication were converted to PKP for the completion of the surgery. The previously described 'double bubble' DALK technique was used in cases that underwent complete DALK.<sup>7</sup>

Partial trepanization was performed in 60-80% thickness using a vacuum trepan (Katena Products, Inc., Denville, NJ, USA). A side port was then created in the limbus at 11 o'clock using a micro vitreoretinal (MVR) blade, and a small amount of anterior chamber (AC) fluid was allowed to escape. A few small bubbles were placed in the AC. A 27-gauge needle attached to a 5 ml air-filled syringe was inserted beveled side down through the incision and advanced 3-4 mm toward the center of the corneal stroma. Air was injected onto the DM. When the small bubbles in the AC moved toward the periphery, it was assumed the DM had separated and the big bubble had formed. The anterior stroma was dissected with a crescent knife. The posterior stroma was perforated with an MVR, and the air bubble was emptied. The AC bubble returned to center. Viscoelastic was placed on the DM and the remaining stromal tissue was removed using corneal scissors. In cases where the DM could not be separated with air, we attempted to access the DM using manual dissection. After preparing the graft bed, a donor cornea 0.25 mm larger in diameter than the graft bed was obtained using a vacuum donor punch (Katena Products, Inc. Denville, New Jersey, USA). Removal of the endothelium and DM was facilitated by

trypan blue. Grafts with 0.5 mm larger diameter were preferred for patients converted to PKP but without keratoconus. The graft was secured to the graft bed using 10/0 nylon sutures. A 16-point continuous suturation technique was used in all patients. In cases with intraoperative microperforation, the procedure was continued after applying air tamponade to the AC. However, the procedure was converted to PKP in cases with widening perforation and macroperforation. The AC bubbles assisted monitoring of DM integrity throughout the procedure.

### Postoperative Follow-up

Postoperatively, all patients were treated with topical 0.5% moxifloxacin (Vigamox 0.5% sterile ophthalmic solution, Alcon) 6 times daily for 3 weeks and artificial tears for approximately 1 year. In group 1, patients received 0.1% dexamethasone (Maxidex sterile ophthalmic suspension, Alcon) starting at 6 times daily with decreasing doses for 6-8 months; in group 2, patients continued with decreasing doses for 3-4 months. When necessary, elevated IOP was controlled with an appropriate antiglaucomatous agent. When elevated IOP was believed to be associated with steroid use, topical dexamethasone treatment was discontinued for patients in the DALK group, and patients in the PKP group were continued with a lower dose of an agent with lower potency (loteprednol). In patients with slackening of the continuous suture in the early postoperative phase, the suturing was renewed by placing individual stitches. In cases of slackened suture in the late phase, the suture was either removed or, when necessary, removed and replaced with additional interrupted stitches. Complete suture removal was performed after 12-24 months depending on postoperative astigmatism values and whether the surgery was DALK or PKP.

### Statistical Analysis

SPSS for Windows version 16.0 (SPSS Inc. Chicago, USA) was used for statistical analyses. Normality of data distribution was assessed using the Kolmogorov-Smirnov test, and homogeneity was checked using one-way ANOVA. Quantitative variables were presented as mean  $\pm$  standard deviation, and comparisons between groups were made using a t-test. Pre- to postoperative numerical changes were compared between groups using two-way repeated measures ANOVA. Qualitative variables were expressed as percentages and compared using the chi-square test. P values less than 0.05 were accepted as statistically significant.

### Results

Fifty-four eyes of 54 patients (23 PKP, 31 DALK) were included. The mean age of the patients was  $41.1 \pm 11.3$  years in the PKP group and  $38.6 \pm 12.8$  years in the DALK group. The female:male ratio was 13/10 in the PKP group and 17/14 in the DALK group. There were no significant differences in age or gender distribution between the groups ( $p=0.457$  and  $p=0.902$ , respectively). The groups were also statistically equivalent in terms of laterality ( $p=0.610$ ). Mean follow-up time was  $14.0 \pm 3.6$  (9-20) months in the PKP group and  $14.8 \pm 5.1$  (7-24) months in the DALK group. There was no significant difference between the groups in terms of follow-up time ( $p=0.492$ ). Preoperative

demographic characteristics, indications and postoperative parameters are presented in Table 1.

CDVA had significantly improved compared to baseline at postoperative 1 day, 1 month, and at final examination in both groups ( $p < 0.001$  for all). However, there was no statistically significant difference in the rates of CDVA increase between the groups ( $p = 0.142$ , two-way repeated measures ANOVA). Changes in CDVA are presented in Figure 1. IOP values measured preoperatively and postoperatively showed no significant differences in either group, and there was no significant difference between the groups ( $p = 0.456$ ). Mean astigmatism value obtained by corneal topography at final examination was  $5.8 \pm 2.3$  diopters in the PKP group and  $5.4 \pm 1.8$  diopters in the DALK group. There was no significant difference between the groups ( $p = 0.430$ ). Mean central corneal thickness obtained by corneal topography at final examination was  $535 \pm 35.2$   $\mu\text{m}$  in the PKP group and  $532 \pm 40.1$   $\mu\text{m}$  in the DALK group. The difference between the groups was not statistically significant ( $p = 0.453$ ).

Of the patients whose procedure was converted to PKP, DM perforation occurred during trepanization or creation of the big bubble in 6 cases (26.1%), while perforating the posterior stroma in 8 cases (34.8%), and during removal of posterior stromal fragments in 9 cases (39.1%). DM microperforation occurred in 2 patients (6.5%) in the DALK group during suturation, but their procedures were completed as DALK. Double AC was

observed on the first postoperative day in 5 patients (16.1%). In these patients, air tamponade was injected to the AC to restore DM attachment and graft transparency was achieved. Clear grafts were observed at final postoperative examination in all 54 patients (100%) in both groups. Pre- and postoperative photographs of one case from each group are shown in Figure 2.

Postoperative steroid-induced glaucoma was observed in 7 patients (30.4%) from the PKP group and 7 patients (22.6%) from the DALK group. The difference was not statistically significant ( $p = 0.515$ ). IOP was controlled in all of these patients with appropriate antiglaucomatous therapy and eliminating or reducing the dosage of topical steroid. None of the patients required glaucoma surgery.

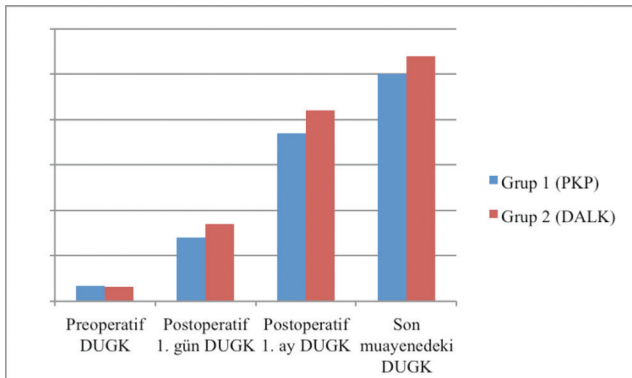
Postoperative cataract developed in 4 patients (17.4%) from the PKP group and 6 (19.4%) from the DALK group. The difference was not statistically significant ( $p = 0.854$ ). Anterior synechia was observed postoperatively in 2 patients (8.7%) in the PKP group and no patients from the DALK group ( $p = 0.094$ ). None of the patients in either group exhibited a rejection reaction postoperatively.

Postoperative recurrent epithelial defect was observed in 1 patient (4.3%) from the PKP group and 3 (9.7%) from the DALK group. Epithelialization was achieved in these cases using conservative methods. All of these patients had a preoperative diagnosis of lattice stromal dystrophy. None of the patients in either group developed keratitis. In addition, a 2-3 mm filamentous foreign body was detected in the paracentral

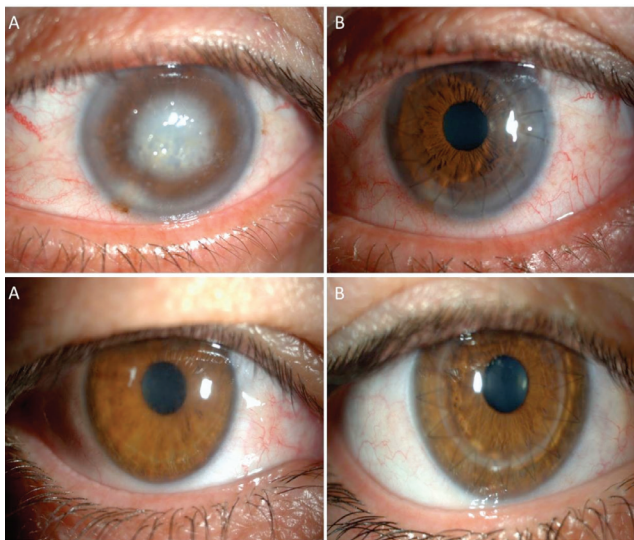
**Table 1. Comparison of demographic, surgical, and pre-/postoperative values for certain parameters between study groups**

	Group 1 (PKP group)	Group 2 (DALK group)	p
Age (years; mean $\pm$ SD)	41.1 $\pm$ 11.3	38.6 $\pm$ 12.8	0.457
Sex, female/male	13/10	17/14	0.902
Eye, right/left	12/11	14/17	0.610
Follow-up time (mean months)	14	14.8	0.492
Donor cornea age (years, mean $\pm$ SD)	53.3 $\pm$ 7.6	53.6 $\pm$ 6.7	0.850
Graft bed diameter (mm)	7.4 $\pm$ 0.2	7.3 $\pm$ 0.2	0.102
Graft diameter (mm)	7.9 $\pm$ 0.2	7.6 $\pm$ 0.2	<0.001
Anesthesia, GA/LA	18/5	29/2	0.098
Preoperative diagnosis	-	-	0.598
Keratoconus	6 (26.1%)	11 (35.5%)	-
Macular stromal dystrophy	8 (34.8%)	9 (29.0%)	-
Lattice stromal dystrophy	5 (21.7%)	8 (25.8%)	-
Stromal scar	4 (17.4%)	2 (6.5%)	-
Basal membrane dystrophy	0 (0%)	1 (3.2%)	-
Preoperative CDVA	0.034 $\pm$ 0.01	0.031 $\pm$ 0.01	0.455
Preoperative IOP	13.9 $\pm$ 2.2	14.2 $\pm$ 2.3	0.625
Final CDVA	0.50 $\pm$ 0.14	0.54 $\pm$ 0.12	0.317
Final IOP	14.6 $\pm$ 1.67	13.7 $\pm$ 1.87	0.083
Final astigmatism (diopter)	5.8 $\pm$ 2.3	5.4 $\pm$ 1.8	0.430
Final central corneal thickness ( $\mu\text{m}$ )	535 $\pm$ 35.2	532 $\pm$ 40.1	0.453

CDVA: Corrected distance visual acuity, PKP: Penetrating keratoplasty, DALK: Deep anterior lamellar keratoplasty, SD: Standard deviation, GA: General anesthesia, LA: Local anesthesia, IOP: Intraocular pressure



**Figure 1.** Changes in corrected distance visual acuity in the study groups  
 Preop: Preoperative, Postop: Postoperative, CDVA: Corrected distance visual acuity, PKP: Penetrating keratoplasty, DALK: Deep anterior lamellar keratoplasty



**Figure 2.** Upper row: Images of a patient with lattice stromal dystrophy who underwent deep anterior lamellar keratoplasty, taken preoperatively (A) and at final postoperative examination (B); bottom row: Images of a patient with lattice stromal dystrophy whose deep anterior lamellar keratoplasty was converted to penetrating keratoplasty, taken preoperatively (A) and at final postoperative examination (B)

interface of 1 DALK patient (3.2%), but no symptoms or side effects were observed in relation to its presence.

## Discussion

The advantages of DALK include protection of a patient's own endothelium, less postoperative immune reaction, and shorter follow-up times and steroid use. The closed system of the procedure reduces complications such as intraoperative expulsive hemorrhage, anterior synechia, cataract, and angle narrowing.<sup>6</sup> With adequate stromal clearing and lowering of the DM, DALK can yield postoperative visual results comparable to those of PKP.<sup>8,9</sup> In the present study, we also achieved similar postoperative visual acuity results in our DALK and PKP cases. We were able to reach the DM surface in all of our DALK cases with complete removal of the posterior stroma.

In a previous study, mean postoperative astigmatism values after suture adjustment were -2.94 diopters in DALK patients and -3.28 diopters in PKP patients; the difference in astigmatism values was not significant.<sup>10</sup> In the same study, postoperative pachymetry values were similar between the groups.<sup>10</sup> In our study, astigmatism values were slightly higher postoperatively in both groups. This difference may be explained by the fact that sutures were not adjusted postoperatively in any of our patients. Consistent with the literature, in the present study we observed similar postoperative corneal thickness values between the groups.

Various studies have reported DM perforation during DALK at rates ranging between 4% and 39.2%.<sup>11,12,13</sup> This rate is associated with surgical experience, keratoplasty indication, and surgical technique.<sup>14</sup> If DM perforation is not central and is small enough that the integrity of the AC can be maintained (microperforation), the procedure can be completed as DALK, without converting to PKP.<sup>14</sup> In our study, the DALK procedure was completed in patients with microperforations whose AC integrity was maintained by injecting air. Of the 54 cases in the study, 23 (42.5%) were converted to PKP. In one study, the rate of PKP conversion was 37.9% in the authors' first 50 cases.<sup>10</sup>

The main advantage of DALK is that it allows the conservation of a patient's own endothelium. This results in a very low possibility of developing complications such as immunologic reaction or graft failure after DALK.<sup>14</sup> We observed no graft rejection in any patients in either of our groups. However, one limitation of our study is that the follow-up period was not very long. Another limitation of our study is that endothelial cell count and morphology were not evaluated postoperatively.

In a study evaluating and comparing 10-year outcomes of postoperative complications such as epithelial defect, suture problems, glaucoma, cataract, rejection, and graft separation, the DALK group showed significantly lower rates of postoperative complications.<sup>15</sup> Minimal endothelial cell damage may allow longer graft survival postoperatively.<sup>5</sup> In our study, patients were followed for a shorter time period (maximum 24 months) compared to the aforementioned study, and the postoperative complication rates in the DALK and PKP groups were comparable. However, these similar complication rates could be associated with the fact that the cases included in the present study were the first DALK procedures performed by the authors. Gaining more surgical experience with DALK may result in lower complication rates that are more consistent with the literature. Our results for postoperative graft transparency, visual, and refractive results were comparable to those of the previous study.

## Conclusion

In summary, our study yielded similar postoperative clinical outcomes for patients who underwent DALK and those converted from DALK to PKP. Further studies including the evaluation of endothelial cell function and longer follow-up times are needed in order to make a more robust comparison.

### Ethics

Ethics Committee Approval: Retrospective study.  
Peer-review: Externally and Internally peer-reviewed.

### Author Contributions

Concept: Yusuf Koçluk, Ayşe Burcu, Design: Yusuf Koçluk, Ayşe Burcu, Data Collection or Processing: Yusuf Koçluk, Emine Alyamaç Sukgen, Analysis or Interpretation: Yusuf Koçluk, Ayşe Burcu, Literature Search: Yusuf Koçluk, Emine Alyamaç Sukgen, Writing: Yusuf Koçluk.

Conflict of Interest: There is no conflict of interest by the authors.

Financial Disclosure: The authors declared that this study received no financial support.

### References

- Javadi MA, Motlagh BE, Jafarinasab MR, Rabbanikhah Z, Anissian A, Souri H, Yazdani S. Outcomes of penetrating keratoplasty in keratoconus. *Cornea*. 2005;24:941-946.
- Beckingsale P, Mavrikakis I, Al-Yousuf N, Mavrikakis E, Daya SM. Penetrating keratoplasty: outcomes from a corneal unit compared to national data. *Br J Ophthalmol*. 2006;90:728-731.
- Thompson RW Jr, Price MO, Bowers PJ, Price FW Jr. Long-term graft survival after penetrating keratoplasty. *Ophthalmology*. 2003;110:1396-1402.
- Patel SV, Hodge DO, Bourne WM. Corneal endothelium and postoperative outcomes 15 years after penetrating keratoplasty. *Am J Ophthalmol*. 2005;139:311-319.
- Reinhart WJ, Musch DC, Jacobs DS, Lee WB, Kaufman SC, Shtein RM. Deep anterior lamellar keratoplasty as an alternative to penetrating keratoplasty: a report by American Academy of Ophthalmology. *Ophthalmology*. 2011;118:209-218.
- Tan DT, Mehta JS. Future directions in lamellar corneal transplantation. *Cornea*. 2007;26(Suppl 1):21-28.
- Jhanji V, Beltz J, Sharma N, Graue E, Vajpayee RB. "Double bubble" deep anterior lamellar keratoplasty for management of corneal stromal pathologies. *Int Ophthalmol*. 2011;31:257-262.
- Ardjomand N, Hau S, McAlister JC, Bunce C, Galaretta D, Tuft SJ, Larkin DE. Quality of vision and graft thickness in deep anterior lamellar and penetrating corneal allografts. *Am J Ophthalmol*. 2007;143:228-235.
- Silva CA, Oliveria ES, Sena Júnior MP, Barbosa de Sousa L. Contrast sensitivity in deep anterior lamellar keratoplasty versus penetrating keratoplasty. *Clinics (Sao Paulo)*. 2007;62:705-708.
- Donoso R, Díaz C, Villavicencio P. Comparative study of keratoconus between Anwar's deep anterior lamellar keratoplasty versus converted penetrating keratoplasty. *Arch Soc Esp Oftalmol*. 2015;90:257-263.
- Fogla R, Padmanabhan P. Results of deep lamellar keratoplasty using the big-bubble technique in patients with keratoconus. *Am J Ophthalmol*. 2006;141:254-259.
- Al-Torbak AA, Al-Motowa S, Al-Assiri A, Al-Kharashi S, Al-Shahwan S, Al-Mezaine H, Teichmann K. Deep anterior lamellar keratoplasty for keratoconus. *Cornea*. 2006;25:408-412.
- Michieletto P, Balestrazzi A, Balestrazzi A, Mazzotta C, Occhipinti I, Rossi T. Factors predicting unsuccessful big bubble deep lamellar anterior keratoplasty. *Ophthalmologica*. 2006;220:379-382.
- Acar BT, Bozkurt TK, Tuğtan S, Acar S. Complications and Management of Deep Anterior Lamellar Keratoplasty. *Turk J Ophthalmol*. 2014;44:337-340.
- MacIntyre R, Chow SP, Chan E, Poon A. Long-term outcomes of deep anterior lamellar keratoplasty versus penetrating keratoplasty in Australian keratoconus patients. *Cornea*. 2014;33:6-9.



# Comparison of Biofilm Formation Capacities of Two Clinical Isolates of *Staphylococcus Epidermidis* with and without *icaA* and *icaD* Genes on Intraocular Lenses

Sertaç Argun Kıvanç\*, Merih Kıvanç\*\*, Volkan Kılıç\*\*, Gülay Güllülü\*\*\*, Ahmet Tuncer Özmen\*

\*Uludağ University Faculty of Medicine, Department of Ophthalmology, Bursa, Turkey

\*\*Anadolu University Faculty of Science, Department of Biology, Eskişehir, Turkey

\*\*\*Armedica Eye Center, Ophthalmology Clinic, Darıca, Turkey

## Abstract

**Objectives:** To compare biofilm formations of two *Staphylococcus epidermidis* (*S. epidermidis*) isolates with known biofilm formation capacities on four different intraocular lenses (IOL) that have not been studied before.

**Materials and Methods:** Two isolates obtained from ocular surfaces and identified in previous studies and stored at -86 °C in 15% glycerol in the microbiology laboratory of the Anadolu University Department of Biology were purified and used in the study. The isolates were *S. epidermidis* KA 15.8 (ICA+), a known biofilm producer isolate positive for *icaA*, *icaD* and *bap* genes, and *S. epidermidis* KA 14.5 (ICA-), known as a non-biofilm producer isolate negative for *icaA*, *icaD* and *bap* genes. The biofilm formation capacities of the 2 isolates on 4 different IOLs were compared. Two of the IOLs were acrylic (UD613 [IOL A], Turkey; SA60AT [IOL B], USA), and the other two were polymethyl methacrylate (PMMA) (B60130C [IOL C], India; B55125C [IOL D], India). Bacterial enumeration and optical density measurements were done from biofilms that formed on the IOLs. Biofilms were imaged using scanning electron microscopy.

**Results:** Mean bacterial counts on the IOLs were  $7.1 \pm 0.4 \log_{10}$  CFU/mL with the ICA+ isolate, and  $6.7 \pm 0.8 \log_{10}$  CFU/mL with the ICA- isolate; there were no statistically significant differences. Biofilm formation was lower with acrylic lenses than PMMA lenses with both isolates ( $p=0.009$  and  $p=0.013$ ). The highest biofilm production was obtained on IOL C (PMMA) ( $p<0.001$ ) and the lowest was obtained on IOL A (hydrophilic acrylic) ( $p<0.001$ ).

**Conclusion:** Bacterial counts after biofilm formation were lower on acrylic lenses, especially hydrophilic acrylic with hydrophobic properties. Further animal and *in vivo* studies are required to support the findings of this study.

**Keywords:** Biofilm, intraocular lenses, *Staphylococcus epidermidis*, hydrophobic, hydrophilic

## Introduction

Postoperative endophthalmitis is one of the most serious complications of intraocular lens (IOL) implantation after cataract surgery.<sup>1</sup> Various studies have reported postoperative endophthalmitis after cataract surgery at rates of 0.02% to 0.2%.<sup>2,3,4,5,6</sup> *Staphylococcus epidermidis* is a coagulase-negative staphylococcus (CNS) and is one of the bacteria frequently isolated in postoperative endophthalmitis. CNS are a normal part of the flora of the eye and surrounding tissues.<sup>7,8</sup> Surgical instruments or contaminated IOLs may introduce these microorganisms into the eye during surgery.<sup>9,10</sup> Biofilms formed by bacteria have also been documented on ocular materials such as contact lenses, IOLs,

glaucoma tubes, and corneal sutures.<sup>11,12</sup> Previous studies have reported that *S. epidermidis* produces biofilms on IOLs.<sup>9,13,14,15</sup> The formation of biofilms by *S. epidermidis* is dependent on microbial and environmental factors. The main microbial factor is whether the bacteria possess an *icaADBC* gene locus. Polysaccharide intercellular adhesin (PIA) is responsible for biofilm production in *S. epidermidis*.<sup>16</sup> The *ica* operon synthesizes poly-N-acetyl-beta-1-6-glucosamine, which enables the formation of PIA. The *ica* genes allow *S. epidermidis* to synthesize a polysaccharide substance called the  $\beta$ -1-6-glycosaminoglycan chain. Of the *ica* genes, *icaA* and *icaD* are more important in *S. epidermidis* biofilm production, allowing synthesis of sugar oligomers

**Address for Correspondence:** Sertaç Argun Kıvanç MD, Uludağ University Faculty of Medicine, Department of Ophthalmology, Bursa, Turkey

Phone: +90 505 923 50 04 E-mail: sakivanc@yahoo.com **Received:** 16.03.2016 **Accepted:** 11.06.2016

**This study was presented as a poster at the ESCRS 2014 London meeting.**

©Copyright 2017 by Turkish Ophthalmological Association

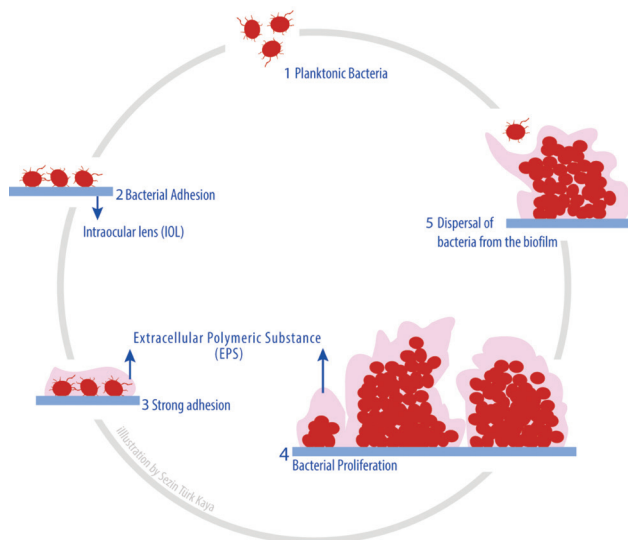
Turkish Journal of Ophthalmology, published by Galenos Publishing House.

using UDP-N-acetylglucosamine as a substrate. This is how the biofilm begins to form (Figure 1).<sup>10</sup> Biofilm formation is a complex process, and environmental factors are also important. The condition and chemical structure of the biomaterial surface, as well as properties such as hydrophilicity or hydrophobicity also play a key role.<sup>13</sup> In this study, we investigated the biofilm production characteristics of two clinical *S. epidermidis* strains, one positive and one negative for the biofilm-producing *icaA* and *icaD* genes, on two acrylic and two polymethyl methacrylate (PMMA) IOLs that have not been previously compared.

## Materials and Methods

### Bacteria

*S. epidermidis* cultures isolated from the ocular surface and purified in previous studies were stored at -86 °C in 15% glycerol. *S. epidermidis* KA 15.8 (ICA+: *icaA*, *icaD*, and *bap* (biofilm-associated protein) gene positive, high biofilm producing) and *S. epidermidis* KA 14.5 (ICA-: *icaA*, *icaD*, and *bap* gene negative)



**Figure 1.** Schematic of biofilm formation on the intraocular lens surface

isolates were obtained from the Microbiology Laboratory of the Anadolu University Faculty of Sciences, Biology Department. The cultures were revived and their purity and viability checked before being used in the study.

### Intraocular Lenses

Four different IOLs were used. Two were foldable acrylic lenses: Acriva UD613 VSY, Turkey (IOL A) and AcrySof SA60AT, Alcon, USA (IOL B). The other two were PMMA: B60130C, Biotech, India (IOL C) and B55125C, Biotech, India (IOL D). IOL A is a hydrophilic acrylic lens with hydrophobic properties and 25% water content. IOL B is a hydrophobic acrylic lens with  $\leq 2\%$  water content. IOL C is a hydrophobic PMMA lens with  $\leq 1\%$  water content and two positioning holes. IOL D is a hydrophobic PMMA lens with  $\leq 1\%$  water content but without the positioning holes found in IOL C. The features of the lenses used in this study are shown in Table 1.

### Identification of Biofilms on the Intraocular Lenses

*S. epidermidis* was cultivated in Tryptic Soy Broth (TSB) containing 0.25% glucose for 24 hours at 37 °C. The IOLs were placed in 12-well polystyrene microplates (Griener, Turkey) with one IOL per well. The *S. epidermidis* cultures were diluted 1:40 with TSB containing 0.25% glucose, then 1 mL aliquots of the diluted cultures were applied to the IOLs in the plates. All plates were incubated at 37 °C for 24 hours. One group of IOLs was incubated in bacteria-free medium. After the incubation period, the presence of biofilm on the IOLs was assessed by spectrophotometry. Before measurement, IOLs were removed from the medium and washed 3 times with phosphate-buffered saline (PBS) and placed in a sterile plate. After drying, the IOLs were stained in 1% crystal violet for 15 minutes, then washed again with PBS. Finally, 200  $\mu$ L of ethanol/acetone (80:20 vol/vol) solution was added to the IOLs to release the cells. These solutions were transferred to a multi-well plate and the optical density (OD) at 620 nm was read using a microplate reader.<sup>17</sup>

Biofilm production in the polystyrene wells was used as a control group. In each group, five trials were done in parallel.

### Enumeration of Intraocular Lens-Adherent Bacteria

IOLs cultivated as described above were washed with PBS, then each IOL was transferred to a 1.5 mL microtube containing

**Table 1. Properties of the intraocular lenses used in the study**

	IOL A	IOL B	IOL C	IOL D
Material	Hydrophilic	Hydrophobic	Hydrophobic	Hydrophobic
	Acrylic	Acrylic	PMMA	PMMA
Water content	25%	$\leq 2\%$	$\leq 1\%$	$\leq 1\%$
A constant	118.0	118.4	118.2	118.0
Haptic size	13	13	13	12.5
Optic size	6	6	6	5.5
Haptic angle	0	0	10°	5°
Other features	Monoblock, Hydrophobic properties	Monoblock	Monoblock, two positioning holes in the surface	Monoblock, No positioning holes

IOL: Intraocular lens, PMMA: Polymethyl methacrylate

1.0 mm glass beads and 1 mL PBS was added. The tubes were vortexed for 1.5 minutes at 2500 rpm in order to separate the cells from the biofilm matrix. Dilutions were prepared and bacterial enumeration was done by drop plate method. All studies were done in five parallel trials.

**Scanning Electron Microscope (SEM) Analysis**

Bacterial adhesion was examined by SEM as described by Okajima et al.<sup>13</sup> with some modifications. *S. epidermidis* isolates were incubated in TSB containing 0.25% glucose for 24 hours at 37 °C. After incubation, the IOLs were carefully washed 3 times with PBS. The IOLs were fixed for 2 hours in room temperature 0.1 M phosphate buffered (pH 7.4) 2.5% (wt/vol) glutaraldehyde, then washed 3 times in 0.5 M sodium cacodylate for 15 minutes. After this process, the lenses were rinsed in distilled water and dehydrated using an ethanol series (50%, 70%, 80%, and 95%). After incubating at each concentration in the series for 7 minutes, the lenses were incubated in pure ethanol for 15 minutes. Immediately following the ethanol series, the drying procedure was performed in the Critical Point Dryer. The IOLs were then coated with gold and analyzed using SEM.

**Statistical Analysis**

Statistical Package for the Social Sciences version 22.0 (IBM Corp., USA) software was used for all statistical analyses. T-test was used to compare bacterial counts and values obtained from the two strains with acrylic and PMMA lenses; Mann-Whitney U test was used for all other comparisons within each lens type. P values less than 0.05 were considered significant.

**Results**

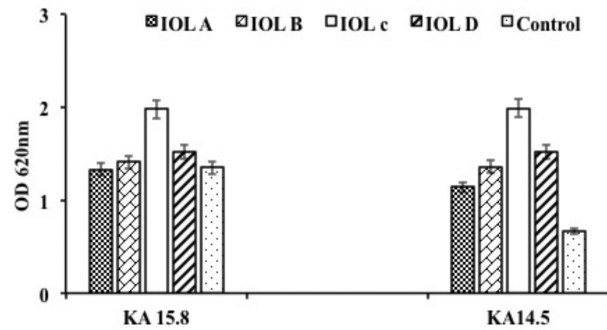
We investigated the biofilm formation of one biofilm-producing and one non-biofilm-producing strain of *S. epidermidis* on acrylic and PMMA lenses. Biofilm evaluation by crystal violet staining and spectrophotometry revealed that both isolates formed biofilms to varying degrees on the IOLs (Figure 2). The known biofilm-producing ICA+ strain had a mean bacterial count of  $7.1 \pm 0.4 \log_{10}$  CFU/mL and mean OD value of  $1.6 \pm 0.8$  across all lens types. These values were  $6.7 \pm 0.8 \log_{10}$  CFU/mL and  $1.5 \pm 0.3$  for the ICA- strain. Although the values of the ICA+ strain were higher, the difference was not statistically significant. Bacterial count correlated with OD ( $p < 0.001$ ,  $r = 0.720$ ).

Although in theory the ICA- *S. epidermidis* strain is considered a non-biofilm-producer, we found that this strain also formed

biofilms on the lenses. A comparison of the biofilm production characteristics of the ICA+ and ICA- strains on the lenses (acrylic and PMMA) is shown in Table 2. The ICA+ strain produced higher bacterial counts than ICA- strain on acrylic lenses, though the difference was not statistically significant. On PMMA lenses, both strains yielded similar results (Table 2). Statistical comparison of acrylic and PMMA lenses showed that there was less biofilm production on acrylic lenses compared to PMMA lenses in both strains ( $p = 0.009$  and  $p = 0.013$ ).

The highest biofilm production from both strains was seen in IOL C, one of the PMMA lenses. The least biofilm production occurred on IOL A, one of the acrylic lenses. Except for IOL A, bacterial counts were similar in the biofilms produced by both strains. The bacterial count on IOL A was significantly lower than on IOLs B, C, and D ( $p < 0.001$ ,  $p < 0.001$ , and  $p = 0.006$ , respectively). On IOL A, the bacterial count in the biofilm produced by the ICA- strain was significantly lower than that of the ICA+ strain ( $p = 0.003$ ). The bacterial counts and OD values of the biofilms formed on the IOLs by the ICA+ and ICA- strains are shown in Table 3.

Enumeration of bacterial colonies revealed high counts for both strains on all the lenses (Figure 3). Bacterial counts on acrylic lenses were lower compared with the other IOLs. Bacterial adhesion was observed via electron microscopy (Figure 4). In the SEM images of the biofilms produced by ICA+ *S. epidermidis*, a multi-layer structure was evident with all of the lenses. In contrast, in images from the ICA- strain, this multi-layer structure did not appear on acrylic IOLs, but was evident on PMMA IOLs.



**Figure 2.** Crystal violet staining of the biofilms produced by *S. epidermidis* KA 15.8 (biofilm producer) and *S. epidermidis* KA 14.5 (non-biofilm producer) isolates on the different intraocular lenses  
IOL: Intraocular lens, OD: Optical density

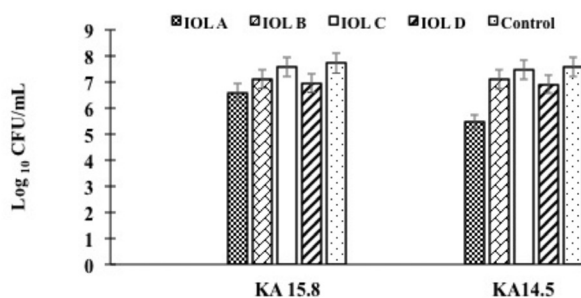
Table 2. Bacterial counts and optical density values for both isolates on the acrylic and polymethyl methacrylate lenses						
	Acrylic	PMMA		Acrylic	PMMA	
	Bacteria ( $\log_{10}$ CFU/mL)	Bacteria ( $\log_{10}$ CFU/mL)	p value	OD (620 nm)	OD (620 nm)	p value
ICA+ isolate	$6.9 \pm 0.3$	$7.3 \pm 0.3$	0.013	$1.4 \pm 0.1$	$1.8 \pm 0.2$	0.003
ICA- isolate	$6.3 \pm 0.9$	$7.2 \pm 0.3$	0.009	$1.2 \pm 0.2$	$1.8 \pm 0.3$	0.001
	0.247	0.315		0.279	0.878	

OD: Optical density, PMMA: Polymethyl methacrylate

## Discussion


Biofilm formation enhances the virulence of bacteria and is a feature that confers resistance against antimicrobial agents.<sup>12,18,19,20</sup> Biofilm production first began to draw the attention of the ophthalmology community at the beginning of the 21<sup>st</sup> century and has steadily continued to gain importance. It was first documented in ophthalmology in 2003 by Kodjikian et al.,<sup>21</sup> who obtained SEM images of *S. epidermidis* forming a biofilm on silicone IOLs with PMMA haptics and reported that strains carrying the *ica* locus produce biofilms more readily. The same authors reported in subsequent studies that bacteria type, incubation time, and IOL design influenced bacterial adhesion, but determined that the most important factor was lens material, and especially its hydrophobicity or hydrophilicity.<sup>14</sup> In the current study, we also investigated the biofilm-forming properties of both *icaA*-positive and *icaA*-negative clinical isolates on PMMA and acrylic lenses.

In our study, both the strains with and the strains without *icaA*, *icaD*, and *bap* genes formed biofilms in both lens groups. We observed from the SEM images and during bacterial enumeration that the biofilm was formed in multiple layers. The two strains yielded similar results in both spectrophotometry and bacterial enumeration. Biofilm production in the strain



**Figure 3.** Bacterial counts in the biofilms produced on the intraocular lenses  
IOL: Intraocular lens

negative for *icaA*, *icaD*, and *bap* genes may be attributable to the influence of virulence factors other than those gene loci in biofilm formation. Prasad et al.<sup>22</sup> also reported that both *icaA*-positive and *icaA*-negative strains formed biofilms on PMMA lenses, which they confirmed through bacterial enumeration. In a similar study comparing biofilm-producing and non-producing



**Figure 4.** Scanning electron microscope images of the biofilms produced by *S. epidermidis* KA 15.8 (biofilm producer) and *S. epidermidis* KA 14.5 (non-biofilm producer) isolates on the different intraocular lenses  
IOL: Intraocular lens

**Table 3. Comparison of bacterial counts and optical density values of the biofilms produced by both isolates on the 4 different intraocular lenses**

	ICA+	ICA-		ICA+	ICA-	
	Bacterial count ( $\log_{10}$ CFU/ml) (mean $\pm$ SD)		p value	OD values (620 nm) (mean $\pm$ SD)		p value
IOL A <sup>a</sup>	6.6 $\pm$ 0.28	5.5 $\pm$ 0.47	0.003	1.3 $\pm$ 0.16	1.1 $\pm$ 0.20	0.202
IOL B <sup>b</sup>	7.1 $\pm$ 0.04	7.1 $\pm$ 0.07	0.660	1.4 $\pm$ 0.09	1.4 $\pm$ 0.10	0.513
IOL C <sup>c</sup>	7.6 $\pm$ 0.01	7.5 $\pm$ 0.12	0.092	2.0 $\pm$ 0.04	2.0 $\pm$ 0.01	0.737
IOL D <sup>d</sup>	7.0 $\pm$ 0.01	6.9 $\pm$ 0.06	0.160	1.5 $\pm$ 0.03	1.5 $\pm$ 0.02	0.787
P <sup>a-b</sup>	<0.001	<0.001		0.605	0.075	
P <sup>a-c</sup>	<0.001	<0.001		<0.001	<0.001	
P <sup>a-d</sup>	0.006	<0.001		0.062	0.002	
P <sup>b-c</sup>	0.001	0.128		<0.001	<0.001	
P <sup>b-d</sup>	0.302	0.605		0.368	0.246	
P <sup>c-d</sup>	<0.001	0.012		<0.001	<0.001	

IOL: Intraocular lens, OD: Optical density, SD: Standard deviation, a: IOL A, b: IOL B, c: IOL C, d: IOL D



*S. epidermidis* strains, Okajima et al.<sup>13</sup> found that both formed biofilms intensely on acrylic lenses.

In our comparison of acrylic and PMMA lenses, we detected significantly more bacteria from both strains on the PMMA lenses. The many studies conducted on this topic have conflicting results. Okajima et al.<sup>13</sup> reported the least *S. epidermidis* biofilm formation on silicone lenses and the most on acrylic lenses, although there was no statistical difference between acrylic and PMMA lenses. Schroeder et al.<sup>23</sup> observed no differences between acrylic, silicone, and PMMA lenses. Baillif et al.<sup>24</sup> found that bacterial growth over time was less on hydrophilic acrylic lenses compared to PMMA, hydrophobic acrylic, and silicone lenses. In contrast to these studies, Fazly Bazzaz et al.<sup>25</sup> observed less biofilm formation on PMMA lenses compared to hydrophilic acrylic lenses. Many authors have suggested that biofilm production may be as dependent on microorganismal characteristics as it is on factors like lens material and surface properties.<sup>10,14</sup> The different results obtained in the abovementioned studies may stem from variations in these characteristics. Those studies were all conducted using IOLs with different properties, not with a standard IOL. Furthermore, the characteristics of the isolated microorganisms also differed. Therefore, we believe comparing the results of these studies may lead to inaccurate conclusions. In the present study, we used two different acrylic lenses from different brands and two PMMA lenses with different properties from the same brand. One of the interesting results of our study is that the lowest bacterial colonization occurred on IOL A. This hydrophilic lens had the highest water content (25%) of all the lenses used in our study and is claimed to show hydrophobic surface behavior due to the lens' unique composition. We also found a difference in bacterial count between the two different PMMA lenses of the same brand (IOL C and IOL D). IOL C has a larger surface area compared to IOL D because of its lens size, and it also has two positioning holes. We believe that these two factors make it easier for bacteria to colonize IOL C.

In cataract surgery, the IOL may become contaminated with bacteria before, during, or after implantation.<sup>23,26,27</sup> The use of cartridges in IOL placement and even the introduction of ready, pre-loaded IOL cartridges have greatly reduced the probability of contamination before and during implantation.<sup>28</sup> However, recent studies have reported that bacteria can be found on the ocular surface and the intraocular space due to influx at the end of cataract surgery performed using phacoemulsification in sterile conditions.<sup>26,29</sup> It has been demonstrated that coating lenses with the inflammatory mediator fibronectin, which is activated during surgery, facilitates bacterial adhesion.<sup>23</sup> For this reason, it is believed that solutions which alter a material's surface can increase the biocompatibility of lenses. Schroeder et al.<sup>23</sup> reported that *S. epidermidis* adherence was less on IOLs with surface modification. Nomura et al.<sup>30</sup> found that heparinization of biomaterial surfaces reduced biofilm formation. Another study demonstrated that hydrophilic coating of a silicone material reduced microorganismal colonization.<sup>31</sup> Various studies have shown reduced bacterial adhesion with lens coating and surface modifications.<sup>12,23,32</sup> We do not know whether the result we

obtained from IOL A is related to the hydrophilicity of the lens or the surface properties conferred by the molecular structure of the new material. We were unable to acquire information about the manufacturer's lens production and the exact process involved.

## Conclusion

In summary, studies have identified a host of factors that influence biofilm formation. In the present study, the lowest bacterial counts were found on a hydrophilic acrylic lens with hydrophobic properties. This research must be supported with animal and in vitro studies. Biofilm formation has been observed in all studies conducted to date, and the production of an IOL completely resistant to bacterial adhesion is not yet a possibility. Recent studies suggest that antibiotics may be effective before biofilm formation, but the efficacy of antibiotics is limited after a biofilm has developed.<sup>20</sup> Therefore, we believe that developing methods for the prevention of biofilm formation is more important than developing ways to treat patients with biofilms. Given these considerations, we believe that new strategies must be developed in lens production.

## Acknowledgements

The project was supported by Anadolu University Research Fund under the scope of project 1404F202 (Investigation of biofilm formation potential of *Staphylococcus epidermidis* on intraocular lenses).

Illustrations were drawn by Sezin Türk Kaya, Associate Professor in the Uludağ University Faculty of Fine Arts, Department of Painting.

## Ethics

Ethics Committee Approval: Animal or human subjects are not involved in this study, Informed Consent: Animal or human subjects are not involved in this study.

Peer-review: Externally peer-reviewed.

## Authorship Contributions

Surgical and Medical Practices: Merih Kıvanç, Volkan Kılıç (laboratory practices), Concept: Sertaç Argun Kıvanç, Merih Kıvanç, Gülay Güllülü, Design: Sertaç Argun Kıvanç, Merih Kıvanç, Gülay Güllülü, Ahmet Tuncer Özmen, Data Collection or Processing: Sertaç Argun Kıvanç, Merih Kıvanç, Gülay Güllülü, Volkan Kılıç, Analysis or Interpretation: Sertaç Argun Kıvanç, Merih Kıvanç, Gülay Güllülü, Ahmet Tuncer Özmen, Literature Search: Sertaç Argun Kıvanç, Merih Kıvanç, Volkan Kılıç, Writing: Sertaç Argun Kıvanç, Merih Kıvanç.

Conflict of Interest: No conflict of interest was declared by the authors.

Financial Disclosure: The project was supported by Anadolu University research fund under the scope of project 1404F202.

## References

1. Wong TY, Chee SP. The epidemiology of acute endophthalmitis after cataract surgery in an Asian population. *Ophthalmology*. 2004;111:699-705.
2. Taban M, Behrens A, Newcomb RL, Nobe MY, Saedi G, Sweet PM, McDonnell PJ. Acute endophthalmitis following cataract surgery: a systematic review of the literature. *Arch Ophthalmol*. 2005;123:613-620.

3. West ES, Behrens A, McDonnell PJ, Tielsch JM, Schein OD. The incidence of endophthalmitis after cataract surgery among the U.S. Medicare population increased between 1994 and 2001. *Ophthalmol.* 2005;112:1388-1394.
4. Miller JJ, Scott IU, Flynn HW Jr, Smiddy WE, Newton J, Miller D. Acute-onset endophthalmitis after cataract surgery (2000-2004): incidence, clinical settings, and visual acuity outcomes after treatment. *Am J Ophthalmol.* 2005;139:983-987.
5. Jabbarvand M, Hashemian H, Khodaparast M, Jouhari M, Tabatabaei A, Rezaei S. Endophthalmitis Occurring after Cataract Surgery: Outcomes of More Than 480 000 Cataract Surgeries, Epidemiologic Features, and Risk Factors. *Ophthalmology.* 2016;123:295-301.
6. Esteban J, Pe'rez-Tanoira R, Pe'rez-Jorge-Peremarch C, Go'mez-Barrena E. Bacterial Adherence to Biomaterials Used in Surgical Procedures. In: Kon K, Rai M, eds. *Microbiology for surgical infections Diagnosis, prognosis and treatment.* Elsevier UK; 2014:41-59.
7. Perkins RE, Kundsinn RB, Pratt MV, Abrahamsen I, Leibowitz HM. Bacteriology of normal and infected conjunctiva. *J Clin Microbiol.* 1975;1:147-149.
8. Speaker MG, Milch FA, Shah MK, Eisner W, Kreiswirth BN. Role of external bacterial flora in the pathogenesis of acute postoperative endophthalmitis. *Ophthalmology.* 1991;98:639-649.
9. Schauersberger J, Amon M, Aichinger D, Georgopoulos A. Bacterial adhesion to rigid and foldable posterior chamber intraocular lenses: in vitro study. *J Cataract Refract Surg.* 2003;29:361-366.
10. Ahmad S, Ashraf H, S.M. Akram SM. Adhesion of Biofilm forming *Staphylococcus epidermidis* strains on Intraocular Lenses – An Update. In: Méndez-Vilas A, ed. *The Battle Against Microbial Pathogens: Basic Science, Technological Advances and Educational Programs.* Formatex; 2015:357-363.
11. Bispo PJ, Haas W, Gilmore MS. Biofilms in infections of the eye. *Pathogens.* 2015;4:111-136.
12. Zegans ME, Becker HI, Budzik J, O'Toole G. The role of bacterial biofilms in ocular infections. *DNA Cell Biol.* 2002;21:415-420.
13. Okajima Y, Kobayakawa S, Tsuji A, Tochikubo T. Biofilm formation by *Staphylococcus epidermidis* on intraocular lens material. *Invest Ophthalmol Vis Sci.* 2006;47:2971-2975.
14. Kodjikian L, Burillon C, Roques C, Pellon G, Renaud FN, Hartmann D, Freney J. Intraocular lenses, bacterial adhesion and endophthalmitis prevention: a review. *Biomed Mater Eng.* 2004;14:395-409.
15. García-Sáenz MC, Arias-Puente A, Fresnadillo-Martinez MJ, Matilla-Rodríguez A. In vitro adhesion of *Staphylococcus epidermidis* to intraocular lenses. *J Cataract. Refract Surg.* 2000;26:1673-1679.
16. Fey PD, Olson ME. Current concepts in biofilm formation of *Staphylococcus epidermidis*. *Future Microbiol.* 2010;5:917-933.
17. Pitts B, Hamilton MA, Zelter N, Stewart PS. A microtiter-plate screening method for biofilm disinfection and removal. *J Microbiol Methods.* 2003;54:269-276.
18. Arciola CR, Baldassarri L, Montanaro L. Presence of *icaA* and *icaD* genes and slime production in a collection of staphylococcal strains from catheter-associated infections. *J Clin Microbiol.* 2001;39:2151-2156.
19. Stewart PS, Costerton JW. Antibiotic resistance of bacteria in biofilms. *Lancet.* 2001;14;358:135-138.
20. Kivanc SA, Akova Budak B, Yildiz M, Kivanc M. The effect of the linezolid and the vancomycin on biofilm production that formed on two different acrylic hydrophobic intraocular lenses. *Invest Ophthalmol Vis Sci.* 2015;56:287.
21. Kodjikian L, Burillon C, Lina G, Roques C, Pellon G, Freney J, Renaud FN. Biofilm formation on intraocular lenses by a clinical strain encoding the *ica* locus: a scanning electron microscopy study. *Invest Ophthalmol Vis Sci.* 2003;44:4382-4387.
22. Prasad S, Nayak N, Satpathy G, Nag TC, Venkatesh P, Pandey RM. Biofilm: The Haven for *Staphylococcus epidermidis* in Post-operative Endophthalmitis. *J Clin Exp Ophthalmol.* 2014;5:1-5.
23. Schroeder AC, Schmidbauer JM, Sobke A, Seitz B, Ruprecht KW, Herrmann M. Influence of fibronectin on the adherence of *Staphylococcus epidermidis* to coated and uncoated intraocular lenses. *J Cataract Refract Surg.* 2008;34:497-504.
24. Baillif S, Ecochard R, Casoli E, Freney J, Burillon C, Kodjikian L. Adherence and kinetics of biofilm formation of *Staphylococcus epidermidis* to different types of intraocular lenses under dynamic flow conditions. *J Cataract Refract Surg.* 2008;34:153-158.
25. Fazly Bazzaz BS, Jalalzadeh M, Sanati M, Zarei-Ghanavati S, Khameneh B. Biofilm Formation by *Staphylococcus epidermidis* on Foldable and Rigid Intraocular Lenses. *Jundishapur J Microbiol.* 2014;7:e10020.
26. Vafidis GC, Marsh RJ, Stacey AR. Bacterial contamination of intraocular lens surgery. *Br J Ophthalmol.* 1984;68:520-523.
27. Bausz M, Fodor E, Resch MD, Kristóf K. Bacterial contamination in the anterior chamber after povidone-iodine application and the effect of the lens implantation device. *J Cataract Refract Surg.* 2006;32:1691-1695.
28. Weston K, Nicholson R, Bunce C, Yang YE. An 8-year retrospective study of cataract surgery and postoperative endophthalmitis: injectable intraocular lenses may reduce the incidence of postoperative endophthalmitis. *Br J Ophthalmol.* 2015;99:1377-1380.
29. Kıvanç SA, Kıvanç M, Bayramlar H. Microbiology of corneal wounds after cataract surgery: biofilm formation and antibiotic resistance patterns. *J Wound Care.* 2016;25:14-19.
30. Nomura S, Lundberg F, Stollenwerk M, Nakamura K, Ljungh A. Adhesion of staphylococci to polymers with and without immobilized heparin in cerebrospinal fluid. *J Biomed Mater Res.* 1997;38:35-42.
31. Çağavi F, Akalan N, Celik H, Gür D, Guçiz B. Effect of hydrophilic coating on microorganism colonization in silicone tubing. *Acta Neurochir (Wien).* 2004;146:603-610.
32. Huang XD, Yao K, Zhang H, Huang XJ, Xu ZK. Surface modification of silicone intraocular lens by 2-methacryloyloxyethyl phosphoryl-choline binding to reduce *Staphylococcus epidermidis* adherence. *Clin Exp Ophthalmol.* 2007;35:462-467.



# Contrast Sensitivity in Microtropic and Anisometric Eyes of Successfully Treated Amblyopes

Özlem Öner\*, Sezin Akça Bayar\*\*, Sibel Oto\*\*, Onur Gökmen\*\*, Mustafa Agah Tekindal\*\*\*

\*Söke Fehime Faik Kocagöz Hospital, Ophthalmology Clinic, Aydın, Turkey

\*\*Başkent University Faculty of Medicine, Department of Ophthalmology, Ankara, Turkey

\*\*\*Başkent University Faculty of Medicine, Department of Biostatistics, Ankara, Turkey

## Abstract

**Objectives:** To assess and compare contrast sensitivity function in the previously amblyopic and non-amblyopic “normal” eyes of patients with microtropia and anisometropia who achieved 20/20 visual acuity after occlusion therapy.

**Materials and Methods:** Contrast sensitivity was tested monocularly on both eyes of 34 successfully treated microtropic and 15 anisometric subjects (visual acuity 20/20 in both eyes). Contrast sensitivity function was evaluated by CSV-1000E and age-matched nomograms were used (spatial frequencies of 3, 6, 12, and 18 cycles per degree [cpd]) for comparison.

**Results:** The mean age of subjects was  $11.2 \pm 1.3$  years in the microtropic group,  $9.8 \pm 1.7$  years in the anisometric group (7-12 years); the mean follow-up time was  $16.4 \pm 3.2$  months (12 to 92) in the microtropic group and  $27.7 \pm 1.8$  months (12-84) in the anisometric group. Statistical comparison of the microtropic amblyopic eyes versus non-microtropic eyes showed significant differences at spatial frequencies of 3, 12 and 18 cpd (3 cpd,  $t=2.8$ ,  $p=0.007$ ; 6 cpd,  $t=1.1$   $p=0.261$ ; 12 cpd,  $t=2.2$ ,  $p=0.033$ ; 18 cpd,  $t=2.2$ ,  $p=0.030$ ). When anisometric eyes were compared with non-anisometric eyes, there was a significant difference only at 12 cpd ( $t=2.1$   $p=0.049$ ). The comparison of non-amblyopic eyes versus age-matched nomograms revealed no differences at any of the spatial frequencies ( $p>0.05$  for all).

**Conclusion:** Contrast sensitivity was decreased in patients with amblyopia, especially in the microtropic group. The assessment of contrast sensitivity function may serve as a new parameter for termination of occlusion therapy.

**Keywords:** Contrast sensitivity, amblyopia, microtropia, anisometropia

## Introduction

Amblyopia, which occurs in 2-4% of the population,<sup>1,2,3</sup> is a developmental visual disorder resulting in reduced visual acuity in one eye due to strabismus, anisometropia, or deprivation in early childhood.<sup>2,3,4,5,6,7,8</sup> The main sign of amblyopia is the presence of decreased vision in one or both eyes without any identifiable ocular pathology. This reduction in visual acuity cannot be improved with refractive correction.<sup>3,5,9</sup>

Although amblyopia is usually diagnosed as a decrease in vision in a single eye, amblyopes also suffer widespread deficits in spatial function. When quantifying variations in the vision systems of amblyopes, most of these deficits can be reduced

to two basic visual parameters, visual acuity and contrast sensitivity.<sup>1,2,4,5,6,10</sup>

Contrast sensitivity function (CSF) is the ability to distinguish sinusoidal gratings within a range of spatial frequencies.<sup>4,9,10</sup> Contrast sensitivity<sup>10</sup> and spatial localization<sup>9,11</sup> are reduced in amblyopia due to developmental defects in the spatial visual processes of the nervous system. The effect of occlusion therapy (patching the stronger eye) in amblyopic patients on CSF is controversial.<sup>9</sup> Although visual acuity is a conventional evaluation used in the treatment of amblyopia and assesses the spatial resolution limits of vision, it cannot predict an individual's performance in other spatial vision tasks such as target perception or discrimination. Therefore, it

**Address for Correspondence:** Özlem Öner MD, Söke Fehime Faik Kocagöz Hospital, Ophthalmology Clinic, Aydın, Turkey  
Phone: +90 505 491 98 87 E-mail: renomelzo@hotmail.com **Received:** 05.11.2015 **Accepted:** 28.06.2016

©Copyright 2017 by Turkish Ophthalmological Association  
Turkish Journal of Ophthalmology, published by Galenos Publishing House.

has been proposed that CSF is a better tool for diagnosing and investigating spatial visual deficits.<sup>4</sup>

The aim of this study was to evaluate differences in contrast sensitivity between the amblyopic and normal eyes of patients with microtropia and anisometropia that were adequately rehabilitated with occlusion therapy.

## Materials and Methods

### Patients

Thirty-four microtropic and 15 anisometropic patients were retrospectively included in the study. The contrast sensitivity test was performed on each eye separately by one of the authors (Ö.Ö.), who was blinded to the patients' clinical condition. After informed consent forms were obtained from the patients' families, the patients underwent ophthalmic and orthoptic examinations. Inclusion criteria were: 1) age between 7 and 12 years old, because the minimum age that allowed for reliable contrast sensitivity test with the CSV-1000E (VectorVision; Dayton, OH, USA) was 7 years old; 2) the presence of congenital, stable fixation not indicating latent or manifest nystagmus on clinical examination; 3) visual acuity of 20/20 or better in the amblyopic and nonamblyopic eyes; 4) history of at least 1 year of successful occlusion therapy; 5) no history of previous surgery; and 6) correction of refractive errors prior to the contrast sensitivity test. Additional criteria for microtropic patients were: 1) deviation less than 10 prism diopters in the absence of alternation; and 2) anisometropia less than 1.5 diopters. Patients were evaluated with their best corrected eyeglass prescription. Snellen decimal charts were used to assess visual acuity.

As amblyopia treatment, patients' nonamblyopic eyes were covered with standard opaque patches. The duration of occlusion therapy was determined based on the patient's age, and the type and severity of amblyopia.

### Contrast Sensitivity Test

Contrast sensitivity data were obtained using the CSV-1000E (VectorVision, Dayton, OH, USA) contrast sensitivity instrument, which consists of a rear-illuminated translucent chart that automatically calibrates to a dim light level of 85 candela per meter squared (cd/m<sup>2</sup>). The chart consists of vertical sinewave gratings at 4 spatial frequencies (3, 6, 12, and 18 cycles per degree [cpd]), each shown on a separate row.

Each row contains 8 pairs of circular patches, one of which contains the sinewave grating while the other is blank. Each of the 4 spatial frequencies are presented at 8 different contrast levels: 3 cpd (range, 0.70-2.08 log units), 6 cpd (range, 0.91-2.29 log units), 12 cpd (range, 0.61-1.99 log units), and 18 cpd (range, 0.17-1.55 log units). The contrast level in each row decreases from left to right by 0.17 log units between patches 1 through 3, and by 0.15 log units between patches 3 through 8.

The tests were performed monocularly using best refractive correction without pupil dilation from a distance of 3 m using the CSV-1000E contrast chart test face (VectorVision). The eye not being evaluated was covered during the test. The 4 spatial frequencies (3, 6, 12, and 18 cpd) were tested using a two-

alternative mandatory selection procedure without orientation. The patients were first asked whether there was a test grating in the presented pairs of stimulus patches, and if yes, whether the grating was in the top or bottom patch of each pair. The test was repeated twice, and the last correct response for each row was accepted as the contrast threshold for the corresponding spatial frequency. These thresholds were recorded on the special diagram that accompanies the CSV-1000E. The diagram's horizontal axis represents spatial frequency (3, 6, 12, and 18 cpd), and the vertical axis represents the contrast level in logarithmic units. Marking the contrast threshold for each spatial frequency creates the contrast sensitivity curve (Figure 1).

### Statistical Analysis

Statistical analyses of logarithmic unit values were done using paired-samples t-test and Wilcoxon signed-rank test with the SPSS statistical software package (SPSS Inc., Chicago, IL, USA). P values less than 0.05 were accepted as statistically significant. For all spatial frequencies, the amblyopic eyes were compared to non-amblyopic fellow eyes and non-amblyopic eyes were compared to age-matched nomograms. Furthermore, microtropic and anisometropic eyes were compared to determine whether amblyopia type has an effect on contrast sensitivity.

## Results

Mean ages were 11.2±1.3 years for the microtropic groups and 9.8±1.7 years for the anisometropic group (range, 7-12 years for both groups). Mean follow-up time was 16.4±3.2 (range, 12-92 months) for the microtropic group and 27.7±1.8 (range, 12-84 months) for the anisometropic group. There was

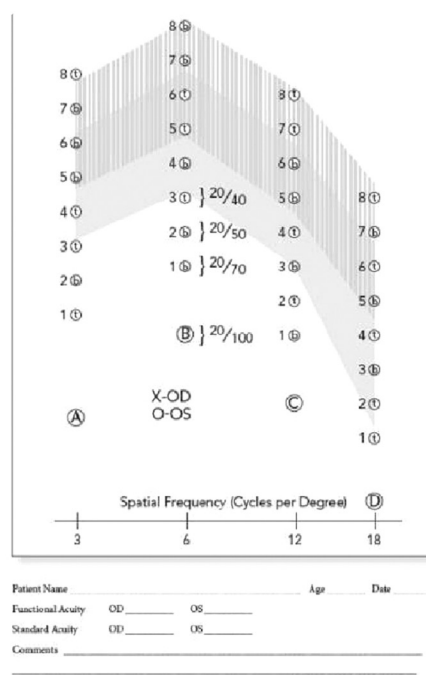
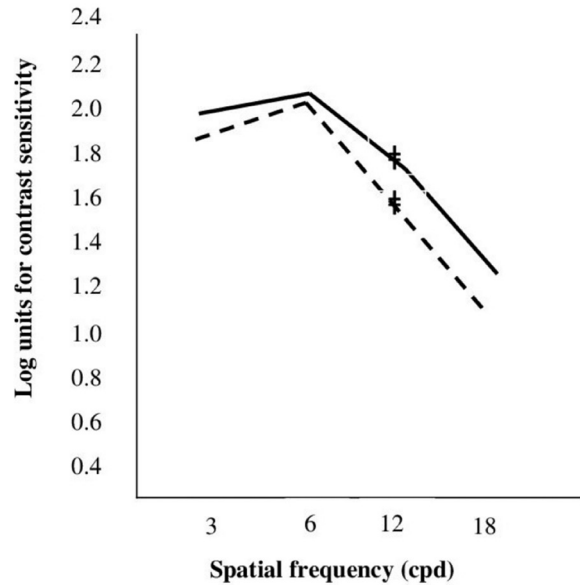


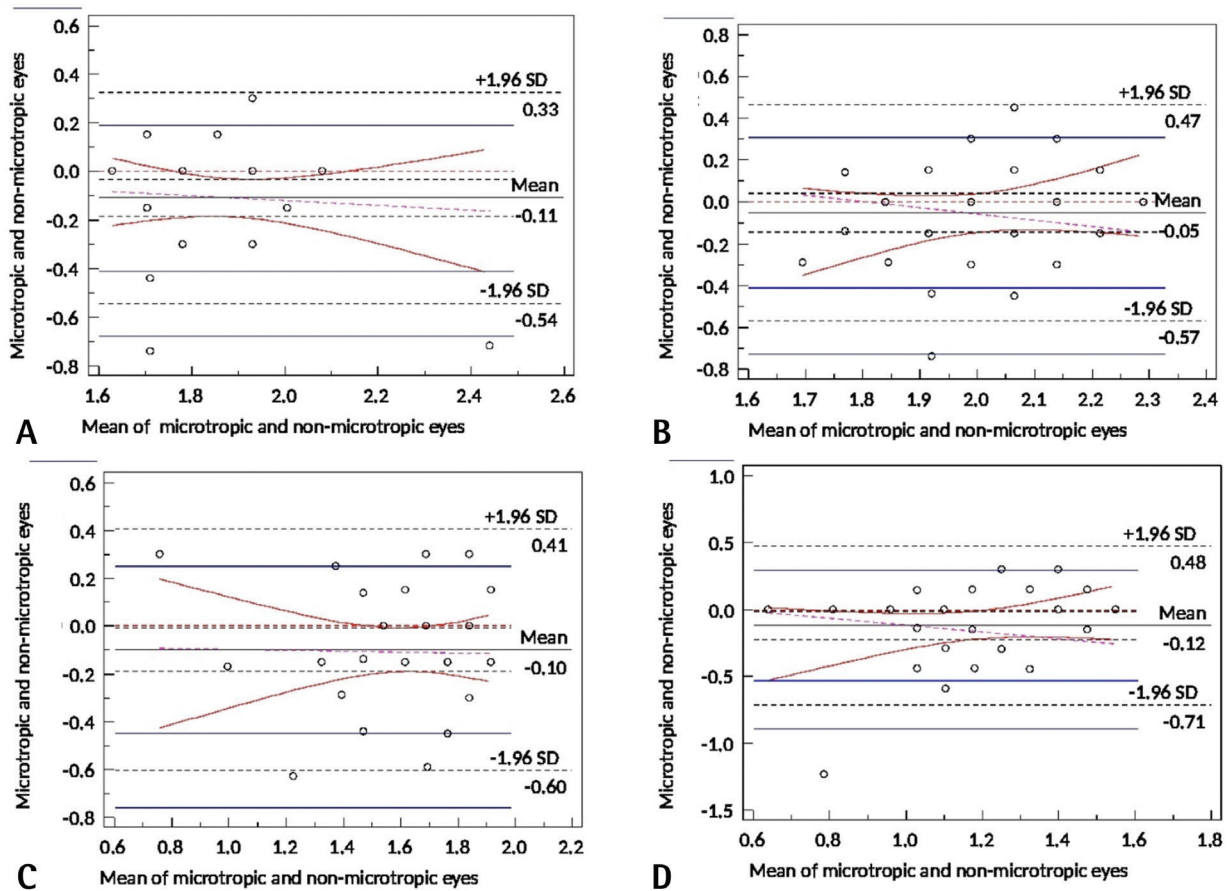
Figure 1. CSV-1000E contrast sensitivity form

a significant difference between the microtropic group and the anisometric group in duration of occlusion therapy (12.9 and 35 months, respectively,  $p=0.010$ ). The age at initiation of occlusion therapy was  $9.6 \pm 2.2$  years in the microtropic group and  $7.3 \pm 2.9$  years for the anisometric group, a statistically significant difference ( $t=2.4$ ,  $p=0.026$ ) (Table 1).

Paired-samples test of microtropic eyes and non-microtropic eyes showed significant differences at spatial frequencies of 3, 12, and 18 cpd (3 cpd:  $t=2.8$ ,  $p=0.007$ ; 12 cpd:  $t=2.2$ ,  $p=0.033$ ; 18 cpd:  $t=2.2$ ,  $p=0.030$ ) (Figure 2, Figure 3A, 3B, 3C, 3D), but there was no significant difference at 6 cpd (6 cpd,  $t=1.1$   $p=0.261$ ). In paired t-test of the anisometric and non-anisometric eyes, a slight reduction was observed at 12 cpd, while no significant differences emerged in 3, 6, or 18 cpd (3 cpd,  $t=1.8$   $p=0.089$ ; 6 cpd,  $t=1.3$   $p=0.207$ ; 18 cpd,  $t=1.2$   $p=0.219$ ) (Figure 4, Figure 5A, 5B, 5C, 5D). Comparison of non-microtropic and non-anisometric eyes with age-matched nomograms revealed no significant differences at any of the spatial frequencies (non-microtropic eyes: 3 cpd,  $p=0.075$ ; 6 cpd,  $p=0.670$ ; 12 cpd,  $p=0.846$ ; 18 cpd,  $p=0.121$ ; non-anisometric eyes: 3 cpd,  $p=0.454$ ; 6 cpd,  $p=0.116$ ; 12 cpd,  $p=0.309$ ; 18 cpd,  $p=0.196$ ).

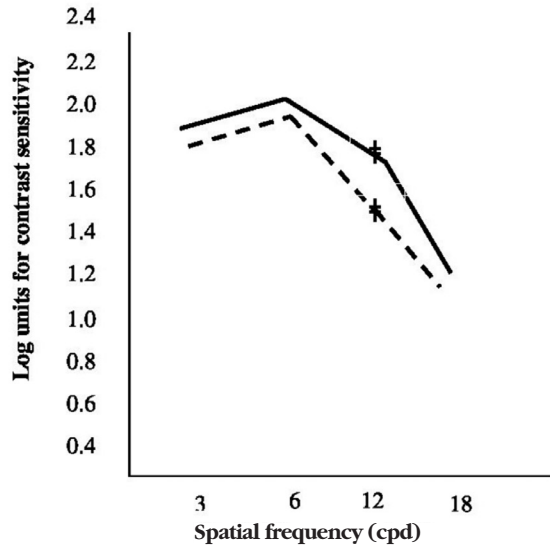


**Figure 2.** Mean contrast sensitivity function values of the microtropic eyes (dotted line) and non-microtropic eyes (solid line)



**Figure 3.** Bland-Altman plot of the microtropic group at spatial frequencies of 3 cpd (A), 6 cpd (B), 12 cpd (C), and 18 cpd (D)  
SD: Standard deviation

No statistical differences were found using paired t-test between the CSFs of the 34 microtropic patients and the 15 anisometric patients at any spatial frequency (3 cpd,  $t=1.1$



**Figure 4.** Mean contrast sensitivity function values of the anisometric eyes (dotted line) and non-anisometric eyes (solid line)

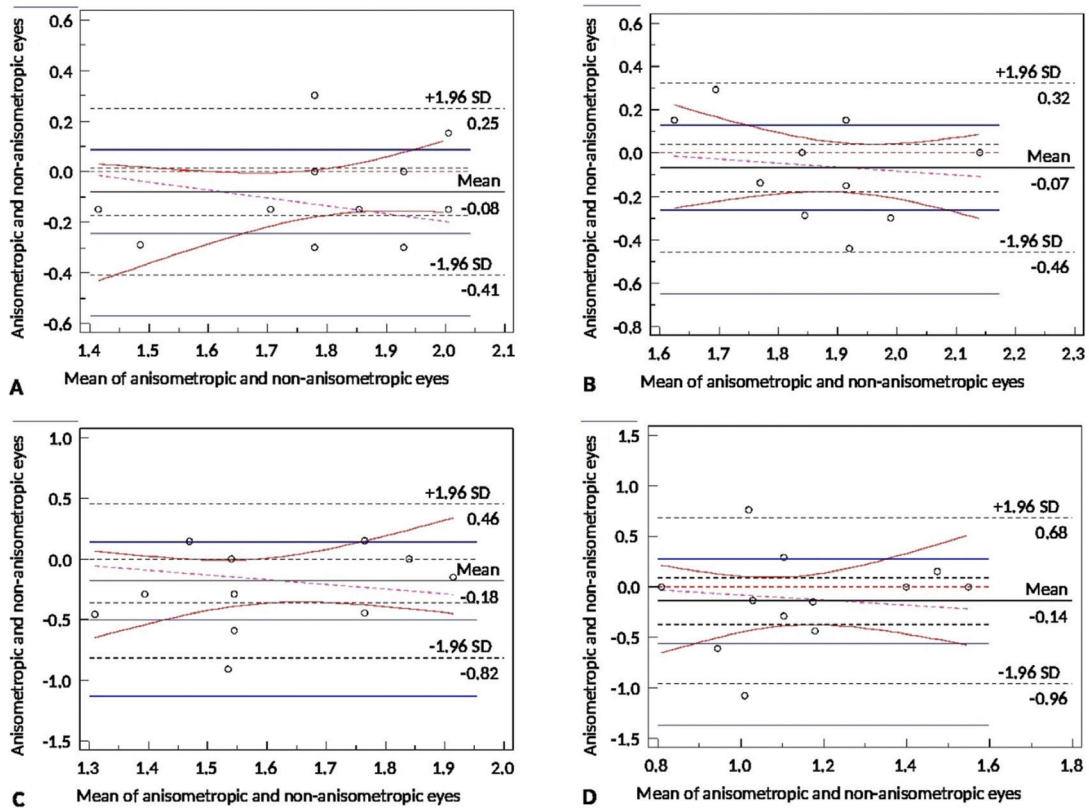
$p=0.254$ ; 6 cpd,  $t=2.0$   $p=0.057$ ; 12 cpd,  $t=1.7$   $p=0.103$ ; 18 cpd,  $t=0.8$   $p=0.418$ ) (Figure 6).

As shown in Table 2, best corrected visual acuities of the microtropic and anisometric groups were 0.33 and 0.25 logMAR, respectively, but the difference was not statistically significant ( $t=0.80$ ,  $p=0.435$ ). Both groups showed statistically significant improvements after treatment (microtropic group, 0.00 logMAR; anisometric group, -0.01 logMAR;  $t=1.46$ ,  $p=0.164$ ).

Randot values before occlusion therapy were 20.6% positive in the microtropic group and 40.0% positive in the anisometric group; after therapy, these values increased to 41.2% in the microtropic group and 66.7% in the anisometric group (Table 2).

### Discussion

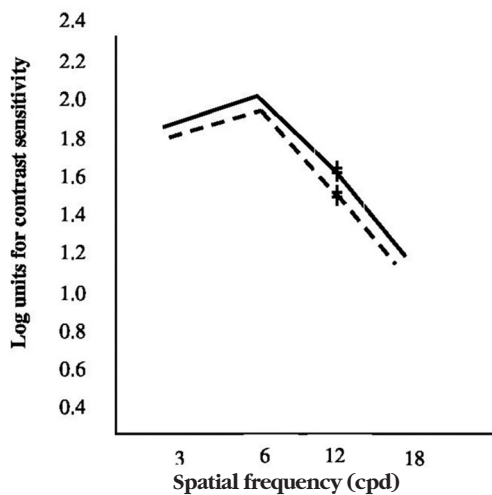
This study focused on the contrast sensitivity values of eyes that became amblyopic due to microtropia or anisometropia and were later successfully rehabilitated using occlusion therapy. We observed significant differences between microtropic and non-microtropic eyes at spatial frequencies of 3, 12, and 18 cpd. Despite regaining normal visual acuity after occlusion therapy, microtropic eyes still exhibited reduced CSF compared to non-microtropic eyes. There was also a significant difference between



**Figure 5.** Bland-Altman plot of the anisometric group at spatial frequencies of 3 cpd (A), 6 cpd (B), 12 cpd (C), and 18 cpd (D)  
SD: Standard deviation

anisometropic and non-anisometropic eyes at 12 cpd. The literature yields contradictory results on this topic. Some studies have reported that contrast sensitivity levels in amblyopia are normal or near normal at low spatial frequencies and decreased at high spatial frequencies.<sup>8,9,12,13,14</sup> However, while some of the more recent contrast sensitivity studies have detected deficits in amblyopes only at high spatial frequencies, others have demonstrated reductions at all spatial frequencies.<sup>15,16</sup> The normal contrast sensitivity curve peaks at a spatial frequency of 5-6 cpd.<sup>11</sup> In the present study, there was no statistical difference between amblyopic eyes and normal eyes at 6 cpd. These differences may be related to differences in the instruments or contrast sensitivity test methods used.

Previous studies have reported that contrast sensitivity levels are reduced at high spatial frequencies in the amblyopic eye of patients with amblyopia,<sup>17,18,19</sup> but normal or near normal at low



**Figure 6.** Mean contrast sensitivity function values of the anisometropic eyes (dotted line) and microtropic eyes (solid line)

spatial frequencies (less than 6 cpd). Chatzistefanou et al.<sup>9</sup> also found that the normal eyes of amblyopic patients had abnormal CSF, regardless of whether they had undergone occlusion therapy. In contrast, Zele et al.<sup>20</sup> found that the normal eyes of amblyopes had normal values at all spatial frequencies. Moreover, Maeberra et al.<sup>8</sup> reported that contrast sensitivity was reduced in amblyopic eyes, while normal eyes were generally normal. Similar to Zele et al.<sup>20</sup>, in the present study we detected no significant differences in CSF throughout the spatial frequency range when the normal eyes of microtropic and anisometropic patients were compared with age-matched nomograms.

There are a few theories which may explain the differences in contrast sensitivity values we observed between the anisometropic and non-anisometropic eyes and between the microtropic and non-microtropic eyes in this study. Firstly, the age at diagnosis and initiation of treatment was low among the anisometropic amblyopic children in this study. In addition, the duration of treatment was longer in the anisometropic group. Lai et al.<sup>21</sup> reported that the vision system has greater plasticity in early childhood, which may be related to the difference in our results. Secondly, it has been suggested in the literature that in anisometropia, visual acuity is affected more than contrast sensitivity.<sup>14</sup> In their most recent study, Tang et al.<sup>22</sup> proposed that anisometropic amblyopes may have intact integration of motion information provided by moving component gratings. They attributed the apparent deficiencies in contrast sensitivity for moving plaids in anisometropic amblyopes almost entirely to these gratings, which are low-level processing deficits. Therefore, the difference observed in our study may be related to amblyopia type.

### Conclusion

In summary, contrast sensitivity assessment may provide valuable information regarding visual function in amblyopic patients, could guide occlusion therapy, and may be a new parameter in the termination of occlusion therapy.

**Table 1. Statistical comparison of age, follow-up time, age at start of treatment, and duration of occlusion therapy in anisometropic and microtropic amblyopes**

	Microtropic group (n=34)	Anisometropic group (n=15)	Statistical difference between groups (p)
Age (years)	11.2±1.3	9.8±1.7	p=0.007
Follow-up time (months)	16.4±3.2	27.7±1.8	p=0.092
Occlusion therapy duration (months)	12.9±3.1	35.0±28.2	p=0.010
Age at start of treatment (years)	9.6±2.2	7.3±2.9	p=0.026

**Table 2. Statistical comparison of best corrected visual acuity and Randot values pre- and post-treatment in anisometropic and microtropic amblyopes**

	Microtropic group	Anisometropic group	Statistical difference between groups (p)
BCVA (pre)	0.33 logMAR	0.25 logMAR	p=0.435, t=0.80
Randot (pre)	20.6% positive	40.0% positive	p=0.164, t=1.46
Randot (post)	41.2% positive	66.7% positive	p=0.019, t=2.64

BCVA: Best corrected visual acuity

### Ethics

Ethics Committee Approval: Başkent University, Ankara, KA11/160.

Peer-review: Externally peer-reviewed.

### Authorship Contributions

Surgical and Medical Practices: Sibel Oto, Sezin Akça Bayar, Concept: Sibel Oto, Sezin Akça Bayar, Design: Sibel Oto, Sezin Akça Bayar, Data Collection or Processing: Sezin Akça Bayar, Onur Gökmen, Özlem Öner, Analysis or Interpretation: Mustafa Ağah Tekindal, Literature Search: Özlem Öner, Writing: Özlem Öner.

Conflict of Interest: There is no conflict of interest by the authors.

Financial Disclosure: The authors declared that this study received no financial support.

### References

1. Astle AT, Webb BS, McGraw PV. Spatial frequency discrimination learning in normal and developmentally impaired human vision. *Vision Res.* 2010;50:2445-2454.
2. Huang CB, Lu ZL, Zhou Y. Mechanisms underlying perceptual learning of contrast detection in adults with anisometropic amblyopia. *J Vis.* 2009;9:24.
3. Li X, Dumoulin SO, Mansouri B, Hess RF. Cortical deficits in human amblyopia: their regional distribution and their relationship to the contrast detection deficit. *Invest Ophthalmol Vis Sci.* 2007;48:1575-1591.
4. Huang C, Tao L, Zhou Y, Lu ZL. Treated amblyopes remain deficient in spatial vision: a contrast sensitivity and external noise study. *Vision Res.* 2007;47:22-34.
5. Chung ST, Lib RW, Levi DM. Identification of contrast-defined letters benefits from perceptual learning in adults with amblyopia. *Vision Res.* 2006;46:3853-3861.
6. Baker DH, Meese TS, Mansouri B, Hess RF. Binocular summation of contrast remains intact in strabismic amblyopia. *Invest Ophthalmol Vis Sci.* 2007;48:5332-5338.
7. Hood AS, Morrison JD. The dependence of binocular contrast sensitivities on binocular single vision in normal and amblyopic human subjects. *J Physiol.* 2002;540:607-622.
8. Maebara G, Thompson B, Mansouri B, Farivar R, Hess RF. The perceptual consequences of interocular suppression in amblyopia. *Invest Ophthalmol Vis Sci.* 2011;52:9011-9017.
9. Chatzistefanou KI, Theodossiadis GP, Damanakis AG, Ladas ID, Moschos MN, Chimonidou E. Contrast sensitivity in amblyopia: The fellow eye of untreated and successfully treated amblyopes. *JAAPOS.* 2005;5:468-474.
10. Baker DH, Meese TS, Hess RF. Contrast masking in strabismic amblyopia: attenuation, noise, interocular suppression and binocular summation. *Vision Res.* 2008;48:1625-1640.
11. Dorn L, Doresic JP. Contrast sensitivity in strabismic functional test. *Acta Clin Croat.* 2008;47(Suppl 1):15-19.
12. Bradley A, Freeman RD. Contrast sensitivity in anisometropic amblyopia. *Invest Ophthalmol Vis Sci.* 1981;21:467-476.
13. Hess RF, Howell ER. The threshold contrast sensitivity function in strabismic amblyopia: evidence for two type classification. *Vision Res.* 1977;17:1049-1055.
14. Levi DM, Harwerth RS. Spatio-temporal interactions in anisometropic and strabismic amblyopia. *Invest Ophthalmol Vis Sci.* 1977;16:90-95.
15. Harwerth RS, Smith EL 3, Boltz RL, Crawford ML, von Noorden GK. Behavioral studies on the effect of abnormal early visual experience in monkeys: spatial modulation sensitivity. *Vision Res.* 1983;23:1501-1510.
16. Harwerth RS, Crawford ML, Smith EL 3, Boltz RL. Behavioral studies of stimulus deprivation amblyopia in monkeys. *Vision Res.* 1981;21:779-789.
17. Koskela PU. Contrast sensitivity in amblyopia, II: Changes during pleoptic treatment. *Acta Ophthalmol (Copenhagen).* 1986;64:563-569.
18. Leguire LE, Rogers GL, Bremer DL. Amblyopia: the normal eye is not normal. *J Pediatr Ophthalmol Strabismus.* 1990;27:32-38.
19. Wali N, Leguire LE, Rogers GL, Bremer DL. CSF interocular interactions in childhood amblyopia. *Optom Vis Sci.* 1991;68:81-87.
20. Zele AJ, Pokorny J, Lee DY, Ireland D. Anisometropic amblyopia: spatial contrast sensitivity deficits in inferred magnocellular and parvocellular vision. *Invest Ophthalmol Vis Sci.* 2007;48:3622-3631.
21. Lai XJ, Alexander J, He M, Yang Z, Suttle C. Visual functions and interocular interactions in anisometropic children with and without amblyopia. *Invest Ophthalmol Vis Sci.* 2011;52:6849-6859.
22. Tang Y, Chen L, Liu Z, Liu C, Zhou Y. Low-level processing deficit underlying poor contrast sensitivity for moving plaids in anisometropic amblyopia. *Vis Neurosci.* 2012;29:315-323.





## Factors Affecting Contrast Sensitivity in Healthy Individuals: A Pilot Study

Arzu Seyhan Karatepe\*, Süheyla Köse\*\*, Sait Eğrilmez\*\*\*

\*Kayseri Training and Research Hospital, Ophthalmology Clinic, Kayseri, Turkey

\*\*Independent Practitioner, İzmir, Turkey

\*\*\*Ege University Faculty of Medicine, Department of Ophthalmology, İzmir, Turkey

### Abstract

**Objectives:** To determine the demographic and ocular features affecting contrast sensitivity levels in healthy individuals.

**Materials and Methods:** Seventy-four eyes of 37 subjects (7-65 years old) with refractive errors less than 1.0 diopter, no history of ocular surgery, and 20/20 visual acuity were included in the study. The participants were divided by age into three groups: group 1, 7-19 years, n=11; group 2, 20-49 years, n=15; and group 3, 50-65 years, n=11. All subjects underwent anterior and posterior segment evaluation, intraocular pressure measurements, refraction measurements, and clinical evaluation for strabismus. Contrast static test was performed using Metrovision MonPack 3 vision monitor system after measuring pupil diameter. Photopic and mesopic measurements were taken sequentially from right eyes, left eyes, and both eyes together.

**Results:** Contrast sensitivity at intermediate and high spatial frequencies was lower with increasing age. Binocular measurements were better than monocular, and mesopic measurements were better than photopic measurements at all spatial frequencies. Contrast sensitivity at higher spatial frequency was lower with hyperopic refraction values.

**Conclusion:** Increasing age, small pupil diameter, hyperopia, and photopic conditions were associated with lower contrast sensitivity in healthy individuals. Binocular contrast sensitivity measurements were better than monocular contrast sensitivity measurements in all conditions and spatial frequencies.

**Keywords:** Contrast sensitivity, age, visual function, photopic

### Introduction

Contrast sensitivity measurement is one of the primary methods currently used to evaluate visual function. The eye is able to perceive an object by comparing differences in light level between the target and the background.

Contrast sensitivity is defined as the ability to detect the lowest luminance difference between an object and the background.<sup>1</sup> Standard visual acuity measurement is done with high contrast conditions. This does not provide any information about visual performance in many of the various activities we perform in our daily lives, such as driving at night or reading in low light, and a patient's vision cannot be fully assessed by evaluating visual acuity alone.<sup>2</sup>

Contrast sensitivity is one of the main requisites for good vision and, unlike visual acuity, can be affected by many factors. The increasing application of multifocal contact lenses and intraocular lenses (IOLs) has created a new patient group whose visual quality is affected independently of visual acuity. Visual acuity measurement is not an adequate assessment of visual function in these patients, which increases the need for contrast sensitivity and glare testing. However, in order to discuss pathological levels, we first need to determine contrast sensitivity levels in normal individuals and understand the daily living and environmental conditions affecting these levels.

The aim of this study, performed in the Electrophysiology division of the Ege University Faculty of Medicine, Department of Ophthalmology, was to determine standard values for photopic

**Address for Correspondence:** Arzu Seyhan Karatepe MD, Kayseri Training and Research Hospital, Ophthalmology Clinic, Kayseri, Turkey  
Phone: +90 505 925 55 65 E-mail: arzuskaratepe@hotmail.com **Received:** 16.11.2015 **Accepted:** 11.06.2016

©Copyright 2017 by Turkish Ophthalmological Association  
Turkish Journal of Ophthalmology, published by Galenos Publishing House.

and mesopic contrast sensitivity at different spatial frequencies in specific age groups. We also evaluated factors which may affect contrast sensitivity such as age, pupil diameter, and lighting conditions.

**Materials and Methods**

Seventy-four eyes of 37 subjects between 7-65 years of age who attended the Ege University Faculty of Medicine, Department of Ophthalmology for routine check-up were included in the study. All subjects underwent a complete ophthalmologic examination including slit-lamp and 90-diometry (D) lens anterior and posterior segment examination, intraocular pressure measurement by applanation tonometry, refraction measurement by autorefractometry, keratometric measurement, and strabismus examination using Hirschberg and cover tests. Prior to contrast sensitivity testing, pupil diameter was measured in the same lighting conditions. Subjects with no ocular pathology, uncorrected 20/20 vision, autorefractometer values less than 1.0 D, and no history of ocular surgery were included.

Contrast sensitivity test was performed using the Metrovision MonPack 3 Vision monitor system. Contrast sensitivity testing was done first in photopic, then in mesopic conditions. At each light level, monocular tests of the right and left eyes (in that order) were followed by binocular tests. During the test, the parameters of the sinusoidal bar such as lamination, contrast, and spatial frequency are adjusted. Each black and white bar was initially presented at low contrast, and the contrast was automatically increased by the instrument. The point at which the subject first perceived the stripes was recorded. The instrument obtained data at spatial frequencies of 0.5, 1.5, 3.0, 6.0, 12.0, and 24.0 cycles/degree (cpd) and at lamination levels of 0-30 decibels (dB).

Prior to contrast sensitivity testing, pupil diameter was measured at the same light level. For comparisons of monocular and binocular function, measurements from the subjects' dominant eye (right for all subjects) was included in the analysis; measurements taken from subjects' other eyes (left) were not included in calculations of monocular values. In the contrast sensitivity test, 0.5-1.5 cpd is defined as low, 3.0-6.0 cpd as intermediate, and 12.0-24.0 cpd as high spatial frequency. The subjects were divided by age into three groups in order to compare contrast sensitivity curves: group 1 included 11 subjects 7-19 years old; group 2 included 15 subjects 20-49 years old; and group 3 included 11 subjects 50-65 years old.

**Statistical Analysis**

Numerical relationships between age, refractive error, pupil diameter, and contrast sensitivity levels were analyzed by Pearson's correlation test; paired comparisons such as contrast sensitivity in light/dark conditions and monocular/binocular were analyzed by dependent-samples t-test.

**Results**

Mean ages of the groups were 11.45±3.55 years for group 1, 35.66±7.62 years for group 2, and 57.09±4.48 years for group 3. Changes between the photopic/mesopic and monocular/

binocular contrast sensitivity curves in the age groups are shown in Figure 1 and Figure 2.

Statistical analysis revealed no differences between the age groups in contrast sensitivity in photopic conditions, but in mesopic conditions, contrast sensitivity at high spatial frequencies decreased with increasing age (Table 1, Figure 3). Furthermore, with increasing age, pupil diameter measured in both mesopic and photopic conditions was smaller (p<0.01) and refraction tended toward hypermetropia at low refractive errors (p<0.01).

In photopic conditions, pupil diameter had no effect on contrast sensitivity values. In mesopic conditions, contrast sensitivity values at high spatial frequencies increased in association with larger pupil diameter (Table 2, Figure 4). Evaluation of the association between contrast sensitivity and spherical equivalent at low refractive errors revealed that contrast sensitivity was decreased at intermediate and especially at high spatial frequencies as refraction became hypermetropic (p<0.01). In mesopic conditions, pupil diameter was smaller in hypermetropes (p<0.05).

In all age groups and at all spatial frequencies, binocular contrast sensitivity values were higher than monocular values (Figure 5), and contrast sensitivity was better in mesopic than photopic conditions (Figure 6). Contrast sensitivity was independent of age and pupil size in photopic conditions.

**Discussion**

In recent years, it has become increasingly recognized that visual acuity alone is an inadequate assessment of an individual's visual quality, and that additional evaluation methods such

**Table 1. Association between age and contrast sensitivity at high spatial frequencies in scotopic conditions**

n=37	12 cpd	24 cpd
Right eye	p=0.006 r=-0.445**	p=0.036 r=-0.347*
Left eye	p=0.002 r=-0.489**	p=0.001 r=-0.529**
Bilateral	p=0.032 r=-0.354*	p=0.011 r=-0.413*

\*Statistical significance level of 0.05  
\*\*Statistical significance level of 0.01

**Table 2. Association between pupil size and contrast sensitivity at high spatial frequencies in scotopic conditions**

n=37	12 cpd	24 cpd
Right eye	p=0.029 r=-0.359**	p=0.009 r=-0.422*
Left eye	p=0.027 r=-0.364**	p=0.005 r=-0.451**
Bilateral	p=0.017 r=-0.390*	p=0.002 r=-0.483*

\*Statistical significance level of 0.05  
\*\*Statistical significance level of 0.01

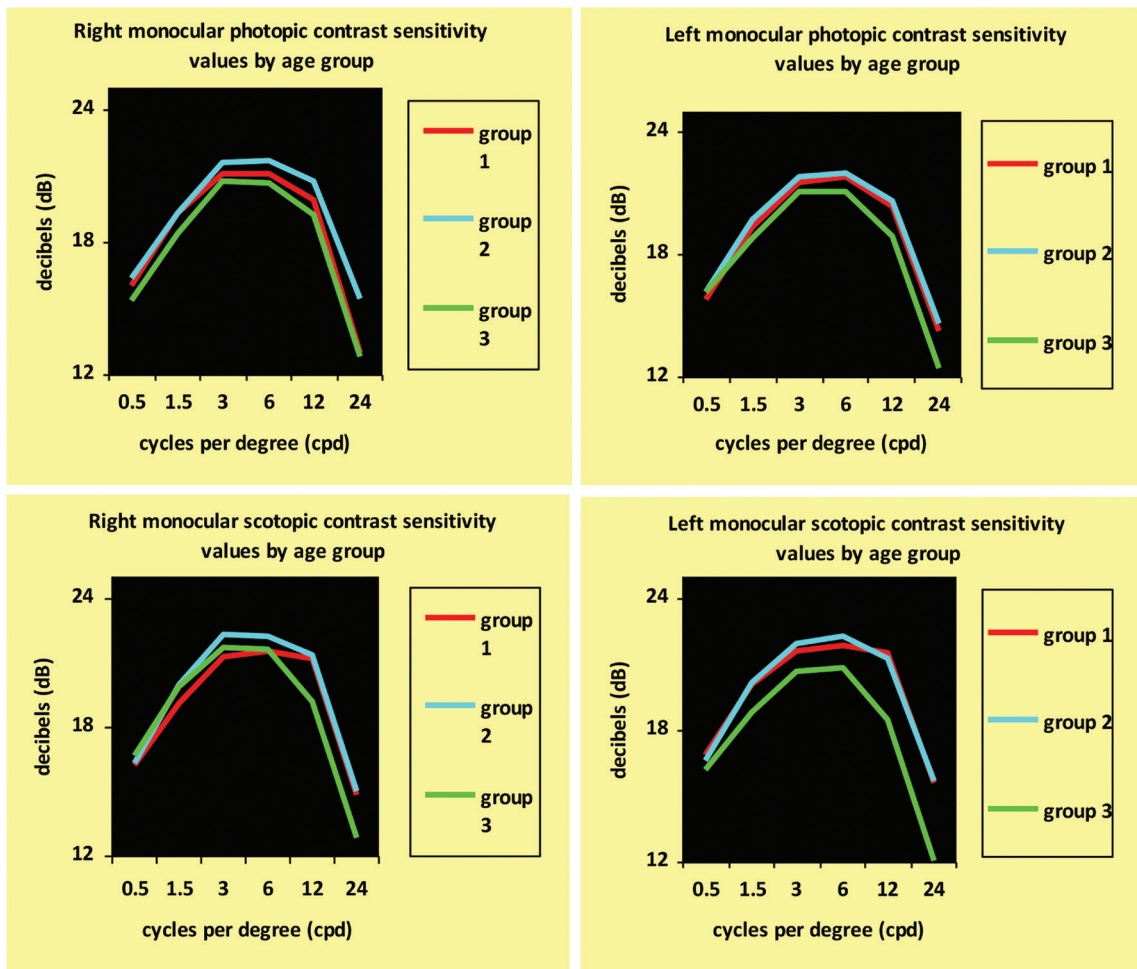


Figure 1. Changes in monocular contrast sensitivity by age group

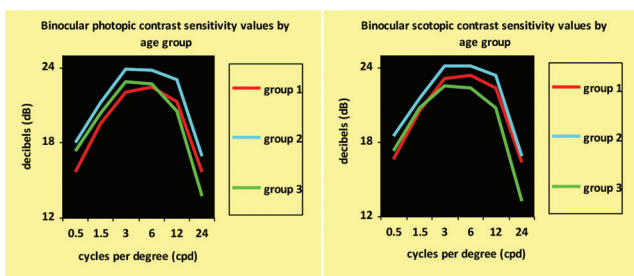


Figure 2. Binocular contrast sensitivity curves by age group

as contrast sensitivity test are needed.<sup>3</sup> Especially with newly developed multifocal intraocular lenses and other refractive procedures, the success of the procedure depends on the contrast sensitivity test results, even if the visual acuity is very good.<sup>4,5,6,7</sup> Therefore, contrast sensitivity testing is becoming more common in our routine practice.

Histopathologic studies have shown that the macular pigments, photoreceptors, and neural paths are affected in the aging retina.<sup>8,9</sup> In these studies, it was particularly noted that there is a much larger decrease in the number of rods compared

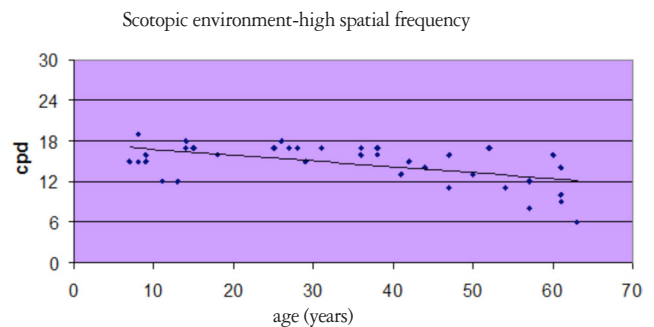
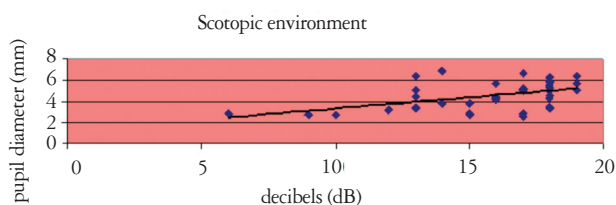
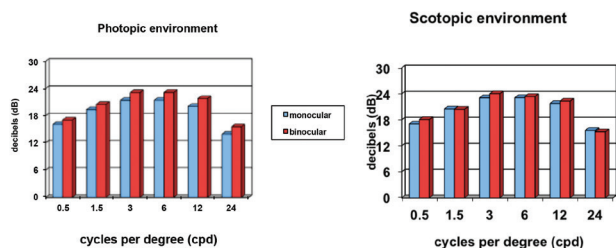


Figure 3. Changes in scotopic contrast sensitivity with age

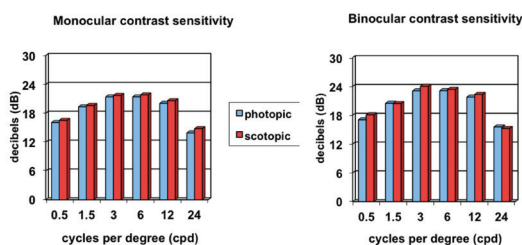
to that of cones.<sup>8,9</sup> These changes explain the decreases in light sensitivity, contrast sensitivity, and visual acuity as well as prolonged dark adaptation that affect individuals over the age of 50.<sup>8,9</sup> Some studies have shown that contrast sensitivity does not decrease appreciably with advancing age.<sup>10,11</sup> However, most studies have reported declines in both photopic and scotopic contrast sensitivity with aging.<sup>12</sup> It has been proposed that age-



**Figure 4.** Effect of pupil diameter on scotopic contrast sensitivity values



**Figure 5.** Effect of monocular and binocular measurement on contrast sensitivity values



**Figure 6.** Effect of lighting conditions on contrast sensitivity

related lens sclerosis may play a role in this decrease.<sup>13,14,15</sup> One of the most comprehensive of these studies is that of Owsley et al.,<sup>16</sup> which included 91 subjects. They observed decreased contrast sensitivity at high spatial frequencies but found no effect at lower frequencies in subjects over 40 years old; they also noted that small children had high contrast sensitivity at low frequencies, but low sensitivity at intermediate and high frequencies. In a study by Zanglonghi<sup>17</sup> including 133 eyes, no differences in contrast sensitivity at low spatial frequencies (0.7, 1.4, 2.7 cpd) were observed between age groups spanning a range of 13-82 years old, whereas the 21-30 age group had the highest contrast sensitivity values at high frequencies (5.5, 11, 22 cpd). Arden<sup>18</sup> and Bradley and Freeman<sup>19</sup> also showed that the contrast sensitivity levels at low and intermediate frequencies were lower in subjects under 13 years old when compared with the other age groups. In the present study, we found that contrast sensitivity decreased in scotopic conditions and at high spatial frequencies with advancing age, but we found no effect of age on contrast sensitivity in photopic conditions. The contrast sensitivity values of the <20 group were comparable to those of the 20-49 year age group.

Contrast sensitivity is also influenced by pupil size. Changes in pupil size negatively affect contrast sensitivity at both ends

of the spectrum. It has been suggested that contrast sensitivity is reduced by diffraction with a miotic pupil, and possibly by spherical aberrations with a dilated pupil.<sup>20</sup> In our study, we observed no association between pupil diameter and contrast sensitivity other than an increase in contrast sensitivity values at intermediate and high frequencies with pupil dilation in scotopic conditions. Aging is known to bring about yellowing of the lens, as well as reduction in photoreceptor numbers, smaller pupil, and less dilation in low light conditions.<sup>12</sup> These may have been factors contributing to the reduction in scotopic contrast sensitivity at high frequencies we observed in the older age group in our study.

It is thought that the decrease in contrast sensitivity as refraction moves toward hypermetropia may explain why hypermetropes are more prone to amblyopia than myopes. Controlled studies may elucidate the relationship between contrast sensitivity and amblyopia.

Contrast sensitivity measurements are also influenced by the ambient light level in which the test is performed. It has been reported that contrast sensitivity that is high in photopic conditions decreases in scotopic conditions.<sup>1</sup> In our study, however, contrast sensitivity measurements were higher in scotopic than photopic conditions. This may be due to an improved ability to distinguish an object from the background as the ambient light darkens. If the background is white and the test object is a dark color, illumination of the background will certainly increase the observer's ability to recognize the object; however, in this situation, the scotopic environment refers to the ambient light, independent of the background. Increasing the ambient light may decrease contrast sensitivity by creating a counter effect to the illumination of the background.

Our study aimed to evaluate a wide range of ages with the instrument we used, and to compare measurements from school-age children with those of other age groups. For children in particular, explaining the test in detail and extending the duration of the test provided higher test reliability; however, this resulted in there being a limited number of subjects in this age group.

### Conclusion

With the astonishingly rapid progression of both medical and surgical therapies, the comparison of newly developed methods with gold standard is inadequate, and contrast sensitivity testing gains importance. It is crucial to create databases of contrast sensitivity values standardized according age, refraction, and pupil diameter. The sample size of our study is insufficient to create such a database. At this stage, we consider this a pilot study which will shed light on future research.

### Ethics

Ethics Committee Approval: The study was designed as an observational research and performed in accordance with the Declaration of Helsinki. The study was designed in 2008 without applied to ethical committee, Informed Consent: Informed consent was taken from the patients.

### Authorship Contributions

Concept: Süheyla Köse, Design: Süheyla Köse, Data Collection or Processing: Arzu Seyhan Karatepe, Analysis or Interpretation: Sait Eğrilmez, Literature Search: Arzu Seyhan Karatepe, Writing: Arzu Seyhan Karatepe.

Conflict of Interest: No conflict of interest was declared by the authors.

Financial Disclosure: The authors declared that this study received no financial support.

### References

1. Jindra LF, Zemon V. Contrast sensitivity testing: a more complete assesment of vision. *J Cataract Refract Surg.* 1989;15:141-148.
2. Wood JM, Owens DA. Standard measures of visual acuity do not predict drivers' recognition performance under day or night conditions. *Optom Vis Sci.* 2005;82:698-705.
3. Amesbury EC, Shallhorn SC. Contrast sensitivity and limits vision. *Int Ophthalmol Clin.* 2003;43:31-42.
4. Tang W, Zhuang S, Liu G. Comparison of visual function after multifocal and accommodative IOL implantation. *Eye Sci.* 2014;29:95-99.
5. Vilupuru S, Lin L, Pepose JS. Comparison of contrast sensitivity an through focus in small aperture inlay, accommodating intraocular lens, or multifocal intraocular lens subjects. *Am J Ophthalmol.* 2015;160:150-162.
6. Çetin B, Arıcı MK, Özeç AV, Toker Mİ, Erdoğan H, Topalkara A. Zaracom ultraflex veya F260 göz içi lens takılan hastalarda kontrast duyarlılığın değerlendirilmesi ve karşılaştırılması. *Turk J Ophthalmol.* 2011;41:230-235.
7. Taşkın O, Özbek Z. Miyop ve astigmatizma nedeniyle LASIK ve LASEK uygulanan hastalarda kontrast duyarlılık sonuçlarının değerlendirilmesi. *Turk J Ophthalmol.* 2014;44:436-439.
8. Curcio CA. Photoreceptor topography in ageing and age-related maculopathy. *Eye (Lond).* 2001;15:376-383.
9. Curcio CA, Medeiros NE, Millican CL. Photoreceptor loss in age-related macular degeneration. *Invest Ophthalmol Vis Sci.* 1996;37:1236-1249.
10. Packer M, Ginsburg AP. Contrast sensitivity and aging. *Ophthalmology.* 2007;114:1589-1590.
11. Li J, Zhao JL. Contrast visual acuity in adults with normal visual acuity. *Zhonghua Yan Ke Za Zhi.* 2012;48:403-408.
12. Weale RA. Aging and vision. *Vision Res.* 1986;26:1507-1512.
13. Lampert P, Hopcroft M, Lempert Y. Evaluation of posterior subcapsular cataracts. with spatial contrast acuity. *Ophthalmology.* 1987;2:14-18.
14. Stifter E, Sacu S, Weghaupt H. Functional vision with cataracts of different morphologies: comparative study. *J Cataract Refract Surg.* 2004;30:1883-1891.
15. Willimson TH, Strong NP, Sparrow J, Aggarwl RK, Harrad R. Contrast sensitivity nd glare in cataract using the Pelli-Robson chart. *Br J Ophthalmol.* 1992;76:719-722.
16. Owsley E, Sekuler R, Siemsen D. Contrast sensitivity throughout adulthood. *Vision Res.* 1983;23:689-699.
17. Zanlonghi X. Sensibilite au contraste, Etude comparative des appareillages actuels. *Coup d'Oeil.* 1991;32:70-74.
18. Arden GB. The importance of measuring contrast sensitivity in the cases of visual disturbance. *Br J Ophtalmol.* 1978;62:198-209.
19. Bradley A, Freeman RD. Contrast sensitivity in children. *Vision Res.* 1982;22:953-959.
20. Strang NC, Atchison DA, Woods RL. Effects of defocus and pupil size on human contrast sensitivity. *Ophthalmic Physiol Opt.* 1999;19:415-426.



# The Relationship between Serum Carbonic Anhydrase I-II Autoantibody Levels and Diabetic Retinopathy in Type 1 Diabetes Patients

Adem Türk\*, Süleyman Mollamehmetoğlu\*\*, Ahmet Alver\*\*\*, Ahmet Menteşe\*\*\*, İrfan Nuhoğlu\*\*\*\*, Cihangir Erem\*\*\*\*, Halil İbrahim İmamoğlu\*

\*Karadeniz Technical University Faculty of Medicine, Department of Ophthalmology, Trabzon, Turkey

\*\*Of State Hospital, Ophthalmology Clinic, Trabzon, Turkey

\*\*\*Karadeniz Technical University Faculty of Medicine, Department of Biochemistry, Trabzon, Turkey

\*\*\*\*Karadeniz Technical University Faculty of Medicine, Department of Internal Medicine, Trabzon, Turkey

## Abstract

**Objectives:** To investigate the relationship between serum carbonic anhydrase I-II (CA-I and II) autoantibody levels and diabetic retinopathy (DRP) in cases with type 1 diabetes.

**Materials and Methods:** A total of 37 type-1 diabetic patients, 17 with DRP (group 1) and 20 without (group 2), and 38 healthy control subjects (group 3) were included. CA-I and CA-II autoantibody levels were measured in serum samples obtained from each of the three groups and compared statistically. Additionally, the correlation between CA-I and CA-II autoantibody levels and the presence of diabetic macular edema was examined.

**Results:** Mean measured CA-I autoantibody levels were  $0.145 \pm 0.072$ ,  $0.117 \pm 0.047$ , and  $0.138 \pm 0.061$  ABSU in group 1, group 2, and group 3, respectively ( $p=0.327$ ). The average CA-II autoantibody levels achieved in the same groups were  $0.253 \pm 0.174$ ,  $0.155 \pm 0.137$ , and  $0.131 \pm 0.085$  ABSU, respectively ( $p=0.005$ ). No significant difference was obtained between the subgroups of group 1, with macular edema ( $n=8$ ) and without ( $n=9$ ), in terms of both CA-I and CA-II autoantibody levels ( $p=0.501$ ,  $p=0.178$ , respectively).

**Conclusion:** A significant correlation was observed between the development of DRP and serum CA-II autoantibody levels in type 1 diabetic cases. However, there was no correlation between the autoantibody levels and the presence of diabetic macular edema in cases with DRP.

**Keywords:** Carbonic anhydrase I, carbonic anhydrase II, diabetes mellitus, diabetic retinopathy

## Introduction

Diabetes mellitus is a chronic endocrine disease which is common worldwide and can cause various micro- and macrovascular complications. Diabetic retinopathy (DRP), an important microvascular complication of the disease, is a common cause of vision loss.<sup>1,2</sup>

Type 1 diabetes, one of the subtypes of diabetes mellitus, is becoming a major health problem as its prevalence steadily rises, especially in the younger population. Type 1 diabetes develops as a result of destruction of pancreatic beta cells due to genetic and multifactorial immune response. Islet cell antibodies were detected in the human pancreas for the first time in the 1970s. In

subsequent decades, the presence of various autoantibodies such as glutamic acid decarboxylase antibody, microinsulin antibody, and zinc transporter antibody were reported.<sup>3,4,5</sup>

The carbonic anhydrases (CA), members of the zinc metalloprotein family, are enzymes which catalyze the interconversion of carbon dioxide and water to bicarbonate and hydrogen ions. To date, about 16 CA isoenzymes responsible for various functions have been identified.<sup>6</sup> The CA isoenzymes found in the eye also serve different functions based on their location.<sup>7</sup> CA-I has been found in corneal endothelial cells, lens cells, capillary endothelial cells, in the stroma of the ciliary body, and in the choroid.<sup>8</sup> CA-II has been documented in the ciliary body epithelial cells, retinal Müller cells, the

**Address for Correspondence:** Adem Türk MD, Karadeniz Technical University Faculty of Medicine, Department of Ophthalmology, Trabzon, Turkey  
Phone: +90 505 536 68 52 E-mail: doktorademturk@yahoo.com **Received:** 29.01.2016 **Accepted:** 11.06.2016

retinal pigment epithelium, cone photoreceptors, and the choriocapillaris.<sup>8,9,10,11,12,13,14,15,16</sup>

Various studies have reported that autoantibodies to CA isoenzymes increase during the course of some immunological diseases.<sup>17,18,19,20,21</sup> Based on this premise, the aim of our study was to investigate the presence of CA autoantibodies in patients with type 1 diabetes, which is considered an immunological disease, and to examine possible associations between these autoantibodies and DRP.

## Materials and Methods

This cross-sectional study was approved by the Ethics Committee and all participants provided informed consent. Thirty-seven type 1 diabetes patients between 13 and 58 years of age and 38 healthy control subjects between 23 and 54 years of age were included in the evaluations.

### Evaluation Criteria

The diabetic patients selected for the study were recruited in part from type 1 diabetes patients being followed in the retina division, and in part from type 1 diabetes patients presenting to the ophthalmology outpatient clinic for examination. Patients with Sjögren's syndrome, autoimmune hepatitis, primary biliary cirrhosis, and other autoimmune conditions such as Graves' disease were not included. Patients with history of uveitis or glaucoma were also not included. Patients underwent a thorough ophthalmic examination upon being accepted to the study. After biomicroscopic examination of the anterior and posterior segments, mydriatic eye drops were instilled in both eyes. After pupil dilation, fundus photographs were taken and optical coherence tomography (OCT) images were obtained to evaluate whether macular edema was present. Based on the examination findings, the patients were divided into two groups: those with DRP findings (group 1) and those without (group 2).

The main criterion for inclusion as a healthy control subject (group 3) was having no systemic or ocular problems other than refractive error.

### Collection and Analysis of Blood Specimens

Venous blood was collected into biochemical tubes once from all subjects in each of the three groups. After 5 minutes at room temperature, the blood specimens were centrifuged and stored at -80 °C. All of the collected specimens were assayed in the biochemistry laboratory during the same time frame using the ELISA method to measure CA-I and CA-II autoantibody levels.

### Statistical Analysis

SPSS version 13.0.1 (SPSS, Chicago, Illinois, USA; License no: 9069728, KTU, Trabzon, Turkey) was used for statistical analyses. Data obtained from the study groups were expressed as mean  $\pm$  standard deviation (SD). Normal distribution of numerical data was analyzed using the one-sample Kolmogorov-Smirnov test. The one-way ANOVA (post hoc Tukey test) was used in comparisons of quantitative values and the chi-square test was used in comparison of qualitative values from the three groups. The Mann-Whitney U test was used to compare

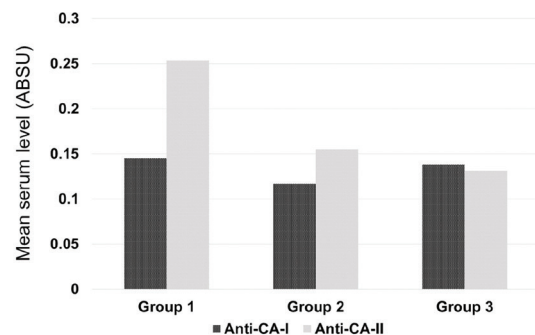
quantitative values from cases in group 1 with and without diabetic macular edema. The relationship between hemoglobin A1c (HbA1c) levels and autoantibody levels in diabetic patients was examined using Pearson correlation analysis, while relationships between autoantibody levels in all study groups were examined by Spearman correlation analysis. Furthermore, independent samples t-test was used to compare CA-I and CA-II autoantibody levels between all of the diabetic patients in groups 1 and 2 (n=37) and the healthy subjects in group 3 (n=38). P values  $\leq 0.05$  were accepted as statistically significant.

## Results

Mean ages of the participants were  $38.82 \pm 8.85$  (24-58) years in group 1,  $29.75 \pm 10.71$  (13-54) years in group 2, and  $35.58 \pm 9.44$  (23-54) years in group 3 ( $p=0.017$ ). There was a significant age difference between groups 1 and 2 ( $p=0.016$ ), while the age differences between groups 1 and 3 ( $p=0.081$ ) and groups 2 and 3 ( $p=0.486$ ) were not significant. Nine of the 17 patients in group 1 were female, 8 of the 20 patients in group 2 were female, and 16 of the 38 healthy volunteers in group 3 were female. There were no significant sex differences between the groups ( $p=0.692$ ).

Mean duration of diabetes among the diabetic patients in the study was  $18.06 \pm 7.8$  (6-37) years for group 1 and  $9.23 \pm 8.6$  (1-34) years for group 2 ( $p=0.003$ ). Mean HbA1c levels were  $9.4 \pm 2.3\%$  (6-14%) in group 1 and  $8.8 \pm 2\%$  (7-15%) in group 2 ( $p=0.387$ ).

Mean CA-I autoantibody levels in groups 1, 2, and 3 were  $0.145 \pm 0.072$ ,  $0.117 \pm 0.047$ , and  $0.138 \pm 0.061$  absorbance units (ABSU), respectively ( $p=0.327$ ). Mean CA-II autoantibody levels in the same groups were  $0.253 \pm 0.174$ ,  $0.155 \pm 0.137$ , and  $0.131 \pm 0.085$  ABSU ( $p=0.005$ ) (Figure 1). There was a significant difference in CA-II autoantibody level between groups 1 and 2 ( $p=0.05$ ) and groups 1 and 3 ( $p=0.003$ ), while the difference between groups 2 and 3 was not significant ( $p=0.756$ ). No significant differences in CA-I or CA-II were found between patients in group 1 who had macular edema on OCT (n=8) and those who did not (n=9) ( $p=0.501$  and  $p=0.178$ , respectively).



**Figure 1.** Comparison of serum carbonic anhydrase I and II autoantibody levels in type I diabetes patients with diabetic retinopathy (group 1) and without diabetic retinopathy (group 2), and in the healthy control group (group 3)

CA: carbonic anhydrases

There was no significant association between HbA1c levels and CA-I autoantibody levels in the diabetic patients in groups 1 and 2 ( $r=0.12$ ,  $p=0.445$ ). A weak correlation was detected between diabetic patients' HbA1c and CA-II autoantibody levels ( $r=0.36$ ,  $p=0.027$ ). There was no statistically significant relationship between the CA-I and CA-II autoantibody levels of subjects in the three study groups ( $n=75$ ) ( $r=0.146$ ,  $p=0.212$ ).

Mean CA-I autoantibody levels of all diabetic patients in the study ( $n=37$ ) and the healthy subjects in group 3 ( $n=38$ ) were  $0.13\pm 0.06$  and  $0.138\pm 0.061$  ABSU, respectively; mean CA-II autoantibody levels in the same groups were  $0.2\pm 0.161$  and  $0.131\pm 0.085$  ABSU. Although the difference in CA-I autoantibody level between the diabetic and nondiabetic subjects was not statistically significant ( $p=0.578$ ), there was a significant difference in CA-II autoantibody level ( $p=0.023$ ).

## Discussion

The immune system comprises specialized cells that protect an organism's body from infection and external agents. Under normal conditions, the immune system does not respond to antigens within the organism. This is defined as selective non-responsiveness to antigens. When this tolerance system is disrupted, the immune system becomes unable to differentiate between foreign and host antigenic structures. This results in an autoimmune response triggered by autoantigenic recognition and subsequent autoimmune disease.<sup>22,23</sup> A search of the literature yields many studies reporting autoimmunity to CA isoenzymes in various autoimmune diseases. The presence of CA autoantibodies has been documented in acute anterior uveitis, Graves' disease, systemic lupus erythematosus, Sjögren's syndrome, endometriosis, idiopathic chronic pancreatitis, primary biliary cirrhosis, tubulointerstitial nephritis, autoimmune hepatitis, and autoimmune cholangitis.<sup>17,18,19,20,21,24,25,26,27</sup>

Taniguchi et al.<sup>20,28</sup> investigated the presence of CA autoantibodies in the etiopathogenesis of type 1 diabetes in two separate studies. In both of the studies, CA-II autoantibody levels were measured in type 1 and 2 diabetes patients, and CA-II autoantibody levels were higher in patients with type 1 diabetes compared to those with type 2 diabetes.<sup>20,28</sup> The results of those studies supports that type 1 diabetes is an autoimmune endocrinopathy. In the present study, which included only type 1 diabetes patients, both CA-II and CA-I autoantibody levels were compared with those of a healthy control group. Our results that CA-II autoantibody levels are higher in diabetic patients than in the healthy controls corroborate those of Taniguchi et al.<sup>20,28</sup> However, unlike the studies by Taniguchi et al.,<sup>20,28</sup> we also investigated the association between CA-II autoantibody levels and the presence of DRP. This analysis revealed that CA-II autoantibody levels in type 1 diabetes patients with DRP were significantly different than those in type 1 diabetes patients without DRP and those of healthy controls. Di Cesare et al.<sup>29</sup> reported that type 1 diabetic patients showed no significant differences in CA-II autoantibody levels compared

to a healthy control group. However, the fact that DRP was not investigated in their studies may explain why the results of Taniguchi et al.<sup>20,28</sup> and Di Cesare et al.<sup>29</sup> differ from ours.

In our study, the increase in CA-II autoantibody levels in type 1 diabetes patients was more pronounced in the presence of DRP. Adamus and Karren<sup>30</sup> reported that CA-II autoantibodies may inhibit CA-II enzyme activity in the retina, which decreases the intracellular pH and leads to the accumulation of intracellular calcium, ultimately resulting in retinal cell dysfunction. This suggests that CA-II autoantibodies may play a role in the etiopathogenesis of both type 1 diabetes and the retinopathy associated with type 1 diabetes. Our finding that CA-II autoantibody levels are statistically elevated in type 1 diabetes patients with DRP further supports this hypothesis.

Levels of CA-I antibody were also evaluated in the present study. There were no significant differences in CA-I levels in type 1 diabetes or in the presence of diabetic retinopathy.

There are no previous studies in the literature examining the relationship between serum CA-I and CA-II levels and the development of DRP in patients with type 1 diabetes. The results of our novel study indicate that CA-I autoantibodies are not significantly associated with the development of type 1 diabetes or DRP. CA-II autoantibodies were significantly elevated only in patients with DRP. The presence of autoantibodies to the CA-II isoenzyme, which functions in many parts of the retina and in the choriocapillaris, may lead to pathologic retinal changes (i.e. DRP) secondary to CA-II dysfunction.

## Conclusion

Our study included a small number of patients, which may have influenced the correlations between the analyzed parameters. Therefore, future studies with larger populations are needed to better elucidate these relationships.

## Ethics

Ethics Committee Approval: Ethics Committee of the Faculty of Medicine of Karadeniz Technical University (2011/131-832), Informed Consent: It was taken. Peer-review: Externally and Internally peer-reviewed.

## Authorship Contributions

Surgical and Medical Practices: Adem Türk, İrfan Nuhuğlu, Cihangir Erem, Concept: Adem Türk, Ahmet Alver, Ahmet Menteşe, Design: Adem Türk, Ahmet Alver, Ahmet Menteşe, Data Collection or Processing: Adem Türk, Süleyman Mollamehmetoğlu, Ahmet Alver, Ahmet Menteşe, İrfan Nuhuğlu, Cihangir Erem, Analysis or Interpretation: Adem Türk, Süleyman Mollamehmetoğlu, Ahmet Alver, Ahmet Menteşe, Halil İbrahim İmamoğlu, Literature Search: Adem Türk, Süleyman Mollamehmetoğlu, Writing: Adem Türk.

Conflict of Interest: No conflict of interest was declared by the authors.

Financial Disclosure: The study was supported by the Karadeniz Technical University scientific research project numbered 2010.114.002.9.



## References

- Turk A, Nuhoglu I, Mentese A, Karahan SC, Erdol H, Erem C. The relationship between diabetic retinopathy and serum levels of ischemia-modified albumin and malondialdehyde. *Retina*. 2011;31:602-608.
- Erdol H, Turk A, Akyol N, Imamoglu HI. The results of intravitreal bevacizumab injections for persistent neovascularizations in proliferative diabetic retinopathy after photocoagulation therapy. *Retina*. 2010;30:570-577.
- Zhang L, Eisenbarth GS. Prediction and prevention of Type 1 diabetes mellitus. *J Diabetes*. 2011;3:48-57.
- Willis JA, Scott RS, Brown LJ, Forbes LV, Schmidl RS, Zimmet PZ, MacKay IR, Rowley MJ. Islet cell antibodies and antibodies against glutamic acid decarboxylase in newly diagnosed adult-onset diabetes mellitus. *Diabetes Res Clin Pract*. 1996;33:89-97.
- Knip M, Kukko M, Kulmala P, Veijola R, Simell O, Akerblom HK, Ilonen J. Humoral beta-cell autoimmunity in relation to HLA-defined disease susceptibility in preclinical and clinical type 1 diabetes. *Am J Med Genet*. 2002;115:48-54.
- Imtaiyaz Hassan M, Shajee B, Waheed A, Ahmad F, Sly WS. Structure, function and applications of carbonic anhydrase isozymes. *Bioorg Med Chem*. 2013;21:1570-1582.
- Hageman GS, Zhu XL, Waheed A, Sly WS. Localization of carbonic anhydrase IV in a specific capillary bed of the human eye. *Proc Natl Acad Sci U S A*. 1991;88:2716-2720.
- Wistrand PJ, Schenholm M, Lönnerholm G. Carbonic anhydrase isoenzymes CA I and CA II in the human eye. *Invest Ophthalmol Vis Sci*. 1986;27:419-428.
- Linsler PJ, Plunkett JA. A role for carbonic anhydrase in early eye morphogenesis. *Invest Ophthalmol Vis Sci*. 1989;30:783-785.
- Linsler P, Moscona AA. Carbonic anhydrase C in the neural retina: transition from generalized to glia-specific cell localization during embryonic development. *Proc Natl Acad Sci U S A*. 1981;78:7190-7194.
- Vardimon L, Fox LE, Moscona AA. Developmental regulation of glutamine synthetase and carbonic anhydrase II in neural retina. *Proc Natl Acad Sci U S A*. 1986;83:9060-9064.
- Scott WJ Jr, Lane PD, Randall JL, Schreiner CM. Malformations in nonlimb structures induced by acetazolamide and other inhibitors of carbonic anhydrase. *Ann N Y Acad Sci*. 1984;429:447-456.
- Sugrue MF. Pharmacological and ocular hypotensive properties of topical carbonic anhydrase inhibitors. *Prog Retin Eye Res*. 2000;19:87-112.
- Dobbs PC, Epstein DL, Anderson PJ. Identification of isoenzyme C as the principal carbonic anhydrase in human ciliary processes. *Invest Ophthalmol Vis Sci*. 1979;18:867-870.
- Wistrand PJ, Garg LC. Evidence of a high-activity C type of carbonic anhydrase in human ciliary processes. *Invest Ophthalmol Vis Sci*. 1979;18:802-806.
- Jampel HD, Chen X, Chue C, Zack DJ. Expression of carbonic anhydrase isozyme III in the ciliary processes and lens. *Invest Ophthalmol Vis Sci*. 1997;38:539-543.
- Nishimori I, Akisawa N, Miyaji E, Kohsaki T, Iwasaki S, Onishi S. Serum antibody to carbonic anhydrase II in patients with chronic viral hepatitis: a review of its prevalence in liver diseases. *Hepatol Res*. 2004;30:210-213.
- Turk A, Aykut M, Akyol N, Kola M, Mentese A, Sumer A, Alver A, Erdvol H. Serum anti-carbonic anhydrase antibodies and oxidant-antioxidant balance in patients with acute anterior uveitis. *Ocul Immunol Inflamm*. 2014;22:127-132.
- Botrè F, Botrè C, Podestà E, Podda M, Invernizzi P. Effect of anti-carbonic anhydrase antibodies on carbonic anhydrases I and II. *Clin Chem*. 2003;49:1221-1223.
- Taniguchi T, Okazaki K, Okamoto M, Seko S, Tanaka J, Uchida K, Nagashima K, Kurose T, Yamada Y, Chiba T, Seino Y. High prevalence of autoantibodies against carbonic anhydrase II and lactoferrin in type 1 diabetes: concept of autoimmune exocrinopathy and endocrinopathy of the pancreas. *Pancreas*. 2003;27:26-30.
- Nishi H, Tojo A, Onozato ML, Jimbo R, Nangaku M, Uozaki H, Hirano K, Isayama H, Omata M, Kaname S, Fujita T. Anti-carbonic anhydrase II antibody in autoimmune pancreatitis and tubulointerstitial nephritis. *Nephrol Dial Transplant*. 2007;22:1273-1275.
- Delves PJ, Roitt IM. The immune system. First of two parts. *N Engl J Med*. 2000;343:37-49.
- Kamradt T, Mitchison NA. Tolerance and autoimmunity. *N Engl J Med*. 2001;344:655-664.
- Alver A, Menteşe A, Karahan SC, Erem C, Keha EE, Arikan MK, Eminağaoğlu MS, Deger O. Increased serum anti-carbonic anhydrase II antibodies in patients with Graves' disease. *Exp Clin Endocrinol Diabetes*. 2007;115:287-291.
- Kino-Ohsaki J, Nishimori I, Morita M, Okazaki K, Yamamoto Y, Onishi S, Hollingsworth M. Serum antibodies to carbonic anhydrase I and II in patients with idiopathic chronic pancreatitis and Sjögren's syndrome. *Gastroenterology*. 1996;110:1579-1586.
- Kiechle FL, Quattrociochi-Longe TM, Brinton DA. Carbonic anhydrase antibody in sera from patients with endometriosis. *Am J Clin Pathol*. 1994;101:611-615.
- Nishimori I, Miyaji E, Morimoto K, Kohsaki T, Okamoto N, Onishi S. Diminished cellular immune response to carbonic anhydrase II in patients with Sjögren's syndrome and idiopathic chronic pancreatitis. *JOP*. 2004;5:186-192.
- Taniguchi T, Okazaki K, Okamoto M, Seko S, Uchida K, Seino Y. Presence of autoantibodies to carbonic anhydrase II and lactoferrin in type 1 diabetes: proposal of the concept of autoimmune exocrinopathy and endocrinopathy of the pancreas. *Diabetes Care*. 2001;24:1695-1696.
- di Cesare E, Previti M, Lombardo F, Mazzù N, di Benedetto A, Cucinotta D. Prevalence of autoantibodies to carbonic anhydrase II and lactoferrin in patients with type 1 diabetes. *Ann N Y Acad Sci*. 2004;1037:131-132.
- Adamus G, Karren L. Autoimmunity against carbonic anhydrase II affects retinal cell functions in autoimmune retinopathy. *J Autoimmun*. 2009;32:133-139.



# Treatment Results in Serpiginous Choroiditis and Multifocal Serpiginoid Choroiditis Associated with Latent Tuberculosis

Merih Oray\*, Zaur Zakiev\*, Tülin Çağatay\*\*, İlnur Tuğal-Tutkun\*

\*İstanbul University İstanbul Faculty of Medicine, Department of Ophthalmology, İstanbul, Turkey

\*\*İstanbul University İstanbul Faculty of Medicine, Department of Pulmonary Medicine, İstanbul, Turkey

## Abstract

**Objectives:** To compare the results of systemic antitubercular therapy (ATT) and immunomodulatory therapy (IMT) in patients with serpiginous choroiditis (SC) or multifocal serpiginoid choroiditis (MSC).

**Materials and Methods:** The clinical records of 28 patients with SC and MSC were reviewed. Patients were divided into 2 groups according to the treatment applied. Group 1 included 12 patients with MSC and 5 with SC treated with ATT and corticosteroid (CS); group 2 included 9 patients with MSC and 2 with SC treated with conventional IMT, interferon alpha-2a, and/or CS monotherapy.

**Results:** In group 1, clinical remission was achieved in 12/12 MSC and 3/5 SC (total 15/17) patients with administration of ATT for 1 year. Two patients (1 SC, 1 MSC) had reactivation 2 and 7 months after cessation of ATT. Two patients with recurrence after completion of ATT and 2 patients resistant to ATT received IMT ± CS therapy. In group 2, clinical remission was achieved in 7/9 MSC and 2/2 SC (total 9/11) patients after 1 year of treatment. Recurrent inflammation was observed in 2 MSC patients 2 and 112 months after initiation of therapy, but responded well to local/systemic CS or IMT modification, and clinical remission was achieved in  $7.8 \pm 4.3$  months. Cumulative dose of CS was higher in group 2 ( $p=0.057$ ). Nine of 12 MSC patients treated with ATT and 4/9 MSC patients treated with IMT achieved remission ( $p=0.203$ ). One of 5 SC patients treated with ATT and 2/2 SC patients treated with IMT achieved remission ( $p=0.142$ ).

**Conclusion:** Although a statistically significant result could not be achieved in this small case series, our results suggest that ATT may be an appropriate first choice in the treatment of MSC associated with latent tuberculosis, and may be administered in patients with SC who are unresponsive to IMT.

**Keywords:** Serpiginous choroiditis, multifocal serpiginoid choroiditis, latent tuberculosis, anti tubercular therapy, immunomodulatory treatment

## Introduction

Serpiginous choroiditis (SC) and multifocal serpiginoid choroiditis (MSC) are uveitic entities on the same spectrum but with different clinical morphologic features. SC is a chronic, progressive, recurrent, usually bilateral intraocular inflammatory disease of undetermined etiology. It is characterized by geographic spread in the form of serpentine infiltrates typically beginning in the peripapillary region and spreading toward the periphery, involving the retinal pigment epithelium and outer retinal layers.<sup>1,2</sup> Multifocal serpiginoid choroiditis, also referred to in the literature as serpiginous-like choroiditis, serpiginoid choroiditis, multifocal serpiginous choroiditis, and amphiginous choroiditis,

may present as multifocal progressive or diffuse choroiditis.<sup>3,4,5,6,7,8</sup> Similar to SC, the condition has a chronic, progressive, and recurrent course; however, in contrast to SC, it is characterized by multifocal, irregular geographic lesions in the fundus, midperiphery, and periphery in addition to the juxtapapillary area, and ocular involvement is frequently unilateral.<sup>1</sup>

Gupta et al.<sup>3</sup> first described in 2003 that MSC is clinically distinct from classic SC and is associated with tuberculosis (TB). Recent studies have shown that aqueous and vitreous samples obtained from MSC patients are positive for *Mycobacterium tuberculosis* DNA.<sup>4,9</sup> While SC is recognized as an immune-mediated inflammatory disease, the *M. tuberculosis* bacillus has

**Address for Correspondence:** Merih Oray MD, İstanbul University İstanbul Faculty of Medicine, Department of Ophthalmology, İstanbul, Turkey  
Phone: +90 532 407 17 53 E-mail: emerih@yahoo.com **Received:** 31.01.2016 **Accepted:** 11.06.2016

been shown to be the triggering factor in MSC.<sup>10,11,12,13</sup> The etiopathogenesis and treatment of both diseases is still debated.

The aim of this study was to compare the results of systemic antitubercular therapy (ATT) and immunomodulatory therapy (IMT) in patients with SC or MSC associated with latent TB.

## Materials and Methods

The medical records of patients diagnosed with SC or MSC at İstanbul University İstanbul Faculty of Medicine, Department of Ophthalmology between January 1995 and December 2013 were analyzed retrospectively. Demographic data such as age and sex, symptoms at presentation, duration of symptoms, systemic and ocular histories, and diagnosis and treatment received at other medical centers were analyzed.

Patients with clinical findings consistent with SC or MSC, purified protein derivative (PPD) test results over 15 mm and/or positive interferon-gamma release assay test (IGRA; Quantiferon-TB Gold, ELISPOT), no manifest signs of extraocular TB, and who regularly attended follow-up for 12 months and regularly took their medications were included in the study.

Thirty-four patients who were followed for less than 12 months, who did not attend follow-up or take their medication

regularly, or in whom latent TB was not detected were excluded.

Best corrected visual acuity was measured using Snellen's chart and converted to logMAR (logarithm of the minimum angle of resolution) for statistical analysis. Anterior segment findings from slit-lamp examination and SC and MSC lesion status on fundus examination were evaluated. In addition, fundus photography, optical coherence tomography, fluorescein angiography, if available, indocyanine green angiography images were evaluated.

The patients were divided into two groups. Group 1 included 17 (12 MSC, 5 SC) patients treated with ATT and corticosteroid (CS) therapy. ATT consisted of a 4-drug regimen (300 mg/day isoniazid, 600 mg/day rifampicin, 2 mg/day pyrazinamide, and 1500 mg/day ethambutol) for 2 months, followed by a 2-drug regimen (300 mg/day isoniazid, 600 mg/day rifampicin) for 10 months. Treatments administered to group 1 patients during relapse are shown in Table 1.

Group 2 included 11 (9 MSC, 2 SC) patients treated with conventional IMT, interferon or CS monotherapy. Treatments administered to group 2 patients during relapse are shown in Table 2.

Visual acuities before treatment, at 1 year after treatment, and at final examination were compared between groups 1 and

**Table 1. Status of group 1 patients after 1 year of treatment and during follow-up, and therapy added for relapse**

Group 1 (patient)	Diagnosis	Activity at 1 year	First attack after 1 year	Activity duration (months)	Number of relapse	Total remission time (months)	Relapse treatment	Final examination
1	MSC	Inactive	-	Remission	0	72	-	Inactive
2	SC	Inactive	-	Remission	0	40	-	Inactive
3	MSC	Inactive	-	Remission	0	25	-	Inactive
4	MSC	Inactive	7 months	1	1	-	CS	Active
5	MSC	Inactive	-	Remission	0	34	-	Inactive
6	SC	Inactive	2 months	2	1	-	CS, IFN	Inactive for 2 months
7	SC	Active	Active	8	0	-	CS, CSA, AZA	Inactive for 33 months
8	MSC	Inactive	-	Remission	0	26	-	Inactive
9	MSC	Inactive	-	Remission	0	26	-	Inactive
10	MSC	Inactive	-	Remission	0	14	-	Inactive
11	MSC	Inactive	-	Remission	0	13	-	Inactive
12	MSC	Inactive	-	Remission	0	14	-	Inactive
13	MSC	Inactive	-	Remission	0	12	-	Inactive
14	MSC	Inactive	-	Remission	0	4	-	Inactive
15	SC	Inactive	-	Remission	0	1	-	Inactive
16	MSC	Inactive	-	Remission	0	5	-	Inactive
17	SC	Active	Active	16	0	-	IFN, CS	Active

SC: Serpiginous choroiditis, MSC: Multifocal serpiginoid choroiditis, CS: Corticosteroid, AZA: Azathioprine, CSA: Cyclosporin A, IFN: Interferon alpha-2a

2. The cumulative systemic CS dose received over the course of 1 year was calculated for both groups and compared.

Disease activity status, number of relapses, and remission time were calculated at the end of 1 year of treatment. The presence of active choroiditis was accepted as a criterion for activation. A patient was considered in remission when at least 1 year had elapsed since their last attack with no new choroiditis activation.

#### Statistical Analysis

Fisher's exact test was used to compare remission rates between groups; the Mann-Whitney U test was used to compare visual acuity and cumulative steroid dose between groups.

### Results

A total of 21 MSC patients and 7 SC patients were included in the study. Mean age was  $35.8 \pm 11.6$  years for MSC patients and  $44.6 \pm 12.8$  for SC patients.

Group 1 consisted of a total of 29 eyes of 17 patients (11 male, 6 female) treated for 1 year with ATT + CS therapy. The patients' mean age at presentation was  $40.9 \pm 12.6$  (28-64) years. Findings were consistent with MSC in 12 patients and SC in 5. Involvement was bilateral in 12 patients and unilateral in 5. Two of the SC patients had undergone 25 and 101 months of IMT prior to ATT, which was initiated due to reactivation, whereas ATT was the first choice for the other patients.

Group 2 included a total of 18 eyes of 11 patients (7 male, 4 female) treated for 1 year with IMT ± CS. The patients' mean age at presentation was  $33.4 \pm 10.8$  (20-50) years. Findings were consistent with MSC in 9 patients and SC in 5. Involvement

was bilateral in 7 patients and unilateral in 4. All patients in group 2 were treated with systemic CS; treatment was further supplemented with interferon alpha-2a in 2 patients, azathioprine in 2 patients, and combination azathioprine and cyclosporin therapy in 4 patients.

In group 1, clinical remission was observed in 12/12 MSC patients and 3/5 SC patients (total 15/17) after 1 year of ATT + CS therapy. Nine MSC and 1 SC patients remained in remission for 1-6 years after cessation of ATT ( $p=0.100$ ). Reactivation occurred in 1 SC and 1 MSC patient at 2 and 7 months, respectively. Clinical remission was achieved in 2 SC patients resistant to ATT and two patients (1 SC, 1 MSC) with recurrence (Table 1).

In group 2, clinical remission was achieved in 7/9 MSC and 2/2 SC (total 9/11) patients after 1 year of IMT ± CS therapy, and remission continued for 1-3 years in 4 MSC patients and for 6-13 years in the 2 SC patients after cessation of treatment ( $p=0.454$ ). Reactivation was observed in 2 MSC patients at 2 and 112 months, respectively. In 2 MSC patients with active disease at 1 year and 2 MSC patients with recurrence, remission was achieved with local/systemic CS and IMT modification (Table 2).

Comparison of treatment outcomes in MSC showed that remission was achieved in 9/12 MSC patients treated with ATT and 4/9 MSC patients treated with IMT ( $p=0.203$ ). Among SC patients, only 1/5 treated with ATT and 2/2 treated with IMT achieved remission ( $p=0.142$ ).

Median logMAR visual acuities at baseline, after 1 year of treatment, and at final examination were 0.4, 0.5, and 0.3 for group 1 and 0.8, 0.4, and 0.3 for group 2, respectively. There were no statistically significant differences between groups 1

**Table 2. Status of group 2 patients after 1 year of treatment and during follow-up, and therapy added for relapse**

Group 2 (patient)	Diagnosis	Inflammation at 1 year	First attack after 1 year	Activity duration (months)	Number of relapses	Total remission time (months)	Relapse treatment	Inflammation at final examination
1	SC	Inactive	-	Remission	0	162	-	Inactive
2	MSC	Inactive	-	Remission	0	39	-	Inactive
3	MSC	Inactive	112 months	6	1	172	CS	Inactive for 60 months
4	MSC	Inactive	2 months	7	1	138	CS, AZA, CSA	Inactive for 136 months
5	MSC	Inactive	-	Remission	0	16	-	Inactive
6	MSC	Active	Active	4	0	82	CS, AZA, CSA	Inactive for 78 months
7	MSC	Inactive	-	Remission	0	2	-	Inactive
8	SC	Inactive	-	Remission	0	73	-	Inactive
9	MSC	Active	Active	14	0	22	CS	Inactive for 8 months
10	MSC	Inactive	-	Remission	0	36	-	Inactive
11	MSC	Inactive	-	Remission	0	30	-	Inactive

SC: Serpiginous choroiditis, MSC: Multifocal serpiginoid choroiditis, CS: Corticosteroid, AZA: Azathioprine, CSA: Cyclosporin A

and 2 in visual acuity at baseline and after 1 year of treatment ( $p=0.287$ ).

After 1 year of treatment, the cumulative prednisolone equivalent mean CS dose was  $1150\pm 859$  mg for group 1 and  $1907\pm 1979$  mg for group 2 ( $p=0.057$ ).

## Discussion

The incidence of SC and MSC both in Turkey and worldwide has not been definitively determined. The largest case series study of MSC was conducted in 2003 by Gupta et al.<sup>3</sup> in India, an endemic area for TB, and included 126 patients. Despite the paucity of epidemiological data regarding SC and MSC in Europe and America, studies conducted in these countries describe it as rare.<sup>1,2,6,7,9</sup> Although the number of TB cases in Turkey dropped significantly toward the end of the 20<sup>th</sup> century, there is still a higher incidence of latent TB compared to developed countries.<sup>14</sup> Between 1995 and 2013, 63 patients were diagnosed with SC or MSC in our clinic. The higher prevalence of SC and MSC in India and Turkey may be related to the higher incidences of latent TB compared to developed countries. This supports the role of latent TB in the etiology of SC and MSC.

SC and MSC are generally considered to not show sex differences. However, Blumenkranz et al.<sup>15</sup> first reported observing SC more often in males. Indeed, Gupta et al.<sup>3</sup> reported that MSC was twice as common in males. In our study, males were predominant among both SC and MSC patients (male:female ratio=18:10).

In the literature, SC is reported to be most common in the white race, in the fourth and fifth decades, and is rare in young patients.<sup>16</sup> However, studies conducted in India suggest that MSC is more common in younger individuals. The average age of MSC patients has been reported as 30 by Gupta et al.<sup>3</sup> and 31 by Madhavan et al.<sup>17</sup> Consistent with the literature, in the present study, the mean age of MSC patients was 35.8 years, while that in SC patients was 44.6 years. Furthermore, as in previous studies, most of the MSC and SC patients in our study exhibited bilateral involvement.

SC and MSC are clinical diagnoses based on typical fundus findings. The clinical morphology of MSC is unlike that of classic autoimmune SC, and it is believed to result from hypersensitivity to TB bacilli in patients with latent TB. The tuberculin skin test is the most commonly used test worldwide to detect latent TB. However, false-negative and false-positive results compromise the reliability of this test. Recent introduction of the more sensitive IGRA tests have substantially facilitated the diagnosis of latent TB. In the present study, IGRA was performed and positive results were confirmed for all patients in group 1 before initiating ATT. PPD was performed in 14/17 patients in that group, 3 of whom had indurations less than 15 mm. All patients with clinical suspicion of MSC who underwent IGRA had positive results. Studies conducted by the manufacturer report the reliability of IGRA results as being in the 90-95% range.<sup>18</sup> Although we found a 100% positivity rate among our patients, Mackensen et al.<sup>9</sup> reported a very low IGRA accuracy rate for

MSC (52%). In the same study, 4 patients remained IGRA positive after ATT. This indicates that the IGRA cannot be used in patient follow-up.

Like the IGRA, polymerase chain reaction (PCR) analysis is another new diagnostic method for MSC. Gupta et al.<sup>3</sup> conducted PCR analysis on aqueous and vitreous samples from 7 MSC patients and reported that results were positive for TB in 5 (71.4%) of them. We did not conduct PCR analysis for any of our patients in the present study.

Although the diagnosis of SC and MSC are based on clinical data, treatment is a controversial topic among the global scientific community. In countries not endemic for TB, SC is considered an autoimmune-derived disease, and treatment with immunosuppressive agents is recommended. Particularly in the presence of clinically active choroiditis, the current therapeutic approach includes high-dose CS therapy, followed by IMT to prevent recurrence in the long term.<sup>19</sup> There is no consensus in the literature regarding which immunomodulatory agents are more effective in the treatment of SC. T-cell inhibitors, antimetabolites, alkylating agents, and biologic agents are the different treatment alternatives currently in use.

In the current study, the SC patients in groups 1 and 2 showed contradictory treatment responses. Five patients in group 1 who had findings consistent with classic SC and latent TB according to IGRA were treated with ATT ± CS; of these, 2 patients continued to have clinically active disease after treatment, and 1 patient showed reactivation 2 months after treatment cessation. The poor treatment results in 3 of the 5 patients treated with ATT may be a coincidence related to the high rate of latent TB in the Turkish population. On the other hand, in the 2 patients treated successfully with ATT, the disease could not be controlled previously with IMT + CS therapy. This suggests that the choroiditis may be associated with latent TB. In group 2, which was not treated with ATT, 2 patients diagnosed with classic SC were treated with IMT + CS therapy. Both of those patients were in clinical remission after 1 year of treatment, and no relapse was observed during follow-up. This contradiction raises the question of whether ATT should be initiated when latent TB is detected in patients with classic SC.

Studies conducted in India have reported that ATT effectively reduces attacks and induces long-term remission in patients with tuberculosis-associated MSC.<sup>20</sup> In their study conducted in Germany, Mackensen et al.<sup>9</sup> also reported observing remission without relapses in MSC patients treated with ATT. Similarly, in the present study we achieved remission in a majority of MSC patients after 1 year of ATT ± CS therapy. Only 1 patient experienced relapse after 7 months. Of the MSC patients treated with IMT ± CS, 2 patients had persistent clinical activity after 1 year of treatment, and 2 others relapsed during follow-up. Based on these results, we can conclude that ATT is more effective in MSC patients. Furthermore, the lower cumulative CS dose in group 1 also demonstrates the efficacy of ATT. Patients in group 2 required CS at higher doses and for longer periods to control active inflammation.

## Conclusion

The etiopathogenesis and treatment of SC and MSC remain controversial. Although SC is described in the literature as an autoimmune disease, MSC is reportedly associated with TB. Latent TB is common among Turkish patients, and the possibility of also detecting latent TB in SC patients poses a problem in terms of treatment approach. Although statistically significant results could not be obtained due to small patient numbers, our observation that ATT may be more effective in the treatment of MSC is consistent with the literature. Prospective studies with larger case series are necessary.

## Ethics

Ethics Committee Approval: İstanbul University İstanbul Faculty of Medicine, 2014/544, Informed Consent: Informed consent was obtained prior to therapeutic procedures. Peer-review: Externally peer-reviewed.

## Authorship Contributions

Surgical and Medical Practices: Merih Oray, İlknur Tuğal-Tutkun, Tülin Çağatay, Concept: İlknur Tuğal-Tutkun, Zaur Zakiev, Merih Oray, Design: İlknur Tuğal-Tutkun, Zaur Zakiev, Merih Oray, Data Collection or Processing: Zaur Zakiev, Merih Oray, Analysis or Interpretation: İlknur Tuğal-Tutkun, Zaur Zakiev, Merih Oray, Literature Search: İlknur Tuğal-Tutkun, Zaur Zakiev, Merih Oray, Writing: Merih Oray.

Conflict of Interest: No conflict of interest was declared by the authors.

Financial Disclosure: The authors declared that this study received no financial support.

## References

- Nazari H, Rao NA. Serpiginous choroiditis and infectious multifocal serpiginoïd choroiditis. *Surv Ophthalmol*. 2013;58:203-232.
- Lim WK, Buggage RR, Nussenblatt RB. Serpiginous choroiditis. *Surv Ophthalmol*. 2005;50:231-244.
- Gupta V, Gupta A, Arora S, Bambery P, Dogra MR, Agarwal A. Presumed tubercular serpiginoïd like choroiditis: clinical presentations and management. *Ophthalmology*. 2003;110:1744-1749.
- Bansal R, Gupta A, Gupta V, Dogra MR, Sharma A, Bambery P. Tubercular Serpiginoïd-like choroiditis presenting as multifocal serpiginoïd choroiditis. *Ophthalmology*. 2012;119:2334-2342.
- Gupta A, Sharma A, Bansal R, Sharma K. Classification of intraocular tuberculosis. *Ocul Immunol Inflamm*. 2015;23:7-13.
- Cunningham ET, Gupta A, Zierhut M. The creeping choroiditis-serpiginoïd and multifocal serpiginoïd choroiditis. *Ocul Immunol Inflamm*. 2014;22:345-348.
- De Luigi G, Mantovani A, Papadia M, Herbot CP. Tuberculosis-related choriocapillaritis (multifocal-serpiginoïd choroiditis): follow-up and precise monitoring of therapy by indocyanine green angiography. *Int Ophthalmol*. 2012;32:55-60.
- Bhuihar SS, Biswas J. Nested PCR-positive tubercular ampiginous choroiditis: a case report. *Ocul Immunol Inflamm*. 2012;20:303-305.
- Mackensen F, Becker MD, Wiehler U, Max R, Dalpke A, Zimmermann S. QuantiFERON TB-Gold-a new test strengthening long-suspected tuberculous involvement in serpiginoïd-like choroiditis. *Am J Ophthalmol*. 2008;146:761-766.
- Broekhuysse RM, van Herck M, Pinckers AJ, Winkens HJ, van Vugt AH, Ryckaert S, Deutman AF. Immune responsiveness to retinal S-antigen and opsin in serpiginoïd choroiditis and other retinal diseases. *Doc Ophthalmol*. 1988;69:83-93.
- Erkkila H, Laatikainen L, Jokinen E. Immunological studies on serpiginoïd choroiditis. *Graefes Arch Clin Exp Ophthalmol*. 1982;219:131-134.
- Witmer R. A specific form of recidivating choroiditis. *Ophthalmologica*. 1952;123:353-354.
- Maumenee AE. Clinical entities in "uveitis". An approach to the study of intraocular inflammation. *Am J Ophthalmol*. 1970;69:1-27.
- Kurçer MA, Külekçi Uğur A, Demirsezen M, Sulak YA. Dünyada ve Türkiye'de tüberküloz epidemiyolojisi. *Türkiye Klinikleri J Inf Dis-Special Topics*. 2011;4:1-5.
- Blumenkranz MS, Gass JD, Clarkson JG. Atypical serpiginoïd choroiditis. *Arch Ophthalmol*. 1982;100:1773-1775.
- Weiss H, Annesley WH Jr, Shields JA, Tomer T, Christopherson K. The clinical course of serpiginoïd choroiditis. *Am J Ophthalmol*. 1979;87:133-142.
- Madhavan HN, Therese KL, Gunisha P, Jayanthi U, Biswas J. Polymerase chain reaction for detection of *Mycobacterium tuberculosis* in epiretinal membrane in Eales' disease. *Invest Ophthalmol Vis Sci*. 2000;41:822-825.
- Çelik Ü, Kocabal E. Tüberküloz tanısında yeni bir yöntem: interferon-gamma araştırılmasına dayanan testler. *Tüberküloz ve Toraks Dergisi*. 2007;55:108-117.
- Jabs DA, Rosenbaum JT, Foster CS, Holland GN, Jaffe GJ, Louie JS, Nussenblatt RB, Stiehm ER, Tessler H, Van Gelder RN, Whitcup SM, Yocum D. Guidelines for the use of immunosuppressive drugs in patients with ocular inflammatory disorders: recommendations of an expert panel. *Am J Ophthalmol*. 2000;130:492-513.
- Gupta V, Arora S, Gupta A, Ram J, Bambery P, Sehgal S. Management of presumed intraocular tuberculosis: possible role of the polymerase chain reaction. *Acta Ophthalmol Scand*. 1998;76:679-682.



# Thyroid-associated Ophthalmopathy

Esra Şahlı\*, Kaan Gündüz\*\*

\*Ankara Numune Training and Research Hospital, Ophthalmology Clinic, Ankara, Turkey

\*\*Ankara University Faculty of Medicine, Department of Ophthalmology, Ankara, Turkey

## Abstract

Thyroid-associated ophthalmopathy is the most frequent extrathyroidal involvement of Graves' disease but it sometimes occurs in euthyroid or hypothyroid patients. Thyroid-associated ophthalmopathy is an autoimmune disorder, but its pathogenesis is not completely understood. Autoimmunity against putative antigens shared by the thyroid and the orbit plays a role in the pathogenesis of disease. There is an increased volume of extraocular muscles, orbital connective and adipose tissues. Clinical findings of thyroid-associated ophthalmopathy are soft tissue involvement, eyelid retraction, proptosis, compressive optic neuropathy, and restrictive myopathy. To assess the activity of the ophthalmopathy and response to treatment, clinical activity score, which includes manifestations reflecting inflammatory changes, can be used. Supportive approaches can control symptoms and signs in mild cases. In severe active disease, systemic steroid and/or orbital radiotherapy are the main treatments. In inactive disease with proptosis, orbital decompression can be preferred. Miscellaneous treatments such as immunosuppressive drugs, somatostatin analogs, plasmapheresis, intravenous immunoglobulins and anticytokine therapies have been used in patients who are resistant to conventional treatments. Rehabilitative surgeries are often needed after treatment.

**Keywords:** Thyroid ophthalmopathy, proptosis, steroid therapy, radiotherapy, decompression surgery

## Introduction

Thyroid-associated ophthalmopathy (TAO) is an ocular condition that frequently manifests with thyroid dysfunction, and is the most common extrathyroidal manifestation of Graves' disease. Graves' disease is an autoimmune disease characterized by hyperthyroidism, diffuse goiter, ophthalmopathy, and in rare cases, dermatopathy. Thyroid dermatopathy consists of pretibial cutaneous nodules or diffuse thickening. In addition to elevated free thyroid hormone levels and suppressed thyroid stimulating hormone (TSH) levels, the levels of serum antithyroglobulin (TG) antibodies, antithyroid peroxidase (anti-TPO), and TSH receptor antibodies levels may be elevated in Graves' disease. Graves' disease is the most common cause of hyperthyroidism.<sup>1</sup> The annual incidence is 0.3% in the United States of America, 2.7% in women in the United Kingdom, and 0.3% in men in the United Kingdom. It is 6 to 7 times more common in females than males. It occurs more often in the 3<sup>rd</sup> and 4<sup>th</sup> decades.<sup>2</sup>

Although TAO is usually seen in patients with Graves' disease (80%), it may also occur in patients with thyroid cancers or autoimmune hypothyroid due to Hashimoto's thyroiditis (10%), as well as individuals with no thyroid disease (10%).<sup>3</sup>

## Epidemiology and Pathogenesis

While TAO is 2.5- to 6-fold more common among women, severe ophthalmopathy is more common among men. Onset is generally between the ages of 30 and 50, and the disease course is more severe after age 50. Ophthalmopathy is reported to occur in 25-50% of patients with Graves' disease and 2% of patients with Hashimoto's thyroiditis. About 3-5% of these patients have severe ophthalmopathy.<sup>4</sup> Most patients develop ophthalmopathy within 18 months of being diagnosed with Graves' disease. However, ophthalmopathy onset may occur up to 10 years before and as late as 20 years after the onset of thyroid disease.<sup>5</sup>

Although the pathogenesis of TAO is not completely understood, it is known to be an autoimmune disorder. It has

**Address for Correspondence:** Esra Şahlı MD, Ankara Numune Training and Research Hospital, Ophthalmology Clinic, Ankara, Turkey  
Phone: +90 505 643 54 07 E-mail: esracansizoglu@gmail.com **Received:** 05.02.2016 **Accepted:** 26.04.2016

©Copyright 2017 by Turkish Ophthalmological Association  
Turkish Journal of Ophthalmology, published by Galenos Publishing House.

been established that autoimmunity develops against antigens common to the thyroid gland and the orbit. Although some support the view that the common pathogenetic antigen is TSH receptor,<sup>6</sup> Salvi et al.<sup>7</sup> identified a 64-kDa protein common to the thyroid gland and the orbit. Recent studies have reported upregulation of the cardiac calsequestrin gene in TAO patients and suggested that autoimmunity against calsequestrin may be a triggering factor in the pathogenesis of ophthalmopathy.<sup>8</sup> Despite a close correlation between ophthalmopathy and TSH receptor antibodies, soon after the publication of autoimmunity against calsequestrin, antibodies against orbital fibroblast membrane antigen collagen XIII were also identified.<sup>9</sup>

Reactive T lymphocytes that recognize thyroid-orbit common antigens infiltrate the orbit and extraocular muscle perimysium. This is enhanced by circulating and local adhesion molecules stimulated by cytokines. Following infiltration of the orbit with T lymphocytes, the common antigen is recognized by T-cell receptors on CD4<sup>+</sup> T lymphocytes (Th). Cytokines secreted by Th lymphocytes activate CD8<sup>+</sup> lymphocytes and autoantibody-producing B cells, which strengthens the immune reaction.<sup>10</sup> These cytokines stimulate the synthesis and secretion of glycosaminoglycans (GAGs) by fibroblasts. Due to their water attracting properties, GAGs lead to periorbital edema, proptosis, and swelling of the extraocular muscles.<sup>11</sup> Fibroblast proliferation stimulated by cytokines also plays a role in the expansion of the orbital contents. Orbital fibroblasts include preadipocytes, which turn into adipocytes with hormonal stimulation. These cells have been shown to contribute to the increase in the volume of retroorbital fat tissue.<sup>12</sup>

Recent studies have demonstrated that thyroid autoantibodies and immune system genes have an important role in predicting before the development of ophthalmopathy and determining its severity after onset. Anti-TPO antibody and anti-TG positivity rates of 90% and 50%, respectively, have been reported in the presence of ophthalmopathy.<sup>13,14</sup>

In addition to autoimmunity, genetic and environmental factors are also known to be influential in the etiopathogenesis of thyroid ophthalmopathy.

#### Genetic Factors

There are many studies investigating the role of genetics in the development of ophthalmopathy. In a study evaluating the ocular and palpebral findings of first and second degree relatives of patients with TAO, Graves' disease, and Hashimoto's thyroiditis, TAO findings such as upper eyelid retraction were present in 33% of euthyroid relatives.<sup>15</sup> Twin studies have shown that the frequency of Graves' disease is up to 30% in monozygotic twins, and it has been predicted that the risk of developing Graves' disease is influenced approximately 79% by genetics and 21% by environmental factors.<sup>16</sup>

Many studies have reported polymorphisms in protein genes affecting immune function such as HLADR-3, CTLA 4, PTPN22, CD40, interleukin (IL)-2RA, FCRL3, and IL-23R, as well as genes encoding thyroid-specific proteins like TG.<sup>17</sup>

The presence of single-nucleotide polymorphisms (SNPs) in the genes of tyrosine phosphatase, which affects TSH receptor, and the genes of inflammatory cytokines IL-13, IL-21, and IL-23 has been demonstrated in TAO patients.<sup>18,19,20,21,22</sup> Gene polymorphism for transcription regulator *NF-κB1* has been associated with the development and onset age of ophthalmopathy.<sup>23</sup> A study evaluating the relationship between major histocompatibility complex (MHC) class II human leukocyte antigen (HLA) alleles and ophthalmopathy revealed an association between the HLA-DRB1 allele and extraocular muscle involvement.<sup>24</sup> SNPs identified in the *ARID5B* and *NRXN3* genes may also regulate fat deposition and have a link to Graves' disease.<sup>25,26</sup> It has been shown that a nucleotide substitution in a TG gene promoter associated with interferon alpha (IFNα) was more common in patients with autoimmune thyroid disease. The authors stated that IFNα directly affected gene expression underlying thyroid autoimmunity via the binding of IFN regulatory factor-1 to the variant TG promoter.<sup>27</sup> In a recent study, calsequestrin-1 gene SNP was proposed as a genetic marker for TAO.<sup>28</sup>

#### Environmental Factors

In individuals with the relevant genes, ophthalmopathy may be triggered by environmental factors such as stress, infectious agents, iodine, IFN and interleukin therapy, and sex steroids. Bacteria may trigger an inflammatory response either by stimulating the expression of costimulatory molecules like MHC class II or by altering presentation of their own proteins. Although there are reports in the literature linking Graves' disease to human foamy virus and *Yersinia enterocolitica* infection, causal relationships could not be demonstrated.<sup>17</sup> Cigarette use is the strongest modifiable risk factor. In fact, the risk is proportionate to the number of cigarettes smoked daily.<sup>29</sup> TAO is more common and more severe in smokers, and smokers also relapse more often and more severely after treatment. Cawood et al.<sup>30</sup> demonstrated that GAG production and adipogenesis increased in a dose-dependent manner in response to cigarette smoke extract in an in vitro TAO model. Moreover, smoking leads to delayed and reduced response to ophthalmopathy treatment.<sup>31</sup>

#### Clinical Course and Signs

Patient evaluation begins with confirming the clinical diagnosis and determining the current disease phase; finally, determining the clinical severity is necessary in order to choose appropriate treatment.

Ophthalmic findings are usually bilateral, but may also be unilateral or asymmetric. Nearly half of Graves' disease patients have symptoms including dryness and stinging, photophobia, epiphora, diplopia, and a feeling of pressure behind the eyes.<sup>29</sup> In a study evaluating 120 TAO patients, the most common ocular findings were eyelid retraction (91%), proptosis (62%), extraocular muscle dysfunction (42%), conjunctival hyperemia (34%), eyelid edema (32%), and chemosis (23%). Findings of optic neuropathy were rarer (6%). In the same patient series, the most common symptom was diplopia (33%), followed by pain



and discomfort (30%), epiphora (21%), photophobia (16%), and blurred vision (9%).<sup>31</sup>

Subclinical involvement is present in approximately 70% of patients with Graves' hyperthyroidism. Expansion of the extraocular muscles may be apparent on magnetic resonance imaging (MRI) and computed tomography (CT). In approximately 3-5% of patients, the disease follows a severe course with severe pain, inflammation, sight-threatening corneal ulceration, and compressive optic neuropathy.<sup>29</sup>

The clinical manifestations of TAO can be evaluated under the headings of soft tissue inflammation, eyelid retraction, proptosis, restrictive myopathy, and optic neuropathy.

#### Soft Tissue Inflammation

Soft tissue inflammation is often the earliest sign of TAO. Soft tissue involvement consists of periorbital edema, conjunctival hyperemia, chemosis, and superior limbic keratoconjunctivitis (SLK). Symptoms may include foreign body sensation, epiphora, palpebral and conjunctival hyperemia and edema, blurred vision, and retroorbital pain. Periorbital edema may lead to prolapse of the retroseptal adipose tissue into the eyelid, venous circulatory disturbance, and retroseptal infiltration. SLK is characterized by upper tarsal conjunctival papillae, superior bulbar conjunctival hyperemia, limbal papillary hypertrophy, punctate epitheliopathy, and filaments in the upper cornea. Thyroid function tests should be performed for all patients with SLK.

#### Eyelid Retraction

Upper eyelid retraction (Dalrymple's sign) may emerge as an early sign of TAO. Upper eyelid retraction in TAO may be caused by increased sympathetic stimulation of Müller's muscle by thyroid hormone, but may also be attributed to the formation of scar tissue between the levator muscle and surrounding tissues, or to overaction of the levator muscle contracting against a tight inferior rectus muscle (Figure 1).<sup>29</sup> In addition to upper eyelid retraction, upper eyelid lag (von Graefe's sign) is also an important sign. Upper eyelid lag refers to a delay in the upper eyelid following as the eye rotates downward as a patient tracks a moving object. This is also an important criterion in the early diagnosis of TAO.

#### Proptosis

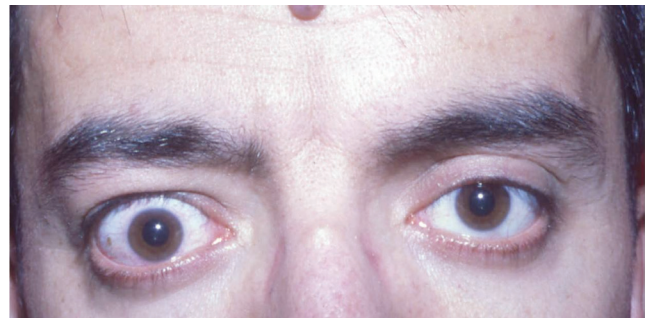Proptosis is spontaneous decompression resulting from enlargement of the extraocular muscles and adipose tissue, as well as orbital fat deposits and the infiltration of orbital tissues by GAGs and leukocytes (Figure 2). TAO is the most common cause of unilateral and bilateral proptosis in adults. It does not respond to hyperthyroidism treatment, and is permanent in 70% of cases. Proptosis is usually (90%) bilateral. Complications such as exposure keratopathy, corneal ulcer, and even corneal perforation may occur in cases of severe proptosis due to the eyelids not fully closing. Upper eyelid retraction may be confused with proptosis. Conditions producing pseudoproptosis include conditions in which the eyeball is enlarged, such as degenerative myopia and congenital glaucoma (buphthalmos), upper eyelid retraction, and contralateral enophthalmos.

#### Restrictive Myopathy

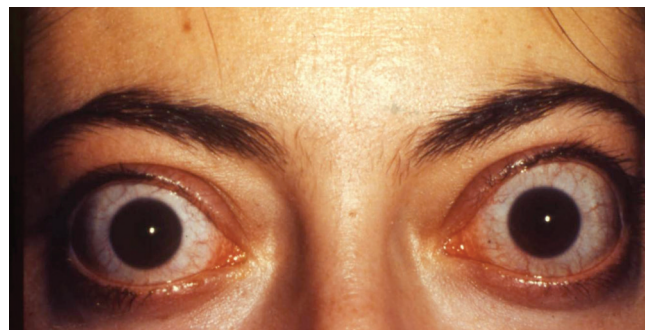Eye movements are restricted due to edema that occurs in the extraocular muscles during the infiltrative stage and the subsequent fibrosis. Diplopia manifesting as the appearance of overlapping images is common. In primary and reading positions, it affects daily activities and causes patients significant discomfort. Despite expansion of the extraocular muscles in TAO, the muscle fibers themselves are normal. Muscle enlargement occurs due to separation of the muscle fibrils by fluid and fat deposits and by GAG material, fibrosis, scar formation, and leukocyte infiltration. Usually a single muscle is involved. While any of the six extraocular muscles may be involved, enlargement of the inferior rectus muscle is seen in most patients (Figure 3), followed by medial and superior rectus muscle involvement (Figure 4).<sup>32</sup> Pressure exerted by a fibrotic inferior rectus muscle on the globe may cause a spike in intraocular pressure during upgaze. In some cases, extraocular muscle fibrosis may also be associated with chronically elevated intraocular pressure.<sup>33</sup>

#### Optic Neuropathy

Optic neuropathy develops as a result of pressure from enlarged muscles on the optic nerve or the vessels that supply it. It may present with gradual decline in visual acuity, color vision disturbance, and central or paracentral scotomas. Fundus examination is usually normal, though optic disc edema, choroidal folds, optic disc paleness may be observed. The presence of optic neuropathy is often not correlated with proptosis.<sup>34</sup>



**Figure 1.** Right upper lid retraction in a 38-year-old male patient. Upper lid retraction (Dalrymple's sign) may be one of the initial signs of thyroid-associated ophthalmopathy

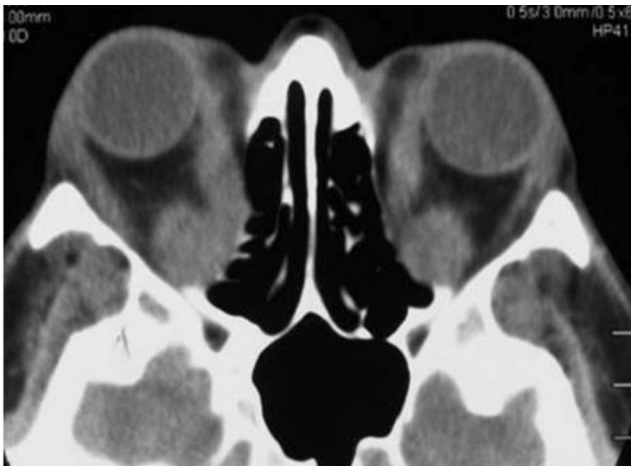

**Figure 2.** Bilateral infiltrative thyroid-associated ophthalmopathy in a 33-year-old female patient. Hertel exophthalmometer values were 28 mm for both eyes

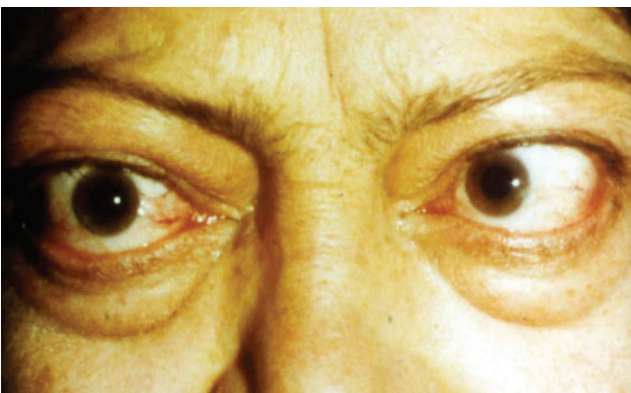
Orbital imaging may be done with ultrasound, CD, or MRI. Ultrasound allows rapid evaluating, but requires an experienced operator. CT and MRI have the advantage of imaging the entire orbit. CT is more sensitive for showing extraocular muscle enlargement. In active disease, the extraocular muscles appear as hyperintense on T2-weighted MRI.<sup>35</sup>

Although the natural course of ophthalmopathy is not fully understood, it has an inflammatory active phase that lasts an average of 3-6 months but may be as long as 3 years, followed by a fibrotic inactive phase. About 1% of patients experience reactivation after a period of inactivity. There is no indicator signaling the beginning of the inactive phase, but stability of clinical findings for a period of 6 months may indicate transition to inactive phase.<sup>36</sup>

In 1969, Werner<sup>36</sup> first systematically classified the clinical characteristics of TAO in order to determine severity of ophthalmopathy. He divided the ocular findings by severity into seven classes, and named the classification system with the acronym "NOSPECS" based on the first letter of each class. The classification was modified in 1977 by the American



**Figure 3.** Orbital computed tomography images showing enlarged inferior and medial rectus muscles in a patient with thyroid-associated ophthalmopathy. The inferior rectus muscle is enlarged, mimicking an orbital tumor



**Figure 4.** Internal rotation of the left eye due to fibrosis of the left medial rectus muscle in a 55-year-old patient with thyroid-associated ophthalmopathy

Thyroid Association.<sup>37</sup> It is not widely used today due to several limitations, including its reliance on subjective criteria, inability to assess disease activity, and the fact that the irregular clinical progression exhibited by most patients does not conform well to the classification system.

In 1989, Mourits et al.<sup>38</sup> developed the Clinical Activity Score (CAS) for evaluating ophthalmopathy activity (Table 1). According to this formula, which includes 10 different inflammatory changes, each finding is scored to yield an activity score between 0 and 10. In 1992, a committee formed by four thyroid societies modified the CAS and reduced the number of criteria. The modified version was published to facilitate the evaluation of ocular changes following ophthalmopathy treatment (Table 2).<sup>39</sup>

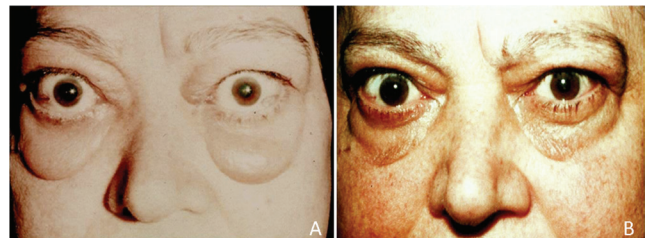According to the European Group on Graves' Orbitopathy (EUGOGO), a CAS score of 3 or higher defines active TAO with a 65% positive predictive value for response to radiotherapy. According to this, it can be expected that patients with higher CAS values will respond better to treatment.<sup>29,40</sup> Regardless, the CAS has certain limitations such as being dependent on the evaluator and being inadequate for following clinical changes.<sup>41</sup>

More recently, Dolman and Rootman<sup>42</sup> developed the VISA classification, based on 4 findings: vision, inflammation, strabismus, and appearance (Table 3). Each parameter is separately graded and scored. Active disease is defined as worsening in any of the VISA parameters. Another classification system most commonly used in evaluating the activity and severity of TAO and making treatment decisions is the EUGOGO classification (Table 4).<sup>43</sup>

#### Treatment

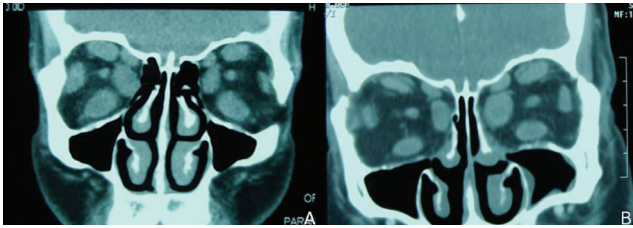
Most TAO patients have mild and nonprogressive ocular involvement which does not require treatment. Less severe ophthalmopathies tend to resolve spontaneously.<sup>3</sup>

Treatment options for TAO can be grouped into medical and surgical therapies. Medical treatment is appropriate for patients with active disease. These treatments are not effective for inactive ophthalmopathy and carry the risk of side effects. Surgical interventions can be implemented in cases where the threat to vision cannot be controlled with medical treatment, and in cases with inactive disease in order to protect function and improve appearance.



**Figure 5.** A 61-year-old female patient with infiltrative thyroid-associated ophthalmopathy. The patient exhibited significant palpebral and conjunctival edema and reported severe pain (A). The same patient showed substantial regression of clinical signs after 3 months of intravenous corticosteroid therapy (B)

Because cigarette smoking increases the severity of ophthalmopathy and reduces treatment response, patients should be urged to quit smoking.<sup>44</sup> Thyroid dysfunction, particularly hypothyroidism, negatively affects ophthalmopathy



**Figure 6.** Coronal computed tomography of a patient with thyroid-associated ophthalmopathy (A). Coronal computed tomography images from the same patient after orbital decompression surgery (B). Postoperative images show the absence of the medial orbital wall and thinning of the cortical bone in the lateral wall

<b>Table 1. Clinical activity score criteria. Active disease is accepted as the presence of 3 or more of the first 7 criteria for patients not examined within the previous 3 months, or 4 or more of the 10 criteria for patients examined within the previous 3 months (Mourits MP, Koornneef L, Wiersinga WM, Prummel MF, Berghout A, van der Gaag R. Clinical criteria for the assessment of disease activity in Graves' ophthalmopathy: a novel approach. Br J Ophthalmol. 1989;73:639-644.)</b>	
<b>Clinical activity score</b>	
1-	Pain or pressure on or behind the globe
2-	Pain on up, down, or side gaze
3-	Redness of the eyelids
4-	Diffuse redness of the conjunctiva
5-	Swelling of the eyelids
6-	Chemosis
7-	Swollen caruncle
8-	Increase in proptosis of $\geq 2$ mm during a period of 1-3 months
9-	Decrease in visual acuity of $\geq 1$ line on Snellen chart during a period of 1-3 months
10-	Decrease in eye movements in any direction of $\geq 5$ degrees during a period of 1-3 months

<b>Table 2. Modified clinical activity score criteria (Pinchera A, Wiersinga W, Glinoeer D, Kendall-Taylor P, Koornneef L, Marocci C, Schleusener H, Romaldini J, Niepominisze H, Nagataki S, Izumi M, Inoue Y, Stockigt J, Wall J, Greenspan F, Solomon D, Garrity J, Gorman CA. Classification of eye changes of Graves' disease. Thyroid. 1992;2:235-236.)</b>	
<b>Modified Clinical Activity Score</b>	
1-	Spontaneous retrobulbar pain
2-	Pain with eye movement
3-	Lid erythema
4-	Conjunctival injection
5-	Chemosis
6-	Swollen caruncle
7-	Lid edema and protrusion

onset; therefore, a euthyroid state must be achieved as quickly as possible and maintained.<sup>45</sup> Euthyroidism may be achieved with antithyroid drugs, radioactive iodine (RAI) therapy, or thyroidectomy. However, it has been shown that RAI therapy leads to new ophthalmopathy development and exacerbates existing ophthalmopathy. This effect does not occur with combined RAI and steroid therapy.<sup>46</sup> The effect of RAI on ophthalmopathy may be explained by two mechanisms. Antigens common to the thyroid and retroorbital tissues may be released due to radiation-induced thyroid damage, and these antigens may play a role in the development of immune-mediated ophthalmopathy. Alternatively, RAI therapy may stimulate the secretion of TSH due to the rapid induction of hypothyroidism, thereby stimulating antigen production by thyrocytes.<sup>47</sup> In contrast, a recent study reported that RAI therapy did not increase the risk of ophthalmopathy development or exacerbation.<sup>48</sup>

Topical lubricants are recommended to protect the cornea and alleviate symptoms of dryness. In addition to using artificial tear drops or gel during the day, at night the eyelids may be taped closed to prevent conjunctival exposure and ointments can be applied. Guanethidine and beta blocker eye drops can be used to treat eyelid retraction. Patients with pronounced periorbital edema may benefit from elevating the head at night. Wearing sunglasses may also provide symptomatic relief. Prismatic spectacles may be prescribed to patients with diplopia.<sup>49</sup> Botulinum toxin injection may provide temporary improvement in upper lid retraction and restrictive myopathy.<sup>50,51</sup>

### Medical Treatment

#### Steroid Therapy

Steroids are still the best medical treatment for active TAO. In addition to their anti-inflammatory and immunosuppressive effects, they also reduce the synthesis and secretion of GAG by orbital fibroblasts. Steroids may be administered via oral, intravenous, retrobulbar, and subconjunctival routes. Retrobulbar and subconjunctival application of steroids is not commonly performed due to side effects and lack of efficacy.<sup>49</sup>

For oral steroids to be effective, high doses (60-100 mg/day or higher prednisolone) and long duration (10-20 weeks) are usually required. Based on treatment response in the first few weeks, the initial dose can be gradually reduced. A decrement of 5-10 mg per week has been shown to be generally safe. However, some patients experience recurrence when medication is reduced or discontinued. Medical treatment has been shown to be effective for soft tissue changes, ocular motility, and optic neuropathy, but its effect on proptosis is limited. Following high-dose steroid therapy, some patients who require steroid treatment again due to trauma, surgery, or infection may develop adrenal insufficiency. Treatment is limited to a few months in patients exhibiting side effects such as Cushingoid appearance, diabetes, hypertension, and osteoporosis. If long-term therapy is required, using nonsteroid immunosuppressants or orbital radiotherapy as supplemental treatment allows the steroid dose to be reduced.<sup>52</sup>

**Table 3. VISA classification (Dolman PJ, Rootman J. VISA classification for Graves orbitopathy. Ophthalm Plast Reconstr Surg. 2006;22:319-324)**

<b>Orbitopati</b>	<b>Thyroid</b>		<b>General</b>	
Time since onset: Progress: Tempo: Symptoms: Therapy:	Time since onset: Progress: Status: Symptoms: Anti-thyroid meds: Radioactive iodine:		Smoking Family Hx: Medical Hx: Allergies: Meds:	
Subjective	Objective	Right	Left	
Vision Vision n/abn Color vis: n/abn Fundus	Central vision: with manifest Color vision errors Pupils (afferent defect) Optic nerve: Edema Pallor	20/ 20/ y/n y/n y/n	20/ 20/ y/n y/n y/n	Refractions Wearing Manifest
Inflammatory Retrobulbar ache At rest (0-1) With gaze (0-1) Lid swelling y/n	Chemosis (0-2) Conjunctival injection (0-1) Lid injection (0-1) Lid edema upper (0-2) Lower (0-2)			Inflammatory index Chemosis (0-2): Conjunctival injection (0-1): Lid injection (0-1): Lid edema (0-2): Retrobulbar ache (0-2): Total (8):
Strabismus/Motility Diplopia: None (0) With gaze (1) Intermittent (2) Constant (3) Head turn: y/n	Duction (degrees): Restriction >45° 30-45° 15-30° <15°	0 1 2 3	0 1 2 3	Prism Measure
Appearance Lid retraction y/n Proptosis y/n Tearing y/n FB sensation y/n	Lid retraction (upper): (lower scleral show): Levator function Lagophthalmos Exophthalmometry Corneal erosions Corneal ulcers IOP -straight -up	mm mm mm mm mm y/n y/n mmHg mmHg	mm mm mm mm mm y/n y/n mmHg mmHg	
<b>Disease Grading</b> V (optic neuropathy) I (inflammation) 0-8 S (strabismus) 0-3 (restriction) 0-3 A (appearance/exposure)	<b>Grade</b> y/n /8 /3 /3 mild/mod/severe			

Intravenous steroids are often administered at a high dose (0.5-1 g methyl prednisolone) for 3 days, followed by oral prednisolone. Giving intravenous pulse steroids in 1- or 2-week cycles has been determined more effective than oral steroids (Figure 5A, 5B). Studies comparing the efficacy of oral and intravenous steroids have reported that intravenous steroids are superior in reducing CAS, and that steroid-related side effects such as Cushingoid appearance, diabetes, hypertension, osteoporosis, and gastric irritation are more common with oral

steroids.<sup>52</sup> In a controlled study comparing intravenous and oral steroid therapy, Kahaly et al.<sup>53</sup> compared a group that received intravenous 500 mg methyl prednisolone once a week for 6 weeks, followed by 250 mg methyl prednisolone once a week for 6 weeks (total 4.5 g) with a group that received oral prednisolone starting at 100 mg/day and reduced by 10 mg per week over 12 weeks (total 4 g). Treatment response was defined as reductions in proptosis, palpebral aperture, ocular pressure, and rectus muscle width; improvement in diplopia;

**Table 4. Treatment algorithm for thyroid-associated ophthalmopathy (Barrio-Barrio J, Sabater AL, Bonet-Farriol E, Velázquez-Villoria Á, Galofré JC. Graves' ophthalmopathy: VISA versus EUGOGO classification, assessment and management. J Ophthalmol. 2015;2015:249125)**

All patients		1. Restore euthyroidism 2. Urge to quit smoking	
Severity	Active	Inactive	
Mild	Artificial tears Sunglasses Elevating head of bed Prismatic glasses	Artificial tears Prismatic glasses Surgical Müllerectomy Blepharoplasty	
Moderate-severe	Intravenous methylprednisolone In patients resistant to steroids: cyclosporin A plus oral steroid, immunosuppressive therapies, anti-cytokine/lymphocyte agents If motility dysfunction is pronounced: orbital radiotherapy	Orbital decompression Strabismus surgery Palpebral surgery	
Threat to vision  Optic neuropathy	Intravenous methylprednisolone, 1 gr for 3 days If nonresponsive: orbital decompression +/- intravenous steroid +/- radiotherapy	Urgent surgical decompression	
Severe corneal involvement	Intravenous steroid, lubrication, tarsorrhaphy orbital decompression	Lateral tarsorrhaphy, orbital decompression, amniotic membrane transplant, keratoplasty	

and increase in visual acuity. The authors reported that 77% of patients in the intravenous group and 60% of patients in the oral group responded to treatment. During 6 months of follow-up, the group that received oral steroids required surgical intervention and exhibited optic neuropathy more often. Macchia et al.<sup>54</sup> conducted a study comparing treatment with intravenous 1 g methyl prednisolone twice a week for 6 weeks and treatment with oral prednisolone starting at 60-80 mg/day and reduced every other week over 4-6 months. In both groups, there was marked reduction in orbital inflammation symptoms and findings, and substantial improvement in proptosis and diplopia. The oral steroid group exhibited side effects related to treatment. In another study, 3-day pulse 1 g methyl prednisolone followed by 3-month oral prednisolone therapy was compared with oral prednisolone therapy alone, and no differences in diplopia, proptosis, or soft tissue activity score were found.<sup>55</sup> An advantage of pulse intravenous steroid therapy is that treatment response may be seen within 1-2 weeks. Intravenous steroids are most effective in reducing inflammatory soft tissue findings and ocular motility dysfunction. However, rare cases that developed acute, severe liver failure during pulse steroid therapy have been documented. The cumulative methyl prednisolone dose in these cases was 10-24 g. This acute liver damage was found to be associated with previous viral hepatitis. Sudden discontinuation of intravenous steroid therapy may exacerbate underlying autoimmune liver disease. Therefore, it is advisable to limit the cumulative methyl prednisolone dose to 6-8 mg and identify patients at risk by evaluating liver morphology, viral markers, and autoantibodies prior to treatment.<sup>52,56,57</sup>

### Orbital Radiotherapy

Orbital radiotherapy is used in the management of ophthalmopathy due to its nonspecific anti-inflammatory effects, its reduction of GAG production, and the high radiosensitivity of the lymphocytes that infiltrate orbital tissue.<sup>58</sup> The main benefit of orbital radiation therapy is the improvement of ocular motility. In the treatment of ophthalmopathy, orbital radiotherapy (cumulative dose of 20 Gy in 10 divided fractions) was shown to be equivalent to placebo in terms of activity score, proptosis, and lid retraction, and superior to placebo in the correction of diplopia.<sup>59</sup> In general, treatment is administered as 1500-2000 cGy divided over 10 days. A study comparing the efficacy of high- and low-dose radiation (16 Gy versus 2.4 Gy and 20 Gy versus 10 Gy) reported no marked difference in effect and stated that the radiotherapy dose should not exceed 2.4 Gy for TAO.<sup>60</sup> It may take a few weeks for the effect of radiation to become apparent; the effect is temporary and may cause an increase in inflammation. Therefore, steroid therapy should be continued in the first few weeks of treatment. The effect is gradual initially and reaches a peak after 6 months. The main side effect is early onset cataract. It may also cause radiation retinopathy and radiation-induced optic neuropathy. These complications are not common when the dose is properly divided and the eyes are closed. Marquez et al.<sup>61</sup> followed patients for an average of 11 years after radiation therapy and determined a 12% rate of cataract development. Diabetes is considered a relative contraindication for radiation due to the risk of exacerbating retinopathy.<sup>62</sup>

It was reported that combined orbital radiotherapy and systemic steroid therapy was substantially more effective than radiotherapy or steroid therapy alone.<sup>63</sup> Although orbital radiotherapy and oral steroid therapy have similar efficacy, side effects are reported to occur more often with steroids.<sup>64</sup>

#### Immunosuppressive Therapies

Due to the autoimmune mechanism of TAO, various immunosuppressive drugs such as cyclosporin, azathioprine, and cyclophosphamide, as well as immunomodulatory agents like ciamexon have been used in treatment. Cyclosporin is the most commonly used immunosuppressive drug in the treatment of ophthalmopathy. Cyclosporin acts by inhibiting cytotoxic T lymphocyte activation and antigen presentation by monocyte and macrophages, which in turn activates suppressor T lymphocytes and inhibits cytokine production. Compared to oral steroid therapy alone, supplementation of oral steroid therapy with cyclosporin results in a greater reduction in activity score, provides marked improvement in proptosis and diplopia, and reduces the relapse rate after discontinuation of steroid therapy.<sup>65</sup> There is no consensus on the efficacy of azathioprine therapy in ophthalmopathy. Despite a reduction in thyroid-associated antibodies in patients receiving azathioprine, no difference was observed in clinical parameters compared to a control group.<sup>66</sup> There are case reports in the literature demonstrating clinical and immunologic improvement with intravenous cyclophosphamide in patients resistant to steroid therapy and/or radiotherapy.<sup>67,68,69</sup>

Treating ophthalmopathy with agents such as octreotide, pentoxifylline, nicotinamide, plasmapheresis, and intravenous immunoglobulin (IVIg) has been attempted, but these are not among the main treatment methods.

#### Somatostatin Analogues

Octreotide is a synthetic somatostatin analogue, and octreoscan-111 positivity may reflect TAO activity and be predictive of treatment response.<sup>70</sup> In a study conducted in France, a reduction in CAS was observed in patients treated with extended-release octreotide. Despite a significant reduction in proptosis, the authors reported that octreotide was not effective in mitigating the activity of mild TAO.<sup>71</sup> Although there are some cases in which octreotide resulted in improvement in soft tissue findings, many studies have demonstrated that it is not adequately effective.<sup>70,72,73</sup> Due to octreotide's short half-life, the long-acting somatostatin analogue lanreotide was developed. Lanreotide administered every other week for 3 months was shown to be effective in the treatment of ophthalmopathy, particularly soft tissue findings.<sup>74</sup>

#### Pentoxifylline and Nicotinamide

The beneficial effects of pentoxifylline and nicotinamide in the treatment of ophthalmopathy have been demonstrated in a limited number of studies. Both agents are believed to act by inhibiting fibroblast GAG synthesis induced cytokines. Compared to a control group, pentoxifylline was reported to be effective in reducing inflammatory symptoms and correcting proptosis.<sup>75,76</sup>

#### Intravenous Immunoglobulin

The role of plasmapheresis and IVIg in the treatment of ophthalmopathy has yet to be definitively determined. While some studies have shown that IVIg therapy has a similar effect to oral steroid therapy and radiotherapy in patients with active TAO,<sup>77</sup> Seppel et al.<sup>78</sup> reported that IVIg therapy was ineffective against ophthalmopathy.

#### Plasmapheresis

Plasmapheresis aims to remove the immunoglobulins and immunocomplexes involved in TAO pathogenesis. When performed in combination with immunosuppressive therapy in 4 sessions within a period of 5-8 days, significant improvement was noted in clinical signs of ophthalmopathy; however, after 1 year, recurrence occurred in some patients and treatment was repeated.<sup>79</sup> Plasmapheresis may be used as a last resort for severe TAO when all other treatments have failed.

#### Anticytokine and Antilymphocyte Antibodies

Anticytokine and antilymphocyte monoclonal antibodies are a new therapeutic approach which may be applied in patients who do not respond to conventional immunosuppressive therapies.<sup>68</sup> There are studies in the literature demonstrating the efficacy of anti-tumor necrosis factor alpha (anti-TNF $\alpha$ ) monoclonal antibodies (etanercept, infliximab), anti-CD-25 antibody (daclizumab), and anti-B lymphocyte antibody (rituximab) against inflammatory symptoms of ophthalmopathy.<sup>69,80,81</sup> Targeting TNF may affect the production of chemoattractant protein 1 and macrophage-attracting protein by preadipocytes in TAO.<sup>29</sup> The monoclonal antibody rituximab, which inhibits active B cells, seems promising.<sup>82</sup> A study demonstrated that rituximab therapy resulted in a significant decrease in the stimulatory anti-thyrotropin receptor antibody subgroup.<sup>83</sup>

Topical 5% guanethidine drops were previously used to treat upper eyelid retraction, but is not used in contemporary practice.<sup>84</sup>

#### Surgical Therapy

Approximately 5% of TAO patients require surgical intervention. Necessary procedures should be performed in the following order: orbital decompression, strabismus surgery, lid lengthening surgery, and blepharoplasty.

Orbital decompression surgery consists of enlarging the bony orbit, extracting orbital adipose tissue, or a combination of the two. Indications for the procedure are compressive optic neuropathy that does not respond to steroid therapy or orbital radiotherapy, or prominent proptosis which will lead to severe corneal involvement.<sup>1</sup> It should not be performed during the active stage of the disease. A recent randomized, controlled study compared surgical versus medical decompression as initial treatment in cases with optic neuropathy and showed that urgent decompression surgery did not yield better outcomes than steroid therapy. In the presence of optic neuropathy, the first choice of treatment should be intravenous followed by oral steroid therapy.<sup>85</sup> The goal of decompression surgery is to increase the volume of the bony orbit, thereby directly relieving apical pressure as much as possible. Commonly used techniques

are removal of the medial and inferior wall, removal of the inferomedial and lateral wall, balanced removal of the medial and lateral wall, and deep lateral wall decompression. Although decompression can be achieved through the medial orbital wall, force applied by the retractors can increase the already high retrobulbar pressure and exceed a critical level for the optic nerve fibers. Preventative removal of the lateral wall facilitates access to the deep orbit and reduces the risk of elevated orbital pressure. Transcaruncular or inferior fornix approaches in medial wall removal prevent scar formation. The endoscopic transnasal approach is an alternative that provides apical access without increasing intraorbital floor.<sup>86</sup> The main disadvantage of the antral-ethmoidal decompression with transantral approach described in 1957 by De Santo<sup>87</sup> is the resulting motility dysfunction in 52% of cases. For patients with moderate exophthalmos, antral-ethmoidal decompression via the eyelid is a valid alternative due to the low risk of iatrogenic diplopia (4.6%). With more severe exophthalmos, combined inferomedial decompression and lateral decompression may be performed.<sup>86</sup> In 1989, Leone et al.<sup>88</sup> recommended balanced removal of the medial and lateral walls in order to reduce strabismus after decompression. Although this technique was considered to theoretically reduce the risk of iatrogenic diplopia, the risk was determined to be higher than that in removal of the lateral wall alone or with the inferomedial wall, as well as 3-wall removal.<sup>89</sup> Medial wall, orbital floor, and lateral wall removal continue to be preferred in contemporary bony decompression surgery (Figure 6A, 6B). Removal of the orbital roof is no longer practiced because it contributes minimally to orbital enlargement and carries the risk of potential complications and side effects. Minimally invasive approaches and hidden incisions in the conjunctiva or at the upper eyelid fold are preferred. According to exophthalmos severity, lateral wall decompression and/or adipose tissue removal, especially from the inferolateral quadrant, may be performed in addition to inferomedial decompression. To decrease postoperative diplopia, lateral wall removal with or without fat excision is recommended first, followed by medial and inferior wall removal if necessary.<sup>86</sup> Recently, deep lateral wall removal has been described as a part of a rehabilitative 3-wall decompression with coronal approach. A 32% reduction in exophthalmos was reported with this technique, without increasing the risk of consecutive diplopia compared to conventional 3-wall decompression. However, some claim that the volume of the deep lateral wall is highly variable between individuals and may not always provide sufficient orbital volume.<sup>90</sup>

A different approach to decompression of the orbital contents involves removing orbital fat in addition to medial or inferolateral orbitotomy. A mean reduction in proptosis of 1.8 mm (0-6 mm) was reported using this technique.<sup>91</sup> Combining fat removal with bony decompression has gained popularity in recent years, and is superior to either fat or bone removal alone in terms of safety and effectiveness.<sup>86</sup>

Fat removal orbital decompression confers greater risk of damaging the oculomotor nerve ciliary branch, lacrimal nerve, orbital vasculature, extraocular muscles, optic nerve

and globe than bony decompression. Rare complications of bony decompression include consecutive strabismus; infraorbital hypoesthesia; sinusitis; lower lid entropion; cerebrospinal fluid leakage; central nervous system infections; damage to the globe, optic nerve, or vasculature; cerebral vasospasm; ischemia; and infarct.<sup>86</sup> Another rare (1.3%) complication reported in recent years is TAO reactivation following rehabilitative bony decompression. This phenomenon is characterized by active TAO symptoms and findings emerging a few weeks after a normal postoperative recovery period in patients not under perioperative steroid therapy and was named 'delayed decompression-related reactivation'. It is treated with systemic immunosuppression or radiotherapy.<sup>92</sup>

Extraocular muscle surgery is performed to correct diplopia. The disease should be stable for 6 months. The muscle that most often requires corrective surgery is the inferior rectus, followed by the medial rectus. Adjustable sutures should be preferred. This reduces the need for multiple operations, which is not uncommon. Surgeries involving more than one muscle should be avoided and recession procedures should be preferred over resection in order to prevent ocular ischemic syndrome. Factors which may lead to surgical failure are tightness and hemorrhagic tendency of the extraocular muscles, potential postoperative scarring, and restricted access to the surgical area due to lid edema.<sup>93</sup> Strabismus surgery is necessary for most patients with severe ophthalmopathy to restore binocular single vision in primary position and while reading.

Eyelid surgery is performed as an emergency procedure (tarsorrhaphy) in patients with exposure keratitis or corneal ulcer, or often for rehabilitation and in cases of lid malformation. Patients should be euthyroid and ophthalmopathy should be stable and inactive for 6-12 months before surgery. Müller's muscle excision or recession is often adequate for treating upper lid retraction. Recession of the levator aponeurosis or levator myotomy may be performed.<sup>94</sup> Lower lid retraction may be corrected by recession of the lid retractors with the insertion of acellular dermal, tarsal, or conjunctival spacer material.<sup>95</sup>

The treatment plan for TAO should be determined individually for each patient. Timely diagnosis is critical for patients at risk for developing serious complications like restrictive myopathy and optic neuropathy. High-risk patients (such as older patients, males, diabetics, and smokers), those with family history of ophthalmopathy, and patients with moderate inflammatory signs should be followed closely. Urgent interventions are necessary for patients with color or central vision loss, progressive diplopia, or severe inflammatory signs.<sup>43</sup>

In light of the current literature, management of TAO may follow the following algorithm: Euthyroidism should be achieved in all patients with TAO and they should be strongly encouraged to quit if they smoke cigarettes. In cases of mild disease, treatments and practices such as topical lubricants, wearing sunglasses, elevating the head during sleep, and using prismatic glasses or botulinum toxin injection to Müller's muscle for diplopia may provide symptomatic

relief. With moderate and severe disease, most patients show improvement in inflammatory soft tissue changes and muscle motility dysfunction with intravenous steroid therapy. For patients who do not respond to steroid therapy, immunosuppressive therapies (oral steroids combined with cyclosporin or cyclophosphamide) are an option, and orbital radiotherapy may be preferred for patients with pronounced ocular motility dysfunction. Antilymphocyte antibody (rituximab) may be tried in patients who do not respond to conventional immunosuppressive therapy. In moderate and severe inactive disease, orbital decompression surgery, strabismus surgery, recession of the levator or lid retractors, and blepharoplasty may be performed as necessary in the specified order. For active disease with sight-threatening severe exposure keratopathy, severe proptosis, or compressive optic neuropathy, patients who do not respond to intravenous pulse steroid therapy followed by oral steroid therapy or orbital radiotherapy are candidates for urgent orbital decompression surgery. Patients with severe corneal involvement may also benefit from procedures such as lateral tarsorrhaphy, amniotic membrane transplantation, and keratoplasty.<sup>43</sup>

## Conclusion

TAO is an autoimmune disease with significant impact on quality of life. Although in most patients ophthalmopathy is mild and nonprogressive, it is of the utmost importance that patients at risk be followed closely and treated appropriately and in a timely manner based on disease severity and activity.

## Ethics

Peer-review: Externally peer-reviewed.

## Authorship Contributions

Surgical and Medical Practices: Kaan Gündüz, Concept: Esra Şahlı, Design: Kaan Gündüz, Data Collection or Processing: Esra Şahlı, Analysis or Interpretation: Esra Şahlı, Kaan Gündüz, Literature Search: Esra Şahlı, Kaan Gündüz, Writing: Esra Şahlı.

Conflict of Interest: No conflict of interest was declared by the authors.

Financial Disclosure: The authors declared that this study received no financial support.

## References

- Ginsberg J. Diagnosis and management of Graves' disease. *CMAJ*. 2003;168:575-585.
- Bartalena L, Tanda ML, Bogazzi F, Piantanida E, Lai A, Martino E. An update on the pharmacological management of hyperthyroidism due to Graves' disease. *Expert Opin Pharmacother*. 2005;6:851-861.
- Bartalena L, Pinchera A, Marcocci C. Management of Graves' ophthalmopathy: reality and perspectives. *Endocr Rev*. 2000;21:168-199.
- Marcocci C, Bartalena L, Bogazzi F, Panicucci M, Pinchera A. Studies on the occurrence of ophthalmopathy in Graves' disease. *Acta Endocrinol (Copenh)*. 1989;120:473-478.
- Bartalena L, Marcocci C, Pinchera A. Graves' ophthalmopathy: a preventable disease? *Eur J Endocrinol*. 2002;146:457.
- McGregor AM. Has the target autoantigen for Graves' ophthalmopathy been found? *Lancet*. 1998;352:595-596.
- Salvi M, Miller A, Wall JR. Human orbital tissue and thyroid membranes express a 64 kDa protein which is recognized by autoantibodies in the serum of patients with thyroid-associated ophthalmopathy. *FEBS Lett*. 1988;232:135-139.
- Gopinath B, Wescombe L, Nguyen B, Wall JR. Can autoimmunity against calsequestrin explain the eye and eyelid muscle inflammation of thyroid eye disease. *Orbit*. 2009;28:256-261.
- Wall JR, Lahooti H. Pathogenesis of thyroid eye disease--does autoimmunity against the TSH receptor explain all cases? *Endokrynol Pol*. 2010;61:222-227.
- Heufelder AE. Pathogenesis of Graves' ophthalmopathy: recent controversies and progress. *Eur J Endocrinol*. 1995;132:532-541.
- Korducki JM, Loftus SJ, Bahn RS. Stimulation of glycosaminoglycan production in cultured human retroocular fibroblasts. *Invest Ophthalmol Vis Sci*. 1992;33:2037-2042.
- Sorisky A, Pardasani D, Gagnon A, Smith TJ. Evidence of adipocyte differentiation in human orbital fibroblasts in primary culture. *J Clin Endocrinol Metab*. 1996;81:3428-3431.
- Kumar S, Schiefer R, Coenen MJ, Bahn RS. A stimulatory thyrotropin receptor antibody (M22) and thyrotropin increase interleukin-6 expression and secretion in Graves' orbital preadipocyte fibroblasts. *Thyroid*. 2010;20:59-65.
- Eckstein AK, Plicht M, Lax H, Neuhäuser M, Mann K, Lederbogen S, Heckmann C, Esser J, Morgenthaler NG. Thyrotropin receptor autoantibodies are independent risk factors for Graves' ophthalmopathy and help to predict severity and outcome of the disease. *J Clin Endocrinol Metab*. 2006;91:3464-3470.
- Ardley M, Mc Corquodale T, Lahooti H, Champion B, Wall JR. Eye findings and immunological markers in probands and their euthyroid relatives from a single family with multiple cases of thyroid autoimmunity. *Thyroid Res*. 2012;5:4.
- Brix TH, Kyvik KO, Christensen K, Hegedüs L. Evidence for a major role of heredity in Graves disease: a population based study of two Danish twin cohorts. *J Clin Endocrinol Metab*. 2001;86:930-934.
- Wang Y, Smith TJ. Current concepts in the molecular pathogenesis of thyroid associated ophthalmopathy. *Invest Ophthalmol Vis Sci*. 2014;55:1735-1748.
- Syed AA, Simmonds MJ, Brand OJ, Franklyn JA, Gough SCL, Heward JM. Preliminary evidence for interaction of PTPN12 polymorphism with TSHR genotype and association with Graves' ophthalmopathy. *Clin Endocrinol (Oxf)*. 2007;67:663-667.
- Chong KK, Chiang SW, Wong GW, Tam PO, Ng TK, Hu YJ, Yam GH, Lam DS, Pang CP. Association of CTLA-4, IL-13 Gene polymorphism with Graves' disease and ophthalmopathy in Chinese children. *Invest Ophthalmol Vis Sci*. 2008;49:2409-2415.
- Huber AK, Jacobson EM, Jazdzewski K, Concepcion ES, Tomer Y. Interleukin (IL)-23 receptor is a major susceptibility gene for Graves' ophthalmopathy: the IL-23/T-helper 17 axis extends to thyroid autoimmunity. *J Clin Endocrinol Metab*. 2008;93:1077-1081.
- Brand OJ, Gough SC. Genetics of thyroid autoimmunity and the role of the TSHR. *Mol Cell Endocrinol*. 2010;322:135-143.
- Zhang J, Xiao XW, Zhu FY, Muhali FS, Xiao L, Jiang WJ, Shi XH, Zhou LH, Zhang JA. Polymorphisms of interleukin-21 and interleukin-21-receptor genes confer risk for autoimmune thyroid diseases. *BMC Endocr Disord*. 2013;13:26.
- Kurylowicz A, Hiromatsu Y, Jurecka-Lubieniecka B, Kula D, Kowalska M, Ichimura M, Koga H, Kaku H, Bar-Andziak E, Nauman J, Jarzab B, Ploski R, Bednarczuk T. Association of NFKB1 -94ins/del ATTG promoter polymorphism with susceptibility to and phenotype of Graves' disease. *Genes Immun*. 2007;8:532-538.
- Akaishi PM, Cruz AA, Silva FL, Rodrigues Mde L, Maciel LM, Donald EA. The role of major histocompatibility complex alleles in the susceptibility of Brazilian patients to develop the myogenic type of Graves' orbitopathy. *Thyroid*. 2008;18:443-447.
- Whitson RH, Tsark W, Huang TH, Itakura K. Neonatal mortality and leanness in mice lacking the ARID transcription factor Mrf-2. *Biochem Biophys Res Commun*. 2003;312:997-1004.



26. Heard-Costa NL, Zillikens MC, Monda KL, Johansson A, Harris TB, Fu M, Haritunians T, Feitosa MF, Aspelund T, Eiriksdottir G, Garcia M, Launer LJ, Smith AV, Mitchell BD, McArdle PF, Shuldiner AR, Bielinski SJ, Boerwinkle E, Brancati F, Demerath EW, Pankow JS, Arnold AM, Chen YD, Glazer NL, McKnight B, Psaty BM, Rotter JI, Amin N, Campbell H, Gyllenstein U, Pattaro C, Pramstaller PP, Rudan I, Struchalin M, Vitart V, Gao X, Kraja A, Province MA, Zhang Q, Atwood LD, Dupuis J, Hirschhorn JN, Jaquish CE, O'Donnell CJ, Vasan RS, White CC, Aulchenko YS, Estrada K, Hofman A, Rivadeneira F, Uitterlinden AG, Witteman JC, Oostra BA, Kaplan RC, Gudnason V, O'Connell JR, Borecki IB, van Duijn CM, Cupples LA, Fox CS, North KE. NRXN3 is a novel locus for waist circumference: a genome-wide association study from the CHARGE Consortium. *PLoS Genet.* 2009;5:e1000539.
27. Stefan M, Jacobson EM, Huber AK, Greenberg DA, Li CW, Skrabanek L, Conception E, Fadlalla M, Ho K, Tomer Y. Novel variant of thyroglobulin promoter triggers thyroid autoimmunity through an epigenetic interferon alpha-modulated mechanism. *J Biol Chem.* 2011;286:31168-31179.
28. Lahooti H, Cultrone D, Edirimanne S, Walsh JP, Delbridge L, Cregan P, Champion P, Wall JR. Novel single-nucleotide polymorphisms in the calcystrin-1 gene are associated with Graves' ophthalmopathy and Hashimoto's thyroiditis. *Clin Ophthalmol.* 2015;9:1731-1740.
29. Bahn RS. Graves' ophthalmopathy. *N Engl J Med.* 2010;362:726-738.
30. Cawood TJ, Moriarty P, O'Farrelly C, O'Shea D. Smoking and thyroid-associated ophthalmopathy: A novel explanation of the biological link. *J Clin Endocrinol Metab.* 2007;92:59-64.
31. Eckstein A, Quadbeck B, Mueller G, Rettenmeier AW, Hoermann R, Mann K, Steuhl P, Esser J. Impact of smoking on the response to treatment of thyroid associated ophthalmopathy. *Br J Ophthalmol.* 2003;87:773-776.
32. Bartley GB, Fatourechi V, Kadras EF, Jacobsen SJ, Ilstrup DM, Garrity JA, Gorman CA. Clinical features of Graves' ophthalmopathy in an incidence cohort. *Am J Ophthalmol.* 1996;121:284-290.
33. Konuk O, Onaran Z, Ozhan Oktar S, Yucler C, Unal M. Intraocular pressure and superior orbital vein blood flow velocity in Graves' orbitopathy: relation with the clinical features. *Graefes Arch Clin Exp Ophthalmol.* 2009;247:1555-1559.
34. McKeag D, Lane C, Lazarus JH, Baldeschi L, Boboridis K, Dickinson AJ, Hullo AI, Kahaly G, Krassas G, Marcocci C, Marinò M, Mourits MP, Nardi M, Neoh C, Orgiazzi J, Perros P, Pinchera A, Pitz S, Prummel MF, Sartini MS, Wiersinga WM; European Group on Graves' Orbitopathy (EUGOGO). Clinical features of dysthyroid optic neuropathy: a European Group on Graves' Orbitopathy (EUGOGO) survey. *Br J Ophthalmol.* 2007;91:455-458.
35. Ahn ES, Subramanian PS. Treatment modalities of thyroid related orbitopathy. *Indian J Ophthalmol.* 2014;62:999-1002.
36. Werner SC. Classification of the eye changes of Graves' disease. *J Clin Endocrinol Metab.* 1969;29:982-984.
37. Werner SC. Modification of the classification of the eye changes of Graves' disease: recommendations of the Ad Hoc Committee of the American Thyroid Association. *J Clin Endocrinol Metab.* 1977;44:203-204.
38. Mourits MP, Koornneef L, Wiersinga WM, Prummel MF, Berghout A, van der Gaag R. Clinical criteria for the assessment of disease activity in Graves' ophthalmopathy: a novel approach. *Br J Ophthalmol.* 1989;73:639-644.
39. Pinchera A, Wiersinga W, Glinier D, Kendall-Taylor P, Koornneef L, Marcocci C, Schleusener H, Romaldini J, Niepominiszce H, Nagataki S, Izumi M, Inoue Y, Stockigt J, Wall J, Greenspan F, Solomon D, Garrity J, Gorman CA. Classification of eye changes of Graves' disease. *Thyroid.* 1992;2:235-236.
40. Mourits MP, Prummel MF, Wiersinga WM, Koornneef L. Clinical activity score as a guide in the management of patients with Graves' ophthalmopathy. *Clin Endocrinol (Oxf).* 1997;47:9-14.
41. Tortora F, Cirillo M, Ferrara M, Belfiore MP, Carella C, Caranci F, Cirillo S. Disease activity in Graves' Ophthalmopathy: Diagnosis with orbital MR imaging and correlation with clinical score. *Neuroradiol J.* 2013;26:555-564.
42. Dolman PJ, Rootman J. VISA classification for Graves orbitopathy. *Ophthalm Plast Reconstr Surg.* 2006;22:319-324.
43. Barrio-Barrio J, Sabater AL, Bonet-Farriol E, Velazquez-Villoria A, Galofre JC. Graves' ophthalmopathy: VISA versus EUGOGO classification, assessment and management. *J Ophthalmol.* 2015;2015:249125.
44. Thornton J, Kelly SP, Harrison RA, Edwards R. Cigarette smoking and thyroid eye disease: a systematic review. *Eye.* 2007;21:1135-1145.
45. Bartalena L, Marcocci C, Bogazzi F, Manetti L, Tanda ML, Dell'Unto E, Bruno, Bossio G, Nardi M, Bartolomei MP, Lepri A, Rossi G, Martino E, Pinchera A. Relation between therapy for hyperthyroidism and the course of Graves' ophthalmopathy. *N Engl J Med.* 1998;338:73-78.
46. Perros P, Kendall-Taylor P, Neoh C, Frewin S, Dickinson J. A prospective study of the effects of radioiodine therapy for hyperthyroidism in patients with minimally active Graves' ophthalmopathy. *J Clin Endocrinol Metab.* 2005;90:5321-5323.
47. Walsh JP, Dayan CM, Potts MJ. Radioiodine and thyroid eye disease. *BMJ.* 1999;319:68-69.
48. El-Kaissi S, Bowden J, Henry MJ, Yeo M, Champion BL, Brochie P, Nicholson GC, Wall JR. Association between radioiodine therapy for Graves' hyperthyroidism and thyroid-associated ophthalmopathy. *Int Ophthalmol.* 2010;30:397-405.
49. Dickinson J, Perros P. Thyroid-associated orbitopathy: who and how to treat. *Endocrinol Metab Clin North Am.* 2009;38:373-388.
50. Uddin JM, Davies PD. Treatment of upper eyelid retraction associated with thyroid eye disease with subconjunctival botulinum toxin injection. *Ophthalmology.* 2002;109:1183-1187.
51. Kikkawa DO, Cruz RC Jr, Christian WK, Rikkers S, Weinreb RN, Levi L, Granet DB. Botulinum A toxin injection for restrictive myopathy of thyroid-related orbitopathy: effects on intraocular pressure. *Am J Ophthalmol.* 2003;135:427-431.
52. Kahaly GJ. Management of moderately severe Graves' orbitopathy. In: Wiersinga WM, Kahaly GJ, eds. *Graves orbitopathy: A multidisciplinary approach.* Basel; Karger; 2007:120-152.
53. Kahaly GJ, Pitz S, Hommel G, Dittmar M. Randomized, single blind trial of intravenous versus oral steroid monotherapy in Graves' orbitopathy. *J Clin Endocrinol Metab.* 2005;90:5234-5240.
54. Macchia PE, Bagattini M, Lupoli G, Vitale M, Vitale G, Fenzi G. High-dose intravenous corticosteroid therapy for Graves' ophthalmopathy. *J Endocrinol Invest.* 2001;24:152-158.
55. Kauppinen-Makelin R, Karma A, Leinonen E, Löyttyniemi E, Salonen O, Sane T, Setälä K, Viikari J, Heufelder A, Välimäki M. High dose intravenous methylprednisolone pulse therapy versus oral prednisone for thyroid-associated ophthalmopathy. *Acta Ophthalmol Scand* 2002;80:316-321.
56. Aktaran S, Akarsu E, Erbağci I, Araz M, Okumuş S, Kartal M. Comparison of intravenous methylprednisolone therapy vs. oral methylprednisolone therapy in patients with Graves' ophthalmopathy. *Int J Clin Pract.* 2007;61:45-51.
57. Marcocci C, Bartalena L, Tanda ML, Manetti L, Dell'Unto E, Rocchi R, Barbesino G, Mazzi B, Bartolomei MP, Lepri P, Cartei F, Nardi M, Pinchera A. Comparison of the effectiveness and tolerability of intravenous or oral glucocorticoids associated with orbital radiotherapy in the management of severe Graves' ophthalmopathy: results of a prospective, single-blind, randomized study. *J Clin Endocrinol Metab.* 2001;86:3562-3567.
58. Bartalena L, Marcocci C, Manetti L, Tanda ML, Dell'Unto E, Rocchi R, Cartei F, Pinchera A. Orbital radiotherapy for Graves' ophthalmopathy. *Thyroid.* 1998;8:439-441.
59. Prummel MF, Terwee CB, Gerding MN, Baldeschi L, Mourits MP, Blank L, Dekker FW, Wiersinga WM. A randomized controlled trial of orbital radiotherapy versus sham irradiation in patients with mild Graves' ophthalmopathy. *J Clin Endocrinol Metab.* 2004;89:15-20.
60. Gerling J, Kommerell G, Henne K, Laubenberger J, Schulte-Mönting J, Fells P. Retrobulbar irradiation for thyroid-associated orbitopathy: double-blind comparison between 2.4 and 16 Gy. *Int J Radiat Oncol Biol Phys.* 2003;55:182-189.
61. Marquez SD, Lum BL, McDougal IR, Katkuri S, Levin PS, MacManus M, Donaldson SS. Long-term results of irradiation for patients with progressive Graves' ophthalmopathy. *Int Radiat Oncol Biol Phys.* 2001;51:766-774.

62. Wakelkamp IM, Tan H, Saeed P, Schlingemann RO, Verbraak FD, Blank LE, Prummel MF, Wiersinga WM. Orbital irradiation for Graves ophthalmopathy: Is it safe? A long-term follow-up study. *Ophthalmology*. 2004;111:1557-1562.
63. Ng CM, Yuen HK, Choi KL, Chan MK, Yuen KT, Ng YW, Tiu SC. Combined orbital irradiation and systemic steroids compared with systemic steroids alone in the management of moderate-to-severe Graves' ophthalmopathy: a preliminary study. *Hong Kong Med J*. 2005;11:322-330.
64. Prummel MF, Mourits MP, Blank L, Berghout A, Koornneef L, Wiersinga WM. Randomized double-blind trial of prednisone versus radiotherapy in Graves' ophthalmopathy. *Lancet*. 1993;342:949-954.
65. Prummel MF, Mourits MP, Berghout A, Krenning EP, van der Gaag R, Koornneef L, Wiersinga WM. Prednisone and cyclosporine in the treatment of severe Graves' ophthalmopathy. *N Engl J Med*. 1989;321:1353-1359.
66. Perros P, Weightman DR, Crombie AL, Kendall-Taylor P. Azathioprine in the treatment of thyroid-associated ophthalmopathy. *Acta Endocrinol (Copenh)*. 1990;122:8-12.
67. Tanikawa T, Okada Y, Tanaka Y. Intravenous cyclophosphamide pulse therapy is effective for refractory Graves' ophthalmopathy. *J UOEH*. 2006;28:185-191.
68. Bigos ST, Nisula BC, Daniels GH, Eastman RC, Johnston HH, Kohler PO. Cyclophosphamide in the management of advanced Graves' ophthalmopathy. A preliminary report. *Ann Intern Med*. 1979;90:921-923.
69. Stan MN, Garrity JA, Bahn RS. The evaluation and treatment of Graves ophthalmopathy. *Med Clin North Am*. 2012;96:311-328.
70. Krassas GE. Somatostatin analogues in the treatment of thyroid eye disease. *Thyroid*. 1998;8:443-445.
71. Wémeau JL, Caron P, Beckers A, Rohmer V, Orgiazzi J, Borson-Chazot F, Nocaudie M, Perimenis P, Bisot-Locard S, Bourdeix I, Dejager S. Octreotide (long acting release formulation) treatment in patients with Graves orbitopathy: clinical results of a four-month, randomized, placebo-controlled, double-blind study. *J Clin Endocrinol Metab*. 2005;90:841-848.
72. Kung AW, Michon J, Tai KS, Chan FL. The effect of somatostatin versus corticosteroid in the treatment of Graves' ophthalmopathy. *Thyroid*. 1996;6:381-384.
73. Ozata M, Bolu E, Sengul A, Tasar M, Beyhan Z, Corakci A, Gundogan MA. Effects of octreotide treatment on Graves' ophthalmopathy and circulating sICAM-1 levels. *Thyroid*. 1996;6:283-288.
74. Pilarska K, Kulig G. Lanreotide in the treatment of thyroid orbitopathy. *Przegl Lek*. 2004;61:845-847.
75. Chang CC, Chang TC, Kao SC, Kuo YF, Chien LF. Pentoxifylline inhibits the proliferation and glycosaminoglycan synthesis of cultured fibroblasts derived from patients with Graves' ophthalmopathy and pretibial myxoedema. *Acta Endocrinol (Copenh)*. 1993;129:322-327.
76. Hiromatsu Y, Yang D, Miyake I, Koga M, Kameo J, Sato M, Inoue Y, Nonaka K. Nicotinamide decreases cytokine-induced activation of orbital fibroblasts from patients with thyroid-associated ophthalmopathy. *J Clin Endocrinol Metab*. 1998;83:121-124.
77. Baschieri L, Antonelli A, Nardi S, Alberti B, Lepri A, Canapicchi R, Fallahi P. Intravenous immunoglobulin vs. corticosteroid in treatment of Graves' ophthalmopathy. *Thyroid*. 1997;7:579-585.
78. Seppel T, Schlaghecke R, Becker A, Engelbrecht V, Feldkamp J, Kornely E. High-dose intravenous therapy with 7S immunoglobulins in autoimmune endocrine ophthalmopathy. *Clin Exp Rheumatol*. 1996;14(Suppl 15):109-114.
79. Berlin G, Hjelm H, Lieden G, Tegler L. Plasma exchange in endocrine ophthalmopathy. *J Clin Apher*. 1990;5:192-196.
80. Kumorowski J, Jankiewicz-Wika J, Siejka A, Lawnicka H, Stepie H. Anti-cytokine and anti-lymphocyte monoclonal antibodies in the treatment of thyroid associated ophthalmopathy. *Pol Merkur Lekarski*. 2007;22:571-574.
81. Hegedüs L, Smith TJ, Douglas RS, Nielsen CH. Targeted biological therapies for Graves' disease and thyroid associated ophthalmopathy. Focus on B-cell depletion with Rituximab. *Clin Endocrinol (Oxf)*. 2011;74:1-8.
82. Salvi M, Vannucchi G, Campi I, Currò N, Dazzi D, Simonetta S, Bonara P, Rossi S, Sina C, Guastella C, Ratiglia R, Beck-Peccoz P. Treatment of Graves' disease and associate ophthalmopathy with the anti-CD20 monoclonal antibody rituximab: an open study. *Eur J Endocrinol*. 2007;156:33-40.
83. El Fassi D, Banga JP, Gilbert JA, Padoa C, Hegedüs L, Nielsen CH. Treatment of Graves' disease with rituximab specifically reduces the production of thyroid stimulating autoantibodies. *Clin Immunol*. 2009;130:252-258.
84. Cant JS, Lewis DR, Harrison MT. Treatment of disthyroid ophthalmopathy with local guanethidine. *Br J Ophthalmol*. 1969;53:233-238.
85. Wakelkamp IM, Baldeschi L, Saeed P, Mourits MP, Prummel MF, Wiersinga WM. Surgical or medical decompression as a first line treatment of optic neuropathy in Graves' ophthalmopathy? A randomized controlled trial. *Clin Endocrinol (Oxf)*. 2005;63:323-328.
86. Baldeschi L. Orbital decompression. In: Wiersinga WM, Kahaly GJ, eds. *Graves orbitopathy: A multidisciplinary approach*. Basel; Karger; 2007:163-175.
87. De Santo LW. Transantral orbital decompression. In: Gorman CA, Waller RR, Dyer JA eds. *The Eye and Orbit in Thyroid disease*. New York; Raven Press; 1984:231-251.
88. Leone CR, Piest KL, Newman RJ. Medial and lateral wall decompression for thyroid ophthalmopathy. *Am J Ophthalmol*. 1989;108:160-166.
89. Goldberg RA, Perry JD, Hortoleza V, Tong JT. Strabismus after balanced medial plus lateral wall versus lateral wall only orbital decompression for dysthyroid orbitopathy. *Ophthal Plast Reconstr Surg*. 2000;16:271-277.
90. Baldeschi L, MacAndie K, Hintschich C, Wakelkamp IM, Prummel MF, Wiersinga WM. The removal of the deep lateral wall in orbital decompression: its contribution to exophthalmos reduction and influence on consecutive diplopia. *Am J Ophthalmol*. 2005;140:642-647.
91. Trokel S, Kazim M, Moore S. Orbital fat removal. Decompression for Graves' orbitopathy. *Ophthalmology*. 1993;100:674-682.
92. Baldeschi L, Lupetti A, Vu P, Wakelkamp IM, Prummel MF, Wiersinga WM. Reactivation of Graves' orbitopathy after rehabilitative orbital decompression. *Ophthalmology*. 2007;114:1395-1402.
93. Mourits MP, Koornneef L, van Mourik-Noordenbos AM, van der Meulen-Schor HM, Prummel MF, Wiersinga WM, Berghout A. Extraocular muscle surgery for Graves' ophthalmopathy: does prior treatment influence surgical outcome? *Br J Ophthalmol*. 1990;74:481-483.
94. Putterman AM. Thyroid ophthalmopathy: surgical management. In: Bardin CW, ed. *Current Therapy in Endocrinology and Metabolism*. 6 th. Mosby; St. Louis; 1997:85-90.
95. Burch HB, Wartofsky L. Graves' ophthalmopathy: current concepts regarding pathogenesis and management. *Endocr Rev*. 1993;14:747-793.



# Spontaneous Late Intraocular Lens and Capsule Tension Ring Dislocation

Ayşe Gül Koçak Altıntaş, Aslıhan Esra Omay, Selda Çelik  
Ulucanlar Eye Training and Research Hospital, Ophthalmology Clinic, Ankara, Turkey

## Abstract

In this report, three cases with pseudoexfoliation (PEX) and advanced age with spontaneous intraocular lens (IOL) and capsule tension ring (CTR) dislocation were presented. All of our cases experienced progressive vision loss without an episode of strenuous physical activity, trauma, or any other ocular disease. Spontaneous dislocation was observed 2.5 to 8 years after uneventful phacosurgery. Each patient underwent complete IOL and CTR removal combined with anterior chamber IOL implantation. No complications were noticed during follow-up. As a result, capsule tension ring does not prevent late IOL dislocation after uncomplicated phacosurgery in the presence of PEX. Therefore, close follow-up is essential for patients with PEX.

**Keywords:** Capsule contraction syndrome, capsule tension ring, intraocular lens dislocation, pseudoexfoliation

## Introduction

Capsule contraction syndrome (CCS) is myofibroblastic metaplasia of the anterior lens epithelia cells (LECs) and exaggerated contraction of both fibrotic anterior capsulectomy opening and capsular bag diameter.<sup>1,2</sup> These changes could lead to intraocular lens (IOL) decentration within the capsular bag followed by dislocation or total IOL luxation into the vitreous cavity.<sup>3,4,5</sup> Early IOL dislocation occurs in cataract surgery with inadequate support for the IOL resulting from intraoperative zonular or capsular damage, but late dislocation following uncomplicated surgery usually occurs several months to many years postoperatively.<sup>4,5,6,7,8</sup>

Several ocular and systemic factors for CCS and IOL dislocation have been identified, such as pseudoexfoliation syndrome (PEX), advanced age, trauma, high myopia, diabetes mellitus, uveitis, certain connective tissue disorders, and previous vitreoretinal surgery.<sup>2,9,10,11,12</sup> Surgical factors including capsulorhexis size and IOL design and materials may also influence the development of CCS and IOL dislocation.<sup>4,5,12</sup>

Here, we present three cases with PEX who developed subluxation of IOL and capsular tension ring (CTR) combined with fibrotic capsular bag, after uneventful phacoemulsification.

## Case Reports

### Case 1

A 72-year-old man presented with symptoms of marked reduction of vision 3 years after cataract surgery on his right eye. He had undergone cataract extraction with anterior chamber IOL implantation in his left eye at another hospital five years before the phacoemulsification surgery on his right eye. Bilateral PEX and phacodonesis in his right eye were noted in his preoperative medical records from our hospital. Therefore, during the uneventful phacoemulsification, one-piece hydrophilic acrylic foldable IOL and CTR implantation was performed. The patient was followed for 3 months, and his visual acuity (VA) was 6/10 and no complication was observed at his final examination. Three years after his uneventful right eye operation, the patient presented to our clinic with complaint of blurred vision early in the morning upon waking. Slit-lamp examination revealed subluxation of the IOL and CTR inside the fibrotic and contracted capsular bag. The subluxation was inferior and towards the posterior when the patient was in supine position. Intraocular pressures (IOP) were 14 and 16 mmHg for right eye and left eye respectively. Fundus examination revealed bilateral dry age-related macular degeneration. The IOL and CTR in the fibrotic capsular bag were extracted with IOL forceps in order to

**Address for Correspondence:** Selda Çelik MD, Ulucanlar Eye Training and Research Hospital, Ophthalmology Clinic, Ankara, Turkey  
Phone: +90 542 467 21 04 E-mail: drsldclk@gmail.com **Received:** 25.11.2014 **Accepted:** 27.07.2015

©Copyright 2017 by Turkish Ophthalmological Association  
Turkish Journal of Ophthalmology, published by Galenos Publishing House.


prevent luxation into the vitreous (Figure 1). After performing anterior vitrectomy and inducing miosis with intracameral 0.5 mL of 0.01% carbachol solution (Miostat®, Alcon, USA), a one-piece polymethyl methacrylate (PMMA) IOL was implanted into the anterior chamber. At final examination at postoperative 6 months, the patient's VA in the right eye had improved to 6/10 and slit-lamp examination revealed the IOL was stable, in correct position with normal pupil shape and without any anterior chamber reaction.

### Case 2

A 76-year-old man was admitted to our clinic with complaint of left-sided visual deterioration. He had undergone phacoemulsification in the left eye two and a half years earlier. His VA was counting fingers from 2 meters and did not improve with correction. On slit-lamp examination of his left eye, pseudoexfoliation material and significant inferior dislocation of the IOL and CTR was observed, and anterior capsule phimosis with a marked decrease in capsular bag diameter was noted (Figure 2). Examination of his right eye revealed marked pseudophacodonesis, nuclear sclerosis, and pseudoexfoliation material at the pupillary margins. Dry age-related macular degenerations were observed. According to his medical records, CTR implantation was done for prophylactic support after a two clock-hour area of zonular dehiscence was recognized intraoperatively. However, no other intraoperative or postoperative complications had been recorded during the regular three-month follow-up period. Because of significant inferior subluxation, complete capsular bag extraction with IOL and CTR followed by anterior chamber IOL implantation were performed to prevent total drop of IOL and CTR into the vitreous, similar to case 1. The patient's best corrected VA improved to 5/10 postoperatively.

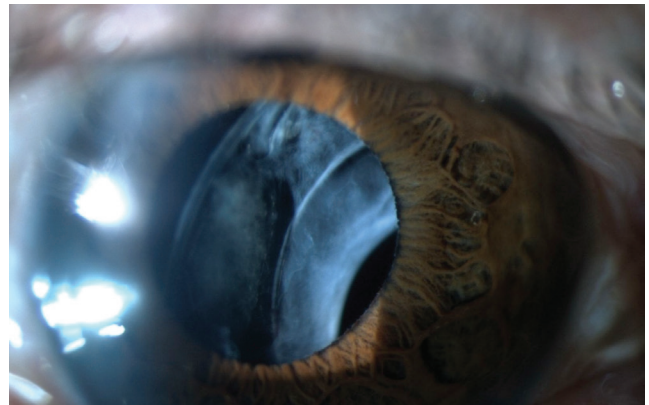### Case 3

A 79-year-old woman reported progressive visual blurring in the left eye for nearly 6 months. Her VA was counting fingers from 1 meter in the left eye and 20/20 in the fellow eye.




**Figure 1.** Intraocular lens and capsular tension ring in the fibrotic capsular bag

According to her medical records, she had undergone uneventful phacoemulsification and one-piece foldable hydrophilic acrylic IOL implantation surgery in both eyes 8 years earlier. She was being medically treated for glaucoma in the right eye and had previously undergone trabeculectomy surgery on her left eye. Despite the absence of significant zonular weakness, CTRs had been implanted in both eyes for preventive purposes due to substantial accumulations of PEX material on both the pupillary margins and anterior capsular surfaces. Slit-lamp examination of the right eye showed bilateral pseudoexfoliation at the pupillary margin and stable IOL in the bag, whereas the left eye showed pronounced inferior dislocation of the IOL and CTR and total curving of the CTR inside the fibrotic and significantly constricted capsular bag. The patient underwent surgery to remove the subluxated capsular bag containing the IOL and CTR followed by anterior chamber IOL implantation (Figure 3). Her VA in the left eye was 6/10 at postoperative 1 month and there were no complications. Fundoscopic evaluation revealed cup-to-disc ratios of 6/10 and 8/10 and IOPs of 14 and 16 mmHg in the right eye and left eye, respectively.



**Figure 2.** Subluxated in-the-bag intraocular lens and capsular tension ring



**Figure 3.** Intraocular lens and capsular tension ring folding in the fibrotic capsular bag

Each of these three cases denied trauma, any other ocular surgery after cataract extraction or ocular disease other than PEX, glaucoma and age-related macular degeneration.

## Discussion

IOL dislocation or decentration is a rare but serious complication following uneventful phacoemulsification.<sup>4</sup> The incidence of repositioning or exchange procedures for dislocated IOL ranges between 0.2% and 3%.<sup>5,13</sup> Mönestam<sup>5</sup> reported that 0.6% of patients were at risk of required surgery for a dislocated IOL 10 years after initial surgery.

Cuboidal anterior lens epithelial cell metaplasia and myofibroblastic transformation to actin-positive smooth muscle cause extreme shrinkage of the capsular bag. This progressive contraction can directly result in zonular dehiscence, leading to IOL and capsular complex dislocation.<sup>11,14,15</sup> Fibrotic contraction and opacification of the anterior capsule usually occurs 3 to 6 months after surgery, but spontaneous dislocation of the IOL with CCS and extensive constriction of the capsular bag following uncomplicated surgery may occur many months to several years later.<sup>4,6</sup> Kumar et al.<sup>4</sup> reported two cases aged 83 and 74 years with IOL dislocation within the bag 3 and 6 months after surgery, respectively. To correct visual deterioration they had removed dislocated IOLs from the bag and implanted rigid IOLs in the sulcus for each patient. Coelho et al.<sup>3</sup> reported a 58-year-old patient with significant inferonasal subluxation of the IOL with a contracted capsular bag 3 years after surgery, similar to our cases. To prevent luxation into the vitreous, their patient underwent complete capsular bag and IOL removal and implantation of another IOL in the ciliary sulcus by scleral fixation. Suturing the IOL and CTR combined with capsular bag into the sclera may have potential complications such as retinal tearing, retinal detachment, and vitreous hemorrhage. Due to these potential complications and the presence of significant capsular folding in our patients, we did not prefer scleral fixation.

We observed dislocation 2.5 to 8 years after uneventful phacosurgery, similar to Coelho et al.'s<sup>3</sup> case. These observations support that dislocations may occur much later than CCS development. Consistent with that case, we preferred extraction of the subluxated IOL and CTR with fibrotic capsular bag in our cases. However, our cases were much older than Coelho et al.'s<sup>3</sup> patient, and we therefore decided to implant the IOL into the anterior chamber. None of our patients had any complications associated with the anterior chamber IOL like corneal edema or anterior chamber flare or cells.

If a recent ocular trauma is ruled out, several predisposing factors such as pseudoexfoliation, advanced age, diabetes mellitus, and high myopia may lead to zonular dehiscence.<sup>3</sup> We observed PEX in each of our three cases and they all had advanced age as risk factor for dislocation.<sup>5</sup> Mönestam<sup>5</sup> reported PEX in 4 out of 5 patients with IOL dislocation. In a comparative study, Hayashi et al.<sup>9</sup> noted greater IOL tilt in eyes with PEX than in otherwise healthy eyes.

A CTR improves capsular stability and prevents focal stress on compromised zonules. CTR implantations were performed to maintain equally distributed equatorial forces and circular contour of the capsular bag to provide zonular stability due to the presence of preoperative phacodonesis in case 1 and intraoperative focal dehiscence in case 2. In cases 1 and 2, IOL and CTR dislocation were noticed earlier than case 3, in whom CTR insertion was done even in the absence of any risk factors other than PEX. Case 3 developed IOL and CTR dislocation 8 years after surgery; to our knowledge, this is the latest spontaneous dislocation reported in the literature.

Different clinical and historical studies have demonstrated that zonules were fragile and had weak stretching capability in PEX.<sup>9,16</sup> Severe capsular fibrosis causes an imbalance between centrifugal and centripetal forces on the capsular bag, which may cause progressive dehiscence of the zonules and spontaneous in-the-bag IOL dislocation. The use of CTRs may reduce the risk of zonular rupture but does not guarantee zonular stability or prevention of spontaneous late IOL dislocation combined with fibrotic capsular bag, as we observed in all three our cases, even in the absence of any preoperative or postoperative complications other than PEX and advanced age.<sup>5,17,18,19,20,21,22</sup> Our patients had experienced progressive vision loss without any precipitating strenuous physical activity, trauma or ocular disease. It is reported that CCS is influenced by IOL design, both the optic and haptic material, and more specifically the hydrophilicity of the optic biomaterial. However, the occurrence of CCS with silicone, PMMA, and both hydrophilic and hydrophobic acrylic IOLs has been reported, despite the use of CTRs.<sup>1,23,24,25,26</sup>

## Conclusion

According to our observations, the use of CTR regardless of optic and haptic material cannot always resist the centripetal forces generated by fibrotic contracting capsulorhexis. There are no specific measures to prevent late postoperative subluxation, but avoiding small capsulorhexis, carefully cleaning the posterior capsule and completely removing all cortical material, especially in the equatorial area, are important steps to prevent CCS. Selecting a hydrophobic IOL with a sharp optical posterior edge and inserting a CTR in suspected cases can also reduce the risk of late CCS development. Despite all of these measures, late CCS is unavoidable in some cases, especially eyes with PEX. Therefore, CTR with scleral fixation may prevent late CCS in cases with high risk, such as eyes with PEX and defective zonules. Furthermore, prolonging close follow-up as long as possible is essential for early diagnosis and prompt treatment of patients at risk of spontaneous IOL decentration or subluxation.

## Ethics

Informed Consent: Present for each patient.  
Peer-review: Externally peer-reviewed.

## Authorship Contributions

Surgical and Medical Practices: Ayşe Gül Koçak Altıntaş, Concept: Ayşe Gül Koçak Altıntaş, Design: Ayşe Gül Koçak Altıntaş, Data Collection or Processing: Ayşe Gül Koçak

Altıntaş, Analysis or Interpretation: Ayşe Gül Koçak Altıntaş, Literature Search: Aslihan Esra Omay, Selda Çelik, Writing: Ayşe Gül Koçak Altıntaş.

Conflict of Interest: No conflict of interest was declared by the authors.

Financial Disclosure: The authors declared that this study received no financial support.

## References

- Al-Mezaine HS. Capsule Contraction Syndrome despite Capsular Tension Ring. *Saudi J Ophthalmol.* 2007;21:35-37.
- Tsinopoulos IT, Tsaousis KT, Symeonidis C, Dimitrakos SA. Bilateral manifestation of severe anterior capsule contraction syndrome after implantation of a preloaded intraocular lens. *Clin Exp Optom.* 2009;92:503-504.
- Coelho RP, Zanatto MC, Paula JS, Romão E. Spontaneous late in-the-bag intraocular lens dislocation after can-opener capsulotomy: case report. *Arq Bras Oftalmol.* 2005;68:864-866.
- Kumar A, Freeman M, Kumar V, Ramanathan US. In the bag IOL dislocation following uncomplicated phacoemulsification. *Cont Lens Anterior Eye.* 2008;31:103-106.
- Mönestam EI. Incidence of dislocation of intraocular lenses and pseudophakodonesis 10 years after cataract surgery. *Ophthalmology.* 2009;116:2315-2320.
- Jehan FS, Mamalis N, Crandall AS. Spontaneous late dislocation of intraocular lens within the capsular bag in pseudoexfoliation patients. *Ophthalmology.* 2001;108:1727-1731.
- Masker S, Osher RH. Late complications with intraocular lens dislocation after capsulorhexis in pseudoexfoliation syndrome. *J Cataract Refract Surg.* 2002;28:1481-1484.
- Shigeeda T, Nagahara M, Kato S, Kunimatsu S, Kaji Y, Tanaka S, Amano S, Oshika T. Spontaneous posterior dislocation of intraocular lenses fixated in the capsular bag. *J Cataract Refract Surg.* 2002;28:1689-1693.
- Hayashi H, Hayashi K, Nakao F, Hayashi F. Anterior capsule contraction and intraocular lens dislocation in eyes with pseudoexfoliation syndrome. *Br J Ophthalmol.* 1998;82:1429-1432.
- Zhang ZD, Song Z, Chen D, Huang F. Bilateral capsule contraction syndrome following pathological myopic cataract surgeries. *Int J Ophthalmol.* 2012;5:406-408.
- Altintas AG, Dal D. Capsule contraction syndrome in Behcet's disease. *Int J Ophthalmol.* 2010;3:358-360.
- Altintas AG, Dal D, Simsek S. Significant intraocular lens folding due to severe capsular contraction. *Jpn J Ophthalmol.* 2008;52:134-136.
- Jin GJ, Crandall AS, Jones JJ. Changing indications for and improving outcomes of intraocular lens exchange. *Am J Ophthalmol.* 2005;140:688-694.
- Arnold P. Anterior Capsular Contraction Syndrome. *Cataract and Refractive Surgery Today.* 2007:80-82.
- Al-Kharashi SA, Al-Obailan M. Capsular phimosis with complete occlusion of the anterior capsular opening after intact continuous curvilinear capsulorhexis. *Saudi J Ophthalmol.* 2009;23:175-178.
- Schlötzer-Schrehardt U, Naumann GO. A histopathologic study of zonular instability in pseudoexfoliation syndrome. *Am J Ophthalmol.* 1994;118:730-743.
- Scherer M, Bertelmann E, Rieck P. Late spontaneous in-the-bag intraocular lens and capsular tension ring dislocation in pseudoexfoliation syndrome. *J Cataract Refract Surg.* 2006;32:672-675.
- Rosenthal K. Improving surgical outcomes with capsular tension rings. *Rev Ophthalmology.* 2001:47-55.
- Moreno-Montañés J, Rodríguez-Conde R. Capsular tension ring in eyes with pseudoexfoliation. *J Cataract Refract Surg.* 2002;28:2241-2242.
- Lee DH, Lee HY, Lee KH, Chung KH, Joo CK. Effect of a capsular tension ring on the shape of the capsular bag and opening and the intraocular lens. *J Cataract Refract Surg.* 2001;27:452-456.
- Hara T, Hara T, Sakanishi K, Yamada Y. Efficacy of equator rings in an experimental rabbit study. *Arch Ophthalmol.* 1995;113:1060-1065.
- Oner FH, Kocak N, Saatci AO. Dislocation of capsular bag with intraocular lens and capsular tension ring. *J Cataract Refract Surg.* 2006;32:1756-1758.
- Faschinger CW, Eckhardt M. Complete capsulorhexis opening occlusion despite capsular tension ring implantation. *J Cataract Refract Surg.* 1999;25:1013-1015.
- Sudhir RR, Rao SK. Capsulorhexis phimosis in retinitis pigmentosa despite capsular tension ring implantation. *J Cataract Refract Surg.* 2001;27:1691-1694.
- Moreno-Montañés J, Sánchez-Tocino H, Rodríguez-Conde R. Complete anterior capsule contraction after phacoemulsification with acrylic intraocular lens and endocapsular ring implantation. *J Cataract Refract Surg.* 2002;28:717-719.
- Jin-Poi T, Shatriah I, Khairy-Shamel ST, Zunaina E. Rapid anterior capsular contraction after phacoemulsification surgery in a patient with retinitis pigmentosa. *Clin Ophthalmol.* 2013;7:839-842.



## Rare Clinical Sign of Hodgkin's Lymphoma: Ocular Involvement

Ziya Ayhan\*, Revan Yıldırım Karabağ\*\*, İnci Alacacıoğlu\*\*\*, Süleyman Kaynak\*, Nilüfer Koçak\*

\*Dokuz Eylül University Faculty of Medicine, Department of Ophthalmology, İzmir, Turkey

\*\*Manisa State Hospital, Ophthalmology Clinic, Manisa, Turkey

\*\*\*Dokuz Eylül University Faculty of Medicine, Department of Hematology, İzmir, Turkey

### Abstract

Bilateral non-granulomatous anterior uveitis with left vitritis and macular edema were detected in a 19-year-old woman presenting with blurred vision in her left eye. Light microscopic study of the pathologic mediastinal lymph node that was detected via contrast computed tomography imaging during etiologic study revealed nodular sclerosing and mixed cellularity Hodgkin's lymphoma (HL). Ocular findings completely resolved with adriablastin, bleomycin, vinblastine, dacarbazine chemotherapy treatment. Herein, it is emphasized that HL should be remembered as one of the differential diagnoses in patients with ocular inflammatory pathologies such as uveitis and vasculitis. The ocular findings of HL are discussed.

**Keywords:** Anterior uveitis, Hodgkin's lymphoma, macular edema, posterior uveitis

### Introduction

Hodgkin's lymphoma (HL) is a disease originating from lymphoid tissues and accounts for less than 1% of all cancers.<sup>1</sup> As lymph nodes are distributed throughout the body, lymphomas may manifest with involvement in various areas.<sup>2</sup> This can cause difficulties in diagnosis as well as delayed treatment.

Ocular involvement is more prevalent in non-HL compared to HL.<sup>3</sup> There are many reports in the literature of ocular involvement in HL, which is reported to generally develop after HL diagnosis.<sup>4,5,6</sup> Though rare, there are also patients who present with ocular symptoms and are subsequently diagnosed with HL.<sup>7,8</sup>

With this case report, we aimed to discuss the case of a 19-year-old patient who presented with complaints of low vision and was diagnosed with HL after testing, to examine the relationship between ocular findings and HL within the context of the literature, and to raise awareness of this condition.

### Case Report

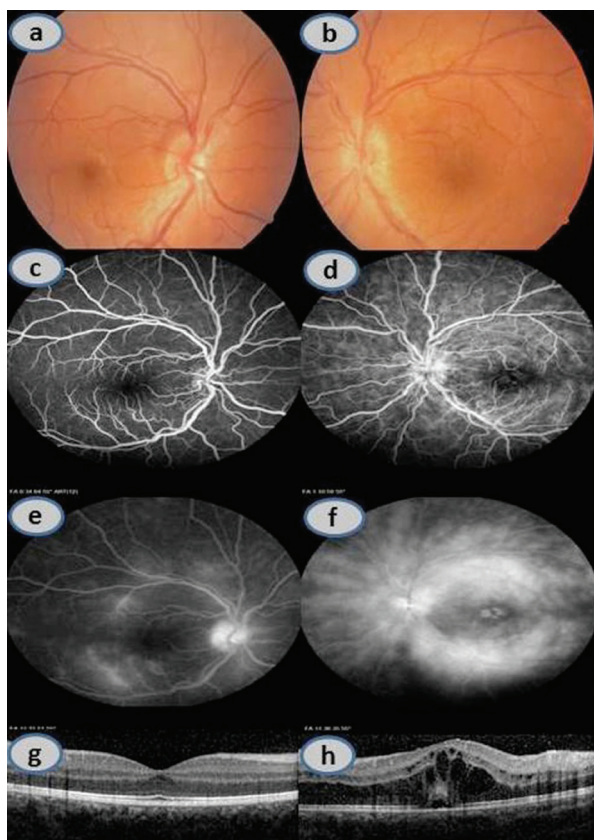
A 19-year-old female patient presented to our clinic with complaints of reduced vision in her left eye. The patient reported

that her symptoms of reduced vision in the left eye had started 6 months earlier and that she had sought treatment for the first time 1 week earlier at a private ophthalmology outpatient clinic, from which she was referred to our clinic. On ophthalmologic examination, her best corrected visual acuity (BCVA) was 10/10 (0.0 logMAR) in the right eye and 2/10 (0.7 logMAR) in the left eye. Slit-lamp examination revealed bilateral non-granulomatous keratic precipitates and 2+ flare which were more pronounced in the left eye. Fundus examination was normal in the right eye, while macular edema and +/++ vitritis were observed in the left eye, though there was no vitreous turbidity (Figure 1a and 1b). Fluorescein angiography revealed extensive leakage from the vascular arcades in both optic discs and macular edema in the left eye (Figure 1c, 1d, 1e, and 1f). On optic coherence tomography (OCT), the right macula appeared normal, and severe cystoid macular edema was observed in the left eye (Figure 1g and 1h). The patient had no known systemic disease, but it was learned that she had lost 10 kg in the last 6 months using an herbal drug, that she tired quickly, and had complaints of numbness in the soles of her feet for the past 1.5 months. Topical treatment was initiated with 1% prednisolone acetate every hour and 1%

**Address for Correspondence:** Nilüfer Koçak MD, Dokuz Eylül University Faculty of Medicine, Department of Ophthalmology, İzmir, Turkey  
Phone: +90 505 525 21 43 E-mail: nkocak@yahoo.com **Received:** 21.01.2015 **Accepted:** 11.06.2015

©Copyright 2017 by Turkish Ophthalmological Association  
Turkish Journal of Ophthalmology, published by Galenos Publishing House.

cyclopentolate HCl 3 times daily. The patient was admitted to our clinic for etiologic study and treatment. Dermatologic examination and tests performed for differential diagnosis of Behçet's disease were normal; neurologic examination and tests revealed no pathologies other than Chiari malformation observed on brain magnetic resonance imaging (MRI). Diffusion brain MRI and orbital MRI were normal. Electromyography test revealed no pathology other than mild sensory neuropathy. Except for elevated sedimentation rate (48 mm/hour) and leukocytosis, no pathology was detected in rheumatologic examination and immunologic tests. Following consultation with the department of pulmonary and respiratory diseases to establish etiology, contrast chest computed tomography revealed mediastinal lymph nodes of pathologic size. Hematology evaluated the condition as lymphoproliferative disease and recommended excisional lymph node biopsy. Atypical cells were found in the peripheral smear. The excised mediastinal lymph node was determined by pathologic examination to be consistent with classic nodular sclerosis and mixed cellularity HL. The patient was diagnosed with stage 3B HL and transferred to the



**Figure 1.** Color fundus photography from January 2012 showing normal OD (a) and indistinct optic disc margins and macular edema in OS (b). In early phase fluorescein angiography, OD appears normal (c) and leakage is evident in the disc and macula of the OS (d). In late phase, there is pronounced leakage around the disc and arcades in OD (e) and extensive leakage around the disc and arcades with macular edema in OS (f). Optical coherence tomography shows normal appearance in OD (g) and macular edema in OS (h)  
OD: Right eye, OS: Left eye

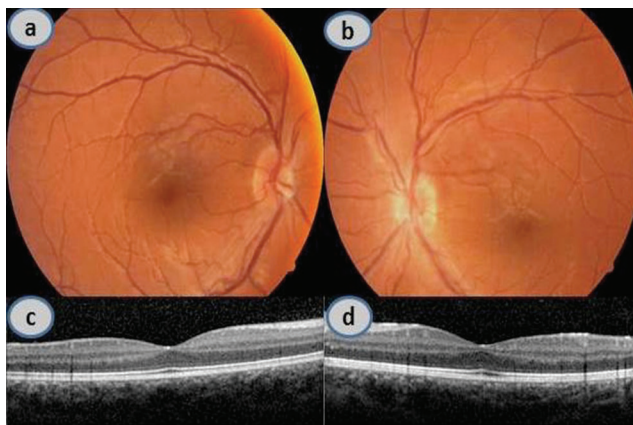hematology department for advanced tests and treatment with 6 courses of adriablastin, bleomycin, vinblastine, and dacarbazine (ABVD).

In ophthalmologic examination conducted in April 2012, after 6 courses of chemotherapy, the patient's BCVA was 10/10 (0.0 logMAR) in both eyes. Slit-lamp examination revealed complete resolution of the anterior uveitis findings. The optic disc, macula, and peripheral retina of both eyes appeared normal in fundus examination. OCT revealed complete regression of the macular edema in the left eye (Figure 2a, 2b, 2c and 2d). Furthermore, her HL was in full remission after chemotherapy. No recurrence of ocular symptoms or HL was observed in follow-up examinations through February 2015.

## Discussion

HL is usually seen in individuals aged 15-34 years and those over 55 years old.<sup>1</sup> The incidence of pediatric HL tends to rise as family size increases and socioeconomic status decreases; the opposite has been reported with the adult form, which is associated with high socioeconomic status in industrialized nations.<sup>9</sup> Although HL is more prevalent among males in all age groups, the nodular sclerosis subtype is more common among females.<sup>9</sup> Unlike most other cancers, HL can be cured, generally through a combination of radiotherapy and chemotherapy.<sup>10</sup> Intraocular involvement is rare in lymphomas, and diagnosis may be delayed due to its nonspecific signs and possible masking by inflammatory processes. For this reason, HL should be included in the differential diagnosis of ocular inflammatory pathologies such as uveitis and vasculitis.

Ocular involvement in HL occurs by various mechanisms including direct lymphomatous or metastatic involvement of the choroid and retina; paraneoplastic vasculitis; and iatrogenic complications arising from HL treatment or immunosuppression.<sup>5,6,7,11</sup> These patients may exhibit infiltration of the ocular structures, retinal periphlebitis, focal chorioretinitis, vitritis, papillary edema, exudative retinal detachment, soft exudates, retinal hemorrhage, necrotizing retinitis, peripheral



**Figure 2.** Appearance is normal in color fundus photograph (a, b) and optical coherence tomography images (c, d) from April 2012



retinal exudates, and retinal white spots.<sup>3,12</sup> In a study by Towler et al.<sup>8</sup> comparing 2 patients whose posterior uveitis preceded HL diagnosis and 2 patients who presented with posterior uveitis after HL diagnosis, the authors reported that the two groups showed no differences in ocular lesion type. Mateo-Montoya et al.<sup>12</sup> reported a patient with macular edema, papillitis, and retinal white spots in the posterior pole and equatorial region who was diagnosed with HL after systemic etiologic study; they noted that the patient's ocular signs completely resolved after chemotherapy and radiotherapy. In our case, both non-granulomatous anterior uveitis and vitritis with macular edema were detected as the first clinical signs of HL.

Granulomatous inflammation is a known sign of HL.<sup>8</sup> The exact source of this granulomatous reaction is unknown, though it is thought to possibly result from an immune reaction to tissue response an underlying viral infection. It has been reported that Epstein-Barr virus (EBV) latent gene products affect lymphomatogenesis and are associated with aggressive subtypes of HL.<sup>13</sup> However, nodular sclerosis HL, the subtype found in our patient, was found to be the subtype least associated with EBV latent membrane protein.<sup>14</sup> Moreover, it has been reported that the anterior uveitis seen in HL, which is composed of macrophages, epithelioid cells, and lymphocytes, may be related to this granulomatous reaction. Barkana et al.<sup>15</sup> also detected atypical granulomatous keratoconjunctivitis in a 19-year-old patient and diagnosed HL based on an inguinal lymph node biopsy.

Towler et al.<sup>8</sup> reported achieving complete remission of ocular inflammation after chemotherapy. They attributed this to chemotherapeutic suppression of the ocular inflammatory response, as well as the reduction of the inflammatory response to malignant cells due to their destruction. After 6 courses of ABVD therapy for stage 3B HL, our patient also showed full HL remission and complete regression of her ocular symptoms.

## Conclusion

In brief, this case highlights the fact that ophthalmologists should be vigilant for potential malignant lesions in patients with ocular signs like uveitis and vasculitis, that these may be indicators of a life-threatening systemic disease, and that systemic investigation is crucial for diagnosis and treatment.

## Ethics

Informed Consent: It was taken.

Peer-review: Externally peer-reviewed.

## Authorship Contributions

Surgical and Medical Practices: Nilüfer Koçak, İnci Alacacıoğlu, Concept: Nilüfer Koçak, Design: Nilüfer Koçak, Data Collection or Processing: Ziya Ayhan, Revan Yıldırım Karabağ, Analysis or Interpretation: Nilüfer Koçak, Süleyman Kaynak, Literature Search: Ziya Ayhan, Revan Yıldırım Karabağ, Writing: Ziya Ayhan, Nilüfer Koçak, İnci Alacacıoğlu.

Conflict of Interest: No conflict of interest was declared by the authors.

Financial Disclosure: The authors declared that this study received no financial support.

## References

1. Knowles MD. Neoplastic hematopathology (2nd ed). New York; Lippincott Williams &Wilkins; 2001:610-680.
2. Young GA. Lymphoma at uncommon sites. *Hematol Oncol.* 1999;17:53-83.
3. Şimşek HC, Akkoyun İ, Yılmaz G. Hematolojik Hastalıklarda Göz Bulguları. *Retina-Vitreus.* 2014;22:85-92.
4. Mosteller MW, Margo CE, Hesse RJ. Hodgkin's disease and granulomatous uveitis. *Ann Ophthalmol.* 1985;17:787-790.
5. Primbs GB, Monsees WE, Irvine AR Jr. Intraocular Hodgkin's disease. *Arch Ophthalmol.* 1961;66:477-482.
6. Brihaye-van Geertruyden M. Retinal lesions in Hodgkin's disease. *AMA Arch Ophthalmol.* 1956;56:94-99.
7. Barr CC, Joondeph HC. Retinal periphlebitis as the initial clinical finding in a patient with Hodgkin's disease. *Retina.* 1983;3:253-257.
8. Towler H, de la Fuente M, Lightman S. Posterior uveitis in Hodgkin's disease. *Aust N Z J Ophthalmol.* 1999;27:326-330.
9. Thomas RK, Re D, Zander T, Wolf J, Diehl V. Epidemiology and etiology of Hodgkin's lymphoma. *Ann Oncol.* 2002;13:147-152.
10. Şeker M, Mengi A, Bilici A, Ustaaloğlu BB, Kefeli U, Özşeker NI, Mayadağlı A, Salepci T, Gümüş M. Hodgkin lenfoma olgularının retrospektif değerlendirilmesi ve prognostik faktörlerin saptanması. *Turk J Oncol.* 2011;26:108-114.
11. Sacks EL, Donaldson SS, Gordon J, Dorfman RF. Epithelioid granulomas associated with Hodgkin's disease: clinical correlation in 55 previously untreated patients. *Cancer.* 1978;41:562-567.
12. Mateo-Montoya A, Bonnel S, Wolff B, Héron E, Sahel JA. White dots in the eye fundus revealing Hodgkin's lymphoma. *Eye (Lond).* 2010;24:934-937.
13. Pallesen G, Hamilton-Dutoit SJ, Rowe M, Young LS. Expression of Epstein-Barr virus latent gene products in tumour cells of Hodgkin's disease. *Lancet.* 1991;337:320-322.
14. O'Grady J, Stewart S, Elton RA, Krajewski AS. Epstein-Barr virus in Hodgkin's disease and site of origin of tumour. *Lancet.* 1994;343:265-266.
15. Barkana Y, Zadok D, Herbert M, Kornberg A, Nemet P. Granulomatous keratoconjunctivitis as a manifestation of Hodgkin lymphoma. *Am J Ophthalmol.* 2001;131:796-797.



# Giant Hidrocystoma of the Orbit Presenting with Inversion and Ptosis of the Upper Eyelid

Melis Palamar\*, Banu Yaman\*\*, Taner Akalın\*\*, Ayşe Yağcı\*

\*Ege University Faculty of Medicine, Department of Ophthalmology, İzmir, Turkey

\*\*Ege University Faculty of Medicine, Department of Pathology, İzmir, Turkey

## Abstract

A case of giant hidrocystoma of the orbit in a 57-year-old female causing pain, epiphora and ptosis is reported. The cystic mass was totally excised as a whole. Histopathologic examination revealed eccrine hidrocystoma of the orbit. Hidrocystoma must be considered in the differential diagnosis of patients presenting with periocular masses causing pain and ptosis.

**Keywords:** Pain, eccrine, hidrocystoma, orbit, ptosis

## Introduction

Hidrocystomas are benign adnexal tumours which may be eccrine or apocrine in origin. Herein we report a case presenting with massive upper eyelid swelling and tension causing severe pain, epiphora, upper eyelid/eyelash ptosis and corneal epithelial erosion. The cyst was removed by total excision and identified as giant eccrine hidrocystoma by histopathologic examination. The aim of this case report is to serve as a reminder that this entity should be considered in the differential diagnosis of adnexal masses.

## Case Report

A 57-year-old female admitted to our clinic with massive upper eyelid swelling and severe pain. On examination, eyelid and eyelash ptosis was observed due to the mechanical effect of a palpable soft, mobile mass located in the anterior orbit (Figure 1A). Inversion of eyelashes resulted, with large central corneal epithelial erosion causing irritation and epiphora. The left eye was displaced inferiorly and downgaze was partially restricted. Best corrected visual acuity was 0.5 in the affected eye. All other ophthalmologic findings were within normal limits in both eyes.

In magnetic resonance imaging, an intraorbital/extraconal large cystic lesion was observed in the superior orbit, with an anterior extension towards the eyelid (Figure 1B, 1C). A

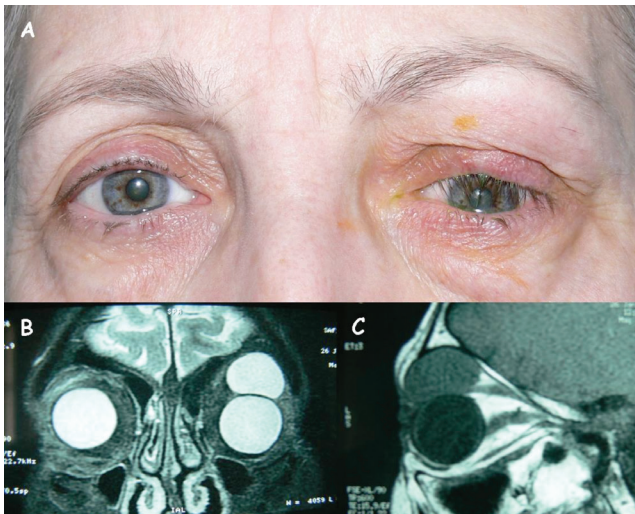
decision to excise the cystic lesion was made on the basis of clinical and radiological findings. A lid crease incision was performed and the cyst was excised as a whole using blunt dissection (Figure 2A). The wound was closed with 6/0 nylon sutures. The dimensions of the cyst were 25x20x20 mm macroscopically. Histopathological examination revealed a cyst lined by cuboidal cells, consistent with eccrine hidrocystoma (Figure 2B). The cyst wall epithelium was compressed in most areas (Figure 2C). The postoperative outcome was good and at 12 months, magnetic resonance imaging evidenced no residual cyst.

## Discussion

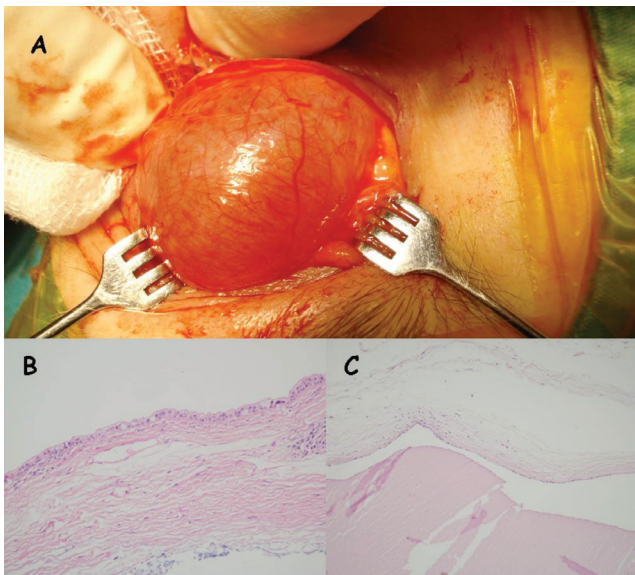
Hidrocystomas are benign adnexal sweat-gland lesions and are less commonly seen in the eyelids than chalasia or other benign masses.<sup>1,2,3</sup> To the best of our knowledge, such cases are rarely reported in the English medical literature. The largest published series of eccrine hidrocystoma reports a mean age at diagnosis of 59 years with the majority of patients having only a single mass usually located on the upper eyelid.<sup>1</sup> Periocular hidrocystomas are relatively uncommon, evidenced by the fact that they comprised only 5% of approximately 1,000 biopsied lesions in the same study. There is no gender or race predisposition.<sup>1</sup> Eccrine hidrocystomas may have a similar clinical appearance to apocrine hidrocystomas. Unlike

**Address for Correspondence:** Melis Palamar MD, Ege University Faculty of Medicine, Department of Ophthalmology, İzmir, Turkey  
Phone: +90 530 408 50 51 E-mail: melispalamar@hotmail.com **Received:** 10.03.2015 **Accepted:** 20.05.2015

©Copyright 2017 by Turkish Ophthalmological Association  
Turkish Journal of Ophthalmology, published by Galenos Publishing House.



**Figure 1.** External appearance of the swollen left upper eyelid causing mechanical ptosis (A). On magnetic resonance imaging, an intraorbital, extraconal lesion is evident in both coronal T2-weighted image (B) and sagittal T1-weighted image (C)



**Figure 2.** Intraoperative view demonstrating exposure and marsupialisation of the upper eyelid cyst (A). Histologic examination revealed the cyst was lined with cuboidal epithelial cells (hematoxylin and eosin x200) (B) and the cyst wall was lined with a compressed single layer of epithelial cells (hematoxylin and eosin x100) (C)

the apocrine type, which may be marginal, they tend to be distributed throughout eyelid skin without involving the eyelid margin. In addition, apocrine hidrocystomas tend to have a bluish color with yellow apical deposits. The eccrine type is more frequently associated with multiple lesions. It is rare for eccrine hidrocystoma of the eyelid to be larger than 10 mm and on average they measure 4 mm in the largest dimension.<sup>1,2,3</sup> As they are considered to be ductal retention cysts, they often enlarge in perspiration-stimulating conditions such as heat and increased humidity. The eccrine hidrocystoma in our case was solitary and

its dimensions were extraordinarily oversized at 25x20x20 mm. Such a big cyst located in the superior part of the orbit caused posterior eyelid lamellar inversion and inferior dystopia.

Histologically, the eccrine type has a single cystic cavity, which is partially collapsed and contains no papillary projections, and lined by a one or two layers of small cuboidal epithelial cells which secrete into the glandular lumen as seen in our case (Figure 2B, 2C).<sup>1</sup> The apocrine type demonstrates multiple, cystic spaces and papillary infoldings, and differs in demonstrating a fibrous outer wall of myoepithelial cells.

The differential diagnosis of the eccrine hidrocystoma includes other cystic lesions of the eyelid such as the follicular derived cysts, epidermal inclusion cyst, haemangioma, lymphangioma, apocrine hidrocystoma, and eccrine acrospiroma.<sup>1</sup>

Spontaneous resolution is rare, especially with large cysts, and successful management usually requires excision with complete removal of the cyst wall. Medical treatment of multiple, smaller periocular lesions has been advocated by laser thermo-ablation and, more recently, trichloroacetic acid chemical ablation.<sup>4</sup> As the hidrocystoma in our case was oversized and caused additional eyelid and ocular surface problems, we chose to perform total excision.

## Conclusion

This rare case illustrates that ocular adnexal eccrine hidrocystoma can cause significant functional and cosmetic morbidity despite their histologically benign nature. This unusual entity should be considered in the differential diagnosis in patients presenting with periocular masses causing pain and ptosis, and may be confirmed by excision and histology.

## Ethics

Informed Consent: It was taken.

Peer-review: Externally peer-reviewed.

## Authorship Contributions

Surgical and Medical Practices: Melis Palamar, Ayşe Yağcı, Concept: Melis Palamar, Ayşe Yağcı, Design: Melis Palamar, Data Collection or Processing: Melis Palamar, Analysis or Interpretation: Melis Palamar, Ayşe Yağcı, Banu Yaman, Taner Akalin, Literature Search: Melis Palamar, Writing: Melis Palamar, Banu Yaman.

Conflict of Interest: No conflict of interest was declared by the authors.

Financial Disclosure: The authors declared that this study received no financial support.

## References

1. Singh A, McCloskey L, Parsons MA, Slater DN. Eccrine hidrocystoma of the eyelid. *Eye (Lond)*. 2005;19:77-79.
2. Sheth HG, Raina J. Giant eccrine hidrocystoma presenting with unilateral ptosis and epiphora. *Int Ophthalmol*. 2008;28:429-431.
3. Eslami F, Fazel F, Ghasemibasir H, Beni AN. Giant eccrine hidrocystoma of orbit. *JRMS*. 2007;12:150-152.
4. Dailey RA, Saulny SM, Tower RN. Treatment of multiple apocrine hidrocystomas with trichloroacetic acid. *Ophthalm Plast Reconstr Surg*. 2005;21:148-150.



# Multiple Intravitreal Ranibizumab Injections for Persistent Choroidal Neovascularization Associated with Presumed Ocular Histoplasmosis Syndrome

Turgut Yılmaz, Seyhan Dikci, Oğuzhan Genç, Kayhan Mutlu  
İnönü University Turgut Özal Medical Center, Department of Ophthalmology, Malatya, Turkey

## Abstract

Presumed ocular histoplasmosis syndrome (POHS) is a clinical entity that is characterized by small, round, discrete, macular or mid peripheral atrophic (punched out) chorioretinal lesions (histo spots), peripapillary scarring, choroidal neovascularization (CNV), and the absence of anterior uveitis and vitritis. Diagnosis of this disorder is based upon characteristic clinical findings and a positive histoplasmin skin test or residence in an endemic region for *Histoplasma capsulatum*. There is no active systemic disease during diagnosis of POHS. Disciform scarring and macular CNV secondary to POHS is a well-known complication which leads to loss of visual acuity or visual disturbance. Without therapy, the visual prognosis in these patients is unfavorable. Submacular surgery, radiation, steroids, photodynamic therapy, and most recently anti-vascular endothelial growth factor therapy are current therapeutic options for this condition. We report a case with persistent CNV secondary to POHS in a middle-aged woman with moderate myopia and the clinical course of treatment with multiple intravitreal ranibizumab (Lucentis®, Novartis) injections.

**Keywords:** Choroidal neovascularization, histoplasmosis, intravitreal injection, ranibizumab

## Introduction

Presumed ocular histoplasmosis syndrome (POHS) was first described in 1959 by Woods and Wahlen<sup>1</sup> as peripheral chorioretinal scar and hemorrhagic macular disciform lesion in a patient with positive histoplasmin skin test. Today, POHS is accepted as an entity characterized by small, round, discrete, atrophic mid-peripheral chorioretinal lesions (called histo spots), peripapillary scarring, and choroidal neovascularization (CNV).<sup>2</sup> These patients do not exhibit anterior segment or vitreous inflammation. Diagnosis is based on typical clinical findings, as well as positive histoplasmin skin test or history of exposure to the pathogen such as residence in an endemic area for *Histoplasma capsulatum*.<sup>3</sup> The histoplasmin skin test becomes positive soon after exposure and remains positive throughout life. However, this test is not used in contemporary practice due to the possibility (albeit unproven) that the histoplasmin skin test can reactivate latent ocular disease.<sup>3</sup> Although *H. capsulatum* can rarely be isolated or cultured in patients suspected of having POHS, patients with typical clinical findings are considered to have this fungal infection.<sup>4</sup>

The main causes of vision loss associated with POHS are macular CNV and formation of disciform scar. Without treatment, the prognosis for these patients is poor.<sup>2</sup> Treatment should aim to minimize the area of scarring and thus reduce the size of scotoma. In this report, we present a case with persistent CNV secondary to POHS in a myopic, middle-aged woman treated with multiple intravitreal ranibizumab (Lucentis®, Novartis) injections.

## Case Report

A 50-year-old female patient presented to our clinic with vision loss in her left eye that she noticed 3 months earlier. She had refractive errors of -3.50 (-1.25x135) in the right eye and -4.00 (-1.00x180) in the left eye. Her best corrected visual acuity (BCVA) was 1.0 in the right eye and 0.6 in the left eye. Anterior segment examination and intraocular pressure measured by Goldmann applanation tonometry were normal in both eyes. Fundus examination with 90-D lens revealed peripapillary atrophy and peripheral tigroid fundus

**Address for Correspondence:** Seyhan Dikci MD, İnönü University Turgut Özal Medical Center, Department of Ophthalmology, Malatya, Turkey  
Phone: +90 505 795 00 31 E-mail: seyhandikci@gmail.com **Received:** 12.04.2015 **Accepted:** 16.06.2015

©Copyright 2017 by Turkish Ophthalmological Association  
Turkish Journal of Ophthalmology, published by Galenos Publishing House.

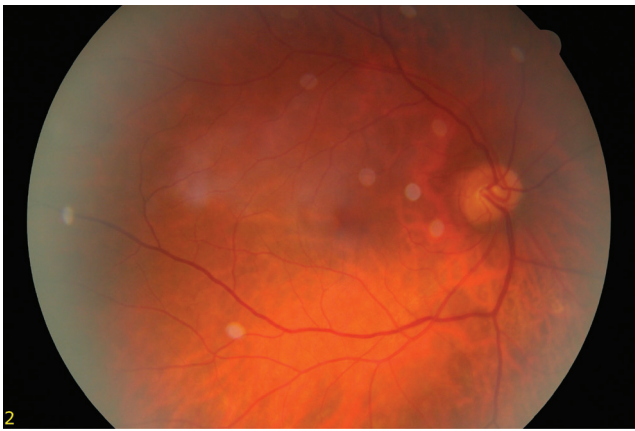in both eyes. Furthermore, tilted optic disc was observed in the right eye, while lesions consistent with macular CNV and a few small, discrete mid-peripheral chorioretinal scars were observed in the left eye (Figures 1 and 2). Fundus fluorescein angiography examination revealed juxtafoveal leakage consistent with classic CNV in the left eye (Figure 3). Optical coherence tomography revealed intraretinal and subretinal fluid due to CNV in the left eye (Figure 4). A detailed history was obtained and it was learned that the patient had a pet bird. She was diagnosed with POHS based on typical clinical findings. Intravitreal ranibizumab therapy was

recommended to treat the CNV. During 1.5 years of follow-up, a total of 5 ranibizumab (Lucentis®, Novartis) injections were applied, with the first 3 administered once a month over the first 3 months. After the injections, the CNV regressed leaving a subretinal scar, and the patient's BCVA in the left eye remained at 0.3 (Figure 5).

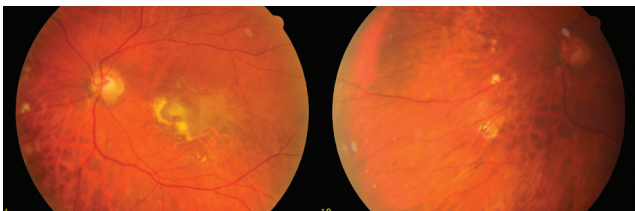
### Discussion

*Histoplasma capsulatum* is a dimorphic fungus generally carried by birds and bats. It is distributed worldwide and is endemic in some regions, such as the USA.<sup>5</sup> Ocular symptoms usually emerge years after exposure to the agent. There are no specific anterior or posterior segment inflammation signs specific to POHS that distinguish it from other retinopathies.<sup>6</sup> Multifocal choroiditis (MFC) is among a group of diseases called primary inflammatory choriocapillaropathies whose pathology involves choriocapillaris perfusion abnormalities.<sup>7</sup> POHS can be difficult to differentiate from MFC because their clinical and FA findings are similar. As in MFC, inflammatory CNV leading to vision loss or visual disturbances is also common in POHS.<sup>7</sup> However, while anterior segment and vitreous inflammation are evident in MFC, this sign is absent in POHS. Furthermore, punctate inner choroidopathy, pathologic myopia, sarcoidosis, tuberculosis, and other causes of chorioretinitis may be considered.<sup>3</sup>

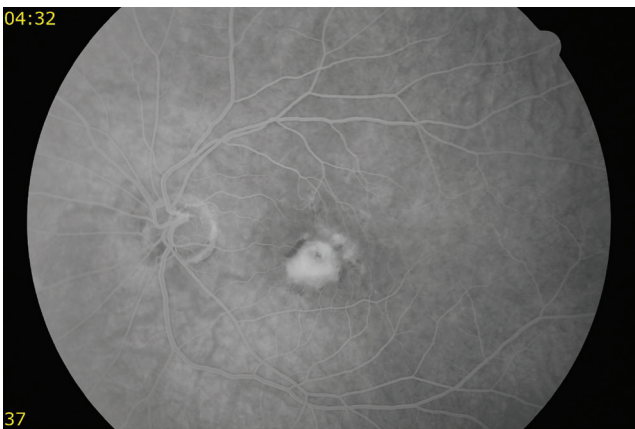
POHS-associated CNV generally occurs in the second and fifth decades and often develops as classic CNV.<sup>8</sup> The disease remains asymptomatic until the macula is affected. Central vision loss is generally seen in the affected eye due to scar formation after serous or hemorrhagic detachment related to



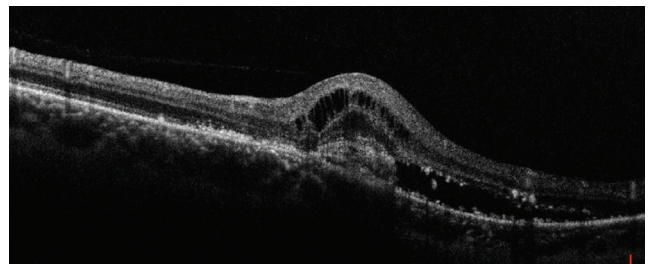
**Figure 1.** Tilted optic disc and tigroid fundus in the right eye



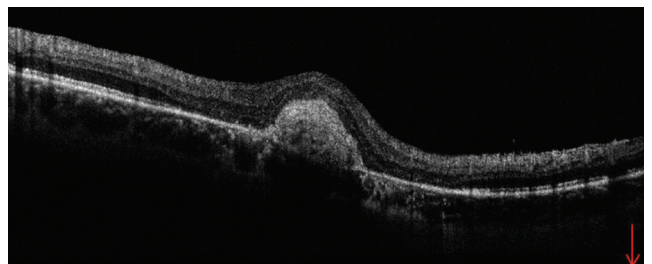
**Figure 2.** Lesions consistent with macular choroidal neovascularization and a few small, discrete mid-peripheral chorioretinal scars in the left eye



**Figure 3.** Fundus fluorescein angiography shows juxtafoveal leakage consistent with classic choroidal neovascularization in the left eye



**Figure 4.** Optical coherence tomography shows intraretinal and subretinal fluid due to choroidal neovascularization in the left eye



**Figure 5.** Optical coherence tomography shows the subretinal scar post-treatment

CNV. It is estimated that 5% of POHS patients will develop disciform lesions, and there are findings indicating that these develop in areas of the fundus with previous atrophic scar.<sup>4</sup> On that basis, the incidence of disciform lesion development is predicted to be 10 times higher in patients with perimacular atrophic scars compared to those without lesions in this region.<sup>4</sup> Vision of 20/40 or better could be preserved in only 15% of patients with CNV involving the fovea. Compared to other causes of CNV, the rate of fellow eye involvement is lower at 1.5 to 2% per year.<sup>4</sup> Visual prognosis is poor in POHS patients, and 20% of patients develop bilateral disciform macular disease.<sup>4</sup> POHS is also one of the rarer causes of peripapillary CNV.<sup>9</sup> Young age, good initial visual acuity, a relatively smaller CNV area, and lack of fellow eye involvement are criteria for good prognosis.<sup>3</sup>

Because the pathophysiology of POHS is not fully understood, current treatment approaches target CNV, which is a major cause of vision loss in these patients.<sup>5</sup> These treatments include laser photocoagulation, photodynamic therapy (PDT), local and systemic corticosteroids, radiation, submacular surgery, macular translocation and, most recently, intravitreal anti-vascular endothelial growth factor (anti-VEGF) implantation.<sup>2,4,5,10,11</sup> With the exception of anti-VEGF therapy, all of these approaches have potential drawbacks and high recurrence rates.<sup>2</sup> Studies on the causes of inflammatory CNV have shown that VEGFs contribute to CNV development and progression in these types of cases.<sup>4</sup> Although it is not known exactly what causes POHS-associated CNV, available data suggest that angiogenetic factors like VEGFs play an important role. As a result, anti-VEGF therapy appears to have an important role in the treatment of this disease.<sup>4</sup> Case reports and case series support the efficacy of anti-VEGF agents in the treatment of CNV secondary to POHS.<sup>4,12,13,14</sup>

The efficacy of ranibizumab to treat CNV was investigated in a phase 1, randomized clinical study including a total of 30 patients (9 POHS patients) with CNV due to causes other than age-related macular degeneration and was reported to be effective in these patients.<sup>12</sup> Nielsen et al.<sup>13</sup> stated that anti-VEGF agents were beneficial in the treatment of CNV related to ocular histoplasmosis syndrome and found that these patients required an average of 4.5 intravitreal injections per year. Recently, Ramaiya et al.<sup>14</sup> compared the efficacy and safety of PDT and intravitreal ranibizumab in the treatment of POHS-associated CNV and found that all patients in the PDT group required rescue ranibizumab injections and that the mean injection number was 7.7 in the ranibizumab group and 2.5 in the PDT group. None of the patients in either group had vision loss during the follow-up period; at 1-year follow-up, 80% of the ranibizumab group and 50% of the PDT group showed visual gains of 15 letters or more. Based on these results, Ramaiya et al.<sup>14</sup> emphasized that ranibizumab alone or in combination with PDT may be effective treatment options

for neovascular complications associated with POHS. None of the studies mentioned reported serious side effects related to treatment.<sup>12,13,14</sup> In our case, CNV regressed after a total of 5 doses of intravitreal ranibizumab, leaving a subretinal scar.

## Conclusion

Turkey is not among the areas where *Histoplasma capsulatum* is endemic, and thus POHS is not a common clinical condition in Turkey. Intravitreal pharmacotherapy is widely used to treat CNV arising due to various causes. For these rare cases, practitioners should keep in mind that intravitreal ranibizumab injection is a safe and effective treatment method and that multiple anti-VEGF injections may be required.

## Ethics

Informed Consent: Informed consent was provided by patient.  
Peer-review: Externally peer-reviewed.

## Authorship Contributions

Surgical and Medical Practices: Turgut Yılmaz, Seyhan Dikci, Oğuzhan Genç, Concept: Turgut Yılmaz, Seyhan Dikci, Design: Turgut Yılmaz, Seyhan Dikci, Data Collection or Processing: Seyhan Dikci, Kayhan Mutlu, Analysis or Interpretation: Turgut Yılmaz, Seyhan Dikci, Literature Search: Seyhan Dikci, Kayhan Mutlu, Writing: Seyhan Dikci, Turgut Yılmaz

Conflict of Interest: No conflict of interest was declared by the authors.

Financial Disclosure: The authors declared that this study received no financial support.

## References

1. Woods AC, Wahlen HE. The propable role of benign histoplasmosis in the etiology of granulomatous uveitis. *Am J Ophthalmol.* 1960;49:205-220.
2. Adan A, Navarro M, Casaroli-Marano RP, Ortiz S, Molina JJ. Intravitreal bevacizumab as initial treatment for choroidal neovascularization associated with presumed ocular histoplasmosis syndrome. *Graefes Arch Clin Exp Ophthalmol.* 2007;245:1873-1875.
3. Tsai JH, Smith RE. Ocular Histoplasmosis. In: Albert DM, Miller JW, Azar DT, Blodi BA, eds. *Albert and Jacobiec's Principles and Practice of Ophthalmology* (3rd ed). Saunders Elsevier; North America; 2008:1211-1220.
4. Trevino R, Salvat R. Preventing reactivation of ocular histoplasmosis: guidance for patients at risk. *Optometry.* 2006;77:10-16.
5. Tsai CB, Tan CY, Yang PM, Chang KP. Bevacizumab treatment for choroidal neovascularization in a patient with chorioretinopathy resembling presumed ocular histoplasmosis syndrome. *Taiwan J Ophthalmol.* 2012;2:144-147.
6. Hatef A, Turkuoglu P, Ibrahim M, Sepah Y, Shulman M, Heo J, Lee JH, Channa R, Khwaja A, Rentiya Z, Shah SM, Do DV, Nguyen QD. Importance of proper diagnosis for management: multifocal choroiditis mimicking ocular histoplasmosis syndrome. *J Ophthalmic Inflamm Infect.* 2011;1:55-63.
7. Herbort CP, Papadia M, Piergiorgio N. Myopia and inflammation. *J Ophthalmic Vis Res.* 2011;6:270-283.

8. Holekamp NM, Halperin NS, Akduman L, Olk RJ. Ocular Histoplasmosis Syndrome. In: Albert DM, Miller JW, Azar DT, Blodi BA, eds. *Albert and Jacobiec's Principles and Practice of Ophthalmology*. (3rd ed). Saunders Elsevier; North America; 2008:2005-2022.
9. Kurtulmuşođlu MÖ, Özdek Ş, Gürelık G, Hasanreisöđlu B. Optik disk ödemine eşlık eden peripapiller koroidal neovasküler membran. *Ret-Vit*. 2008;16:145-148.
10. Rechtman E, Allen VD, Danis RP, Pratt LM, Harris A, Speicher MA. Intravitreal triamcinolone for choroidal neovascularization in ocular histoplasmosis syndrome. *Am J Ophthalmol*. 2003;136:739-741.
11. Özmert E. Koroid Neovasküler Membranlarının Cerrahi Tedavisi. *Ret-Vit*. 2004;12 (Özel Sayı):289-293.
12. Heier JS, Brown D, Ciulla T, Abraham P, Bankert JM, Chong S, Daniel PE Jr, Kim IK. Ranibizumab for choroidal neovascularization secondary to causes other than age-related macular degeneration: a phase I clinical trial. *Ophthalmology*. 2011;118:111-118.
13. Nielsen JS, Fick TA, Saggau DD, Barnes CH. Intravitreal anti-vascular endothelial growth factor therapy for choroidal neovascularization secondary to ocular histoplasmosis syndrome. *Retina*. 2012;32:468-472.
14. Ramaiya KJ, Blinder KJ, Ciulla T, Cooper B, Shah GK. Ranibizumab versus photodynamic therapy for presumed ocular histoplasmosis syndrome. *Ophthalmic Surg Lasers Imaging Retina*. 2013;44:17-21.



# Three-dimensional Optical Coherence Tomography Imaging and Treatment of Glaucomatous Optic Nerve Head Defects Associated with Schisis-like Maculopathy

Zafer Öztaş, Jale Menteş, Halil Ateş, Serhad Nalçacı  
Ege University Faculty of Medicine, Department of Ophthalmology, İzmir, Turkey

## Abstract

We present the three-dimensional (3D) spectral-domain optical coherence tomography (SD-OCT) findings of schisis-like maculopathy associated with structural changes of the optic nerve (ON) head as well as the treatment outcomes of a case of advanced glaucoma. In addition to ophthalmological examination, B-scan and 3D-SD-OCT images of the ON head, peripapillary retina, and the macula were obtained. The B-scan images only detected typical retinoschisis findings. However, the 3D-SD-OCT images of the ON head revealed defects of various sizes, shapes, and depths at the outer wall of the prelaminar and laminar regions of the ON canal. The 3D images were able to establish that these defects were both adjacent to and interconnected with the retinal layers. The patient successfully received 3D-SD-OCT-guided thermal laser treatment that is used in congenital optic disc pits complicated with macular schisis. In brief, 3D-SD-OCT is very useful for demonstrating the ON head defects that can lead to schisis-like maculopathy in cases of advanced glaucoma.

**Keywords:** Glaucoma, retinoschisis, optical coherence tomography

## Introduction

Acquired optic disc pits, a finding specific to glaucomatous optic nerve (ON) head damage, develop in association with localized depressions in the lamina cribrosa (LC). This special condition was first described by Radius et al.<sup>1</sup> in 1978. Acquired optic disc pit typically appears as a pale area at the inner periphery of the optical disc margin. Unlike congenital optic disc pits, acquired pits may form as a result of neuroretinal rim loss secondary to glaucoma.

Macular retinoschisis (or schisis-like maculopathy), a complication of congenital optic disc pits, and subsequent serous retinal detachment may also develop in acquired optic disc pits and result in serious vision loss. In fact, even in the absence of a detectable pit lesion, peripapillary and macular retinoschisis and associated serous macular detachment have been reported in glaucomatous eyes with severe optic disc cupping.<sup>2,3,4,5</sup> In recent years, optical coherence tomography (OCT) imaging techniques have allowed the detection of these pathologies, which can now

be visualized in the peripapillary area, ON head, and even the LC with the use of advanced techniques.<sup>6,7,8</sup>

This study presents the three-dimensional (3D) spectral domain (SD) OCT features and treatment outcomes of prelaminar and laminar defects in the walls of the ON canal caused by advanced glaucomatous ON head damage and leading to macular retinoschisis.

## Case Report

A 30-year-old man whose vision level exhibited diurnal fluctuations was referred to our clinic for bilateral macular retinoschisis. The patient underwent a detailed ophthalmologic examination including best corrected visual acuity (BCVA), slit-lamp examination, intraocular pressure measurement, fundus photography, and fluorescein angiography.

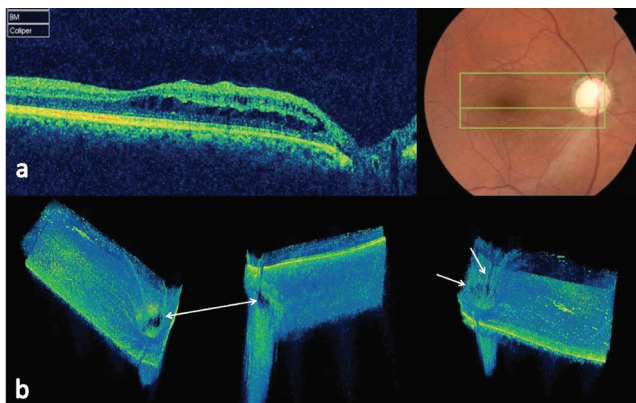
In addition, B-scan and 3D SD-OCT (Topcon 3D OCT-2000, Tokyo, Japan) images of the ON head, peripapillary retina, and macula were obtained and analyzed.

**Address for Correspondence:** Zafer Öztaş MD, Ege University Faculty of Medicine, Department of Ophthalmology, İzmir, Turkey  
Phone: +90 553 203 29 00 E-mail: zaferdr2000@gmail.com **Received:** 16.03.2015 **Accepted:** 06.07.2015



The patient's history revealed he had been diagnosed with closed-angle glaucoma and undergone bilateral trabeculectomy 6 years earlier. His BCVA fluctuated periodically, and was measured as 2/10 in the right eye and 10/10 in the left eye. Substantial BCVA fluctuations between 1/10 and 4/10 were noted in the patient's right eye prior to treatment. The patient also reported BCVA fluctuations in his left eye; the lowest measurement we obtained was 9/10. On slit-lamp examination, the anterior chambers of both eyes appeared quiet and the surgical iridectomies were open. The corneas and crystalline lenses of both eyes were clear. Right and left intraocular pressures were 12 and 13 mmHg with latanoprost and were measured as 11 and 15 mmHg during follow-up. Fundoscopic examination revealed cup-to-disc ratios of 1.0 and 0.9 in the right and left eyes, respectively, and no abnormalities were detected other than advanced glaucomatous cupping of the optic discs. Fundus fluorescein angiography was normal in both eyes. The OCT images were examined in detail in light of these findings. B-scan SD-OCT images showed retinoschisis-like cystic structures in the papillomacular and macular areas (an area about 4x4 mm between the ON and fovea) and separation of the outer retinal layers (Figure 1a). Furthermore, to determine the underlying pathologic causes, 3B-SD-OCT images were examined and revealed focal defects of at the outer ON margins in the prelaminar and lamellar regions of the ON head (Figure 1b).

Presuming that the intraretinal fluid was probably vitreous and may have leaked between the retinal layers through these defects, the patient was treated with thermal laser photocoagulation to the peripapillary areas adjacent to the defects. Under 3D-SD-OCT guidance, thermal laser settings similar to treat congenital optic disc pits (100 µm spot size, 0.3 s duration, 200 mW power) were used to produce the desired level of whiteness to the desired area using consecutive burns (Figure 2).



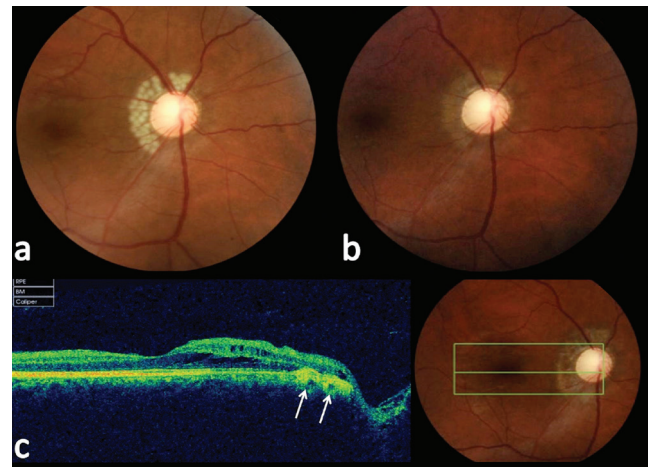
**Figure 1.** a) B-scan spectral-domain optical coherence tomography images showing retinoschisis-like cystic structures in the papillomacular and macular areas and separation of the outer retinal layers; b) three-dimensional-spectral-domain optical coherence tomography showing focal defects in the side walls of the optic nerve canal (white arrows)

Within 6 months after the laser therapy induced fibrosis and cicatrization of the peripapillary areas, the focal defects in the ON periphery were observed to markedly decrease in size, though some large defects did not resolve completely. The intraretinal fluid regressed substantially and BCVA stabilized (Figure 3). Furthermore, the fluctuations in visual acuity resolved. The patient was followed for a total of 24 months, during which the favorable outcomes persisted.

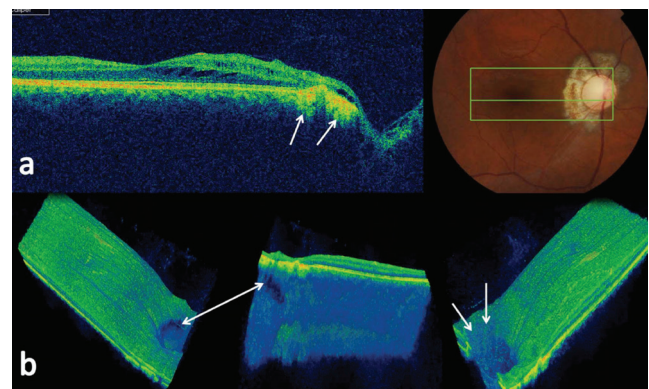
Although all examinations, imaging, and treatments were applied to both eyes, the findings were more pronounced in the right eye and these images are presented in this report. Due to inconsistencies in the patient's visual field test, evaluations related to visual field are not presented here.

### Discussion

Macular retinoschisis, a term used to describe large separations of the retinal layers in the posterior pole, often



**Figure 2.** a) Peripapillary thermal laser therapy, b) peripapillary atrophy, c) B-scan optical coherence tomography showing peripapillary fibrosis and cicatrization (white arrows)



**Figure 3.** a) B-scan optical coherence tomography images taken 6 months after treatment showing marked regression of intraretinal fluid, and peripapillary fibrosis and cicatrization (white arrows); b) three-dimensional spectral-domain optical coherence tomography images showing incomplete closure of a large lamellar defect (white arrow) and complete closure of small prelaminar defects (white arrows)

accompanies congenital optic disc pits. Macular retinoschisis may also form due to various reasons such as tractional causes, venous occlusive diseases, cystoid macular edema, and juvenile retinoschisis.<sup>9</sup> This condition, also called optic disc maculopathy, may also be seen with acquired optic disc pits. Cases of macular retinoschisis without a visible pit have been reported recently in patients with advanced closed- or narrow-angle glaucoma.<sup>2,3,4,5</sup> These studies reported that retinoschisis and possibly subsequent serous macular detachment may have developed as a result of a small hole associated with elevated intraocular pressure. The aim of this case report was to investigate the 3D-SD-OCT characteristics of peripheral ON head focal defects which developed in the absence of a visible pit and led to macular retinoschisis in a patient with advanced glaucoma, and to present the results of 3D-SD-OCT-guided thermal laser therapy.

In the present study, we closely evaluated optic disc, peripapillary, and macular OCT images in order to determine the primary cause of retinoschisis in our patient. While peripapillary and macular cystoid cavities and detachment of the outer retinal layers were detected on standard B-scan SD-OCT imaging, 3D-SD-OCT imaging revealed optically dark (empty) defects in the optic disc margins at the prelaminar and laminar levels. In our search of the literature to identify these defects, we found reports of pathologies with similar appearance in recent studies using enhanced-depth imaging (EDI) OCT and swept source (SS) OCT.<sup>6,7,8</sup> Using EDI-OCT, You et al.<sup>7</sup> described LC holes and defects appearing as LC degeneration adjacent to the side walls of the ON canal in patients with advanced glaucomatous neuroretinal rim thinning. Takayama et al.<sup>8</sup> used SS-OCT to demonstrate similar defects in the LC region in glaucomatous eyes. Kiumehr et al.<sup>10</sup> examined the LC region of normal and glaucomatous eyes using EDI-OCT and found focal LC defects in 76% of glaucomatous eyes. They noted that a large proportion of these defects are not detected during routine examinations, and found that the LC of healthy eyes was intact. These advances in OCT imaging techniques have enabled the visualization of the optic disc pit and deeper optic disc structures such as the LC. These studies confirmed that focal defects may develop in the LC.<sup>6,7,8,10</sup> In our patient, the focal glaucomatous defects in the peripheral ON and their relationship to the areas of macular retinoschisis were shown with 3D-SD-OCT. Due to the inadequate tissue penetration of SD-OCT, the LC area adjacent to these defects could not be clearly evaluated.

There is a debate as to whether the intraretinal fluid seen in congenital optic disc pits is cerebrospinal fluid or vitreous. However, we believe that this fluid is vitreous that leaks in through focal defects in the outer layers of the optic nerve. Nevertheless, we found no OCT findings directly supporting the vitreous as the source of this fluid.

In our patient, macular retinoschisis caused fluctuations in vision, especially in the right eye. In order to stabilize

visual acuity, obtain a dry macula, and prevent possible serous macular detachment, we treated both of our patient's eyes with thermal laser therapy as used in congenital optic disc pits, under 3D-SD-OCT guidance. Due to the lack of serous retinal detachment accompanying the macular retinoschisis and the advanced glaucomatous ON damage, pars plana vitrectomy was considered risky in this patient, whose clinical signs were relatively mild.

Following treatment, the defects in the peripheral optic cup had substantially decreased in size, but larger and deeper defects did not close completely. Green argon thermal laser therapy resulted in fibrosis and scar tissue in the peripapillary regions adjacent to the defects which could prevent leakage of the vitreous between the retinal layers. Our patient showed substantial regression of the intraretinal fluid and stabilized visual acuity after treatment.

## Conclusion

In summary, 3D-SD-OCT imaging is useful and effective in detecting peripheral ON defects at the prelaminar and laminar levels which result in macular retinoschisis in advanced glaucoma patients, and in determining the efficacy of treatment.

## Ethics

Informed Consent: It was taken.

Peer-review: Externally peer-reviewed.

## Authorship Contributions

Surgical and Medical Practices: Jale Menteş, Zafer Öztaş, Concept: Jale Menteş, Zafer Öztaş, Serhad Nağacı, Halil Ateş, Design: Jale Menteş, Zafer Öztaş, Serhad Nağacı, Halil Ateş, Data Collection or Processing: Zafer Öztaş, Serhad Nağacı, Analysis or Interpretation: Jale Menteş, Zafer Öztaş, Serhad Nağacı, Halil Ateş, Literature Search: Jale Menteş, Zafer Öztaş, Serhad Nağacı, Halil Ateş, Writing: Jale Menteş, Zafer Öztaş.

Conflict of Interest: No conflict of interest was declared by the authors.

Financial Disclosure: The authors declared that this study received no financial support.

## References

1. Radius RL, Maumenee AE, Green WR. Pit-like changes of the optic nerve head in open-angle glaucoma. *Br J Ophthalmol.* 1978;62:389-393.
2. Hollander DA, Barricks ME, Duncan JL, Irvine AR. Macular schisis detachment associated with angle closure glaucoma. *Arch Ophthalmol.* 2005;123:270-272.
3. Kahook MY, Noecker RJ, Ishikawa H, Wollstein G, Kagemann L, Wojtkowski M, Duker JS, Srinivasan VJ, Fujimoto JG, Schuman JS. Peripapillary schisis in glaucoma patients with narrow angles and increased intraocular pressure. *Am J Ophthalmol.* 2007;143:697-699.
4. Zumbro DS, Jampol LM, Folk JC, Olivier MM, Anderson-Nelson S. Macular schisis and detachment associated with presumed acquired enlarged optic nerve head cups. *Am J Ophthalmol.* 2007;144:70-74.

5. Mavrikakis E, Lam WC. Macular schisis and detachment secondary to large optic nerve head cup: a newly recognized syndrome amenable to vitrectomy. *Acta Ophthalmol.* 2011;89:95-96.
6. Nuyen B, Mansouri K, N Weinreb R. Imaging of the Lamina Cribrosa using Swept-Source Optical Coherence Tomography. *J Current Glau Prac.* 2012;6:113-119.
7. You J, Park S, Su D, Teng CC, Liebmann JM, Ritch R. Focal lamina cribrosa defects associated with glaucomatous rim thinning and acquired pits. *JAMA Ophthalmol.* 2013;131:314-320.
8. Takayama K, Hangai M, Kimura Y, Morooka S, Nukada M, Akagi T, Ikeda HO, Matsumoto A, Yoshimura N. Three-dimensional imaging of lamina cribrosa defects in glaucoma using swept-source optical coherence tomography. *Invest Ophthalmol Vis Sci.* 2013;54:4798-4807.
9. Spaide RF, Costa DL, Huang SJ. Macular schisis in a patient without an optic disk pit optical coherence tomographic findings. *Retina.* 2003;23:238-240.
10. Kiumehr S, Park SC, Syril D, Teng CC, Tello C, Liebmann JM, Ritch R. In vivo evaluation of focal lamina cribrosa defects in glaucoma. *Arch Ophthalmol.* 2012;130:552-559.



# Intravitreal Bevacizumab in Vitreous Hemorrhage and Diabetes Mellitus

Beuy Joob\*, Viroj Wiwanitkit\*\*

\*Sanitation Medical Academic Center, Bangkok, Thailand

\*\*Hainan Medical University, China (Visiting Professor)

## Dear Editor,

The recent report on “Intravitreal Bevacizumab in Vitreous Hemorrhage and DM” is very interesting.<sup>1</sup> Alagöz et al.<sup>1</sup> noted that “intravitreal bevacizumab was found effective in cases with vitreous hemorrhage secondary to proliferative diabetic retinopathy in terms of reducing the need for surgery and increasing the rate of subjects to whom panretinal photocoagulation could be applied in the early period, although there was no impact on final visual acuity”.<sup>1</sup> There is no doubt that intravitreal bevacizumab can be a good alternative management. However, there are many concerns. First, the cost of intravitreal bevacizumab is high and it is an issue for further assessment of cost effectiveness. Second, although there is no serious complication due to intravitreal bevacizumab administration, subconjunctival hemorrhage is common and becomes an issue for consideration in diabetes mellitus cases.<sup>2,3</sup> Also, in cases with underlying severe diabetes mellitus, possible unwanted gastrointestinal side effects have been reported.<sup>4</sup> Onoda et al.<sup>4</sup> suggested that “ophthalmologists should apply alternative therapies instead of intravitreal bevacizumab to patients with severe diabetes mellitus”.

**Keywords:** Bevacizumab, vitreous hemorrhage, diabetes mellitus

## Ethics

Peer-review: Internally peer-reviewed.

## Authorship Contributions

Surgical and Medical Practices: Beuy Joob, Viroj Wiwanitkit, Concept: Beuy Joob, Viroj Wiwanitkit, Design: Beuy Joob, Viroj Wiwanitkit, Data Collection or Processing: Beuy Joob, Viroj Wiwanitkit, Analysis or Interpretation: Beuy Joob, Viroj Wiwanitkit, Literature Search: Beuy Joob, Viroj Wiwanitkit, Writing: Beuy Joob, Viroj Wiwanitkit.

**Conflict of Interest:** No conflict of interest was declared by the authors.

**Financial Disclosure:** The authors declared that this study received no financial support.

## References

1. Alagöz C, Yıldırım Y, Kocamaz M, Baz Ö, Çiçek U, Çelik B, Demirkale Hİ, Yazıcı AT, Taşkapılı M. The Efficacy of Intravitreal Bevacizumab in Vitreous Hemorrhage of Diabetic Subjects. *Turk J Ophthalmol.* 2016;46:221-225.
2. Okoye O, Okonkwo O, Oderinlo O, Hassan K, Ijasa A. Bilateral concomitant intravitreal anti-vascular endothelial growth factor injection: Experience in a Nigerian tertiary private eye care facility. *Niger J Clin Pract.* 2016;19:544-548.
3. Smith JM, Steel DH. Anti-vascular endothelial growth factor for prevention of postoperative vitreous cavity haemorrhage after vitrectomy for proliferative diabetic retinopathy. *Cochrane Database Syst Rev.* 2015:CD008214.
4. Onoda Y, Shiba T, Hori Y, Maeno T, Takahashi M. Two cases of acute abdomen after an intravitreal injection of bevacizumab. *Case Rep Ophthalmol.* 2015;6:110-114.

**Address for Correspondence:** Beuy Joob MD, Sanitation Medical Academic Center, Bangkok, Thailand  
Phone: 6624658292 E-mail: beuyjoob@hotmail.com **Received:** 17.11.2016 **Accepted:** 13.02.2017

## Response from the Authors

Dear Editor,

We thank Drs. Beuy Joob and Viroj Wiwanitkit for their commentary on our article "The Efficacy of Intravitreal Bevacizumab in Vitreous Hemorrhage of Diabetic Subjects". In our study, we found that intravitreal bevacizumab was effective in vitreous hemorrhage secondary to diabetic retinopathy in terms of reducing the need for surgery and increasing the rate of panretinal photocoagulation (PRP) completion in the early period.<sup>1</sup> It has been demonstrated that treatment with only intravitreal anti-vascular endothelial growth factor (anti-VEGF) in proliferative diabetic retinopathy (PDR) patients did not result in worse results compared to PRP treatment alone in 2 years follow-up; that is, PRP was not found superior to intravitreal anti-VEGF treatment.<sup>2</sup> Therefore, intravitreal anti-VEGF treatment might be considered as an alternative treatment option for PDR patients, though long-term results are needed. Drs. Beuy Joob and Viroj Wiwanitkit rightly pointed out that intravitreal anti-VEGF treatment is an expensive treatment; however, compared to a vitrectomy surgery, intravitreal bevacizumab is still more cost effective. Like all other intravitreal injection applications, intravitreal bevacizumab may also result in various complications. Subconjunctival hemorrhage is among the most common, but it does not have any impact on visual acuity or the course of the disease. It is well-known that a reduction occurs in serum and plasma-free VEGF levels after intravitreal anti-VEGF injections,<sup>3</sup> and that there is an increased risk of artherothrombotic events after systemic use of anti-VEGF agents. Fortunately, meta-analysis could not demonstrate any increased risk in clinical practice.<sup>4</sup> This is mostly because high-

risk patients such as subjects with a history of recent myocardial infarction or cerebrovascular event were not involved in the studies. In our clinical practice, we also do not administer any kind of intravitreal anti-VEGF treatment to those high-risk patients.

Best Regards

**Cengiz Alagöz, Yusuf Yıldırım, Murat Kocamaz, Ökkeş Baz, Uğur Çiçek, Burcu Çelik, Halil İbrahim Demirkale, Ahmet Taylan Yazıcı, Muhittin Taşkapılı**

**Beyoğlu Eye Training and Research Hospital, İstanbul, Turkey**

## References

1. Alagöz C, Yıldırım Y, Kocamaz M, Baz Ö, Çiçek U, Çelik B, Demirkale Hİ, Yazıcı AT, Taşkapılı M. The Efficacy of Intravitreal Bevacizumab in Vitreous Hemorrhage of Diabetic Subjects. *Turk J Ophthalmol.* 2016;46:221-225.
2. Writing Committee for the Diabetic Retinopathy Clinical Research Network, Gross JG, Glassman AR, Jampol LM, Inusah S, Aiello LP, Antoszyk AN, Baker CW, Berger BB, Bressler NM, Browning D, Elman MJ, Ferris FL, Friedman SM, Marcus DM, Melia M, Stockdale CR, Sun JK, Beck RW. Panretinal Photocoagulation vs Intravitreal Ranibizumab for Proliferative Diabetic Retinopathy: A Randomized Clinical Trial. *JAMA.* 2015;314:2137-2146.
3. Zehetner C, Kirchmair R, Huber S, Kralinger MT, Kieselbach GF. Plasma levels of vascular endothelial growth factor before and after intravitreal injection of bevacizumab, ranibizumab and pegaptanib in patients with age-related macular degeneration, and in patients with diabetic macular oedema. *Br J Ophthalmol.* 2013;97:454-459.
4. Virgili G, Parravano M, Menchini F, Brunetti M. Antiangiogenic therapy with anti-vascular endothelial growth factor modalities for diabetic macular oedema. *Cochrane Database Syst Rev.* 2012;12:CD007419.

## 2017 INTERNATIONAL CONGRESSES

**AAPOS 43<sup>rd</sup> Annual Meeting**  
2-6 April 2017, Nashville, TN, USA

**1<sup>st</sup> Balkan Ophthalmology Meeting**  
21-23 April 2017, Sarajevo, Bosnia and Herzegovina

**ASCRS 2017 Annual Meeting**  
5-9 May 2017, Los Angeles, CA, USA  
<http://www.ascrs.org/>

**ARVO**  
7-11 May 2017, Baltimore, MD, USA  
<http://www.arvo.org/>

**Euretina 2017**  
7-10 September 2017, Barcelona, Spain

**2017 ESA/AAPOS Joint Meeting**  
13-16 September 2017, Porto, Portugal  
<http://esa2017.com>

**EVER 2017**  
27-30 September 2017, Nice, France

**ESCRS**  
7-11 October 2017, Lisbon, Portugal  
<http://www.es CRS.org/>

**An International Perspective of Pediatric  
Ophthalmology and Strabismus AAPOS/CAPOS Joint  
Meeting**  
12-15 October 2017, Shanghai, China

**AAO**  
11-14 November 2017, New Orleans, LA, USA  
<http://www.aao.org/annual-meeting>

## 2017 NATIONAL CONGRESSES

**TOA March Symposium**  
18-20 March 2017, Erzurum, Turkey

**TOA April Course**  
7-9 April 2017, Ankara, Turkey

**TOA Spring Symposium**  
26-28 May 2017, İstanbul, Turkey

**TOA Live Surgery**  
16-18 June 2017, İstanbul, Turkey

**TOA Summer Symposium**  
22-24 September 2017, İzmir, Turkey

**TOA 51<sup>th</sup> National Congress**  
24-29 October 2017, Antalya, Turkey

# TURKISH JOURNAL OF OPHTHALMOLOGY

TJO



www.ofthalmoloji.org

Avrupa Konutları Kale, Maltepe Mah. Yedikule Çırpıcı Yolu Sk.9.Blok No:2 Kat.1 Ofis:1 Zeytinburnu-İstanbul-Turkey  
Phone: +90 212 801 44 36 -37 Fax: +90 212 801 44 39 E-mail: dergi@oftalmoloji.org

## Copyright Transfer Form

Corresponding author:.....

Registered number:.....

Title of Article:.....

We, the undersigned authors, accept that the Turkish Journal of Ophthalmology bears no responsibility for the manuscript concerned prior to its acceptance to the Journal. We guarantee that the submitted paper is original, has not previously been published in any other journal, and that, in the event that it is accepted for publication, in whole or in part, the Turkish Journal of Ophthalmology has obtained all permission necessary for publication, and the original copyright form has been submitted to the responsible directorship of publication of the Turkish Journal of Ophthalmology. By signing this form, we transfer copyright of the manuscript to the Turkish Journal of Ophthalmology.

The Turkish Journal of Ophthalmology follows the criteria defined by the International Committee of Medical Journal Editors for authorship of scientific articles; we hereby acknowledge the requirement that each and every person listed in this work should have made a considerable contribution during the creation of this work (such as study design; gathering, analyzing and interpreting the data; or in the writing and scientific review of the article). By signing the Copyright Transfer Form, we hereby declare that all persons identified within the list of authors below have fulfilled the above-mentioned criteria. The authors reserve the following rights.

**Note:** When used as stated above, a complete reference should be given indicating that the manuscript has been published in the Turkish Journal of Ophthalmology.

1. All proprietary rights, apart from copyright, such as patent rights, etc.
2. The right to use the manuscript in whole or in part in any future work such as books and lectures, free of charge.
3. The right to copy the manuscript for personal use, provided it is not offered for sale.

All authors sign as follows

Name - Surname.....Signature.....Date .....

Name - Surname.....Signature.....Date .....

Name - Surname.....Signature.....Date .....

Name - Surname.....Signature.....Date .....

Name - Surname.....Signature.....Date .....

Name - Surname.....Signature.....Date .....

Name - Surname.....Signature.....Date .....

Name - Surname.....Signature.....Date .....

Address for Correspondence:

Phone:

Fax:

E-mail:

This form should be filled out completely, including original signatures, scanned and submitted electronically together with your manuscript. If you are unable to upload the file, e-mail it as an attachment to dergi@oftalmoloji.org within three days of manuscript submission.

## Distance Visual Acuity Measurements Equivalency Table

ETDRS Standard Line Number						Spatial Frequency
	Qualitative Measurements	Decimal	Snellen	LogMAR	Angle of Resolution	Cycle per Degree
-3		2.00	20/10	-0.30	0.5	60.00
-2		1.60	20/12.5	-0.20	0.625	48.00
-1		1.25	20/16	-0.10	0.8	37.50
0		1.00	20/20	0.00	1	30.00
		0.90		0.05		27.00
1		0.80	20/25	0.10	1.25	24.00
		0.70		0.15		21.00
2		0.63	20/32	0.20	1.6	18.75
		0.60		0.22		18.00
3		0.50	20/40	0.30	2	15.00
4		0.40	20/50	0.40	2.5	12.00
		0.30		0.52		9.00
5		0.32	20/63	0.50	3.15	9.52
6		0.25	20/80	0.60	4	7.50
7		0.20	20/100	0.70	5	6.00
8		0.16	20/125	0.80	6.25	4.80
9		0.13	20/160	0.90	8	3.75
10	CF from 6 m	0.10	20/200	1.00	10	3.00
11	CF from 5 m	0.08	20/250	1.10	12.5	2.40
12	CF from 4 m	0.06	20/320	1.20	16	1.88
13	CF from 3 m	0.05	20/400	1.30	20	1.50
14		0.04	20/500	1.40	25	1.20
15	CF from 2 m	0.03	20/640	1.51	32	0.94
16		0.025	20/800	1.60	40	0.75
17		0.020	20/1000	1.70	50	0.60
18	CF from 1 m	0.016	20/1250	1.80	62.5	0.48
21	CF from 50 cm	0.008	20/2500	2.10	125	0.24
31	HM from 50 cm	0.0008	20/25000	3.10	1250	0.02

**Abbreviations:**

CF: Counting fingers, HM: Perception of hand motions, m= meter, cm= centimeter

**Equations of conversions for Microsoft Excel:**

- Log10 (Decimal Acuity)= LogMAR Equivalent

Power (10; -Logmar Equivalent)= Decimal Acuity (for English version of Microsoft Excel)

Kuvvet (10; -Logmar Equivalent)= Decimal Acuity (for Turkish version of Microsoft Excel)

**Reference**

Eğrilmez S, Akkın C, Erakgün T, Yağcı A. Standardization in evaluation of visual acuity and a comprehensive table of equivalent. Turk J Ophthalmol. 2002;32:132-136.



**Near Visual Acuity Measurements Related Equivalency Table\***

<b>Snellen</b>	<b>20/400</b>	<b>20/320</b>	<b>20/250</b>	<b>20/200</b>	<b>20/160</b>	<b>20/125</b>	<b>20/100</b>	<b>20/80</b>	<b>20/63</b>	<b>20/50</b>	<b>20/40</b>	<b>20/32</b>	<b>20/25</b>	<b>20/20</b>
Decimal	0.05	0.063	0.08	0.10	0.125	0.16	0.20	0.25	0.32	0.40	0.50	0.63	0.80	1.00
Jaeger	J19	J18	J17	J16	J15	J14	J13	J11	J9	J7	J5	J3	J2	J1
Times New Roman Point	60	48	36	30	24	18	14	12	10	8	6	5	4	3
LogMAR	1.3	1.2	1.1	1.0	0.9	0.8	0.7	0.6	0.5	0.4	0.3	0.2	0.1	0.0

\*Adapted from Rabbets RB: Visual acuity and contrast sensitivity. In: Rabbets RB, editor: Clinical visual optics. Edinburgh: Butterworth-Heinemann, 1998:19-61.