



www.offalmoloji.org

ISSN 2149-8695

# TURKISH JOURNAL OF OPHTHALMOLOGY

**TJO**

## Original Articles

*Changes in Anterior Chamber Depth after Phacoemulsification in Pseudoexfoliative Eyes and their Effect on Accuracy of Intraocular Lens Power Calculation*

Sirel Gür Güngör et al; Ankara, Turkey

*Comparison of Anterior Segment Measurements Obtained by Aladdin Optical Biometer and Sirius Corneal Topography*

Onur Polat et al; Afyonkarahisar, Turkey

*Does Retinal Neurodegeneration Seen in Diabetic Patients Begin in the Insulin Resistance Stage?*

Sedat Arıkan et al; Çanakkale, Turkey

*Intravitreal Bevacizumab Treatment in Type 2 Idiopathic Macular Telangiectasia*

Tuğba Aydoğan et al; İstanbul, Turkey

*Prevalence of Split Nerve Fiber Layer Bundles in Healthy People Imaged with Spectral Domain Optical Coherence Tomography*

Sirel Gür Güngör et al; Ankara, Turkey

*The Importance of Frozen Section-Controlled Excision in Recurrent Basal Cell Carcinoma of the Eyelids*

Berna Şahan et al; İstanbul, Turkey

## Review

*Use of Botulinum Neurotoxin in Ophthalmology*

Emel Başar and Ceyhan Arıcı; İstanbul, Turkey

## Case Reports

*Isolated Schwannoma of the Upper Eyelid Margin in a 50-year-old Male*

Mehmet Serdar Dervişoğulları et al; Konya, Ankara, Düzce, Turkey

*Cataract Surgery after Retinal Detachment Surgery with Arruga's Sutures: Case Report*

Erkan Ünsal et al; İstanbul, Turkey

*Focal Choroidal Excavation*

Zafer Cebeci et al; İstanbul, Turkey

## Letter to the Editor

*A Baseline Algorithm for Molecular Diagnosis of Genetic Eye Diseases: Ophthalmologist's Perspective*

Hande Taylan Şekeroğlu et al; Ankara, Turkey

**November  
December 2016**  
**46** Volume  
Issue **6**

# TURKISH JOURNAL OF OPHTHALMOLOGY



www.ofthalmoloji.org

TJO

## Editor-in-Chief

### Murat İRKEÇ, MD

Hacettepe University Faculty of Medicine, Department of Ophthalmology, Ankara, Turkey  
Areas of Interest: Cornea and Ocular Surface Disease, Glaucoma, Allergy and Immunology  
E-mail: mirkec@hacettepe.edu.tr

## Associate Editors

### Tomris ŞENGÖR, MD

İstanbul Bilim University Faculty of Medicine, Department of Ophthalmology, İstanbul, Turkey  
Areas of Interest: Cornea and Ocular Surface Disease, Contact Lens  
E-mail: tomris.sengor@gmail.com

### Sait EĞRİLMEZ, MD

Ege University Faculty of Medicine, Department of Ophthalmology, İzmir, Turkey  
Areas of Interest: Cornea and Ocular Surface Disease, Contact Lens, Refraction, Cataract and Refractive Surgery  
E-mail: saitegrilmez@gmail.com

### Özlem YILDIRIM, MD

Mersin University Faculty of Medicine, Department of Ophthalmology, Mersin, Turkey  
Areas of Interest: Uveitis, Medical Retina, Glaucoma  
E-mail: dryildirimoz@hotmail.com

### Banu BOZKURT, MD, FEBO

Selçuk University Faculty of Medicine, Department of Ophthalmology, Konya, Turkey  
Areas of Interest: Cornea and Ocular Surface Disease, Glaucoma, Allergy and Immunology  
E-mail: drbanubozkurt@yahoo.com

## Statistical Board

### Ahmet DİRİCAN

İstanbul University İstanbul Faculty of Medicine, Department of Biostatistics and Medical Informatics, İstanbul, Turkey

## Language Editor

Jacqueline Renee GUTENKUNST, Maryland, USA



## Publishing House

Molla Gürani Mah. Kaçamak Sokak No: 21, 34093  
Findıkzade-İstanbul-Turkey  
Phone: +90 212 621 99 25 Fax: +90 212 621 99 27  
E-mail: info@galenos.com.tr  
Printed at: Özgün Ofset Ticaret Ltd. Şti. Yeşilce Mah. Aytekin Sk.  
No: 21 34418 4. Levent / İstanbul / Turkey  
Phone: 0212 280 00 09 Certificate No: 13837  
Date of printing: December 2016  
International scientific journal published bimonthly.  
ISSN 2149-8695  
E-ISSN: 2149-8709

## Advisory Board

### Yonca Aydın Akova,

Bayındır Kavaklıdere Hospital, Ophthalmology Clinic, Ankara, Turkey

### Gürsoy Alagöz,

Sakarya University Faculty of Medicine, Department of Ophthalmology, Sakarya, Turkey

### Mehmet Baykara,

Uludağ University Faculty of Medicine, Department of Ophthalmology, Bursa, Turkey

### Jose M. Benitez-del-Castillo,

Universidad Complutense de Madrid, Hospital Clinico San Carlos, Department of Ophthalmology, Madrid, Spain

### Özlem Budakoğlu,

Ulucanlar Eye Research and Training Hospital, Department of Ophthalmology, Ankara, Turkey

### Güngör Sobacı,

Hacettepe University Faculty of Medicine, Department of Ophthalmology, Ankara, Turkey

### Bülent Gürlü,

Fatih University Faculty of Medicine, Department of Ophthalmology, İstanbul, Turkey

### Murat Doğru,

Keio University Faculty of Medicine, Department of Ophthalmology, Tokyo, Japan

### Kadircan Keskinbora,

Ophthalmology, Independent Practitioner, İstanbul, Turkey

### Anastasios G.P. Konstas,

Aristotle University of Thessaloniki, Department of Ophthalmology, Thessaloniki, Greece

### Anat Loewenstein,

Tel Aviv University Sackler Faculty of Medicine, Department of Ophthalmology, Tel Aviv, Israel

### Ahmet Maden,

Dokuz Eylül University Faculty of Medicine, Department of Ophthalmology, İzmir, Turkey

### Jale Menteş,

Ege University Faculty of Medicine, Department of Ophthalmology, İzmir, Turkey

### Mehmet Cem Mocan,

Hacettepe University Faculty of Medicine, Department of Ophthalmology, Ankara, Turkey

### Mehmet Okka,

Necmettin Erbakan University Meram Faculty of Medicine, Department of Ophthalmology, Konya, Turkey

### Sibel Oto,

Başkent University Faculty of Medicine, Department of Ophthalmology, Ankara, Turkey

### Pınar Çakar Özdal,

Ulucanlar Eye Research and Training Hospital, Department of Ophthalmology, Ankara, Turkey

### Hakan Özdemir,

Bezmialem Vakıf University Faculty of Medicine, Department of Ophthalmology, İstanbul, Turkey

### Afsun Şahin,

Osmangazi University Faculty of Medicine, Department of Ophthalmology, Eskişehir, Turkey

### İlknur Tuğal Tutkun,

İstanbul University İstanbul Faculty of Medicine, Department of Ophthalmology, İstanbul, Turkey

### Ahmet Tuncer Özmen,

Uludağ University Faculty of Medicine, Department of Ophthalmology, Bursa, Turkey

### Ayşen Topalkara,

Cumhuriyet University Faculty of Medicine, Department of Ophthalmology, Sivas, Turkey

### Murat Tunç,

Ankara Numune Research and Training Hospital, Department of Ophthalmology, Ankara, Turkey

### Zeliha Yazar,

Ankara Research and Training Hospital, Department of Ophthalmology, Ankara, Turkey;  
Kafkas University Faculty of Medicine, Department of Ophthalmology, Kars, Turkey

## The Turkish Journal of Ophthalmology is an official journal of the Turkish Ophthalmological Association.

On Behalf of Turkish Ophthalmological Association Owner

### T. Reha Ersöz,

Çukurova University Faculty of Medicine, Department of Ophthalmology, Adana, Turkey

# TURKISH JOURNAL OF OPHTHALMOLOGY



www.ofthalmoloji.org

TJO

## ABOUT US

The Turkish Journal of Ophthalmology (TJO) is the only scientific periodical publication of the Turkish Ophthalmological Association and has been published since January 1929. In its early years, the journal was published in Turkish and French. Although there were temporary interruptions in the publication of the journal due to various challenges, the Turkish Journal of Ophthalmology has been published continually from 1971 to the present.

The Turkish Journal of Ophthalmology is currently published in Turkish and English languages. TJO is an independent international periodical journal based on single-blind peer-review principle. TJO is regularly published six times a year and special issues are occasionally released. The aim of TJO is to publish original research papers of the highest scientific and clinical value at an international level. Furthermore, review articles, case reports, editorial comments, letters to the editor, educational contributions and congress/meeting announcements are released.

The target audience includes specialists and physicians in training in ophthalmology in all relevant disciplines.

The editorial policies are based on the "Recommendations for the Conduct, Reporting, Editing, and Publication of Scholarly Work in Medical Journals (ICMJE Recommendations)" by the International Committee of Medical Journal Editors (2013, archived at <http://www.icmje.org/>) rules.

The Turkish Journal of Ophthalmology is indexed in the **PubMed Central (PMC)**, **Web of Science-Emerging Sources Citation Index (ESCI)**, **Directory of Open Access Journals (DOAJ)**, **Gale/Cengage Learning**, **Index Copernicus**, **EBSCO Database**, **Scopus**, **Turkish Medline-National Citation Index**, **Turk Medline**, **Cinahl**, **Proquest**, **TUBITAK/ULAKBIM** and **Turkish Citation Index** databases.

### Open Access Policy

This journal provides immediate open access to its content on the principle that making research freely available to the public supports a greater global exchange of knowledge.

Open Access Policy is based on the rules of the Budapest Open Access Initiative (BOAI) <http://www.budapestopenaccessinitiative.org/>. By "open access" to peer-reviewed research literature, we mean its free availability on the public internet, permitting any users to read, download, copy, distribute, print, search, or link to the full texts of these articles, crawl them for indexing, pass them as data to software, or use them for any other lawful purpose, without financial, legal, or technical barriers other than those inseparable from gaining access to the internet itself. The only constraint on reproduction and distribution, and the only role for copyright in this domain, should be to give authors control over the integrity of their work and the right to be properly acknowledged and cited.

### Subscription Information

TJO is sent free of charge to subscribers. Address changes should be immediately reported to the affiliates and to the managing editor. Subscribers who do not receive the journal in the relevant time period should contact the managing editor. All published volumes in full text can be reached free of charge through the website [www.ofthalmoloji.org](http://www.ofthalmoloji.org). Requests for subscription should be addressed to the Turkish Ophthalmological Association.

Manuscripts can only be submitted electronically through the Journal Agent website (<http://journalagent.com/tjo/>) after creating an account. This system allows online submission and review.

### Membership Procedures

#### Turkish Ophthalmological Association

Bank Account: Yapı Kredi Bankası, Şehremini Şubesi 65774842

IBAN: TR10 0006 7010 0000 0065 7748 42

Annual Subscription: Domestic: 100.-TL (Tax Incl)

Abroad: 100 USD (Tax Incl.)

#### Correspondence Address

Editor-in-Chief, Murat İrkeç, MD, Professor in Ophthalmology  
Hacettepe University Faculty of Medicine, Department of Ophthalmology  
06100 Sıhhiye-Ankara-Turkey

**Phone:** +90 212 801 44 36/37 Fax: +90 212 801 44 39

**E-mail:** [mirkec@hacettepe.edu.tr](mailto:mirkec@hacettepe.edu.tr)

#### Secretary, Arzu Sevdasız

**E-mail:** [dergi@ofthalmoloji.org](mailto:dergi@ofthalmoloji.org) - [sekreter@ofthalmoloji.org](mailto:sekreter@ofthalmoloji.org)

**Address:** Avrupa Konutları Kale, Maltepe Mah. Yedikule Çırpıcı Yolu Sk.

9. Blok No: 2 Kat:1 Ofis:1 Zeytinburnu-Istanbul-Turkey

**Phone:** +90 212 801 44 36/37 Fax: +90 212 801 44 39

**Web Page:** [www.ofthalmoloji.org](http://www.ofthalmoloji.org)

#### Permissions

Requests for permission to reproduce published material should be sent to the editorial office.

**Editor-in-Chief:** Murat İrkeç, MD, Professor in Ophthalmology

**Address:** Avrupa Konutları Kale, Maltepe Mah. Yedikule Çırpıcı Yolu Sk.

9. Blok No: 2 Kat:1 Ofis:1 Zeytinburnu-Istanbul-Turkey

**Phone:** +90 212 801 44 36/37 Fax: +90 212 801 44 39

**Web Page:** [www.ofthalmoloji.org](http://www.ofthalmoloji.org)

**E-mail:** [dergi@ofthalmoloji.org](mailto:dergi@ofthalmoloji.org) - [sekreter@ofthalmoloji.org](mailto:sekreter@ofthalmoloji.org)

#### Advertisement

Applications for advertisement should be addressed to the editorial office.

**Address:** Avrupa Konutları Kale, Maltepe Mah. Yedikule Çırpıcı Yolu Sk.

9. Blok No: 2 Kat:1 Ofis:1 Zeytinburnu-Istanbul-Turkey

**Phone:** +90 212 801 44 36/37 Fax: +90 212 801 44 39

**Web Page:** [www.ofthalmoloji.org](http://www.ofthalmoloji.org)

**E-mail:** [dergi@ofthalmoloji.org](mailto:dergi@ofthalmoloji.org) - [sekreter@ofthalmoloji.org](mailto:sekreter@ofthalmoloji.org)

#### Publisher Corresponding Address

**Publisher:** Erkan Mor

Galenos Yayınevi Tic. Ltd. Şti.

**Address:** Molla Gürani Mah. Kaçamak Sk. No: 21, 34093

Fındıkzade-Istanbul-Turkey

**Phone:** +90 212 621 99 25 Fax: +90 212 621 99 27

**E-mail:** [info@galenos.com.tr](mailto:info@galenos.com.tr)

#### Instructions for Authors

Instructions for authors are published in the journal and on the website [www.ofthalmoloji.org](http://www.ofthalmoloji.org)

#### Material Disclaimer

The author(s) is (are) responsible for the articles published in the Turkish Journal of Ophthalmology.

The editor, editorial board and publisher do not accept any responsibility for the articles.

The journal is printed on acid-free paper.

## INSTRUCTIONS TO AUTHORS

The Turkish Journal of Ophthalmology is an official peer-reviewed publication of the Turkish Ophthalmological Association. Accepted manuscripts are published in both Turkish and English languages.

Manuscripts written in Turkish should be in accordance with the Turkish Dictionary and Writing Guide ("Türkçe Sözlüğü ve Yazım Kılavuzu") of the Turkish Language Association. Turkish forms of ophthalmology-related terms should be checked in the TODNET Dictionary ("TODNET Sözlüğü" <http://www.todnet.org/v3/sozluk/default.asp>) and used accordingly.

The Turkish Journal of Ophthalmology does not charge any article submission or processing charges.

A manuscript will be considered only with the understanding that it is an original contribution that has not been published elsewhere.

Reviewed and accepted manuscripts are translated either from Turkish to English or from English to Turkish by the Journal through a professional translation service. Prior to printing, the translations are submitted to the authors for approval or correction requests, to be returned within 7 days. If no response is received from the corresponding author within this period, the translation is checked and approved by the editorial board. The abbreviation of the Turkish Journal of Ophthalmology is TJO, however, it should be denoted as Turk J Ophthalmol when referenced. In the international index and database, the name of the journal has been registered as Turkish Journal of Ophthalmology and abbreviated as Turk J Ophthalmol.

The scientific and ethical liability of the manuscripts belongs to the authors and the copyright of the manuscripts belongs to the Turkish Journal of Ophthalmology. Authors are responsible for the contents of the manuscript and accuracy of the references. All manuscripts submitted for publication must be accompanied by the Copyright Transfer Form [copyright transfer]. Once this form, signed by all the authors, has been submitted, it is understood that neither the manuscript nor the data it contains have been submitted elsewhere or previously published and authors declare the statement of scientific contributions and responsibilities of all authors.

All manuscripts submitted to the Turkish Journal of Ophthalmology are screened for plagiarism using the 'iThenticate' software. Results indicating plagiarism may result in manuscripts being returned or rejected.

Experimental, clinical and drug studies requiring approval by an ethics committee must be submitted to the Turkish Journal of Ophthalmology with an ethics committee approval report confirming that the study was conducted in accordance with international agreements and the Declaration of Helsinki (revised 2008) (<http://www.wma.net/en/30publications/10policies/b3/>). The approval of the ethics committee and the fact that informed consent was given by the patients should be indicated in the Materials and Methods section. In experimental animal studies, the authors should indicate that the procedures followed were in accordance with animal rights as per the Guide for the Care and Use of Laboratory Animals (<http://oacu.od.nih.gov/regs/guide/guide.pdf>) and they should obtain animal ethics committee approval. Authors must provide disclosure/acknowledgment of financial or material support, if any was received, for the current study. If the article includes any direct or indirect commercial links or if any institution provided material support to the study, authors

must state in the cover letter that they have no relationship with the commercial product, drug, pharmaceutical company, etc. concerned; or specify the type of relationship (consultant, other agreements), if any.

Authors must provide a statement on the absence of conflicts of interest among the authors and provide authorship contributions.

The Turkish Journal of Ophthalmology is an independent international journal based on single-blind peer-review principles. The manuscript is assigned to the Editor-in-Chief, who reviews the manuscript and makes an initial decision based on manuscript quality and editorial priorities. Manuscripts that pass initial evaluation are sent for external peer review, and the Editor-in-Chief assigns an Associate Editor. The Associate Editor sends the manuscript to three reviewers (internal and/or external reviewers). The reviewers must review the manuscript within 21 days. The Associate Editor recommends a decision based on the reviewers' recommendations and returns the manuscript to the Editor-in-Chief. The Editor-in-Chief makes a final decision based on editorial priorities, manuscript quality, and reviewer recommendations. If there are any conflicting recommendations from reviewers, the Editor-in-Chief can assign a new reviewer.

The scientific board guiding the selection of the papers to be published in the Journal consists of elected experts of the Journal and if necessary, selected from national and international authorities. The Editor-in-Chief, Associate Editors, biostatistics expert and English language consultant may make minor corrections to accepted manuscripts that do not change the main text of the paper.

In case of any suspicion or claim regarding scientific shortcomings or ethical infringement, the Journal reserves the right to submit the manuscript to the supporting institutions or other authorities for investigation. The Journal accepts the responsibility of initiating action but does not undertake any responsibility for an actual investigation or any power of decision.

The Editorial Policies and General Guidelines for manuscript preparation specified below are based on "Recommendations for the Conduct, Reporting, Editing, and Publication of Scholarly Work in Medical Journals (ICMJE Recommendations)" by the International Committee of Medical Journal Editors (2013, archived at <http://www.icmje.org/>).

Preparation of research articles, systematic reviews and meta-analyses must comply with study design guidelines:

CONSORT statement for randomized controlled trials (Moher D, Schulz KF, Altman D, for the CONSORT Group. The CONSORT statement revised recommendations for improving the quality of reports of parallel group randomized trials. *JAMA* 2001; 285: 1987-91) (<http://www.consort-statement.org/>);

PRISMA statement of preferred reporting items for systematic reviews and meta-analyses (Moher D, Liberati A, Tetzlaff J, Altman DG, The PRISMA Group. Preferred Reporting Items for Systematic Reviews and Meta-Analyses: The PRISMA Statement. *PLoS Med* 2009; 6(7): e1000097.) (<http://www.prisma-statement.org/>);

STARD checklist for the reporting of studies of diagnostic accuracy (Bossuyt PM, Reitsma JB, Bruns DE, Gatsonis CA, Glasziou PP, Irwig LM, et al., for the STARD Group. Towards complete and accurate reporting of studies of diagnostic

accuracy: the STARD initiative. *Ann Intern Med* 2003;138:40-4.) (<http://www.stard-statement.org/>);

STROBE statement, a checklist of items that should be included in reports of observational studies (<http://www.strobe-statement.org/>);

MOOSE guidelines for meta-analysis and systemic reviews of observational studies (Stroup DF, Berlin JA, Morton SC, et al. Meta-analysis of observational studies in epidemiology: a proposal for reporting Meta-analysis of observational Studies in Epidemiology (MOOSE) group. *JAMA* 2000; 283: 2008-12).

### GENERAL GUIDELINES

Manuscripts can only be submitted electronically through the Journal Agent website (<http://journalagent.com/tjo/>) after creating an account. This system allows online submission and review.

The manuscripts are archived according to ICMJE, Index Medicus (Medline/PubMed) and Ulakbim-Turkish Medicine Index Rules.

Format: Manuscripts should be prepared using Microsoft Word, size A4 with 2.5 cm margins on all sides, 12 pt Arial font and 1.5 line spacing.

**Abbreviations:** Abbreviations should be defined at first mention and used consistently thereafter. Internationally accepted abbreviations should be used; refer to scientific writing guides as necessary.

**Cover letter:** The cover letter should include statements about manuscript type, single-journal submission affirmation, conflict of interest statement, sources of outside funding, equipment (if applicable), approval of language for articles in English and approval of statistical analysis for original research articles.

### REFERENCES

Authors are solely responsible for the accuracy of all references.

**In-text citations:** References should be indicated as a superscript immediately after the period/full stop of the relevant sentence. If the author(s) of a reference is/are indicated at the beginning of the sentence, this reference should be written as a superscript immediately after the author's name. If relevant research has been conducted in Turkey or by Turkish investigators, these studies should be given priority while citing the literature.

Presentations presented in congresses, unpublished manuscripts, theses, Internet addresses, and personal interviews or experiences should not be indicated as references. If such references are used, they should be indicated in parentheses at the end of the relevant sentence in the text, without reference number and written in full, in order to clarify their nature.

**References section:** References should be numbered consecutively in the order in which they are first mentioned in the text. All authors should be listed regardless of number. The titles of journals should be abbreviated according to the style used in the Index Medicus.

### Reference Format

**Journal:** Last name(s) of the author(s) and initials, article title, publication title and its original abbreviation, publication date, volume, the inclusive page numbers. Example: Collin JR, Rathbun JE. Involitional entropion: a review with evaluation of a procedure. *Arch Ophthalmol*. 1978;96:1058-1064.

## INSTRUCTIONS TO AUTHORS

**Book:** Last name(s) of the author(s) and initials, chapter title, book editors, book title, edition, place of publication, date of publication and inclusive page numbers of the extract cited.

**Example:** Herbert L. The Infectious Diseases (1st ed). Philadelphia; Mosby Harcourt; 1999:11;1-8.

**Book Chapter:** Last name(s) of the author(s) and initials, chapter title, book editors, book title, edition, place of publication, date of publication and inclusive page numbers of the cited piece.

**Example:** O'Brien TP, Green WR. Periocular Infections. In: Feigin RD, Cherry JD, eds. Textbook of Pediatric Infectious Diseases (4th ed). Philadelphia; W.B. Saunders Company; 1998:1273-1278.

**Books in which the editor and author are the same person:** Last name(s) of the author(s) and initials, chapter title, book editors, book title, edition, place of publication, date of publication and inclusive page numbers of the cited piece.

**Example:** Solcia E, Capella C, Kloppel G. Tumors of the exocrine pancreas. In: Solcia E, Capella C, Kloppel G, eds. Tumors of the Pancreas. 2nd ed. Washington: Armed Forces Institute of Pathology; 1997:145-210.

### TABLES, GRAPHICS, FIGURES, AND IMAGES

All visual materials together with their legends should be located on separate pages that follow the main text.

**Images:** Images (pictures) should be numbered and include a brief title. Permission to reproduce pictures that were published elsewhere must be included. All pictures should be of the highest quality possible, in

JPEG format, and at a minimum resolution of 300 dpi.

**Tables, Graphics, Figures:** All tables, graphics or figures should be enumerated according to their sequence within the text and a brief descriptive caption should be written. Any abbreviations used should be defined in the accompanying legend. Tables in particular should be explanatory and facilitate readers' understanding of the manuscript, and should not repeat data presented in the main text.

### BIOSTATISTICS

To ensure controllability of the research findings, the study design, study sample, and the methodological approaches and applications should be explained and their sources should be presented.

The "P" value defined as the limit of significance along with appropriate indicators of measurement error and uncertainty (confidence interval, etc.) should be specified. Statistical terms, abbreviations and symbols used in the article should be described and the software used should be defined. Statistical terminology (random, significant, correlation, etc.) should not be used in non-statistical contexts.

All results of data and analysis should be presented in the Results section as tables, figures and graphics; biostatistical methods used and application details should be presented in the Materials and Methods section or under a separate title.

### MANUSCRIPT TYPES

#### Original Articles

Clinical research should comprise clinical observation, new techniques or laboratories studies. Original research articles should include title, structured abstract, keywords relevant to the content of the article, introduction, materials and methods,

results, discussion, study limitations, conclusion, references, tables/figures/images and acknowledgement sections. Title, abstract and key words should be written in both Turkish and English. The manuscript should be formatted in accordance with the above-mentioned guidelines and should not exceed sixteen A4 pages.

**Title Page:** This page should include the title of the manuscript, short title, name(s) of the authors and author information. The following descriptions should be stated in the given order:

1. Title of the manuscript (Turkish and English), as concise and explanatory as possible, including no abbreviations, up to 135 characters
2. Short title (Turkish and English), up to 60 characters
3. Name(s) and surname(s) of the author(s) (without abbreviations and academic titles) and affiliations
4. Name, address, e-mail, phone and fax number of the corresponding author
5. The place and date of scientific meeting in which the manuscript was presented and its abstract published in the abstract book, if applicable

**Abstract:** A summary of the manuscript should be written in both Turkish and English. References should not be cited in the abstract. Use of abbreviations should be avoided as much as possible; if any abbreviations are used, they must be taken into consideration independently of the abbreviations used in the text. For original articles, the structured abstract should include the following sub-headings:

**Objectives:** The aim of the study should be clearly stated.

**Materials and Methods:** The study and standard criteria used should be defined; it should also be indicated whether the study is randomized or not, whether it is retrospective or prospective, and the statistical methods applied should be indicated, if applicable.

**Results:** The detailed results of the study should be given and the statistical significance level should be indicated.

**Conclusion:** Should summarize the results of the study, the clinical applicability of the results should be defined, and the favorable and unfavorable aspects should be declared.

**Keywords:** A list of minimum 3, but no more than 5 key words must follow the abstract. Key words in English should be consistent with "Medical Subject Headings (MESH)" ([www.nlm.nih.gov/mesh/MBrowser.html](http://www.nlm.nih.gov/mesh/MBrowser.html)). Turkish key words should be direct translations of the terms in MESH.

#### Original research articles should have the following sections:

**Introduction:** Should consist of a brief explanation of the topic and indicate the objective of the study, supported by information from the literature.

**Materials and Methods:** The study plan should be clearly described, indicating whether the study is randomized or not, whether it is retrospective or prospective, the number of trials, the characteristics, and the statistical methods used.

**Results:** The results of the study should be stated, with tables/figures given in numerical order; the results should be evaluated according to the statistical analysis methods applied. See General Guidelines for details about the preparation of visual material.

**Discussion:** The study results should be discussed in terms of their favorable and unfavorable aspects and they should be compared with the literature. The conclusion of the study should be highlighted.

**Study Limitations:** Limitations of the study should be discussed. In addition, an evaluation of the implications of the obtained findings/results for future research should be outlined.

**Conclusion:** The conclusion of the study should be highlighted.

**Acknowledgements:** Any technical or financial support or editorial contributions (statistical analysis, English/Turkish evaluation) towards the study should appear at the end of the article.

**References:** Authors are responsible for the accuracy of the references. See General Guidelines for details about the usage and formatting required.

#### Case Reports

Case reports should present cases which are rarely seen, feature novelty in diagnosis and treatment, and contribute to our current knowledge. The first page should include the title in Turkish and English, an unstructured summary not exceeding 150 words, and key words. The main text should consist of introduction, case report, discussion and references. The entire text should not exceed 5 pages (A4, formatted as specified above).

#### Review Articles

Review articles can address any aspect of clinical or laboratory ophthalmology. Review articles must provide critical analyses of contemporary evidence and provide directions of or future research. Most review articles are commissioned, but other review submissions are also welcome. Before sending a review, discussion with the editor is recommended.

Reviews articles analyze topics in depth, independently and objectively. The first chapter should include the title in Turkish and English, an unstructured summary and key words. Source of all citations should be indicated. The entire text should not exceed 25 pages (A4, formatted as specified above).

#### Letters to the Editor

Letters to the Editor should be short commentaries related to current developments in ophthalmology and their scientific and social aspects, or may be submitted to ask questions or offer further contributions in response to work that has been published in the Journal. Letters do not include a title or an abstract; they should not exceed 1,000 words and can have up to 5 references.

#### CORRESPONDENCE

All correspondence should be directed to the TJO editorial board:

**Post:** Turkish Ophthalmological Association  
Adress: Avrupa Konutları Kale, Maltepe Mah. Yedikule Çırpıcı Yolu Sk. 9. Blok No: 2 Kat:1 Ofis:1 Zeytinburnu-İstanbul-Turkey

**Phone:** +90 212 801 44 36/37 Fax: +90 212 801 44 39

**Web Page:** [www.ofthalmoloji.org](http://www.ofthalmoloji.org)

**E-mail:** [dergi@ofthalmoloji.org](mailto:dergi@ofthalmoloji.org) / [sekreter@ofthalmoloji.org](mailto:sekreter@ofthalmoloji.org)

# TURKISH JOURNAL OF OPHTHALMOLOGY



www.ofthalmoloji.org

TJO

## CONTENTS

### Original Articles

- 255 Changes in Anterior Chamber Depth after Phacoemulsification in Pseudoexfoliative Eyes and their Effect on Accuracy of Intraocular Lens Power Calculation  
Sirel Gür Güngör, Ahmet Akman, Leyla Asena, Mustafa Aksoy, Almila Sarıgül Sezenöz
- 259 Comparison of Anterior Segment Measurements Obtained by Aladdin Optical Biometer and Sirius Corneal Topography  
Onur Polat, Zeki Baysal, Serkan Özcan, Sibel İnan, Ümit Übeyt İnan
- 264 Does Retinal Neurodegeneration Seen in Diabetic Patients Begin in the Insulin Resistance Stage?  
Sedat Arıkan, İsmail Erşan, Mustafa Eroğlu, Mehmet Yılmaz, Hasan Ali Tufan, Baran Gencer, Selçuk Kara, Mehmet Aşık
- 270 Intravitreal Bevacizumab Treatment in Type 2 Idiopathic Macular Telangiectasia  
Tuğba Aydoğan, Gürkan Erdoğan, Cihan Ünlü, Ahmet Ergin
- 274 Prevalence of Split Nerve Fiber Layer Bundles in Healthy People Imaged with Spectral Domain Optical Coherence Tomography  
Sirel Gür Güngör, Ahmet Akman, Almila Sarıgül Sezenöz, Gülşah Tanrıaşıki
- 277 The Importance of Frozen Section-Controlled Excision in Recurrent Basal Cell Carcinoma of the Eyelids  
Berna Şahan, Ferda Çiftçi, Ferda Özkan, Vildan Öztürk

### Review

- 282 Use of Botulinum Neurotoxin in Ophthalmology  
Emel Başar, Ceyhan Arıcı

### Case Reports

- 291 Isolated Schwannoma of the Upper Eyelid Margin in a 50-year-old Male  
Mehmet Serdar Dervişoğulları, Yüksel Totan, Ümrhan Yıldırım
- 293 Cataract Surgery after Retinal Detachment Surgery with Arruga's Sutures: Case Report  
Erkan Ünsal, Kadir Eltutar, Osman Kızılay, Belma Karini
- 296 Focal Choroidal Excavation  
Zafer Cebeci, Şerife Bayraktar, Merih Oray, Nur Kır

### Letter to the Editor

- 299 A Baseline Algorithm for Molecular Diagnosis of Genetic Eye Diseases: Ophthalmologist's Perspective  
Hande Taylan Şekeroğlu, Gülen Eda Utine, Mehmet Alikasıfoğlu

## EDITORIAL

### 2016 issue 6 at a glance;

The final issue of 2016 contains 6 original articles, 3 case reports and a review for your reading pleasure.

In the third issue of 2016, Elgin et al. reported that greater anterior chamber deepening after cataract surgery in eyes with pseudoexfoliative glaucoma than in eyes with open-angle glaucoma without pseudoexfoliation syndrome. In this issue, Güngör et al. report their study in which they compared anterior chamber depth before and after cataract surgery in 22 eyes with pseudoexfoliation syndrome and 30 age-matched non-pseudoexfoliative eyes. They found that anterior depth increased by 0.46 mm in the pseudoexfoliation group versus 0.12 mm in the eyes with non-pseudoexfoliative cataract, a statistically significant difference. Their results add to the growing body of evidence supporting the need for approaches that take pseudoexfoliation into account in the formulas used to calculate intraocular lens power after cataract surgery.

The instruments available for measuring anterior segment structures continue to grow in number. Polat et al. evaluated the agreement between two of these devices, the Aladdin Pptic Biometer and the Sirius Corneal Topography system. Although measurements were strongly and significantly correlated, they observed significant differences in parameters like anterior chamber depth and K1 keratometric axis. This highlights the importance of being aware of these types of measurement variations in values obtained using different instruments when comparing case series in the literature.

Arıkan et al. report that in the insulin resistance phase, a stage in which patients are not yet expected to develop diabetic retinopathy, ganglion cell/inner plexiform layer thinning can be detected by optical coherence tomography prior to the development of functional loss manifesting as reduction in contrast sensitivity. It is beyond doubt that the ability to detect neural damage by noninvasive morphologic examination before functional losses occur is extremely valuable in order to prevent irreversible damage.

Aydoğan et al. followed 6 eyes of 5 patients with type 2 idiopathic macular telangiectasia for an average of 26 months and reported improved visual acuity and reduced central macular thickness in all cases. The increasingly popular anti-VEGF therapeutic agents seem to also have noteworthy utility in idiopathic macular telangiectasia.

Güngör et al. evaluated the presence of split nerve fiber bundles, which can mimic retinal nerve fiber layer (RNFL) loss, in 718 eyes of 359 normal, healthy eyes using spectral-domain optical coherence tomography. This study notably demonstrates that we should be cautious about labeling normal

variations revealed by our increasingly sensitive diagnostic instruments as pathologic. For patients whose optic disc appears normal and healthy on examination, especially cases where superior RNFL defects are seen on the RNFL deviation map, it is recommended to carefully analyze the RNFL thickness map and graph to detect split nerve fiber bundles.

Basal cell carcinoma (BCC) is the most common cutaneous tumor, and does not show metastasis to distant organs. Şahan et al. performed frozen section controlled excision in 35 eyes of 35 patients whose BCC recurred following a previous excision with visually determined surgical margins. They authors determined that frozen section may need to be repeated between 1 and 4 times per surgery and reported that the procedure was effective, resulting in a fairly low rate of re-recurrence, 5.7%, over the average follow-up period of 4.3 years.

This issue's review by Başar and Arıcı looks at the full range of esthetic and functional indications for the ophthalmic use of botulinum neurotoxin. We believe its inclusion of nearly the entirety of the recent relevant literature and its thorough description of the types of botulinum neurotoxin and clinically important details such as preparation and application methods make this review a valuable reference text.

Derişoğulları et al. share a case of Schwannoma in a rare clinical presentation: an isolated Schwannoma at the eyelid margin. Their case expands the differential diagnosis for eyelid margin tumors.

In their case report, Ünsal et al. document the possibility that Arruga sutures used for scleral buckling may cause intraocular invasion many years later and state that preventative measures should be taken against potential complications of procedures like cataract surgery in these patients. Their report brings a new awareness of medical implants and their long-term complications.

Cebeci et al. present 3 eyes of 2 patients diagnosed with focal choroidal excavation, a relatively rare entity that can be diagnosed using optical coherence tomography, and report the follow-up and treatment options.

Finally, in a letter to the Editor, Şekeroğlu et al. share their "basic algorithm for the molecular diagnosis of genetic eye diseases", prepared from an ophthalmologist's perspective, which they believe will save money and time, as well as lead to practical advances in diagnosis and treatment.

**Respectfully on behalf of the Editorial Board,**

**Sait Eğrilmez, MD**



# Changes in Anterior Chamber Depth after Phacoemulsification in Pseudoexfoliative Eyes and their Effect on Accuracy of Intraocular Lens Power Calculation

Sirel Gür Güngör, Ahmet Akman, Leyla Asena, Mustafa Aksoy, Almıla Sarıgül Sezenöz

Başkent University Faculty of Medicine, Department of Ophthalmology, Ankara, Turkey

## Summary

**Objectives:** To compare anterior chamber depth (ACD) changes after phacoemulsification surgery in patients with pseudoexfoliation syndrome (PEX) and normal patients using an anterior segment imaging method. Another aim of this study was to evaluate the effect of these changes on the accuracy of intraocular lens (IOL) power calculation and postoperative refraction.

**Materials and Methods:** Twenty-two eyes of 22 patients with PEX and 30 eyes of 30 normal patients who underwent uneventful phacoemulsification surgery and IOL implantation were included in the study. The ACD of all patients was evaluated preoperatively and at 3 months postoperatively with the ALLEGRO Oculyzer (WaveLight® Oculyzer™ II, Alcon, Novartis)-Scheimpflug imaging system.

**Results:** The postoperative mean ACD values were significantly larger than the preoperative ACD values in both groups ( $p < 0.001$  for both groups). The pre- to postoperative change in ACD was  $0.46 \pm 0.3$  mm in the PEX group, which was a larger change than seen in the normal patients ( $0.12 \pm 0.1$  mm) ( $p = 0.04$ ). The mean absolute errors (MAE) calculated with different IOL formulas (SRK/T, Haigis, Hoffer and Holladay 1 formulas) were comparable and no statistically significant difference was observed between the two groups ( $p = 0.21$ ).

**Conclusion:** Phacoemulsification induces more significant ACD changes in patients with PEX compared to normal patients. However, the MAE did not differ significantly between the groups.

**Keywords:** Anterior chamber depth, mean absolute error, phacoemulsification surgery, pseudoexfoliation syndrome

## Introduction

Accurate intraocular lens (IOL) power calculation in cataract surgery is essential to achieve the postoperative target refraction and high patient satisfaction.<sup>1</sup> The accuracy of IOL power calculation mainly depends on the accuracy of three factors: preoperative biometric data (axial length (AL), anterior chamber depth (ACD), lens thickness, and keratometric index), IOL power calculation formulas, and IOL power quality control by the manufacturer.<sup>1,2,3</sup> The true effective lens position (ELP) is defined as the effective distance from the anterior surface of the cornea to the lens plane.<sup>4</sup> ELP is the only parameter that cannot be measured preoperatively. Most biometric formulas estimate ELP mathematically by using keratometric data and AL. ELP plays a

key role in the accuracy of IOL power formulas.<sup>5</sup> Thus, a difference of only 1 mm in IOL position leads to approximately 1.25 diopter (D) change in refraction.<sup>6,7</sup> Therefore, correct estimation of ELP is a critical step in IOL power prediction.<sup>3</sup>

Patients with pseudoexfoliation syndrome (PEX) frequently undergo phacoemulsification and IOL implantation for cataract surgery; however, according to our clinical observations, refractive outcomes for (PEX) patients are less accurate than the normal population. We thought that this may be due to difficulties in calculating the ELP arising from zonular laxity in (PEX) patients.

The aim of this study was to compare the ACD changes in patients with (PEX) and normal eyes after phacoemulsification. Another aim of this study was to evaluate the effect of these changes on the postoperative refraction.

**Address for Correspondence:** Sirel Gür Güngör MD, Başkent University Faculty of Medicine, Department of Ophthalmology, Ankara, Turkey  
Phone: +90 312 212 68 68 E-mail: sirelgur@yahoo.com **Received:** 11.12.2015 **Accepted:** 02.03.2016

©Copyright 2016 by Turkish Ophthalmological Association  
Turkish Journal of Ophthalmology, Published by Galenos Publishing House



## Materials and Methods

A total of 52 eyes (22 eyes affected by (PEX) and 30 normal eyes) of 52 patients (22 men, 30 women) who underwent uneventful phacoemulsification surgery and IOL implantation performed between May 2013 and May 2014 were enrolled in this prospective study. Patients with corneal pathology, glaucoma, uveitis, previous eye surgery or eye trauma, posterior segment pathology, diabetes, and those using topical or systemic medications that might influence anterior segment parameters were excluded from the study.

In patients undergoing sequential bilateral phacoemulsification cataract surgery, we randomly selected (by coin toss) only one eye to be included in the study. Informed consent was obtained from all patients in compliance with the World Medical Association's Declaration of Helsinki. The local institutional review board approved the protocol.

One surgeon (A.A.) performed all operations under topical anesthesia. In all eyes, a 2.2 mm clear corneal incision through a temporal approach was created. Through this incision, a continuous curvilinear capsulorhexis measuring approximately 5.5 mm in diameter was performed. The hydrodissection was followed by phacoemulsification of the nucleus and cortex aspiration. The lens capsule was inflated with an ophthalmic viscosurgical device and the same foldable hydrophobic acrylic IOL (SN60WF AcrySof; Alcon Laboratories, Fort Worth, TX, USA) was placed in the capsular bag. The corneal wound was not sutured. There were no intraoperative or postoperative complications for any patients.

The ACDs of all patients were evaluated preoperatively and at the third month postoperatively with the ALLEGRO Oculyzer (WaveLight® Oculyzer™ II, Alcon, Novartis) - Scheimpflug imaging system, which is a diagnostic device based on the Pentacam HR technology, providing non-contact measurement and analysis of the complete anterior eye segment. The measurements were obtained by two blinded, independent observers (L.A. and M.A.) and averaged for analysis. All measurements were obtained under standard dim light conditions and without pupil dilation with the patient seated using a chinrest and forehead strap. Three measurements were obtained in each study eye and the mean value was used in quantitative analyses. Postoperative ACD was determined using inbuilt calipers on the Scheimpflug image (Figure 1) because of the possible failure to identify the anterior surface of the IOL.<sup>8</sup>

Preoperative AL, keratometric power, and ACD were also measured using the IOL-Master (Zeiss IOL-Master 500, Carl Zeiss Meditec, Jena, Germany). Preoperative biometric data in both groups were used in the IOL power formula to calculate the power of the implanted IOL, which was used to calculate predicted refractive spherical equivalent (SE). The power of the implanted IOL was determined using Haigis, SRK/T, Hoffer, and Holladay 1 formulas. Postoperative refractive errors were measured 3 months after cataract surgery using automatic refracto-keratometry (RKT-7700; Nidek, Hiroshi, Japan). The mean absolute error (MAE)

was defined as the average of the absolute value of the differences between the actual and predicted SE of the postoperative refractive error.

## Statistical Analysis

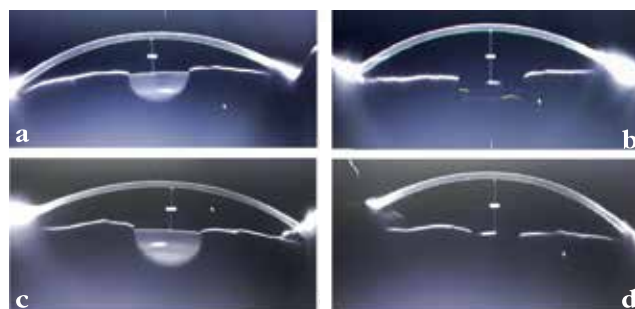
Statistical analysis was performed with SPSS for Windows version 13.0 (SPSS Inc, Chicago, IL, USA). All data were reported as means  $\pm$  standard deviations (SD). Normality of continuous variables in a group was determined by Shapiro-Wilks test. The variables showed normal distribution ( $p > 0.05$ ). Therefore, a paired t-test, chi-square test and Mann-Whitney U-test were used to compare variables between the pre- and postoperative periods. The predictive accuracy of the formula was analyzed by comparing the MAEs. A paired t-test was used to compare the between-group difference in MAEs calculated by the Haigis, SRK/T, Hoffer, and Holladay 1 formula. A repeated-measures analysis of variance was used to determine the between-group difference. The difference in MAEs between the formulas was assessed using the Tukey multiple comparison test. A value of  $p < 0.05$  was considered statistically significant.

## Results

Mean age was  $68.3 \pm 7.3$  years in the (PEX) group (8 men, 14 women) and  $67.4 \pm 5.8$  years in the normal group (14 men, 16 women). Preoperative refractive status was  $-1.42$  D in (PEX) patients and  $-1.26$  D in normal patients. There was no statistically significant difference with respect to gender and age between groups ( $p > 0.05$ ). Patients' characteristics are listed in Table 1.

Mean IOL power was  $21.21 \pm 2.1$  D (range, 17.5-23.5 D) in the (PEX) group and  $21.70 \pm 2.2$  D (range, 17.5-25 D) in the normal group ( $p = 0.67$ ). The AL measured by the IOL-Master was  $23.78 \pm 1.37$  mm (range, 22.02-25.53 mm) in the (PEX) group and  $23.48 \pm 0.80$  mm (range, 21.79-25.03 mm) in the normal group ( $p = 0.12$ ). There was no statistically significant difference in mean keratometric values between groups ( $43.37 \pm 2.20$  D in the (PEX) group;  $43.39 \pm 1.80$  D in the normal group;  $p = 0.23$ ).

The mean preoperative ACD was  $3.04 \pm 0.5$  mm in the (PEX) group and  $3.26 \pm 0.3$  mm in normal patients ( $p = 0.28$ ). At



**Figure 1.** ALLEGRO Oculyzer-Scheimpflug imaging system showing the changes in the anterior chamber depth induced by cataract surgery in an eye with pseudoexfoliation syndrome and in a normal eye. In the eye with pseudoexfoliation syndrome, the anterior chamber depth increased from 2.50 mm (a) to 3.85 mm (b). In the normal eye, the anterior chamber depth increased from 2.90 mm (c) to 3.80 mm (d)

postoperative month 3, the mean ACD was  $3.52 \pm 0.3$  mm in the (PEX) group and  $3.38 \pm 0.2$  mm in normal patients ( $p=0.35$ ). The postoperative mean ACD values were significantly higher than the preoperative ACD values in both groups ( $p<0.0001$  for both groups.). The difference between postoperative and preoperative ACD values was  $0.46 \pm 0.3$  mm in the (PEX) group, which was a greater change than in the normal patients ( $0.12 \pm 0.1$  mm) ( $p=0.04$ ).

The MAEs calculated by the SRK/T, Haigis, Hoffer and Holladay 1 formulas were comparable between the 2 groups ( $p>0.05$ ) (Table 2) and no statistically significant difference was observed with different formulas in the same group of patients ( $p=0.21$ , Tukey multiple comparison).

## Discussion

Reports in the literature concerning the overall ocular dimensions of eyes with (PEX) are controversial. Earlier studies that looked at ACD in eyes with (PEX) did not detect significant shallowing of the anterior chamber in comparison with normal control eyes.<sup>9,10</sup> In contrast, one recent study that analyzed age- and gender- matched patients with and without (PEX) found significantly smaller anterior segments in eyes with (PEX).<sup>11</sup> In addition, the anterior chamber volume was found to be significantly smaller in eyes with (PEX) than in eyes without (PEX).<sup>12</sup> In a study by Doganay et al.<sup>13</sup> evaluating anterior segment parameters in patients with (PEX) syndrome or (PEX) glaucoma with the Pentacam-Scheimpflug imaging system, ACD in the (PEX) glaucoma group ( $2.49 \pm 0.39$  mm) was found to be significantly lower than the control group and there was no statistically difference between the (PEX) group ( $2.50 \pm 0.29$  mm) and the control group ( $2.60 \pm 0.31$  mm). In our study, the

preoperative ACD values in the (PEX) group (3.04 mm) were lower than the normal group (3.26 mm) but the difference was not statistically significant.

The ALLEGRO Oculyzer is an easy-to-use, non-contact tomography system that uses a Scheimpflug rotating camera for the analysis of the anterior segment. The measurements taken by the system are fast and user-independent. Scheimpflug imaging has been reported to calculate the ACD with a mean SD of 20  $\mu$ m in healthy eyes.<sup>14</sup>

Significant changes in ACD measurements obtained by the Pentacam rotating Scheimpflug camera have been reported following phacoemulsification cataract surgery.<sup>15,16,17</sup> However, this is the first report comparing ACD changes after phacoemulsification surgery in (PEX) patients and normal patients.

Ucakhan et al.<sup>15</sup> demonstrated significant deepening of the anterior chamber using a Pentacam rotating Scheimpflug camera in healthy eyes. The mean preoperative ACD was  $3.0 \pm 0.8$  mm and the mean postoperative ACD was  $3.9 \pm 0.9$  mm. Similarly, the difference in ACD measured preoperatively and postoperatively was significant in a study by Doganay et al.;<sup>16</sup> who reported a mean preoperative ACD of  $2.79 \pm 0.42$  mm and mean postoperative ACD of  $4.63 \pm 0.57$  mm. The differences between the preoperative and postoperative ACD values in both of these studies were greater than those in our study. The refractive state of the patients is not mentioned by Ucakhan et al.<sup>15</sup> or Doganay et al.<sup>16</sup>; both groups also used the Pentacam but on slightly younger patients (and therefore with potentially thinner crystalline lenses preoperatively) than in our study. Dooley et al.<sup>17</sup> observed a significant increase in ACD after uneventful phacoemulsification cataract surgery in patients who had a tendency towards hypermetropia preoperatively

**Table 1. Characteristics of patients**

	Eyes with pseudoexfoliation syndrome (n=22)	Normal (n=30)	p
Age (years $\pm$ SD)	68.3 $\pm$ 7.5	67.4 $\pm$ 5.8	0.54*
Gender (male:female)	8:14	14:16	0.53 <sup>†</sup>
Laterality (right:left)	10:12	18:12	0.12 <sup>†</sup>
Refractive error (diopters)	-1.42 $\pm$ 0.21	-1.26 $\pm$ 0.32	0.83*
Intraocular pressure (mmHg)	18.3 $\pm$ 3.4	16.5 $\pm$ 7.1	0.44*
Follow-up period (months)	7.8 $\pm$ 4.5	6.3 $\pm$ 1.9	0.19*

\*Mann-Whitney U-test; <sup>†</sup>Chi-square test, SD: Standard deviation

**Table 2. Comparison of mean absolute error with different intraocular lens power calculation formulas in pseudoexfoliative and normal patients**

Mean absolute error (D)	Eyes with pseudoexfoliation syndrome (n=22)	Normal (n=30)	p
SRK T	0.42 $\pm$ 0.22	0.28 $\pm$ 0.37	0.38
Haigis	0.55 $\pm$ 0.18	0.39 $\pm$ 0.39	0.41
Hoffer	0.53 $\pm$ 0.17	0.33 $\pm$ 0.36	0.32
Holladay 1	0.45 $\pm$ 0.10	0.28 $\pm$ 0.22	0.3

D: Diopter

(median preoperative SE was +0.50 D, mean preoperative ACD was  $2.66 \pm 0.38$  mm and mean postoperative ACD was  $3.70 \pm 0.75$  mm). It has been shown that hypermetropes exhibit more dramatic changes in anterior segment parameters after cataract surgery.<sup>18</sup> In our study, the preoperative refractive status was -1.26 D in normal patients and -1.42 D in (PEX) patients. Mean increase in the ACD value (0.12 mm in the normal group; 0.46 mm in the (PEX) group) observed in our study was lower than those reported by previous authors.<sup>15,16,17</sup>

Recently developed biometric formulas (Haigis, Holladay 2) use preoperatively measured ACD to predict ELP.<sup>19,20</sup> It has long been known how significant ELP is in calculation of IOL power formulas.<sup>5,6,7</sup> Therefore, the amount of increase in the ACD postoperatively can affect the ELP and the accuracy of IOL power calculations. In this study, preoperative and postoperative ACD and MAE were evaluated and compared between (PEX) and normal groups. To our knowledge, this is the first study to evaluate the ACD and MAE following phacoemulsification surgery in eyes with (PEX). We observed that the increase in ACD values were higher in patients with (PEX) than the normal group. We thought that this difference might affect the ELP position and planned post-surgical refraction. However, the MAE calculated using different IOL calculation formulas did not differ significantly between the groups.

#### Ethics

Ethics Committee Approval: KA 15-24. Informed Consent: Obtained.

Peer-review: Externally peer-reviewed.

#### Authorship Contributions

Surgical and Medical Practices: Ahmet Akman, Concept: Ahmet Akman, Sirel Gür Güngör, Design: Ahmet Akman, Sirel Gür Güngör, Data Collection or Processing: Mustafa Aksoy, Almila Sarigül Sezenöz, Analysis or Interpretation: Sirel Gür Güngör, Leyla Asena, Literature Search: Sirel Gür Güngör, Writing: Sirel Gür Güngör, Ahmet Akman.

Conflict of Interest: No conflict of interest was declared by the authors.

Financial Disclosure: The authors declared that this study received no financial support.

#### References

1. Wang JK, Hu CY, Chang SW. Intraocular lens power calculation using the IOLMaster and various formulas in eyes with long axial length. *J Cataract Refract Surg.* 2008;34:262-267.
2. Olsen T. Sources of error in intraocular lens power calculation. *J Cataract Refract Surg.* 1992;18:125-129.
3. Findl O. Biometry and intraocular lens power calculation. *Curr Opin Ophthalmol.* 2005;16:61-64.
4. Cekic O, Batman C, Totan Y, Emre MI, Zilelioglu O. Changes in anterior chamber depth and intraocular pressure after phacoemulsification and posterior chamber intraocular lens implantation. *Ophthalmic Surg Lasers.* 1998;29:639-642.
5. Norrby S. Sources of error in intraocular lens power calculation. *J Cataract Refract Surg.* 2008;34:368-376.
6. Erickson P. Effects of intraocular lens position errors on postoperative refractive error. *J Cataract Refract Surg.* 1990;16:305-311.
7. Sanders DR, Higginbotham RW, Opatowsky IE, Confino J. Hyperopic shift in refraction associated with implantation of the single-piece Collamer intraocular lens. *J Cataract Refract Surg.* 2006;32:2110-2112.
8. Pereira FA, Cronemberger S. Ultrasound biomicroscopic study of anterior segment changes after phacoemulsification and foldable intraocular lens implantation. *Ophthalmology.* 2003;110:1799-1806.
9. Forsius H, Sveinsson K, Als E, Luukka H. Pseudoexfoliation of the lens capsule and depth of anterior chamber in northern Iceland. *Acta Ophthalmol (Copenh).* 1974;52:421-428.
10. Bartholomew RS. Anterior chamber depth in eyes with pseudoexfoliation. *Br J Ophthalmol.* 1980;64:322-323.
11. Jünemann A, Martus P, Handel A, Naumann GOH. Ocular dimensions in pseudoexfoliation syndrome. *Ophthalmic Res.* 1997;29:88.
12. Gharagozloo NZ, Baker RH, Brubaker RE. Aqueous dynamics in exfoliation syndrome. *Am J Ophthalmol.* 1992;114:473-478.
13. Doganay S, Tasar A, Cankaya C, Firat PG, Yologlu S. Evaluation of Pentacam-Scheimpflug imaging of anterior segment parameters in patients with pseudoexfoliation syndrome and pseudoexfoliative glaucoma. *Clin Exp Optom.* 2012;95:218-222.
14. Rabsilber TM, Khoramnia R, Auffarth GU. Anterior chamber measurements using Pentacam rotating Scheimpflug camera. *J Cataract Refract Surg.* 2006;32:456-459.
15. Ucakhan OO, Ozkan M, Kanpolat A. Anterior chamber parameters measured by the Pentacam CES after uneventful phacoemulsification in normotensive eyes. *Acta Ophthalmol.* 2009;87:544-548.
16. Doganay S, Bozgul Firat P, Emre S, Yologlu S. Evaluation of anterior segment parameter changes using the Pentacam after uneventful phacoemulsification. *Acta Ophthalmol.* 2010;88:601-606.
17. Dooley I, Charalampidou S, Malik A, Loughman J, Molloy L, Beatty S. Changes in intraocular pressure and anterior segment morphometry after uneventful phacoemulsification cataract surgery. *Eye (Lond).* 2010;24:519-526.
18. MacLaren RE, Natkunarajah M, Riaz Y, Bourne RR, Restori M, Allan BD. Biometry and formula accuracy with intraocular lenses used for cataract surgery in extreme hyperopia. *Am J Ophthalmol.* 2007;143:920-931.
19. Holladay JT. Standardizing constants for ultrasonic biometry, keratometry, and intraocular lens power calculations. *J Cataract Refract Surg.* 1997;23:1356-1370.
20. Olsen T, Corydon L, Gimbel H. Intraocular lens power calculation with an improved anterior chamber depth prediction algorithm. *J Cataract Refract Surg.* 1995;21:313-319.



# Comparison of Anterior Segment Measurements Obtained by Aladdin Optical Biometer and Sirius Corneal Topography

Onur Polat\*, Zeki Baysal\*\*, Serkan Özcan\*\*, Sibel İnan\*\*, Ümit Übeyt İnan\*\*

\*Afyonkarahisar State Hospital, Ophthalmology Clinic, Afyonkarahisar, Turkey

\*\*Afyon Kocatepe University Faculty of Medicine, Department of Ophthalmology, Afyonkarahisar, Turkey

## Summary

**Objectives:** To assess the agreement of anterior segment parameter measurements derived from Aladdin optical biometer using optical low coherence interferometer and Sirius corneal topography using combined Scheimpflug-Placido disk.

**Materials and Methods:** Data obtained using the Aladdin and Sirius systems from 110 eyes of 59 subjects who had no health problems other than refractive errors were retrospectively evaluated. Anterior chamber depth (ACD), flat (K1) and steep (K2) keratometry readings, and white-to-white distance (WTW) measurements taken with both devices were noted.

**Results:** The mean age of the patients was  $47.31 \pm 18.57$  years (range, 25 to 79 years). Mean ACD was  $3.35 \pm 0.4$  mm using Aladdin and  $3.42 \pm 0.44$  mm using Sirius. Mean difference in ACD was 0.075 mm greater with Sirius than Aladdin ( $p < 0.001$ ). K1 measurement obtained by Aladdin was an average of 0.409 D higher ( $p < 0.001$ ). No statistically significant differences were detected between the two devices in respect to K2 and WTW measurements ( $p = 0.18$ ,  $p = 0.85$  respectively). Pearson correlation analysis showed high correlation between the two devices for all measurements ( $r = 0.985$ ,  $0.895$ ,  $0.961$  and  $0.766$  for ACD, K1, K2 and WTW respectively;  $p < 0.001$ ).

**Conclusion:** Anterior segment parameters obtained by Aladdin optical biometer and Sirius anterior segment analysis system correlated well with each other and measurement differences between the devices were clinically negligible except for K1 values.

**Keywords:** Aladdin, optical biometer, anterior segment parameters, Sirius

## Introduction

The accurate and precise evaluation of anterior segment parameters is critical in order to diagnose many anterior segment diseases, to plan anterior segment surgeries, and to ensure satisfactory postoperative results, patient satisfaction and proper patient management. In recent years, various instruments/techniques including optical coherence tomography, ultrasonic biomicroscopy, Scheimpflug imaging, slit-scanning topography and interferometry have been commonly used in clinical practice to evaluate the anterior segment.<sup>1</sup>

The Aladdin optical biometry instrument (Topcon, Tokyo, Japan) is a new noncontact optical biometry instrument introduced into clinical use in 2012. The device operates on the optical low-

coherence interferometry principle and measures axial length (AL), anterior chamber depth (ACD), keratometry, corneal topography, white-to-white distance (WTW) and pupillometry values.<sup>2</sup>

The Sirius topography device (Costruzione Strumenti Oftalmici, Florence, Italy) is an anterior segment analysis system combining Scheimpflug camera and Placido disc technology. This system provides data for corneal thickness, ACD, aqueous depth, lens thickness, keratometry, WTW, pupillography, anterior and posterior corneal topography and corneal wavefront analysis.<sup>3</sup>

There are studies in the literature demonstrating measurement reproducibility for both of these instruments.<sup>2,3,4,5</sup> However, we were unable to find any published studies examining the agreement between measurements obtained using the two devices.

**Address for Correspondence:** Onur Polat MD, Afyonkarahisar State Hospital, Ophthalmology Clinic, Afyonkarahisar, Turkey  
Phone: +90 536 615 62 50 E-mail: dr\_onurpolatt@hotmail.com **Received:** 20.05.2015 **Accepted:** 06.01.2016

©Copyright 2016 by Turkish Ophthalmological Association  
Turkish Journal of Ophthalmology, Published by Galenos Publishing House

In this study we aimed to compare and assess the agreement between anterior segment parameters measured using the Aladdin optical biometer and data obtained using the Sirius corneal topography system.

## Materials and Methods

One hundred ten eyes of 59 healthy subjects who had no pathology other than refractive errors and underwent measurements using both the Aladdin and Sirius devices in our clinic between May 2014 and October 2014 were included in the study and retrospectively evaluated.

Subjects who had a history of ocular surgery, refractive errors greater than  $\pm 3$  diopters (D), ocular surface problems, topical medication use, or difficulty fixating were not included in the study. The study was designed in accordance with the principles of the Declaration of Helsinki and approval was granted by our departmental ethics committee.

Patients' demographic data and values for ACD, flat (K1) and steep (K2) keratometry, and WTW obtained using both instruments were recorded.

### Combined Scheimpflug-Placido Disc System (Sirius)

The Sirius topography instrument is an anterior segment analysis system combining a monochromatic 360-degree rotating Scheimpflug camera with a 22-ring Placido disc. Twenty-five radial sections are acquired from the cornea and anterior chamber. The system provides data regarding the tangential and axial curvature of the anterior and posterior corneal surfaces, the global refractive power of the cornea, corneal pachymetry mapping and wavefront analysis. The anterior and posterior surfaces of the cornea are examined using 475 nm blue LED light. While the anterior corneal surface measurements are provided by appropriately combining the Placido and Scheimpflug images, measurements of other interior structures are provided by Scheimpflug imaging.

### Optical Low-Coherence Reflectometry (Aladdin)

The Aladdin optical biometer (Topcon, Tokyo, Japan), introduced into clinical use in 2012, is able to automatically measure biometric parameters such as AL, ACD, keratometry/corneal topography, WTW and pupillometry. AL is measured using an 820 nm superluminescent diode laser. ACD is measured using LED light projected horizontally. The 24-ring Placido disk is used to obtain keratometry and corneal topography measurements. Pupillometry measurements are taken under infrared LED and white LED light to determine photopic and mesopic pupil diameter.

Data were recorded and analyzed using SPSS for Windows 18.0 (SPSS Inc., Chicago, IL, USA). Paired *t*-test was used to compare data obtained using the two devices. Correlation between the measurements was assessed using Pearson correlation analysis. Evaluations were done between 95% confidence interval and *p* values less than 0.05 were accepted as statistical significance.

## Results

Of the 59 patients in the study, 33 (55.9%) were women and 26 (44.1%) were men. Mean age was  $47.31 \pm 18.57$  (range, 25-79) years. Mean ACD values were  $3.35 \pm 0.4$  mm as measured by the Aladdin device and  $3.42 \pm 0.44$  mm using the Sirius

device; the Aladdin device yielded significantly lower mean ACD values ( $p < 0.001$ ). Mean K1 values were  $43.11 \pm 1.57$  D using the Aladdin and  $42.62 \pm 1.71$  D using the Sirius. K1 measured significantly flatter with the Sirius device ( $p < 0.001$ ). K2 and WTW values measured by Aladdin were  $44.04 \pm 1.61$  D and  $11.75 \pm 0.47$  mm, respectively. In addition, K2 and WTW values measured by Sirius were  $44.10 \pm 1.65$  D and  $11.76 \pm 0.55$  mm, respectively. There were no significant differences in K2 or WTW measurements between the two devices ( $p = 0.183$  and  $p = 0.852$ , respectively).

The mean differences in Aladdin and Sirius measurements were  $-0.075 \pm 0.08$  mm for ACD;  $0.409 \pm 0.53$  D for K1;  $-0.091 \pm 0.37$  D for K2; and  $-0.015 \pm 0.33$  mm for WTW. There was a high level of correlation between all anterior segment parameter measurements obtained with the two devices (Table 1, Figures 1, 2).

## Discussion

In cataract surgery, currently the most commonly performed procedure, determination of anterior segment parameters is important for the accurate calculation of intraocular lens (IOL) power. Errors in AL, keratometry and ACD measurement have been reported as the most common causes of inaccurate IOL power calculation.<sup>6</sup> An error of 1 mm in ACD causes postoperative refractive errors of about 1 D in myopic eyes, 1.5 D in emmetropic eyes and 2.5 D in hypermetropic eyes. An error of 0.1 D in keratometry values results in a refractive error of approximately 0.1 D.<sup>7</sup>

In addition to its role in calculating IOL power, ACD is also clinically important for identifying risk of angle closure and detecting anterior segment changes in accommodation and pseudophakic accommodation.<sup>8</sup> Furthermore, the ACD is one of the factors influencing the accurate determination of optic zone diameter for ablation therapy applied in refractive surgery.<sup>9</sup> Corneal power, another anterior segment parameter, is important in many critical aspects of refractive surgery planning such as the accurate determination of astigmatism values and axis orientation, power calculation of the IOL to be implanted, and deciding whether corneal astigmatism will be corrected during the same operation.<sup>10,11</sup> Therefore, it is necessary to assess the accuracy of data from new anterior segment analysis devices by comparing them with those from reference instruments accepted as the gold standard in the measurement of these parameters.

Although conventional A-scan ultrasonography is the gold standard method for measuring ACD, noncontact methods and devices such as partial coherence interferometry, slit-scanning topography, anterior segment optical coherence tomography and Scheimpflug imaging have become widely used in clinics in recent years. Many studies have compared noncontact devices and methods and assessed their reliability and superiority to A-scan ultrasonography in ACD assessment; however, due to the variability in their results, they failed to determine which device or method should be the gold standard in ACD measurement and facilitate standardization.<sup>12,13,14,15,16</sup> Rabsilber et al.<sup>16</sup> found a mean ACD of 2.93 mm, while Meinhardt et al.<sup>15</sup> found a mean

ACD of 3.91 mm. Turkish investigators Emre et al.<sup>17</sup> reported a mean ACD of 3.14 mm in healthy subjects using the Pentacam. Zengin et al.<sup>18</sup> compared data from ultrasonic biometry and the

Orbscan II topography device and reported mean ACD values of 3.05 mm and 3.33 mm, respectively, from the two methods. In another Turkish study, mean ACD was determined to be 3.21 mm using partial optical coherence interferometry and 3.23 mm using optical low-coherence reflectometry.<sup>19</sup> In the present study, we found mean ACD values of 3.35 mm using the Aladdin device versus 3.42 mm using the Sirius system. These variations in measurements may be a result of differences in the instruments and the methods they use.

In the clinical setting, corneal power measurement used for calculating IOL power is generally performed using an autokeratometer or computerized videokeratography. Many studies have reported that manual keratometry, autokeratometry and corneal topography all yield comparable results in corneal power measurement.<sup>20,21</sup>

Previous studies have also demonstrated that the Aladdin and Sirius devices both provide reproducible measurement.<sup>2,3,4,5</sup> However, while using the anterior segment parameters measured by these devices it is important to know how their results compare with those of gold standard devices. We found only one study in the literature that utilized the optic biometer (Aladdin) used in the present study.<sup>2</sup> The authors compared biometric measurements obtained from the Aladdin optical biometry instrument with those of IOL Master, the accepted reference for optic biometric devices, and reported no significant differences between the two devices' mean ACD and keratometry values.<sup>2</sup> However, ACD, keratometry values and other anterior segment parameters from the Aladdin optical biometry device must still be compared to those of other devices, especially A-scan ultrasound. Furthermore, studies comparing the reliability of the Sirius system with other Scheimpflug imaging-based devices and instruments using other methods have presented varying results.<sup>6,22,23</sup>

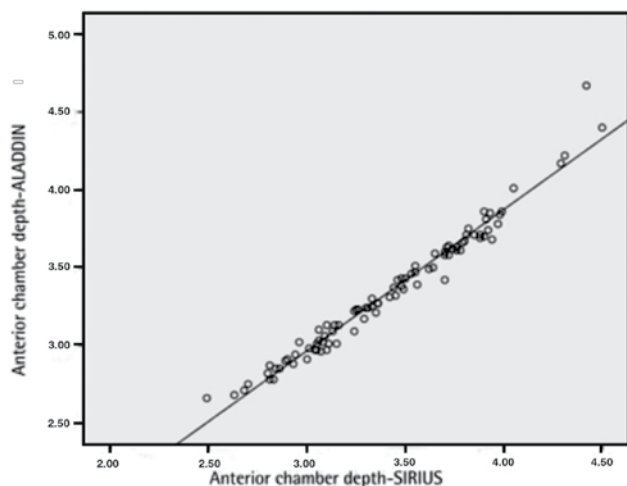
Although we detected a statistically significant difference in the ACD measurements of the Aladdin and Sirius in the present study, this difference is clinically negligible. It is known that when using the Haigis formula, each 0.1 mm change in ACD results in a 0.06 D deviation in the calculated IOL power.<sup>7</sup> The mean difference in ACD measured by the two devices was  $-0.075 \pm 0.08$  (95% confidence limits: -0.092 and -0.059). Therefore, the 0.07 mm difference between devices is at a clinically acceptable level. In our literature search we found two different studies comparing the Sirius system with Lenstar, another optical biometry instrument. The studies reported differences in ACD values between the devices of  $-0.10 \pm 0.06$  mm and  $-0.07 \pm 0.03$  mm, thus concluding for the same reason that these differences were negligible in clinical practice.<sup>23,24</sup> Although it may be negligible, this discrepancy between Aladdin and Sirius measurements may be due to differences in measurement techniques used. Correlation analysis also revealed a high rate of agreement between the measurements obtained using the two instruments.

In the present study, we detected a statistically significant difference of  $0.409 \pm 0.53$  D (95% confidence limits: 0.295 and 0.523 D) in the K1 measurements obtained using the Aladdin and Sirius. An error of 0.1 D in keratometry values causes a refractive error of approximately 0.1 D.<sup>7</sup> This 0.4 D difference

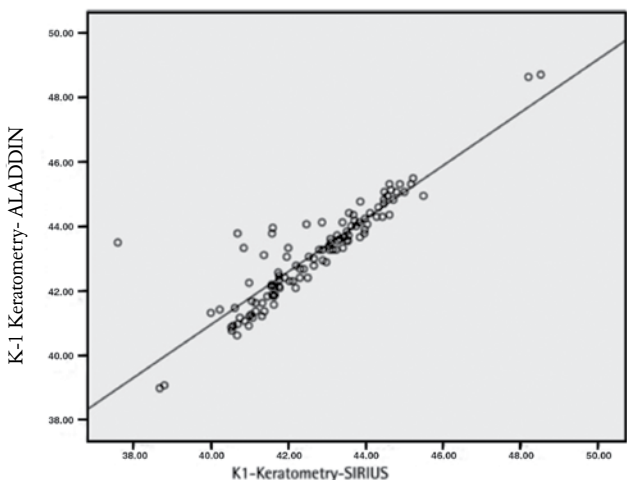
**Table 1. Differences and correlations between anterior segment parameters measured by the Aladdin and Sirius instruments**

Parameter	Difference $\pm$ SD (Aladdin-Sirius)	Confidence interval 95%		Pearson correlation	
		Lower limit	Upper limit	r	p value
ACD (mm)	$-0.075 \pm 0.08$	-0.092	-0.059	0.985	<0.001
K1 (D)	$0.409 \pm 0.53$	0.295	0.523	0.895	<0.001
K2 (D)	$-0.091 \pm 0.37$	-0.171	-0.011	0.961	<0.001
WTW (mm)	$-0.015 \pm 0.33$	-0.086	0.055	0.766	<0.001

ACD: Anterior chamber depth, K1: Flat keratometry value, K2: Steep keratometry value, WTW: White-to-white distance, SD: Standard deviation



**Figure 1.** Correlation plot for anterior chamber depth measurements from the Aladdin and Sirius instruments



**Figure 2.** Correlation plot for flat keratometry measurements from the Aladdin and Sirius instruments

would result in an error of about 0.4 D, which may bring about an undesired and difficult to ignore outcome. In contrast, the difference in K2 values obtained from the two devices was not statistically significant. We were unable to find any information that might explain our finding of significantly different K1 values but comparable K2 values, despite both devices acquiring keratometry measurements from similar paracentral areas (3 mm and 5 mm). Furthermore, correlation analysis showed a high rate of agreement between the K1 and K2 measurements obtained using the two instruments. Although we did not encounter any studies in the literature comparing keratometric analyses of the two devices used in our study, there are various reports using and comparing many different devices and methods in keratometric analysis.<sup>25,26,27</sup> Some of those studies reported that using certain devices as substitutes for one another may not be suitable due to significant differences in keratometric measurements.<sup>26,27</sup> As an explanation, the authors suggested that using different methods to measure keratometry may yield different results.

The determination of keratometry values, anterior segment parameters such as ACD and central corneal thickness, as well as WTW is necessary when planning and executing refractive surgery and achieving satisfactory postoperative outcomes. WTW is also utilized in the diagnosis and management of various ocular diseases such as congenital glaucoma, microcornea and megalocornea.<sup>28</sup> In addition, WTW is important for IOL calculations in modern cataract surgery using third generation formulas to determine haptic dimensions of capsular tension rings and angle-supported IOLs, anterior chamber IOLs and phakic IOLs.<sup>29,30</sup> We observed no significant difference in the WTW measurements obtained using the Aladdin and Sirius devices and found high correlation between the values.

#### Study Limitations

The high correlation between the measurements obtained by these two devices in the present study does not rule out the possibility that those values may be inaccurate. Not using gold standard methods for the measurement of ACD, K1, K2 and WTW in our study and therefore being unable to compare data from the Aladdin and Sirius instruments with those of gold standard devices is a limitation of our study. Our small subject group is another drawback limiting the strength of the study.

#### Conclusion

Although there were significant differences between the Aladdin and Sirius instruments in the ACD and K1 parameters, there was high correlation between measurements in all studied parameters. The difference in ACD measurements may be clinically negligible, but it may not be appropriate to use these devices interchangeably to measure K1.

#### Ethics

Ethics Committee Approval: Retrospective study. Informed Consent: Retrospective study.

Peer-review: Externally peer-reviewed.

#### Authorship Contributions

Surgical and Medical Practices: Onur Polat, Zeki Baysal, Serkan Özcan, Sibel İnan, Ümit Übeyt İnan, Concept: Onur Polat, Zeki Baysal, Serkan Özcan, Sibel İnan, Ümit Übeyt İnan, Design: Onur Polat, Zeki Baysal, Serkan Özcan, Sibel İnan, Ümit Übeyt İnan, Data Collection or Processing: Onur Polat, Zeki Baysal, Serkan Özcan, Sibel İnan, Ümit Übeyt İnan, Analysis or Interpretation: Onur Polat, Zeki Baysal, Serkan Özcan, Sibel İnan, Ümit Übeyt İnan, Literature Search: Onur Polat, Zeki Baysal, Serkan Özcan, Sibel İnan, Ümit Übeyt İnan, Writing: Onur Polat, Zeki Baysal, Serkan Özcan, Sibel İnan, Ümit Übeyt İnan.

Conflict of Interest: No conflict of interest was declared by the authors.

Financial Disclosure: The authors declared that this study received no financial support.

#### References

1. Konstantopoulos A, Hossain P, Anderson DE. Recent advances in ophthalmic anterior segment imaging: a new era for ophthalmic diagnosis? *Br J Ophthalmol.* 2007;91:551-557.
2. Mandal P, Berrow EJ, Naroo SA, Wolffsohn JS, Uthoff D, Holland D, Shah S. Validity and repeatability of the Aladdin ocular biometer. *Br J Ophthalmol.* 2014;98:256-258.
3. Savini G, Barboni P, Carbonelli M, Hoffer KJ. Repeatability of automatic measurements by a new Scheimpflug camera combined with Placido topography. *J Cataract Refract Surg.* 2011;37:1809-1816.
4. Savini G, Carbonelli M, Sbriglia A, Barboni P, Deluigi G, Hoffer KJ. Comparison of anterior segment measurements by 3 Scheimpflug tomographers and 1 Placido corneal topographer. *J Cataract Refract Surg.* 2011;37:1679-1685.
5. Fu J, Li SN, Wang XZ, Wu GW, Mu DP, Wang J, Wang NL. Measurement of anterior chamber volume with rotating scheimpflug camera and anterior segment optical coherence tomography. *Chin Med J (Engl).* 2010;123:203-207.
6. Jin GJ, Crandall AS, Jones JJ. Intraocular lens exchange due to incorrect lens power. *Ophthalmology.* 2007;114:417-424.
7. Lee AC, Qazi MA, Pepose JS. Biometry and intraocular lens power calculation. *Curr Opin Ophthalmol.* 2008;19:13-17.
8. Devereux JG, Foster PJ, Baasanhu J, Uranchimeg D, Lee PS, Erdenbelegit T, Machin D, Johnson GJ, Alsbirk PH. Anterior chamber depth measurement as a screening tool for primary angle-closure glaucoma in an East Asian population. *Arch Ophthalmol.* 2000;118:257-263.
9. Vinciguerra P, Azzolini M, Airaghi P, Radice P, De Molfetta V. Effect of decreasing surface and interface irregularities after photorefractive keratectomy and laser in situ keratomileusis on optical and functional outcomes. *J Refract Surg.* 1998;14:199-203.
10. Hoffmann PC, Hutz WW. Analysis of biometry and prevalence data for corneal astigmatism in 23,239 eyes. *J Cataract Refract Surg.* 2010;36:1479-1485.
11. Ünlü C, Turan Vural E, Erdoğan G, Sezgin Bİ, Bayramlar H. Katarakt Cerrahisi Hastalarımızda Astigmatik Profilin Değerlendirilmesi. *Glo-Kat.* 2010;5:199-202.
12. Nemeth G, Hassan Z, Modis L, Jr., Szalai E, Katona K, Berta A. Comparison of anterior chamber depth measurements conducted with Pentacam HR(R) and IOLMaster(R). *Ophthalmic Surg Lasers Imaging.* 2011;42:144-147.
13. Lee JY, Kim JH, Kim HM, Song JS. Comparison of anterior chamber depth measurement between Orbscan IIz and ultrasound biomicroscopy. *J Refract Surg.* 2007;23:487-491.
14. Salouti R, Nowroozadeh MH, Zamani M, Ghoreyshi M, Salouti R. Comparison of anterior chamber depth measurements using Galilei, HR Pentacam, and Orbscan II. *Optometry.* 2010;81:35-39.

15. Meinhardt B, Stachs O, Stave J, Beck R, Guthoff R. Evaluation of biometric methods for measuring the anterior chamber depth in the non-contact mode. *Graefes Arch Clin Exp Ophthalmol.* 2006;244:559-564.
16. Rabsilber TM, Khoramnia R, Auffarth GU. Anterior chamber measurements using Pentacam rotating Scheimpflug camera. *J Cataract Refract Surg.* 2006;32:456-459.
17. Emre S, Koç B, Doğanay S, Yologlu S. Sağlıklı Bireylerde Pentacam ile Elde Edilen Ön Segment Parametreleri Üzerine Yaşın Etkisinin Değerlendirilmesi. *Turk J Ophthalmol.* 2008;38:452-428.
18. Zengin Ö, Selver ÖB, Özbek Z, Yaman A, Durak İ. Ön Kamara Derinliği Ölçümlerinin Ultrasonik Biometri ve Orbscan II Topografi Teknikleri ile Karşılaştırılması. *Turk J Ophthalmol.* 2009;39:27-31.
19. Doğan M, Polat O, Karataş M, Küsbeci T, Yavaş GE, İnan S, İnan ÜÜ. Kataraktı Olan Gözlerde Göz İçi Lens Gücü Hesaplanmasında Parsiyel Kohorens İnterferometri ile Optik Düşük Kohorens Reflektometri Yöntemlerinin Karşılaştırılması. *Turk J Ophthalmol* 2014;44:419-423.
20. Cuaycong MJ, Gay CA, Emery J, Haft EA, Koch DD. Comparison of the accuracy of computerized videokeratography and keratometry for use in intraocular lens calculations. *J Cataract Refract Surg.* 1993;19(Suppl):178-181.
21. Tennen DG, Keates RH, Montoya C. Comparison of three keratometry instruments. *J Cataract Refract Surg.* 1995;21:407-408.
22. Savini G, Barboni P, Carbonelli M, Hoffer KJ. Accuracy of corneal power measurements by a new Scheimpflug camera combined with Placido-disk corneal topography for intraocular lens power calculation in unoperated eyes. *J Cataract Refract Surg.* 2012;38:787-792.
23. Chen W, McAlinden C, Pesudovs K, Wang Q, Lu F, Feng Y, Chen J, Huang J. Scheimpflug-Placido topographer and optical low-coherence reflectometry biometer: repeatability and agreement. *J Cataract Refract Surg.* 2012;38:1626-1632.
24. Bayhan HA, Bayhan SA, Muhafız E, Can I. Optik Düşük Kohorens Reflektometri ve Kombine Scheimpflug-Placido Disk Topografisi ile Değerlendirilen Ön Segment Parametrelerinin Değerlendirilmesi. *Glo-Kat.* 2013;8:78-82.
25. Módis L Jr, Szalai E, Kolozsvári B, Németh G, Vajas A, Berta A. Keratometry evaluations with the Pentacam high resolution in comparison with the automated keratometry and conventional corneal topography. *Cornea.* 2012;31:36-41.
26. Wang Q, Savini G, Hoffer KJ, Xu Z, Feng Y, Wen D, Hua Y, Yang F, Pan C, Huang J. A comprehensive assessment of the precision and agreement of anterior corneal power measurements obtained using 8 different devices. *PLoS One.* 2012;7:45607.
27. Turk A, Arıcı C, Ceylan OM, Kola M. Potec PRK-6000 Otreofraktometre, IOLMaster ve Pentacam ile Ölçülen Keratometri Değerlerinin Tekrarlanabilirliği ve Karşılaştırılması. *Turk J Ophthalmol.* 2014;44:179-183.
28. Wallace DK, Plager DA. Corneal diameter in childhood aphakic glaucoma. *J Pediatr Ophthalmol Strabismus.* 1996;33:230-234.
29. Hoffer KJ. Clinical results using the Holladay 2 intraocular lens power formula. *J Cataract Refract Surg.* 2000;26:1233-1237.
30. Vass C, Menapace R, Schmetterer K, Findl O, Rainer G, Steineck I. Prediction of pseudophakic capsular bag diameter based on biometric variables. *J Cataract Refract Surg.* 1999;25:1376-1381.





# Does Retinal Neurodegeneration Seen in Diabetic Patients Begin in the Insulin Resistance Stage?

Sedat Arıkan\*, İsmail Erşan\*, Mustafa Eroğlu\*\*, Mehmet Yılmaz\*, Hasan Ali Tufan\*, Baran Gencer\*, Selçuk Kara\*, Mehmet Aşık\*\*

\*Çanakkale Onsekiz Mart University Faculty of Medicine, Department of Ophthalmology, Çanakkale, Turkey

\*\*Çanakkale Onsekiz Mart University Faculty of Medicine, Department of Endocrinology and Metabolism, Çanakkale, Turkey

## Summary

**Objectives:** To investigate whether retinal neurodegeneration and impairment in contrast sensitivity (CS), which have been demonstrated to begin in diabetic patients before the presence of signs of diabetic retinal vasculopathy, also occur in the stage of insulin resistance.

**Materials and Methods:** The average, minimum and sectoral (inferior, superior, inferonasal, superonasal, inferotemporal and superotemporal) thicknesses of the ganglion cell-inner plexiform layer (GCIPL) measured using optical coherence tomography were compared between an insulin-resistant group and control group in order to evaluate the presence of retinal neurodegeneration. The CS of the two groups was also compared according to the logarithmic values measured at spatial frequencies of 1.5, 3, 6, 12 and 18 cycles per degree in photopic light using functional acuity contrast test (FACT).

**Results:** Twenty-five eyes of 25 patients with insulin resistance (insulin resistant group) and 25 eyes of 25 healthy subjects (control group) were included in this study. There were no statistically significant differences between the two groups in any of the spatial frequencies in the FACT. The mean average GCIPL thickness and mean GCIPL thickness in the inferotemporal sector were significantly less in the insulin-resistant group when compared with the control group (mean average GCIPL thicknesses in the insulin-resistant and control groups were  $83.6 \pm 4.7 \mu\text{m}$  and  $86.7 \pm 3.7 \mu\text{m}$  respectively,  $p=0.01$ ; mean inferotemporal GCIPL thicknesses in the insulin-resistant and control groups were  $83 \pm 6.0 \mu\text{m}$  and  $86.7 \pm 4.6 \mu\text{m}$  respectively,  $p=0.02$ ).

**Conclusion:** Although it may not lead to functional visual impairment such as CS loss, the retinal neurodegeneration seen in diabetic patients may begin in the insulin resistance stage.

**Keywords:** Insulin resistance, retinal ganglion cell layer, contrast sensitivity

## Introduction

Diabetes mellitus continues to be an important public health problem that adversely affects quality of life through serious microvascular complications such as retinopathy, nephropathy and neuropathy. The prevalence of this disease is steadily rising; it is estimated that the total number of patients with diabetes will reach 366 million by 2030, compared to 171 million in 2000.<sup>1</sup> Thus, the investigation and management of factors responsible for

the development of diabetes and its complications have become particularly important in order to prevent this increase. Several clinical trials including the Diabetic Control and Complication Trial and EURODIAB Prospective Complications Study have provided clinical evidence that confirm insulin resistance as a major risk factor for the development of diabetes and diabetic retinopathy (DR).<sup>2,3,4</sup> In addition to its role in the pathogenesis of DR, insulin resistance was also found to be an important factor

**Address for Correspondence:** Sedat Arıkan MD, Çanakkale Onsekiz Mart University Faculty of Medicine, Department of Ophthalmology, Çanakkale, Turkey  
Phone: +90 286 218 00 18 E-mail: drsarikan@gmail.com **Received:** 01.09.2015 **Accepted:** 09.11.2015

©Copyright 2016 by Turkish Ophthalmological Association  
Turkish Journal of Ophthalmology, Published by Galenos Publishing House

related to the occurrence of other microvascular complications of diabetes through vascular endothelial injury.<sup>5</sup>

It has been proposed that impaired insulin action, which is the primary defect of diabetes, directly affects the retina and may initiate retinal dysfunction.<sup>6</sup> Several clinical trials investigating retinal functions in diabetic patients without DR have revealed the neurodegenerative component of DR can begin even before the occurrence of retinal vasculopathic manifestations of diabetes.<sup>7,8,9</sup> This concept has also been supported by histopathological examination. Wolter<sup>10</sup> demonstrated the atrophy of ganglion cells and degeneration of the inner nuclear layer in the retinas of patients with early diabetes and reported that neuronal degeneration of the retina seen in diabetic patients may be a primary pathology leading to vascular changes. Gastinger et al.<sup>11</sup> have shown the loss of retinal ganglion cells (RGCs) within the first 3 months of diabetes in mice. Abu-El-Asrar et al.<sup>12</sup> suggested that RGCs are the cells most vulnerable to the increased apoptosis that occurs in diabetic retina.

Apart from histopathological studies, the decrease in the thickness of the RGC layer has been clinically demonstrated using optical coherence tomography (OCT) both in patients with type 1 diabetes and in patients with type 2 diabetes with minimal or no retinopathy.<sup>13,14</sup> Although the neuroprotective effect of insulin on retinal neurons has been reported in previous studies,<sup>15,16</sup> there are no studies investigating the presence of neurodegeneration in patients with insulin resistance. In ophthalmic practice, spectral-domain OCT (SD-OCT) in particular is a widely used tool for early detection of the structural changes that occur in the retinal layers and for follow-up of the disease's progression.<sup>17</sup> Unlike other SD-OCTs, high-definition (HD)-OCT enables us to assess the thicknesses of the retinal nerve fiber layer (RNFL) and ganglion cell-inner plexiform layer (GCIPL) separately.<sup>18</sup> Besides that, the contrast sensitivity (CS) test has been shown to be beneficial in the detection of functional changes that may occur in the early stages of glaucoma in patients with good visual acuity.<sup>19</sup>

Taken together, it is reasonable to use OCT along with CS test for the structural and functional evaluation of possible early retinal neurodegeneration which is thought to arise from insulin resistance. Therefore, in this study we aimed to compare CS test results and RNFL and GCIPL thicknesses between patients with insulin resistance and healthy subjects in order to evaluate the structural and functional effects of impaired insulin sensitivity on the retina.

## Materials and Methods

This prospective, comparative study was carried out in the Ophthalmology Department of Çanakkale Onsekiz Mart University Faculty of Medicine. After the local ethics committee approved the study protocol according to the Declaration of Helsinki for research involving human subjects, healthy subjects and patients who were diagnosed as having insulin resistance and were followed in the Endocrinology and Metabolism Departments of Çanakkale Onsekiz Mart University Faculty of Medicine were recruited for the study. Written informed consent was obtained

from each patient with insulin resistance and from each healthy subject who agreed to participate in this study as a volunteer. All participants underwent a comprehensive ophthalmologic examination consisting of measurement of best corrected visual acuity (BCVA) and intraocular pressure, slit-lamp biomicroscopy and fundoscopic examination.

Patients meeting one or more of the following exclusion criteria were not included in the study: history of previous ocular surgery or eye trauma; contact lens wear; corneal and conjunctival diseases; ocular inflammatory diseases; dry eye disease; diagnosis of glaucoma or ocular hypertension (intraocular pressure >22 mmHg); vascular or degenerative retinal diseases; systemic diseases which can lead to retinal or optic nerve disorders (hypertension, diabetes mellitus, multiple sclerosis, etc.); diagnosis of cataract; BCVA level greater than 0 logMAR; refractive error exceeding  $\pm 2.0$  diopter as spherical equivalent (SE) value. Participants whose homeostasis model assessment of insulin resistance index (HOMA-IR) [fasting insulin ( $\mu\text{U}/\text{mL}$ ) $\times$ fasting glucose (mmol)/22.5] value  $\geq 2.7$  was accepted to have insulin resistance. Apart from HOMA-IR value, plasma insulin level and body mass index (BMI) value were also assessed for each patient. The participants who met the eligibility criteria were assessed by CS test using functional acuity contrast test (FACT) (OPTEC 6500 Stereo Optical Co., Chicago, IL, USA) and OCT imaging using Cirrus HD-OCT 4000 (Carl Zeiss Meditec Inc., Dublin, CA, USA) consecutively.

### Contrast Sensitivity Test

Binocular CS of participants was evaluated using sine wave grating charts of FACT with five spatial frequencies in photopic conditions (85 candela/m<sup>2</sup>) in far vision and without glare mode. The spatial frequencies consisted of 1.5 cycle/per degree (cpd) (threshold range 0.045-2.00), 3 cpd (threshold range 0.70-2.20), 6 cpd (threshold range 0.78-2.26), 12 cpd (threshold range 0.60-2.08) and 18 cpd (threshold range 0.30-1.81). There are nine gradually blurred gratings available in each spatial frequency. While testing CS, the participants were asked to describe the position (right, up, or left) of nine gratings in each row that corresponds to each spatial frequency. The true position of the last grating that could be identified by the participant in a tested row was accepted as the CS score of the tested spatial frequency. The CS score for each spatial frequency was then transformed to logarithmic value.

### Optical Coherence Tomography Imaging

The 512x128 macular cube and 200x200 optic disc cube protocols of Cirrus HD-OCT were used to obtain macular scan and optic nerve head scan, respectively, for the purpose of measuring the central foveal thickness (CFT), GCIPL thickness, and peripapillary RNFL thickness. The average, minimum and sectoral (superotemporal, superior, superonasal, inferonasal, inferior, inferotemporal) GCIPL thicknesses of each participant were measured from ganglion cell analysis algorithm. The average and sectoral (superior, inferior, nasal and temporal) thicknesses of peripapillary RNFL of each participant were also measured.

### Statistical Analyses

Statistical analyses were performed using SPSS software version 15. The variables were investigated using visual (histograms,

probability plots) and analytical methods (Kolmogorov-Smirnov/ Shapiro-Wilk test) to determine whether or not they were normally distributed. Descriptive analyses were presented using means and standard deviations for all variables. Since the average, minimum and sectoral GCIPL thickness, the average and sectoral RNFL thickness and SE value of participants were normally distributed, the Student's t-test was used to compare these parameters between the insulin resistant and control groups. The Mann-Whitney U test was used for intergroup comparisons of spatial frequency CS scores, plasma insulin level, BMI value, and HOMA-IR value because these parameters did not show normal data distribution. Additionally, the associations between average GCIPL thickness and plasma insulin level, fasting plasma glucose level (FPG), BMI value and HOMA-IR value were evaluated using the Spearman test. A p-value of less than 0.05 was considered to show a statistically significant result.

### Results

Twenty-five eyes of 25 patients with insulin resistance (insulin resistant group), and 25 eyes of 25 healthy subjects (control group) were included in this study. There was no significant difference in terms of age, sex and mean SE value between the insulin resistant group and control group. However, in comparison with the control group, the insulin resistant group showed significantly higher values in other parameters such as mean plasma insulin level, mean FGL, mean BMI value, and mean HOMA-IR value (Table 1). The mean values and statistical comparisons of average, minimum and sectoral GCIPL thicknesses between insulin resistant group and control group are shown in Table 2. The mean average GCIPL thickness was found to be significantly thinner in the insulin resistant group than in the control group (83.6±4.7 µm vs. 86.7±3.7 µm, respectively, p=0.01). Among the sectoral GCIPL parameters, only the mean inferotemporal thickness was significantly thinner in the insulin resistant group compared to control group (83.0±6.0 µm vs. 86.7±4.6 µm, respectively, p=0.02). The mean CFT of the insulin resistant group and control group was 243±19 µm and 249±16 µm, respectively (p=0.4). Spearman's correlation test showed that there were negative correlations between average GCIPL thickness and insulin plasma level, BMI value and HOMA-IR value (Table 3). The mean logarithmic values of FACT scores measured in each spatial frequency of the insulin resistant group and control group were in normal range (1.51±0.19 vs 1.45±0.16, p=0.2 at 1.5 cpd; 1.67±0.25 vs 1.62±0.20, p=0.4 at 3 cpd; 1.66±0.26 vs 1.63±0.18, p=0.5 at 6 cpd; 1.32±0.25 vs 1.25±0.16, p=0.2 at 12 cpd; and 0.95±0.33 vs 0.82±0.29, p=0.1 at 18 cpd). As can also be seen in Figure 1, there were no statistically significant differences between the insulin resistant group and control group in low (1.5 cpd), middle (3 and 6 cpd) or high (12 and 18 cpd) spatial frequencies of the CS test. The mean average and sectoral RNFL thicknesses were similar between two groups (Figure 2).

### Discussion

The exact cause of the retinal neurodegeneration seen in diabetic patients has not been determined yet, but strong evidence from animal studies has demonstrated the significant

role of apoptosis in the retinal cell death of diabetic patients. In a histopathological examination, a significant number of apoptotic RGCs, as well as pronounced reduction in the thickness of both inner-plexiform and inner nuclear layers was shown in streptozotocin-induced diabetic rat retina.<sup>20</sup> The increased susceptibility of RGCs to apoptosis in diabetics was also confirmed by demonstrating the increased number of both apoptosis markers such as TUNEL positive cells and caspase-3 positive cells in the RGC layer of streptozotocin-induced diabetic mice.<sup>21</sup> Aside from animal studies, RGC loss due to diabetes was also shown in a number of postmortem human studies.<sup>22</sup>

Increased apoptotic damage of RGCs in diabetic patients can be due to impaired retinal insulin receptor signaling, which works on the phosphatidylinositol 3-kinase (PI3-K)/Akt signaling pathway. It has been shown that both insulin and insulin-like growth factor-1 (IGF-1) can act as a trophic factors for the survival of retinal neurons including RGCs through a PI3-K/Akt signaling pathway.<sup>23,24</sup> In this pathway, a conformational change in the retinal insulin receptor after insulin stimulation is thought to cause a series of phosphorylations in which phosphorylated PI3-K activates Akt, then phosphorylated Akt inhibits apoptosis by phosphorylating caspase-9, which is the head of proteolytic cascade.<sup>25</sup> On the other hand, it has been shown that insulin

**Table 1. Demographics of insulin resistant group and control group**

Parameters	Insulin resistant group (n=25) Mean ± SD	Control group (n=25) Mean ± SD	p value
Age (years)	34.2±11.6	37.3±11.5	0.36
Sex (Male:female)	4:21	5:20	0.5
Plasma insulin level	17.3±5.9	6.7±2.5	<0.0001*
FPG	95.9±5.5	90.6±5.5	0.02*
BMI value	33.11±6.2	26.78±4.3	<0.0001*
HOMA-IR value	4.05±1.3	1.52±0.6	<0.0001*
SE value	0.25±0.69	0.20±1.1	0.8
BCVA (logMAR)	0	0	

FPG: Fasting plasma glucose level, BMI: Body mass index, HOMA-IR: Homeostasis model assessment of insulin resistance index, SE: Spherical equivalent, BCVA: Best corrected visual acuity, SD: Standard deviation

**Table 2. The mean values and statistically comparisons of average, minimum and sectoral thicknesses of ganglion cell inner plexiform layer between insulin resistant group and control group**

GCIPL thickness	Insulin resistant group (n=25) Mean ± SD (µm)	Control group (n=25) Mean ± SD (µm)	p value
Average	83.6±4.7	86.7±3.7	0.01*
Superior	86.4±6.8	89.0±4.5	0.1
Inferior	82.0±8.1	85.5±6.5	0.08
Inferonasal	83.4±5.5	85.6±8.0	0.07
Inferotemporal	83.0±6.0	86.7±4.6	0.02*
Superonasal	85.5±6.0	86.8±5.0	0.4
Superotemporal	83.4±1.3	86.1±0.6	0.09
Minimum	78.3±12.2	79.4±9.9	0.5

GCIPL: Ganglion cell inner plexiform layer, SD: Standard deviation

and IGF-1 need to use insulin receptor substance (IRS) as an integrating factor in order to properly transmit the survival signal to the PI3-K/Akt signaling pathway.<sup>26</sup> The deficiency of IRS-2 in mice was revealed to induce loss of RGC and photoreceptors, which is associated with decreased Akt activation and increased caspase-3 activation.<sup>27</sup> Therefore, deterioration in the retinal insulin/IGF receptor signaling pathway or deficiency in its intermediary components such as IRS has been associated with neurodegeneration and retinopathy.<sup>28</sup>

Although the association between diabetes/retinal cell apoptosis and the onset time of diabetic retinal neurodegeneration has been well documented, less is known about whether RGC

loss also occurs in the period of insulin resistance (in other words, prior to the development of diabetes). In the pathogenesis of insulin resistance, suppression of cytokine signaling 1 (SOCS-1) and SOCS-3 has been suggested to cause an impairment in insulin signaling in the liver through inhibiting the activity of IRS-1 and IRS-2.<sup>29</sup> Furthermore, persistent expression of SOCS-3 has also been implicated in the development of retinal insulin resistance by leading to diminished activity of IRS-2 in rats.<sup>30</sup> Taken together, it is conceivable to think that patients with insulin resistance may suffer from decreased visual function as a result of reduced RGC number. Dosso et al.<sup>31</sup> demonstrated the impaired CS function in both insulin resistant obese patients and diabetic patients without retinopathy, and they associated this result with the possible involvement of RGCs.

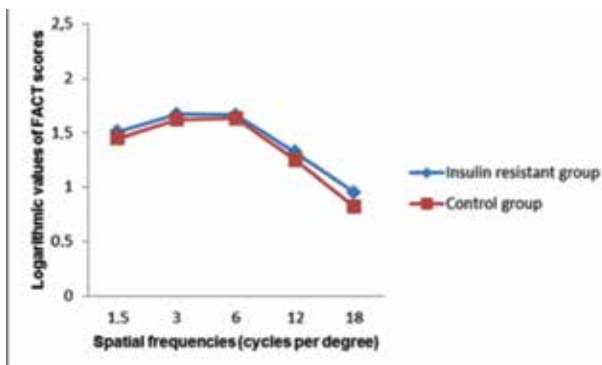
Despite the numerous studies which have exhibited the damage of RGCs in diabetic patients, to our knowledge there are no published studies investigating the status of RGCs in insulin resistant patients. Since increased apoptosis has been shown to cause thinning of the RGC layer or RNFL,<sup>32</sup> in the present study we compared GCIPL and RNFL thicknesses in insulin resistant patients with those measured in healthy subjects. We determined that the mean average GCIPL thickness in insulin resistant patients was significantly less in comparison with the healthy subjects. Because the abundance of both insulin and its receptors has been shown in the retina, especially in the inner plexiform layer,<sup>33</sup> the decrease in the average GCIPL thickness of insulin resistant patients may be consistent with the possibly increased apoptosis in RGCs. In previous studies, decreased RGC layer thickness was shown in patients with either type 1 or type 2 diabetes.<sup>13,14</sup> However, the correlation between RGC layer thickness and plasma insulin level, which varies according to diabetes type, was not assessed in these studies.

In the present study, we evaluated the correlation between average GCIPL thickness and the parameters of insulin resistance such as plasma insulin level, BMI value, and HOMA-IR value. We detected statistically significant negative correlations between mean average GCIPL thickness and all of the insulin resistance parameters. However, increased BMI had a more pronounced effect on average GCIPL thickness compared to plasma insulin level and HOMA-IR value. This result may be due to insufficient perfusion of the RGCs, because increased levels of vasoconstrictor molecules (endothelin-1 and angiotensin-2), which can lead to impaired perfusion, have been associated with higher BMI.<sup>34,35</sup> Moreover, detection of narrowed retinal arterioles in patients with higher BMI may indicate possible deterioration in the microvascular circulation of inner retinal layers.<sup>36</sup> Although mean FPGL was in the normal range in both groups, it was significantly higher in the insulin resistant patients. Nevertheless, we did not detect any correlation between mean FPGL and GCIPL thickness. The evaluation of this correlation may have importance in terms of ruling out the possible apoptotic effect of increased blood glucose level on RGCs, and therefore demonstrating the significant effect of impaired insulin action on retinal neurodegeneration, since both hyperglycemia and deficiency in insulin action have been reported to be involved in apoptotic cell damage of the diabetic mouse retina.<sup>37</sup>

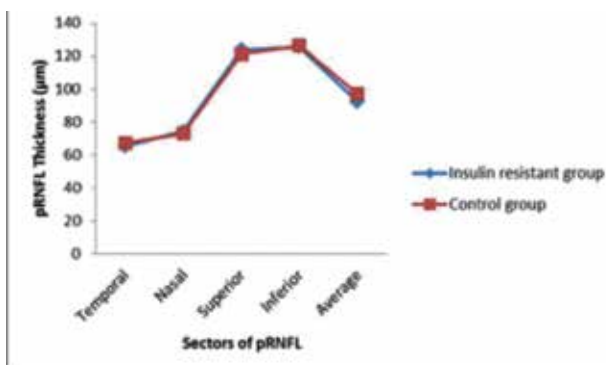
**Table 3. Spearman's rank correlation coefficients between average ganglion cell inner plexiform layer thickness and insulin resistance parameters and spherical equivalent value**

Parameters	Average GCIPL thickness Spearman's rho coefficient	p value
Plasma insulin level	-0.310	0.03*
BMI value	-0.413	0.03*
HOMA-IR value	-0.327	0.02*
Fasting plasma glucose level	-0.143	0.3
SE value	0.135	0.3

BMI: Body mass index, HOMA-IR: Homeostasis model assessment of insulin resistance index, SE: Spherical equivalent, GCIPL: Ganglion cell inner plexiform layer



**Figure 1.** The mean functional acuity contrast test scores in terms of logarithmic values at all spatial frequencies in the insulin resistant group and control group  
FACT: Functional acuity contrast test



**Figure 2.** The mean average and sectoral (temporal, nasal, superior, inferior) thicknesses of peripapillary retinal nerve fiber layer in the insulin resistant group and control group  
pRNFL: Peripapillary retinal nerve fiber layer

It has been previously suggested that some of the RGCs participate in the parvocellular (P cells) system, which is thought to function in high-contrast, high-spatial resolution, while other RGCs participate in the magnocellular (M cells) system, which is thought to function in low-spatial contrast.<sup>38</sup> Therefore, in this study we performed the CS test at low (1.5 cpd), middle (3 cpd and 6 cpd), and high (12 cpd and 18 cpd) spatial frequencies in order to assess the function of M cells and P cells and thereby evaluate RGC function. We found similar scores between the insulin resistant and control groups at all spatial frequencies. The preservation of CS function in insulin resistant patients may be due to mild RGC loss; considering the findings of Zhang et al.,<sup>39</sup> it may be estimated that there was a 4% difference in the number of macular RGCs between the two groups in our study. However, it has been reported that functional visual loss occurs in cases with damage to 20% to 40% of RGCs.<sup>40</sup>

#### Study Limitations

Despite a number of studies suggesting the relationship between axial length (AL) of the eye and thickness of GCIPL,<sup>41</sup> we could not assess the AL of the participants during this study due to the absence of an optical biometer in our clinic. However, we ensured the participants in our study had comparable, low SE values. Apart from the small sample size, we consider the absence of AL measurement a major limitation of this study.

#### Conclusion

Although the decreases observed in average and inferotemporal GCIPL thicknesses were not found to cause loss of CS function in patients with insulin resistance, it may provide evidence that retinal neurodegeneration likely begins in the insulin resistance stage.

#### Ethics

Ethics Committee Approval: The study were approved by the Çanakkale Onsekiz Mart University of Local Ethics Committee, Informed Consent: It was taken.

Peer-review: Externally peer-reviewed.

#### Authorship Contributions

Concept: Sedat Arıkan, Mustafa Eroğlu, Design: Sedat Arıkan, İsmail Erşan, Data Collection or Processing: Mehmet Yılmaz, Mustafa Eroğlu, Mehmet Aşık, Analysis or Interpretation: Baran Gencer, Selçuk Kara, Literature Search: Hasan Ali Tufan, Writing: Sedat Arıkan.

Conflict of Interest: No conflict of interest was declared by the authors.

Financial Disclosure: The authors declared that this study received no financial support.

#### References

- Wild S, Roglic G, Green A, Sicree R, King H. Global prevalence of diabetes: estimates for the year 2000 and projections for 2030. *Diabetes Care*. 2004;27:1047-1053.
- Weyer C, Bogardus C, Mott DM, Pratley RE. The natural history of insulin secretory dysfunction and insulin resistance in the pathogenesis of type 2 diabetes mellitus. *J Clin Invest*. 1999;104:787-794.
- Zhang L, Krzentowski G, Albert A, Lefebvre PJ. Risk of developing retinopathy in Diabetes Control and Complications Trial type 1 diabetic patients with good or poor metabolic control. *Diabetes Care*. 2001;24:1275-1279.
- Chaturvedi N, Sjoelie AK, Porta M, Aldington SJ, Fuller JH, Songini M, Kohner EM, Study EPC. Markers of insulin resistance are strong risk factors for retinopathy incidence in type 1 diabetes. *Diabetes Care*. 2001;24:284-289.
- Stuhlinger MC, Abbasi F, Chu JW, Lamendola C, McLaughlin TL, Cooke JP, Reaven GM, Tsao PS. Relationship between insulin resistance and an endogenous nitric oxide synthase inhibitor. *JAMA*. 2002;287:1420-1426.
- Antonetti DA, Barber AJ, Bronson SK, Freeman WM, Gardner TW, Jefferson LS, Kester M, Kimball SR, Krady JK, LaNoue KF, Norbury CC, Quinn PG, Sandirasegarane L, Simpson IA, Group JDRC. Diabetic retinopathy: seeing beyond glucose-induced microvascular disease. *Diabetes*. 2006;55:2401-2411.
- Ghafour IM, Foulds WS, Allan D, McClure E. Contrast sensitivity in diabetic subjects with and without retinopathy. *Br J Ophthalmol*. 1982;66:492-495.
- Roy MS, Gunkel RD, Podgor MJ. Color vision defects in early diabetic retinopathy. *Arch Ophthalmol*. 1986;104:225-228.
- Di Leo MA, Caputo S, Falsini B, Porciatti V, Minnella A, Greco AV, Ghirlanda G. Nonspecific loss of contrast sensitivity in visual system testing in early type I diabetes. *Diabetes Care*. 1992;15:620-625.
- Wolter JR. Diabetic retinopathy. *Am J Ophthalmol*. 1961; 51:1123-1141.
- Gastinger MJ, Kunselman AR, Conboy EE, Bronson SK, Barber AJ. Dendrite remodeling and other abnormalities in the retinal ganglion cells of Ins2 Akita diabetic mice. *Invest Ophthalmol Vis Sci*. 2008;49:2635-2642.
- Abu-El-Asrar AM, Dralands L, Missotten L, Al-Jadaan IA, Geboes K. Expression of apoptosis markers in the retinas of human subjects with diabetes. *Invest Ophthalmol Vis Sci*. 2004;45:2760-2766.
- van Dijk HW, Verbraak FD, Kok PH, Garvin MK, Sonka M, Lee K, DeVries JH, Michels RP, van Velthoven ME, Schlingemann RO, Abramoff MD. Decreased retinal ganglion cell layer thickness in patients with type 1 diabetes. *Invest Ophthalmol Vis Sci*. 2010;51:3660-3665.
- van Dijk HW, Verbraak FD, Kok PH, Stehouwer M, Garvin MK, Sonka M, DeVries JH, Schlingemann RO, Abramoff MD. Early neurodegeneration in the retina of type 2 diabetic patients. *Invest Ophthalmol Vis Sci*. 2012;53:2715-2719.
- Reiter CE, Wu X, Sandirasegarane L, Nakamura M, Gilbert KA, Singh RS, Fort PE, Antonetti DA, Gardner TW. Diabetes reduces basal retinal insulin receptor signaling: reversal with systemic and local insulin. *Diabetes*. 2006;55:1148-1156.
- Nakamura M, Barber AJ, Antonetti DA, LaNoue KF, Robinson KA, Buse MG, Gardner TW. Excessive hexosamines block the neuroprotective effect of insulin and induce apoptosis in retinal neurons. *J Biol Chem*. 2001;276:43748-43755.
- Leite MT, Rao HL, Weinreb RN, Zangwill LM, Bowd C, Sample PA, Tafreshi A, Medeiros FA. Agreement among spectral-domain optical coherence tomography instruments for assessing retinal nerve fiber layer thickness. *Am J Ophthalmol*. 2011;151:85-92 e81.
- Mwanza JC, Oakley JD, Budenz DL, Chang RT, Knight OJ, Feuer WJ. Macular ganglion cell-inner plexiform layer: automated detection and thickness reproducibility with spectral domain-optical coherence tomography in glaucoma. *Invest Ophthalmol Vis Sci*. 2011;52:8323-8329.
- Onal S, Yenice O, Cakir S, Temel A. FACT contrast sensitivity as a diagnostic tool in glaucoma: FACT contrast sensitivity in glaucoma. *Int Ophthalmol*. 2008;28:407-412.
- Barber AJ, Lieth E, Khin SA, Antonetti DA, Buchanan AG, Gardner TW. Neural apoptosis in the retina during experimental and human diabetes. Early onset and effect of insulin. *J Clin Invest*. 1998;102:783-791.
- Martin PM, Roon P, Van Ells TK, Ganapathy V, Smith SB. Death of retinal neurons in streptozotocin-induced diabetic mice. *Invest Ophthalmol Vis Sci*. 2004;45:3330-3336.
- Bloodworth JM, Jr. Diabetic retinopathy. *Diabetes*. 1962;11:1-22.
- Meyer-Franke A, Kaplan MR, Pflieger FW, Barres BA. Characterization of the signaling interactions that promote the survival and growth of developing retinal ganglion cells in culture. *Neuron*. 1995;15:805-819.
- Barber AJ, Nakamura M, Wolpert EB, Reiter CE, Seigel GM, Antonetti DA, Gardner TW. Insulin rescues retinal neurons from apoptosis by a phosphatidylinositol 3-kinase/Akt-mediated mechanism that reduces the activation of caspase-3. *J Biol Chem*. 2001;276:32814-32821.

25. Kanan Y, Matsumoto H, Song H, Sokolov M, Anderson RE, Rajala RV. Serine/threonine kinase akt activation regulates the activity of retinal serine/threonine phosphatases, PHLPP and PHLPL. *J Neurochem.* 2010;113:477-488.
26. van der Heide LP, Ramakers GM, Smidt MP. Insulin signaling in the central nervous system: learning to survive. *Prog Neurobiol.* 2006;79:205-221.
27. Yi X, Schubert M, Peachey NS, Suzuma K, Burks DJ, Kushner JA, Suzuma I, Cahill C, Flint CL, Dow MA, Leshan RL, King GL, White MF. Insulin receptor substrate 2 is essential for maturation and survival of photoreceptor cells. *J Neurosci.* 2005;25:1240-1248.
28. Diaz B, Serna J, De Pablo F, de la Rosa EJ. In vivo regulation of cell death by embryonic (pro)insulin and the insulin receptor during early retinal neurogenesis. *Development.* 2000;127:1641-1649.
29. Ueki K, Kondo T, Kahn CR. Suppressor of cytokine signaling 1 (SOCS-1) and SOCS-3 cause insulin resistance through inhibition of tyrosine phosphorylation of insulin receptor substrate proteins by discrete mechanisms. *Mol Cell Biol.* 2004;24:5434-5446.
30. Liu X, Mameza MG, Lee YS, Eseonu CI, Yu CR, Kang Derwent JJ, Ekwuagu CE. Suppressors of cytokine-signaling proteins induce insulin resistance in the retina and promote survival of retinal cells. *Diabetes.* 2008;57:1651-1658.
31. Dosso AA, Yenice-Ustun F, Sommerhalder J, Golay A, Morel Y, Leuenberger PM. Contrast sensitivity in obese dyslipidemic patients with insulin resistance. *Arch Ophthalmol.* 1998;116:1316-1320.
32. Kumar B, Gupta SK, Nag TC, Srivastava S, Saxena R, Jha KA, Srinivasan BP. Retinal neuroprotective effects of quercetin in streptozotocin-induced diabetic rats. *Exp Eye Res.* 2014;125:193-202.
33. Rosenzweig SA, Zetterstrom C, Benjamin A. Identification of retinal insulin receptors using site-specific antibodies to a carboxyl-terminal peptide of the human insulin receptor alpha-subunit. Up-regulation of neuronal insulin receptors in diabetes. *J Biol Chem.* 1990;265:18030-18034.
34. Stepp DW, Boesen EI, Sullivan JC, Mintz JD, Hair CD, Pollock DM. Obesity augments vasoconstrictor reactivity to angiotensin II in the renal circulation of the Zucker rat. *Am J Physiol Heart Circ Physiol.* 2007;293:H2537-2542.
35. Cardillo C, Campia U, Bryant MB, Panza JA. Increased activity of endogenous endothelin in patients with type II diabetes mellitus. *Circulation.* 2002;106:1783-1787.
36. Boillot A, Zoungas S, Mitchell P, Klein R, Klein B, Ikram MK, Klaver C, Wang JJ, Gopinath B, Tai ES, Neubauer AS, Hercberg S, Brazionis L, Saw SM, Wong TY, Czernichow S, Group M-ES. Obesity and the microvasculature: a systematic review and meta-analysis. *PLoS One.* 2013;8:e52708.
37. Fort PE, Losiewicz MK, Reiter CE, Singh RS, Nakamura M, Abcouwer SE, Barber AJ, Gardner TW. Differential roles of hyperglycemia and hypoinsulinemia in diabetes induced retinal cell death: evidence for retinal insulin resistance. *PLoS One.* 2011;6:26498.
38. Sadun AA. Dyslexia at The New York Times: (mis)understanding of parallel visual processing. *Arch Ophthalmol.* 1992;110:933-934.
39. Zhang C, Tatham AJ, Weinreb RN, Zangwill LM, Yang Z, Zhang JZ, Medeiros FA. Relationship between ganglion cell layer thickness and estimated retinal ganglion cell counts in the glaucomatous macula. *Ophthalmology.* 2014;121:2371-2379.
40. Quigley HA, Dunkelberger GR, Green WR. Retinal ganglion cell atrophy correlated with automated perimetry in human eyes with glaucoma. *Am J Ophthalmol.* 1989;107:453-464.
41. Koh VT, Tham YC, Cheung CY, Wong WL, Baskaran M, Saw SM, Wong TY, Aung T. Determinants of ganglion cell-inner plexiform layer thickness measured by high-definition optical coherence tomography. *Invest Ophthalmol Vis Sci.* 2012;53:5853-5859.



## Intravitreal Bevacizumab Treatment in Type 2 Idiopathic Macular Telangiectasia

Tuğba Aydoğın, Gürkan Erdoğan, Cihan Ünlü, Ahmet Ergin  
Ümraniye Training and Research Hospital, Ophthalmology Clinic, İstanbul, Turkey

### Summary

**Objectives:** To evaluate the efficacy of intravitreal bevacizumab treatment in type 2 idiopathic macular telangiectasia (IMT).

**Materials and Methods:** Six eyes of 5 patients with type 2 IMT who received intravitreal bevacizumab between 2009 and 2014 were included in this study. All the patients had an ophthalmological examination including best corrected visual acuity (BCVA), dilated fundus examination, spectral domain optical coherence tomography (OCT) and fluorescein angiography. Intravitreal bevacizumab injection was planned for patients who had macular edema and/or decreased visual acuity at baseline. Patients were examined 1 week and 1 month after the intravitreal injection. Intravitreal injection was repeated in patients whose visual acuity decreased and/or whose macular edema persisted or increased. Changes in BCVA, central macular thickness (CMT) and central macular volume from baseline at 1 month after the first injection and at final examination were evaluated.

**Results:** Average age of the patients (4 female and 1 male) was  $62 \pm 11.8$  years. Average follow-up period was  $26 \pm 11$  months. Patients received an average of 2.3 (range 1-4) injections during follow-up. Average Snellen BCVA of the patients was  $0.48 \pm 0.29$ . BCVA increased at final examination compared to baseline in all of the patients. The difference between baseline and final visual acuities was significant ( $p < 0.05$ ). The patients' average CMT was  $328 \pm 139$   $\mu\text{m}$  at baseline and decreased by a mean of  $85 \pm 153$   $\mu\text{m}$  at 1 month after the first injection and  $65 \pm 142$   $\mu\text{m}$  at final examination, but the changes were not significant. CMT decreased at final examination compared to baseline in four patients and increased in both eyes of one patient.

**Conclusion:** Intravitreal bevacizumab injection is a preferable treatment method in regard to both visual acuity and OCT findings.

**Keywords:** Type 2 idiopathic macular telangiectasia, intravitreal bevacizumab, macular edema

### Introduction

Idiopathic macular telangiectasia (IMT), first described by Gass and Oyakawa,<sup>1</sup> is a clinical condition of telangiectasia and aneurysmal dilatations of the juxtafoveal retinal capillaries. IMT type 2 affects both genders equally and is more common in the fifth and sixth decades. Telangiectatic changes are the most common changes seen in the fundus. Although patients may initially present with unilateral involvement, long-term follow-up usually reveals changes in the fellow eye as well.<sup>2</sup> Yannuzzi et al.<sup>3</sup> separated IMT into nonproliferative and proliferative subgroups.

Clinical findings are highly variable; mild cases may manifest as loss of retinal transparency in the perifoveal temporal region,

while more severe cases exhibit prominent telangiectatic vessels on funduscopy, right-angle venules, intraretinal crystalline deposits, retinal pigment epithelium cell migration, and ultimately transformation to the proliferative type.<sup>2,3</sup> On fluorescein angiography (FA), slight intraretinal staining is observed in the early disease stages, whereas patients with substantial telangiectatic changes exhibit filling of the superficial telangiectatic capillaries and leakage from the deep capillaries.<sup>3</sup> Increased foveal thickness and intraretinal cystoid changes may be observed on spectral domain optical coherence tomography (SD-OCT).<sup>3,4,5,6</sup> Other possible findings are outer retinal atrophy and disruption of the inner segment/outer segment junction.<sup>5,6</sup>

**Address for Correspondence:** Tuğba Aydoğın MD, Ümraniye Training and Research Hospital, Ophthalmology Clinic, İstanbul, Turkey  
Phone: +90 536 521 21 75 E-mail: tuay1@hotmail.com **Received:** 30.09.2015 **Accepted:** 28.01.2016

©Copyright 2016 by Turkish Ophthalmological Association  
Turkish Journal of Ophthalmology, Published by Galenos Publishing House

Various treatments such as focal/grid argon laser therapy,<sup>7</sup> transpupillary thermotherapy,<sup>8</sup> photodynamic therapy,<sup>9</sup> subretinal membrane surgical excision,<sup>10</sup> and intravitreal triamcinolone<sup>11,12</sup> have been tried in type 2 IMT patients. In recent years, intravitreal anti-vascular endothelial growth factor (VEGF) injection has been administered to proliferative and nonproliferative patient groups in a variety of studies.<sup>12,13,14,15,16,17,18,19,20,21,22,23,24</sup> Although the results of these studies differ, some patients reportedly benefited from intravitreal anti-VEGF injections.

In the present study we aimed to examine the functional and morphologic effects of intravitreal bevacizumab injection in type 2 IMT patients.

## Materials and Methods

The study included 6 eyes of 5 patients treated with intravitreal bevacizumab therapy and followed in our clinic for type 2 IMT between 2009 and 2014. Approval was granted by the local ethics committee and informed consent forms were obtained from all patients.

All patients underwent a full ophthalmologic examination including best corrected visual acuity (BCVA) measurement and dilated fundus examination, SD-OCT (RTVue; Optovue Inc, CA, USA) and FA (Visucam; Zeiss, Meditec, Germany). Visual acuity was measured using Snellen chart and converted to logMAR (logarithm of the minimum angle of resolution) for statistical analysis. OCT measurements were done using a MM5 (5x5 mm<sup>2</sup> grid) protocol. Intravitreal bevacizumab injection was indicated in patients with macular edema and/or reduced visual acuity at presentation.

Intravitreal injections were performed in sterile operating room conditions. Intravitreal bevacizumab (1.25 mg) (Avastin, Roche, Germany) injections were done using a 27-gauge needle applied 3.5 mm from the temporal limbus in phakic patients and 3 mm in pseudophakic patients. Follow-up examinations were conducted at 1 week and 1 month after intravitreal injection. FA was repeated an average of once every 3 months. Intravitreal bevacizumab injections were repeated in patients whose BCVA decreased and/or whose macular edema persisted or worsened.

BCVA, central macular thickness (CMT) and central macular volume (CMV) were compared at baseline, at 1 month after the first injection and at final examination.

## Statistical Analysis

Number Cruncher Statistical System 2007&PASS (Power Analysis and Sample Size) 2008 Statistical Software (Utah, USA) was used for all statistical analyses. Study data were evaluated using descriptive statistical methods (mean, standard deviation, median, minimum and maximum) and the paired-samples t-test was used to compare quantitative data. Level of significance was  $p < 0.05$ .

## Results

Mean age of the patients (4 female and 1 male) was  $62 \pm 11.8$  years. Lesions were nonproliferative in all cases. Mean follow-up time was  $26 \pm 11$  months, during which patients received an average of 2.3 (range 1-4) injections. Patients' BCVA, CMT and CMV values at baseline, 1 month after the first injection and at final examination are shown in Table 1.

Mean Snellen BCVA (expressed as decimal) was  $0.48 \pm 0.29$  at baseline,  $0.68 \pm 0.36$  at 1 month after first injection and  $0.77 \pm 0.35$  at final examination (Figure 1). There was no significant difference in BCVA at 1 month after first injection compared to baseline, but the increase in BCVA between baseline and final examination was significant ( $p < 0.05$ ). All patients' showed improved BCVA at final examination compared to baseline.

Mean CMT value was  $328 \pm 139$   $\mu\text{m}$  at baseline, and decreased by a mean of  $85 \pm 153$   $\mu\text{m}$  at 1 month after first injection and by a mean of  $65 \pm 142$   $\mu\text{m}$  at final examination (Figure 2). However, the reductions in CMT were not statistically significant. CMT decreased in 4 patients at final examination compared to baseline, but increased in both eyes of the other patient. No significant changes in mean CMV were observed during follow-up.

Following intravitreal injection, patient 1's Snellen BCVA improved to 20/20 and OCT revealed that the extrafoveal intraretinal cysts had resolved. The juxtafoveal telangiectatic changes observed on FA diminished but did not completely resolve. There were no changes in the patient's BCVA during follow-up, so no further injections were administered.

After the first intravitreal injection, patient 2's Snellen BCVA improved from 20/100 to 20/25, the intraretinal cysts seen on OCT shrank, and a reduction in the juxtafoveal telangiectatic structures

**Table 1. Clinical data of type 2 idiopathic macular telangiectasia patients treated with intravitreal bevacizumab**

	Baseline		1 month post-injection					Final examination							
	BCVA	OCT	BCVA	OCT	CMV	Follow-up time (months)	Last injection month	Number of injections	BCVA	OCT	CMV				
Patient	Sex	Age	R/L	Snellen	CMT ( $\mu\text{m}$ )	CMV ( $\text{mm}^3$ )	Snellen	CMT ( $\mu\text{m}$ )	CMV ( $\text{mm}^3$ )	Follow-up time (months)	Last injection month	Number of injections	Snellen	CMT ( $\mu\text{m}$ )	CMV ( $\text{mm}^3$ )
1	F	58	L	0.6	269	5.658	1	263	5.558	7	Presentation	1	1	263	5.558
2	F	55	R	0.2	351	5.885	0.8	325	5.772	23	3	2	0.8	250	5.677
3	M	50	L	0.8	311	6.288	1	237	6.048	37	23	3	1	244	6.197
4	F	79	L	0.05	593	8.146	0.05	200	6.172	23	21	4	0.1	268	6.031
5	F	70	R	0.7	218	5.403	0.7	222	5.476	32	Presentation	1	1	272	5.506
			L	0.5	227	5.402	0.5	213	5.249	32	10	3	0.7	282	5.654

BCVA: Best corrected visual acuity, OCT: Optical coherence tomography, CMT: Central macular thickness, CMV: Central macular volume, F: Female, M: Male, R: Right, L: Left



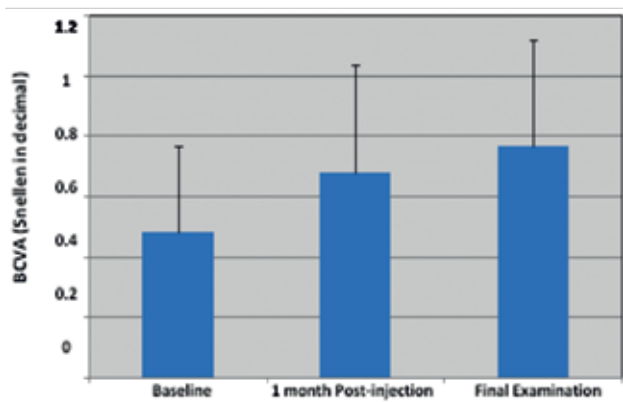
was observed on FA. The patient's BCVA declined during follow-up and another intravitreal injection was administered. Following the second intravitreal injection, BCVA remained stable at 20/25; therefore, no further injections were performed.

Following the first intravitreal injection, patient 3's Snellen BCVA improved to 20/20, the extrafoveal intraretinal cysts detected by OCT completely resolved, and foveal contours

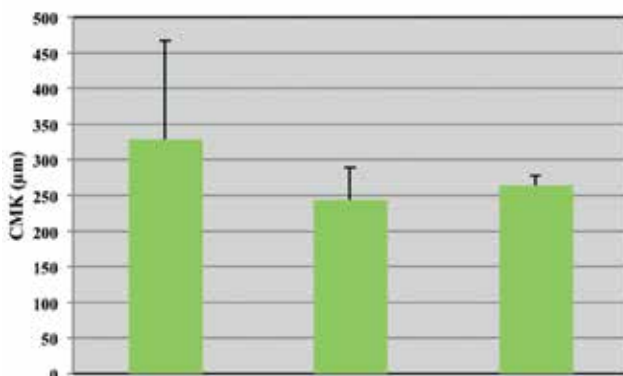
returned to normal. FA showed that the amount of leakage was reduced (Figure 3). Two additional injections were administered during follow-up due to decreased BCVA and increased CMT. After the final injection, BCVA remained stable at 20/20 and the foveal contours returned to normal.

Following the first intravitreal injection, patient 4's Snellen BCVA remained at 20/400. The intraretinal cysts were smaller on OCT, CMT was substantially decreased and the degree of leakage seen on FA was reduced. Repeated injections were done because the patient's CMT increased again during follow-up. There were no significant changes in BCVA during follow-up. This was attributed to the development of retinal atrophy due to prolonged macular edema.

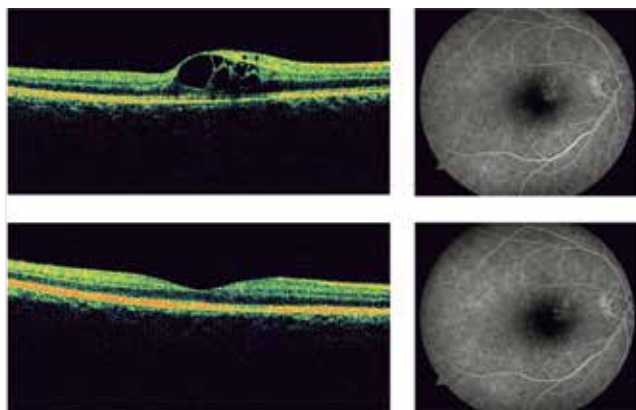
In patient 5, BCVA improved in both eyes after intravitreal injection. OCT at final examination revealed slightly increased CMT in both eyes, but the intraretinal cysts were smaller in size. Reduced leakage was observed in both eyes on FA. Additional injections were applied to the patient's left eye due to reduced visual acuity. Visual acuity in the right eye remained stable after a single injection.



**Figure 1.** Changes in patients' mean best corrected visual acuity  
BCVA: Best corrected visual acuity



**Figure 2.** Changes in patients' mean central macular thickness  
CMK: Central macular thickness



**Figure 3.** Optical coherence tomography and fluorescein angiography images obtained from patient #3 at presentation and at 1 month after intravitreal bevacizumab injection

## Discussion

The pathogenesis of type 2 IMT and the role of VEGF molecules in that pathogenetic process continues to be a controversial topic. Yannuzzi et al.<sup>3</sup> posited that endothelial cell degeneration may be the triggering factor of vasogenic mechanisms in the absence of pronounced ischemia or inflammation. Other investigators have claimed that, considering the function of Müller cells in supporting the retina, dysfunction in these cells may initiate and accelerate endothelial cell degeneration.<sup>25,26</sup> In their histopathologic study, Green et al.<sup>27</sup> proposed that endothelial degeneration and capillary structural disruption lead to retinal hypoxia, which may increase VEGF release and angiogenic activity.

Most studies of intravitreal injection of anti-VEGF agents in type 2 IMT have demonstrated that leakage on FA is generally reduced after injection.<sup>12,15,16,17,18,19,20,21,22</sup> In some of these studies, however, the leakage on FA was reported to return to baseline levels during periods without injections.<sup>15,17,20,22</sup> Similarly, though decreases in macular thickness measured by OCT may be detected initially,<sup>12,16,17,18,19,20,21,22,24</sup> studies with long-term follow-up after the final injection reported that OCT findings also returned to baseline.<sup>17,18,20,22</sup> Besides these studies, there are others in which no substantial changes in OCT findings were observed.<sup>13,14,15</sup> Results concerning visual acuity vary. Some studies show improvements in visual acuity,<sup>12,18,19,20,22</sup> whereas others report no change or even decline over time.<sup>13,14,15,16,20,22,24</sup> Response to treatment varies in terms of disease duration and severity, and degree of neuroretinal degeneration.

In the present study, the finding which most strongly supports intravitreal anti-VEGF therapy is the significant improvement in visual acuity at final examination. Although the patients showed some improvement in OCT findings, the changes were nonsignificant. This may be due to the small number of patients. The better results achieved by some patients may be attributable to

factors such as individual differences in treatment response, disease duration, and previous therapies. Despite variation in extent of treatment response, our study demonstrates that intravitreal anti-VEGF is a preferable treatment for type 2 IMT in terms of both visual acuity and OCT findings.

To date, no treatment protocol has been developed for type 2 IMT. Several treatment modalities are being tested. Studies of intravitreal injection of anti-VEGF agents have yielded conflicting data regarding treatment outcomes. Future studies including larger patient groups may provide results which more clearly demonstrate treatment response.

## Conclusion

In the present study and others in the literature, there are patients who have clearly benefited from intravitreal anti-VEGF therapy. Therefore, patients should be evaluated individually during the course of disease management.

### Ethics

Ethics Committee Approval: It was taken. Informed Consent: Obtained.

Peer-review: Externally peer-reviewed.

### Authorship Contributions

Surgical and Medical Practices: Tuğba Aydoğan, Gürkan Erdoğan, Cihan Ünlü, Ahmet Ergin, Concept: Tuğba Aydoğan, Gürkan Erdoğan, Cihan Ünlü, Ahmet Ergin, Design: Tuğba Aydoğan, Gürkan Erdoğan, Cihan Ünlü, Ahmet Ergin, Data Collection or Processing: Tuğba Aydoğan, Gürkan Erdoğan, Cihan Ünlü, Ahmet Ergin, Analysis or Interpretation: Tuğba Aydoğan, Gürkan Erdoğan, Cihan Ünlü, Ahmet Ergin, Literature Search: Tuğba Aydoğan, Gürkan Erdoğan, Cihan Ünlü, Ahmet Ergin, Writing: Tuğba Aydoğan, Gürkan Erdoğan, Cihan Ünlü, Ahmet Ergin.

Conflict of Interest: No conflict of interest was declared by the authors.

Financial Disclosure: The authors declared that this study received no financial support.

## References

- Gass JD, Oyakawa RT. Idiopathic juxtafoveal retinal telangiectasis. *Arch Ophthalmol.* 1982;100:769-780.
- Gass JD, Blodi BA. Idiopathic juxtafoveal retinal telangiectasis. Update of classification and follow-up study. *Ophthalmology.* 1993;100:1536-1546.
- Yannuzzi LA, Bardal AM, Freund KB, Chen KJ, Eandi CM, Blodi B. Idiopathic macular telangiectasia. 2006. *Retina.* 2012;32(Suppl 1):450-460.
- Surguch V, Gamulescu MA, Gabel VP. Optical coherence tomography findings in idiopathic juxtafoveal retinal telangiectasis. *Graefes Arch Clin Exp Ophthalmol.* 2007; 245:783-788.
- Paunescu LA, Ko TH, Duker JS, Chan A, Drexler W, Schuman JS, Fujimoto JG. Idiopathic juxtafoveal retinal telangiectasis: new findings by ultrahigh-resolution optical coherence tomography. *Ophthalmology.* 2006;113:48-57.
- Cohen SM, Cohen ML, El-Jabali F, Pautler SE. Optical coherence tomography findings in nonproliferative group 2a idiopathic juxtafoveal retinal telangiectasis. *Retina.* 2007;27:59-66.
- Park DW, Schatz H, McDonald HR, Johnson RN. Grid laser photocoagulation for macular edema in bilateral juxtafoveal telangiectasis. *Ophthalmology.* 1997;104:1838-1846.
- Shukla D, Singh J, Kolluru CM, Kim R, Namperumalsamy P. Transpupillary thermotherapy for subfoveal neovascularization secondary to group 2A idiopathic juxtafoveal telangiectasis. *Am J Ophthalmol.* 2004;138:147-149.
- Snyers B, Verougstraete C, Postelmans L, Leys A, Hykin P. Photodynamic therapy of subfoveal neovascular membrane in type 2A idiopathic juxtafoveal retinal telangiectasis. *Am J Ophthalmol.* 2004;137:812-819.
- Berger AS, McCuen BW, Brown GC, Brownlow RL Jr. Surgical removal of subfoveal neovascularization in idiopathic juxtafoveal retinal telangiectasis. *Retina.* 1997;17:94-98.
- Allredge CD, Garretson BR. Intravitreal triamcinolone for the treatment of idiopathic juxtafoveal telangiectasis. *Retina.* 2003;23:113-116.
- Raza S, Toklu Y, Anayol MA, Şimşek Ş, Özkan B, Altıntaş AK. Comparison between efficacy of triamcinolone acetonide and bevacizumab in a case with type 2A idiopathic parafoveal telangiectasia. *Turk J Ophthalmol.* 2011;41:6-9.
- Roller AB, Folk JC, Patel NM, Boldt HC, Russell SR, Abramoff MD, Mahajan VB. Intravitreal bevacizumab for treatment of proliferative and nonproliferative type 2 idiopathic macular telangiectasia. *Retina.* 2011;31:1848-1855.
- Kovach JL, Rosenfeld PJ. Bevacizumab (avastin) therapy for idiopathic macular telangiectasia type II. *Retina.* 2009;29:27-32.
- Rouvas A, Malamos P, Douvali M, Ntouraki A, Markomichelakis NN. Twelve months of follow-up after intravitreal injection of ranibizumab for the treatment of idiopathic parafoveal telangiectasia. *Clin Ophthalmol.* 2013;7:1357-1362.
- Toy BC, Koo E, Cukras C, Meyerle CB, Chew EY, Wong WT. Treatment of nonneovascular idiopathic macular telangiectasia type 2 with intravitreal ranibizumab: results of a phase II clinical trial. *Retina.* 2012;32:996-1006.
- Matt G, Sacu S, Ahlers C, Schütze C, Dunavoelgyi R, Prager F, Prunte C, Schmidt-Erfurth U. Thirty-month follow-up after intravitreal bevacizumab in progressive idiopathic macular telangiectasia type 2. *Eye (Lond).* 2010;24:1535-1541.
- Charbel Issa P, Finger RP, Holz FG, Scholl HP. Eighteen-month follow-up of intravitreal bevacizumab in type 2 idiopathic macular telangiectasia. *Br J Ophthalmol.* 2008;92:941-945.
- Charbel Issa P, Holz FG, Scholl HP. Findings in fluorescein angiography and optical coherence tomography after intravitreal bevacizumab in type 2 idiopathic macular telangiectasia. *Ophthalmology.* 2007;114:1736-1742.
- Charbel Issa P, Finger RP, Kruse K, Baumüller S, Scholl HP, Holz FG. Monthly ranibizumab for nonproliferative macular telangiectasia type 2: a 12-month prospective study. *Am J Ophthalmol.* 2011;151:876-886.
- Maia OO Jr., Bonanomi MT, Takahashi WY, Nascimento VP, Takahashi BS. Intravitreal bevacizumab for foveal detachment in idiopathic perifoveal telangiectasia. *Am J Ophthalmol.* 2007;144:296-299.
- Veloso CE, Vianna RN, Pelayes DE, Nehemy MB. Intravitreal bevacizumab for type 2 idiopathic macular telangiectasia. *Ophthalmic Res.* 2013;49:205-208.
- Meyer-ter-Vehn T, Herzog S, Schargus M, Gobel W, Guthoff R. Long-term course in type 2 idiopathic macular telangiectasia. *Graefes Arch Clin Exp Ophthalmol.* 2013;251:2513-2520.
- Matsumoto Y, Yuzawa M. Intravitreal bevacizumab therapy for idiopathic macular telangiectasia. *Jpn J Ophthalmol.* 2010; 54:320-324.
- Tout S, Chan-Ling T, Hollander H, Stone J. The role of Muller cells in the formation of the blood-retinal barrier. *Neuroscience.* 1993;55:291-301.
- Newman E, Reichenbach A. The Muller cell: a functional element of the retina. *Trends Neurosci.* 1996; 19:307-312.
- Green WR, Quigley HA, De la Cruz Z, Cohen B. Parafoveal retinal telangiectasis. Light and electron microscopy studies. *Trans Ophthalmol Soc U K.* 1980;100:162-170.



# Prevalence of Split Nerve Fiber Layer Bundles in Healthy People Imaged with Spectral Domain Optical Coherence Tomography

Sirel Gür Güngör, Ahmet Akman, Almıla Sarıgül Sezenöz, Gülşah Tanrıaşıklı

Başkent University Faculty of Medicine, Department of Ophthalmology, Ankara, Turkey

## Summary

**Objectives:** The presence of retinal nerve fiber layer (RNFL) split bundles was recently described in normal eyes scanned using scanning laser polarimetry and by histologic studies. Split bundles may resemble RNFL loss in healthy eyes. The aim of our study was to determine the prevalence of nerve fiber layer split bundles in healthy people.

**Materials and Methods:** We imaged 718 eyes of 359 healthy persons with the spectral domain optical coherence tomography in this cross-sectional study. All eyes had intraocular pressure of 21 mmHg or less, normal appearance of the optic nerve head, and normal visual fields (Humphrey Field Analyzer 24-2 full threshold program). In our study, a bundle was defined as 'split' when there is localized defect not resembling a wedge defect in the RNFL deviation map with a symmetrically divided RNFL appearance on the RNFL thickness map. The classification was performed by two independent observers who used an identical set of reference examples to standardize the classification.

**Results:** Inter-observer consensus was reached in all cases. Bilateral superior split bundles were seen in 19 cases (5.29%) and unilateral superior split was observed in 15 cases (4.16%). In 325 cases (90.52%) there was no split bundle.

**Conclusion:** Split nerve fiber layer bundles, in contrast to single nerve fiber layer bundles, are not common findings in healthy eyes. In eyes with normal optic disc appearance, especially when a superior RNFL defect is observed in RNFL deviation map, the RNFL thickness map and graphs should also be examined for split nerve fiber layer bundles.

**Keywords:** Retinal nerve fiber layer, split nerve fiber layer bundles, optical coherence tomography

## Introduction

The retinal nerve fiber layer (RNFL) contains ganglion cell axons, which are one of the components of the data pathway from the retinal photoreceptors to the visual cortex in the brain. Studies using scanning laser polarimetry (SLP) have demonstrated that the axons originating from the optic disc form two bundles (superior and inferior). Nerve fiber bundles may diverge, but these split bundles are physiologic rather than pathologic.<sup>1,2</sup>

Pieroth et al.<sup>3</sup> first described the 'double hump' pattern on optical coherence tomography (OCT) in individuals with split superior bundles. Colen and Lemij<sup>2</sup> also described superior, inferior or both split bundle patterns as SLP imaging findings.

The aim of this study was to describe split nerve fiber layer bundles and determine their prevalence in the healthy population of Turkey.

## Materials and Methods

The data of 359 subjects were examined cross-sectionally. The mean age was 43.5±8.8 years (range, 30-60 years). All subjects had intraocular pressure under 21 mmHg, normal visual field (on Humphrey Visual Field test 24-2 full threshold program) and normal optic nerve head. None of the subjects had any systemic or ocular diseases.

Seven hundred eighteen eyes of 359 healthy subjects were examined by Cirrus HD spectral-domain OCT (Carl Zeiss

**Address for Correspondence:** Sirel Gür Güngör MD, Başkent University Faculty of Medicine, Department of Ophthalmology, Ankara, Turkey

Phone: +90 312 212 68 68 E-mail: sirelgur@yahoo.com **Received:** 15.11.2015 **Accepted:** 02.03.2016

This article was presented as a poster at the Hong Kong World Glaucoma Congress held June 6-9<sup>th</sup>, 2015.

©Copyright 2016 by Turkish Ophthalmological Association

Turkish Journal of Ophthalmology, Published by Galenos Publishing House

Meditec, Dublin, CA, USA) under mydriasis. Subjects with signal strength less than 6 were not included in the study. In our study, we defined 'split bundles' as those showing a localized defect not resembling a wedge defect on the RNFL deviation map together with a relatively symmetrically division on the thickness map. Classification was performed by two independent observers. To standardize the classification, both observers used the reference example sets created by Colen and Lemij<sup>2</sup>. The final groups were formed by consensus agreement between the two observers for all subjects.

In fact, there is a wide spectrum between a fully split bundle and a single bundle, and partially split bundles have been previously described.<sup>2</sup> As a working principle, our criteria for a fully split bundle was that the nerve fiber bundle diverged completely extending to the optic nerve head on the RNFL thickness map and this divergence was reflected on the thickness graph as a double hump. We only included fully split bundles in this study.

### Results

The interobserver agreement of the classification was evaluated using  $\kappa$  statistics, and the  $\kappa$  value of 0.85 showed good agreement. In cases of disagreement, a consensus was reached. Nineteen subjects (5.29%) had bilateral superior split bundle (Figure 1) and 15 (4.16%) had unilateral superior split bundle (Figure 2). Split bundles were not detected in the remaining 325 subjects (90.52%). The distribution of split retinal nerve fiber bundles in our subjects is shown in Table 1.

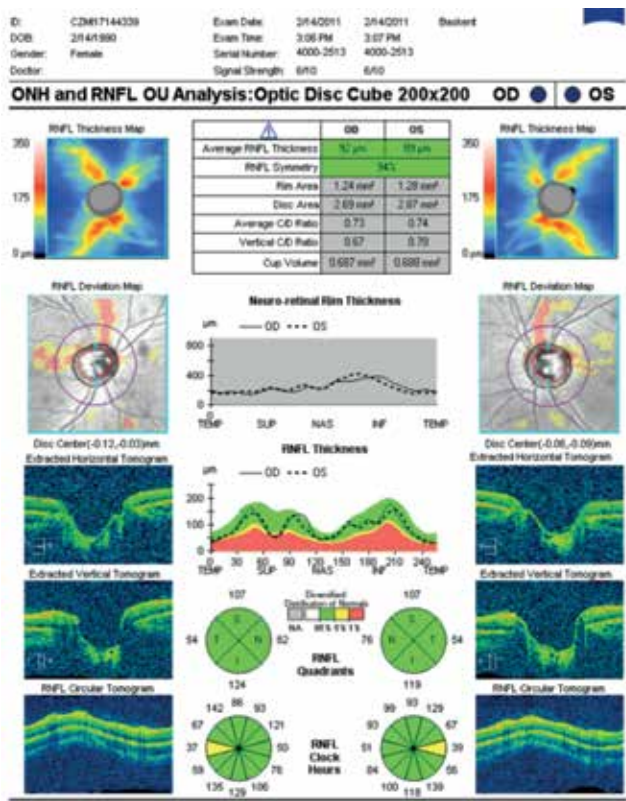
Of the subjects with unilateral split superior bundles, 8 (2.23%) were in right eyes and 7 (1.95%) were in left eyes. The prevalence of split bundles in right and left eyes was comparable ( $p=0.67$ ).

### Discussion

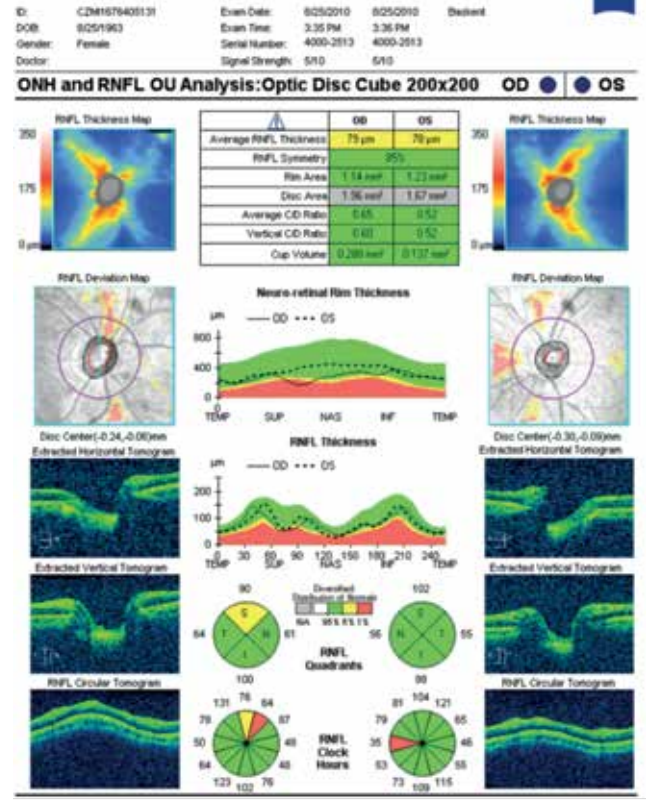
In healthy eyes, the peripapillary RNFL surrounding the optic disc is thickest in the superior and inferior quadrants and thinner in the nasal and temporal quadrants, exhibiting a double-hump pattern on the temporal-superior-nasal-inferior-temporal (TSNIT) graph.<sup>4,5</sup> Pieroth et al.<sup>3</sup> first described the split bundle pattern on OCT in a healthy eye. Colen and Lemij<sup>2</sup> demonstrated with GDx fixed corneal compensation data that a proportion of normal eyes exhibited superior and inferior split bundles on SLP, resulting in a triple or quadruple hump pattern in the RNFL thickness modulation graph. In other words, the superior and inferior bundles have two peaks. Of 454 eyes of 254 healthy subjects, Colen and Lemij<sup>2</sup> observed a clear split superior bundle pattern in 6.4%, clear split inferior bundle

**Table 1. Distribution of split retinal nerve fiber bundles in the study subjects**

Split bundle	Number of subjects	%
Bilateral superior	19	5.29
Unilateral superior	15	4.16
Single bundle	325	90.52



**Figure 1.** Bilateral split superior retinal nerve fiber bundle



**Figure 2.** Right split superior retinal nerve fiber bundle

pattern in 1.1%, and both split superior and inferior bundle patterns in 0.2% of the eyes. We also observed split superior bundles in 9.18% of the subjects in our study, similar to the results of Colen and Lemij.<sup>2</sup>

Using GDx variable corneal compensation, Kaliner et al.<sup>6</sup> demonstrated in a healthy eye with superior split bundle that the division in the bundle became more pronounced as the diameter of the measurement ring surrounding the optic disc increased. As a continuation of this study, Kaliner et al.<sup>6</sup> did a histologic investigation to determine whether the split bundle pattern was a real phenomenon. They performed a post mortem examination of 14 eyes of 13 patients and found the prevalence of split bundles was 36% (5/14; 3 superior, 2 inferior). None of the eyes exhibited both split superior and split inferior bundles. The high prevalence of split bundles found in this study compared to others can likely be attributed to low patient number. That study definitively demonstrated that split bundles are not an artifact of RNFL imaging but instead a real anatomic finding.

Glaucoma is a chronic optic neuropathy characterized by progressive optic nerve damage and typical visual field losses due to retinal ganglion cell death. Methods that provide reliable and objective data regarding optic disc and RNFL damage are critical in the diagnosis and monitoring of glaucoma. The use of OCT has become increasingly common to measure RNFL thickness and optic nerve head parameters in the diagnosis and management of glaucoma.<sup>7</sup> Although split bundles appear to be a normal finding that does not indicate disease, they may affect GDx and OCT parameters and be mistaken for wedge defect. In contrast to split bundles, wedge defects are separated from adjacent tissue with sharper margins and occur with glaucomatous changes in the optic nerve.<sup>2</sup> In the deviation maps and quadrant or clock hour graphs of certain imaging modalities, split bundles may give the impression of decreased retinal nerve fiber thickness compared to the normative data. In fact, TSNIT analysis without evaluating physiological variance between bundles within normative values is not very sensitive or specific. Determining separate normative value ranges for split and single bundles may increase sensitivity.

## Conclusion

Split nerve fiber bundles may be encountered in healthy eyes. For individuals with a normal, healthy optic nerve on examination, the RNFL thickness map and graph should be assessed for split

nerve fiber bundles, especially in the presence of a superior RNFL defect on the RNFL deviation map.

## Ethics

Ethics Committee Approval: Retrospective study. Informed Consent: It was taken.

Peer-review: Externally peer-reviewed.

## Authorship Contributions

Surgical and Medical Practices: Sirel Gür Güngör, Ahmet Akman, Almıla Sarıgül Sezenöz, Gülşah Tanrıaşıklı, Concept: Sirel Gür Güngör, Ahmet Akman, Almıla Sarıgül Sezenöz, Gülşah Tanrıaşıklı, Design: Sirel Gür Güngör, Ahmet Akman, Almıla Sarıgül Sezenöz, Gülşah Tanrıaşıklı, Data Collection or Processing: Sirel Gür Güngör, Ahmet Akman, Almıla Sarıgül Sezenöz, Gülşah Tanrıaşıklı, Analysis or Interpretation: Sirel Gür Güngör, Ahmet Akman, Almıla Sarıgül Sezenöz, Gülşah Tanrıaşıklı, Literature Search: Sirel Gür Güngör, Ahmet Akman, Almıla Sarıgül Sezenöz, Gülşah Tanrıaşıklı, Writing: Sirel Gür Güngör, Ahmet Akman, Almıla Sarıgül Sezenöz, Gülşah Tanrıaşıklı.

Conflict of Interest: No conflict of interest was declared by the authors.

Financial Disclosure: The authors declared that this study received no financial support.

## References

1. Vermeer KA, Reus NJ, Vos FM, Lemij HG, Vossepoel AM. Split bundle detection in polarimetric images of the human retinal nerve fiber layer. *Methods Inf Med.* 2007;46:425-431.
2. Colen TP, Lemij HG. Prevalence of split nerve fiber layer bundles in healthy eyes imaged with scanning laser polarimetry. *Ophthalmology.* 2001;108:151-156.
3. Pieroth L, Schuman JS, Hertzmark E, Hee MR, Wilkins JR, Coker J, Mattox C, Pedut-Kloizman R, Puliafito CA, Fujimoto JG, Swanson E. Evaluation of focal defects of the nerve fiber layer using optical coherence tomography. *Ophthalmology.* 1999;106:570-579.
4. Essock EA, Sinai MJ, Bowd C, Zangwill LM, Weinreb RN. Fourier analysis of optical coherence tomography and scanning laser polarimetry retinal nerve fiber layer measurements in the diagnosis of glaucoma. *Arch Ophthalmol.* 2003;121:1238-1245.
5. Leung CK, Chan WM, Chong KK, Yung WH, Tang KT, Woo J, Chan WM, Tse KK. Comparative study of retinal nerve fiber layer measurement by StratusOCT and GDx VCC, I: correlation analysis in glaucoma. *Invest Ophthalmol Vis Sci.* 2005;46:3214-3220.
6. Kaliner E, Cohen MJ, Miron H, Kogan M, Blumenthal EZ. Retinal nerve fiber layer split bundles are true anatomic variants. *Ophthalmology.* 2007;114:2259-2264.
7. Korkmaz B, Yiğit U, Ağaçhan A, Helvacıoğlu E, Bilen H, Tuğcu B. Evaluation of the relationship between retinal nerve fiber layer and ganglion cell complex measured by optical coherence tomography in glaucomatous and normal cases. *Turk J Ophthalmol.* 2010;40:338-342.



# The Importance of Frozen Section-Controlled Excision in Recurrent Basal Cell Carcinoma of the Eyelids

Berna Şahan\*, Ferda Çiftçi\*, Ferda Özkan\*\*, Vildan Öztürk\*

\*Yeditepe University Faculty of Medicine, Department of Ophthalmology, İstanbul, Turkey

\*\*Yeditepe University Faculty of Medicine, Department of Pathology, İstanbul, Turkey

## Summary

**Objectives:** To show the importance of frozen section-controlled excision to avoid the re-recurrence of recurrent basal cell carcinoma (BCC) of the eyelids.

**Materials and Methods:** Thirty-five cases who underwent eyelid tumor excision in different centers and were admitted to our clinic with recurrent eyelid tumors. Recurrent tumors were resected by excision 1-2 mm from the tumor's visible margin and sent to pathology for frozen section examination. Eyelid reconstructions with flap and graft were performed after confirming that the surgical margins were negative.

**Results:** Twenty-one (60%) of our patients were male and 14 (40%) were female. Median age of our group was 63.4±14.2 years. Excision and sending the excised material for frozen section control was performed once for 11 patients, twice for 12 patients, 3 times for 8 patients and 4 times for 4 patients to confirm that the surgical margins were clean. All pathology samples were reported as BCC. All patients had eyelid reconstruction with flap and graft. Recurrence was detected in 2 patients (5.7%) during 1 to 8 years (mean 4.3 years) of follow-up and those patients were reoperated; no recurrence was detected in the remaining 33 patients (94.3%).

**Conclusion:** Frozen section control can provide low re-recurrence rate in patients with recurrent BCC of the eyelids.

**Keywords:** Recurrent basal cell carcinoma, frozen section, eyelid reconstruction

## Introduction

Basal cell carcinoma (BCC) comprises approximately 90% of malignant tumors on and around the eyelid.<sup>1</sup> In Turkey this rate has been reported as 70-95.5%.<sup>2,3,4,5,6</sup> Prolonged sun exposure, light skin complexion, advanced age, and diseases like Xeroderma pigmentosum and Gorlin syndrome are among the known risk factors for BCC.<sup>7</sup>

The most common histopathologic subtype of BCC is the nodular type.<sup>8</sup> Rodent ulcers, which form as a result of a nodule with central elevation and overlying ulceration, are seen in this type. The morpheiform type of BCC is a more aggressive tumor and may simulate chronic blepharitis clinically.<sup>9</sup>

In the periocular region, BCC occurs most often in the lower eyelid, followed by the inner canthus, upper eyelid and outer canthus.<sup>10</sup> BCC generally progresses slowly and very rarely metastasizes.<sup>11</sup> Local spread to surrounding tissues is clinically significant. Tissues which may be affected include the conjunctiva, cornea, orbit, paranasal sinuses, nasal cavity and central nervous system.<sup>12</sup>

Frozen section is a technique which ensures clean surgical margins during excision. In this procedure, after excising the mass, its anatomic position is mapped on paper and the mass is sent to pathology for frozen section examination. If carcinoma cells are found at the surgical margins, the excision area is enlarged and frozen section control is repeated. This process is repeated until the surgical margins are clean.<sup>13</sup>

**Address for Correspondence:** Berna Şahan MD, Yeditepe University Faculty of Medicine, Department of Ophthalmology, İstanbul, Turkey  
Phone: +90 538 961 68 61 E-mail: gokceberna@hotmail.com **Received:** 01.10.2015 **Accepted:** 05.02.2016

©Copyright 2016 by Turkish Ophthalmological Association  
Turkish Journal of Ophthalmology, Published by Galenos Publishing House

Surgery excision is considered the gold standard in BCC therapy.<sup>14</sup> Surgical techniques like Mohs micrographic surgery and frozen section can be used to minimize postoperative recurrence. Postoperative recurrence of primary BCC has been reported at rates of 1.7% in the frozen section group and 1.6% in a Mohs micrographic surgery group.<sup>13,15</sup> Although both of these techniques result in similar recurrence rates, Mohs micrographic surgery is more difficult and costly to perform.<sup>16</sup> The aim of the present study was to report the surgical outcomes of patients who presented to our clinic with recurrent periocular BCC after primary excision and underwent frozen section controlled excision to prevent further recurrence.

## Materials and Methods

The records of all patients who had previously undergone a primary surgery for periocular BCC and who later underwent frozen section-controlled excision in our clinic due to recurrence between 2007 and 2015 were analyzed retrospectively. Preoperatively, all patients' initial histologic diagnosis was reported as BCC. The records of 37 patients met these criteria; 2 patients were excluded from the study due to inadequate follow-up time. Thirty-five eyes of 35 patients followed regularly for at least 1 year were included in the study.

Patients were evaluated in terms of age, gender, location of the mass, how many rounds of intraoperative frozen section were performed, surgery duration, mass histopathology (noduloulcerative type or morpheaform type), spread to surrounding tissues, reconstructive procedures used, presence of new recurrence, time and location of new recurrence, and follow-up time.

All operations were performed by the same surgeon (E.Ç.). After marking the margins of the BCC with a sterile pen, local anesthesia was injected (2% lidocaine with 1/10.000 adrenaline). The area of excision extended 1-2 mm beyond the apparent mass margin; the mass was mapped on paper, then sent to pathology for frozen section examination (Figure 1). The excision area was enlarged and frozen section was repeated until the surgical margins were clean on examination.

Specimens for frozen section were frozen to -22 °C within 10 minutes in the Shandon Cryotome SME Cryostat (Thermo Fisher Scientific, Inc., Waltham, MA, USA) and 5-micron-thick sections of the surgical margin were stained for 3 minutes with hematoxylin-eosin (H&E) stain. All surgical margins were evaluated by pathologist and reports were issued. The total examination time, including all procedures, varied between 15 and 20 minutes for each sample.

Eyelid reconstruction procedures were performed after the results of pathologic examination confirmed the surgical margins were clean. Reconstructive procedures were chosen based on the size, location and shape of the defect and the anatomic structures involved.

During reconstruction for partial lower eyelid defects, the posterior lamella was created from an ipsilateral upper eyelid tarsoconjunctival flap (modified Hughes method), while contralateral upper eyelid tarsoconjunctival grafts were used

for larger defects. The reconstruction procedure was completed by creating the anterior lamella using a cheek advancement or rotation flap. For partial upper eyelid defects, reconstruction was done using an ipsilateral tarsoconjunctival transposition flap (tarsal rotation flap) to create the posterior lamella and an ipsilateral upper eyelid transposition flap or contralateral upper eyelid free graft for the anterior lamella. For larger upper eyelid defects, reconstruction was done using a lower eyelid tarsoconjunctival flap and free muscle-skin graft for the anterior lamella or by one-step reconstruction (contralateral upper eyelid tarsoconjunctival graft and local muscle-skin flap for the anterior lamella). Patients with upper eyelid defects and excision of the medial canthal area underwent reconstruction by tarsal rotational flap and glabellar rotation flap recruited from the forehead.

No complications occurred in any of the patients postoperatively. Patients were followed at 6-month intervals.

## Results

Mean age of the 35 patients who were diagnosed with recurrent BCC and underwent frozen section controlled excision was 63.4±14.2 years (range, 35-83 years). Twenty-one (60%) of the patients were female, 14 (40%) were male. BCC was located on the lower eyelid in 26 patients (74.3%), upper eyelid in 4 (11.4%) and upper eyelid/medial canthal region in 5 patients (14.3%).

Frozen section control was performed once in 11 patients, twice in 12 patients, 3 times in 8 patients and 4 times in 4 patients in order to achieve clean surgical margins. Time required for the frozen section procedure ranged from 15-20 minutes for all samples. Definite pathologic examination results were reported as morpheaform BCC in 2 cases (5.7%) and as noduloulcerative BCC in the remaining 33 cases (94.3%) (Table 1). Lacrimal system involvement was noted in one patient whose mass was in the upper eyelid/medial canthal region; the lacrimal system and canaliculi were included in the excision area (Figure 1).

In all patients, primary repair was inadequate to reconstruct the eyelid defects resulting from surgical excision. Therefore, graft and flap reconstruction was done in all patients (Figures 2, 3).

Modified Hughes procedure and cheek muscle-skin advancement flap was performed in 14 patients in whom more than 50% of the lower eyelid was excised and primary closure could not be performed (Figure 2). For the 5 patients with full lower eyelid defect, the posterior lamella was formed by a tarsoconjunctival graft taken from the contralateral upper eyelid, while the anterior lamella was formed using a cheek transposition or rotation flap.

For the 9 patients whose upper eyelid defects could not be repaired by primary closure or had 50-75% of the upper eyelid excised, reconstruction was done using an ipsilateral tarsal rotational flap to create the posterior lamella and an ipsilateral upper eyelid advancement or contralateral upper eyelid free graft for the anterior lamella. Three patients with defects greater than 75% of the upper eyelid after excision underwent reconstruction using either lower eyelid tarsoconjunctival flap and free muscle-skin graft or one-step reconstruction.

Of the 4 patients whose mass was located in the upper eyelid/medial canthal region, lacrimal system involvement was discovered intraoperatively in 1 patient and the excision area was expanded to include the lacrimal sac and canaliculi. During reconstruction for these 4 patients, the posterior lamella was formed using ipsilateral tarsal rotational flap and the anterior lamella of the upper eyelid and canthal region was created with a glabellar rotation flap.

A cosmetically acceptable outcome was achieved in all cases. Patients were followed at 6-month intervals. Recurrence occurred in 2 patients (5.7%) during the postoperative follow-up period of 1-8 years (mean: 4.3±2.1 years), at postoperative 1 year in a patient with total lower eyelid involvement and at postoperative 7 months in a patient with medial canthal region and lacrimal system involvement. Definitive pathology was reported as morpheaform BCC for both of the patients with recurrence.

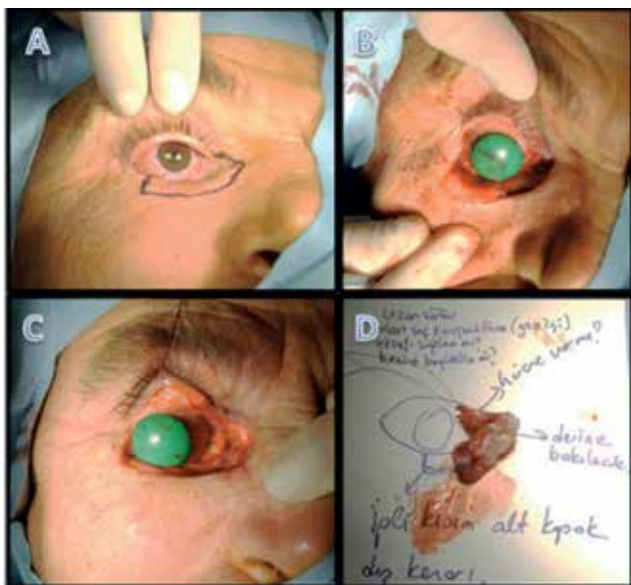
### Discussion

BCC is the most common malign neoplasm of the periocular region. About 95% of patients with BCC are between 40 and 79 years of age. Its slow progression and spread to surrounding tissues conjunctiva, cornea, orbit, paranasal sinuses, nasal cavity

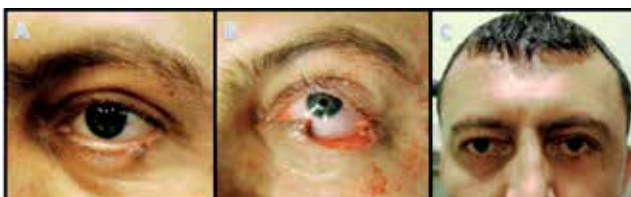and central nervous system) are clinically significant.<sup>11,12</sup> Spread of the tumor into surrounding tissues makes complete excision and reconstruction a challenge.

Risk factors for recurrence in BCC include previous recurrence of the tumor, location in the medial canthal region,<sup>17</sup> morpheaform type<sup>18</sup> and large tumor size. Mohs<sup>19</sup> reported a cure rate of 80% in patients with tumors larger than 3 cm, whereas the cure rate for smaller tumors was 99.4%.

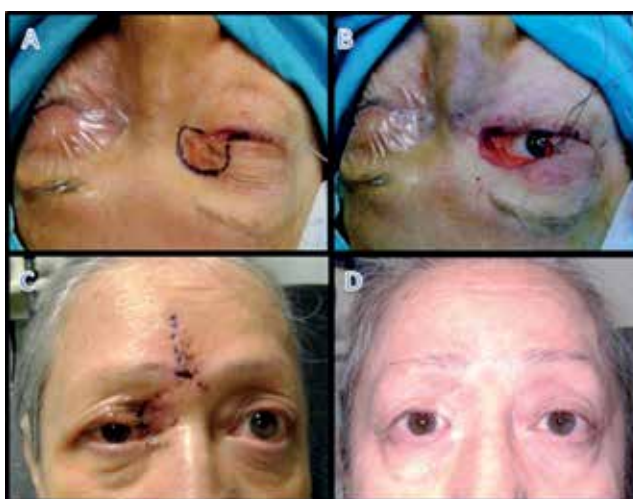Nonsurgical treatment options for BCC include cryotherapy, radiotherapy, photodynamic therapy, curettage and electrodissection, and topical immunomodulators such as topical 5-fluorouracil and imiquimod. However, surgical excision is accepted as the definitive treatment for BCC.<sup>14</sup> Recurrence rates after BCC excision and primary repair without performing Mohs micrographic surgery or frozen section controlled surgery were reported as 64% by Downes et al.,<sup>20</sup> 50% by Older et al.,<sup>21</sup> 26%



**Figure 1.** A 54-year-old male patient with mass in the left lower eyelid and medial canthal area: preoperative marking of mass margins (A); appearance after 3 rounds of intraoperative frozen section controlled excision (B,C); appearance of mass while sending for frozen section examination (D)



**Figure 2.** A 35-year-old male patient with mass of the lower eyelid: preoperative appearance (A); appearance after 3 rounds of intraoperative frozen section controlled excision (B); postoperative 1 year appearance after reconstruction by ipsilateral tarsoconjunctival flap and cheek muscle-skin advancement (C)



**Figure 3.** A 65-year-old female patient: preoperative marking showing planned excision area (A); appearance of the excision area related to the lacrimal system after 3 rounds of frozen section controlled excision (B); appearance at 1 week after reconstruction using tarsal rotational flap and glabellar skin flap (C); appearance at postoperative 3 years (D)

Table 1. Patients' demographic data and tumoral anatomic location and histologic type		
n=35	Number (%)	
Gender (female/male)	21 (60)/14 (40)	
Mean age (years)	63.4±14.2	
<b>Tumor location</b>		
Partial lower eyelid	14 (40)	9 lateral (25.7) 5 central (14.3)
Partial upper eyelid	12 (34.3)	7 medial (20) 5 central (14.3)
Upper eyelid and medial canthal area	4 (11.4)	
Total lower eyelid	5 (14.3)	
<b>Histopathologic type</b>		
Noduloulcerative	33 (94.3)	
Morpheaform	2 (5.7)	



by Doxanas et al.<sup>22</sup> and in Turkey, 8% by Günel and Akbaş<sup>8</sup> and 16.7% by Yalçın Tök et al.<sup>23</sup> Variations in amount of tissue excised and follow-up times contribute to the differences in these reported rates.

Recurrence rates after frozen section controlled excision were reported as 1.7% by Gayre et al.,<sup>13</sup> 4% by Nemet et al.,<sup>10</sup> 0.7% by Wong et al.,<sup>24</sup> 0.26% by Ho et al.<sup>25</sup> and 1.3% by Gill et al.,<sup>26</sup> while no recurrence was observed by Conway et al.<sup>27</sup> after 5 years, by Taherian et al.<sup>28</sup> after 38 months or by Akbaş Kocaoğlu et al.<sup>29</sup> in Turkey after 18.7 months of follow-up.

Among patients with recurrent BCC, new recurrence occurred after frozen section-controlled excision in 4.4% of 21 patients studied by Older et al.,<sup>21</sup> 3.8% of 26 patients for Ho et al.<sup>25</sup> and 4.8% of 21 patients in a study by Giordano Resti et al.<sup>30</sup>

This demonstrates that the recurrence rate is higher in recurrent BCC than in primary BCC. Consistent with these other studies, recurrence occurred in 2 patients (5.7%) in the present study during the follow-up period. Evaluation of recurrent BCC cases in the literature reveals that tumors of the morpheaform subtype and those located in the medial canthus are particularly prone to recurrence.<sup>25,30</sup> In our series, both recurrent tumors were of the morpheaform type; one was located in the medial canthus area, while the other showed total lower eyelid involvement.

The Mohs micrographic surgery is currently considered the most reliable intraoperative method for minimizing the recurrence rate of BCC.<sup>31</sup> In the procedure, tissue blocks which are 5-10 mm<sup>2</sup> and 2-4 mm thick are excised in a lamellar fashion until the surgical margins are proven to be clear. The recurrence rate after Mohs micrographic surgery has been reported as 2% over a 5-year follow-up period, with this rate increasing to 3-20% in patients with previous recurrence.<sup>15,32,33,34</sup> However, the procedure cannot be performed in many clinics in Turkey and abroad due to the cost and need for an experienced pathologist.<sup>16</sup> In recurrent BCC cases, frozen section controlled excision and Mohs micrographic surgery have comparable postoperative recurrence rates.

All patients in the present study presented to our clinic with recurrent BCC, and treatment with frozen section controlled excision was chosen in order to reduce the risk of possible re-recurrence. The first excision was done 1-2 mm beyond the visible tumor margin. The number of rounds of frozen section control required for the pathologist to intraoperatively confirm clean surgical margins was 1 in 11 patients, 2 in 12 patients, 3 in 8 patients and 4 in 4 patients. These excisions resulted in an excision area that was several times larger than the apparent size of the tumor preoperatively. Graft and flap eyelid reconstruction was performed in all cases. It is well known that BCC can extensively invade surrounding tissues and that excising an area much larger than the clinically visible tumor may be necessary, especially in cases of recurrence. In the present study, frozen section controlled excision both ensured that enough tissue was removed to achieve clean surgical margins and allowed the labor intensive reconstruction procedures to be conducted with confidence knowing that the surgical margins were clean.

During the follow-up period of mean 4.3 years, 2 patients (5.7%) experienced recurrence, 1 with total lower eyelid

involvement and 1 with a tumor in the upper eyelid/medial canthal region with lacrimal gland involvement, and were reoperated; recurrence was not detected in the other 33 patients (94.3%). All patients in our series presented with recurrent BCC; therefore, frozen section controlled excision was chosen in order to minimize the risk of new recurrence postoperatively. Excision was initially performed 1-2 mm beyond the visible tumor margins and the excision area was enlarged until clean surgical margins were confirmed. Traditionally, in BCC surgery the excision area includes 3-4 mm of healthy tissue.<sup>25</sup> Furthermore, it is known that inadequate excision increases recurrence. However, excessive tissue removal makes reconstructive procedures more challenging and may be an obstacle to achieving a cosmetically acceptable outcome. It is therefore considered adequate to begin excising 1-2 mm beyond the visible lesion in surgeries performed with intraoperative frozen section control. Using the frozen section control procedure in our patients, we ensured clean surgical margins while minimizing tissue excision and achieved cosmetically acceptable results after reconstruction (Figures 2, 3).

Intraoperative frozen section control extends surgery times, increases costs and requires an experience pathologist to be present at the medical center where the surgery is performed. In recurrent BCC, which has a higher recurrence rate than primary BCC, excision with frozen section control may lower the incidence of recurrence for these patients.

#### Ethics

Ethics Committee Approval: A retrospective study, Informed Consent: It was taken.

Peer-review: Externally peer-reviewed.

#### Authorship Contributions

Surgical and Medical Practices: Ferda Çiftçi, Ferda Özkan, Concept: Ferda Çiftçi, Design: Ferda Çiftçi, Data Collection or Processing: Berna Şahan, Analysis or Interpretation: Berna Şahan, Ferda Çiftçi, Vildan Öztürk, Literature Search: Berna Şahan, Writing: Berna Şahan, Ferda Çiftçi.

Conflict of Interest: No conflict of interest was declared by the authors.

Financial Disclosure: The authors declared that this study received no financial support.

#### References

1. Donaldson MJ, Sullivan TJ, Whitehead KJ, Williamson RM. Squamous cell carcinoma of the eyelids. *Br J Ophthalmol.* 2002;86:1161-1165.
2. Demir CY, Köhle Ü. Periorbital bölge malign cilt tümörleri: retrospektif çalışma. *Fırat Tıp Dergisi.* 2003;8:206-209.
3. Özkılıç E, Peksayar G. Epidemiologic investigation of eyelid tumors. *Turk J Ophthalmol.* 2003;33:631-640.
4. Soysal H, Albayrak A. Primary malignant tumors of the eyelids. *Turk J Ophthalmol.* 2001;31:370-377.
5. Taşkıran Çömez A, Akçay L, Özgür Ö, Karadağ O, Doğan ÖK. Histopathological and epidemiological evaluation of eyelid masses. *Turk J Ophthalmol.* 2007;37:84-92.
6. Gundogan FC, Yolcu U, Tas A, Sahin OF, Uzun S, Cermik H, Ozaydin S, Ilhan A, Altun S, Ozturk M, Sahin F, Erdem U. Eyelid tumors: clinical data from an eye center in Ankara, Turkey. *Asian Pac J Cancer Prev.* 2015;16:4265-4269.
7. Garcia de Marcos JA, Dean-Ferrer A, Arroyo Rodriguez S, Calderon-Polanco J, Alamillos Granados FJ, Poblet E. Basal cell nevus syndrome: clinical and genetic diagnosis. *Oral Maxillofac Surg.* 2009;13:225-230.

8. Günalp İ, Akbaş F. Göz kapağının bazal hücreli karsinomu: 1100 olguda klinik bulgular ve tedavi yaklaşımları. *MN Oftalmoloji*. 1996;3:292-301.
9. Loeffler M, Hornblass A. Characteristics and behavior of eyelid carcinoma (basal cell, squamous cell sebaceous gland, and malignant melanoma). *Ophthalmic Surg*. 1990;21:513-518.
10. Nemet AY, Deckel Y, Martin PA, Kourt G, Chilov M, Sharma V, Benger R. Management of periocular basal and squamous cell carcinoma: a series of 485 cases. *Am J Ophthalmol*. 2006;142:293-297.
11. Prabhakaran VC, Gupta A, Huilgol SC, Selva D. Basal cell carcinoma of the eyelids. *Compr Ophthalmol Update*. 2007;8:1-14.
12. Weber RS, Lippman SM, McNeese MD. Advanced basal and squamous cell carcinomas of the skin of the head and neck. *Cancer Treat Res*. 1990;52:61-81.
13. Gayre GS, Hybarger CP, Mannor G, Meecham W, Delfanti JB, Mizono GS, Guerry TL, Chien JS, Sooy CD, Anooshian R, Simonds R, Pietila KA, Smith DW, Dayhoff DA, Engman E, Lacy J. Outcomes of excision of 1750 eyelid and periocular skin basal cell and squamous cell carcinomas by modified en face frozen section margin-controlled technique. *Int Ophthalmol Clin*. 2009;49:97-110.
14. Cook BE Jr, Bartley GB. Treatment options and future prospects for the management of eyelid malignancies: an evidence-based update. *Ophthalmology*. 2001;108:2088-2098.
15. Litwin AS, Rytina E, Ha T, Rene C, Woodruff SA. Management of periocular basal cell carcinoma by Mohs micrographic surgery. *J Dermatolog Treat*. 2013;24:232-234.
16. Hamada S, Kersey T, Thaller VT. Eyelid basal cell carcinoma: non-Mohs excision, repair, and outcome. *Br J Ophthalmol*. 2005;89:992-994.
17. Abe M, Ohnishi Y, Hara Y, Shinoda Y, Jingu K. Malignant tumor of the eyelid--clinical survey during 22-year period. *Jpn J Ophthalmol*. 1983;27:175-184.
18. Wolf DJ, Zitelli JA. Surgical margins for basal cell carcinoma. *Arch Dermatol*. 1987;123:340-344.
19. Mohs FE. Micrographic surgery for the microscopically controlled excision of eyelid cancers. *Arch Ophthalmol*. 1986;104:901-909.
20. Downes RN, Walker NP, Collin JR. Micrographic (MOHS') surgery in the management of periocular basal cell epitheliomas. *Eye (Lond)*. 1990;4:160-168.
21. Older JJ, Quickert MH, Beard C. Surgical removal of basal cell carcinoma of the eyelids utilizing frozen section control. *Trans Sect Ophthalmol Am Acad Ophthalmol Otolaryngol*. 1975;79:658-663.
22. Doxanas MT, Green WR, Iliff CE. Factors in the successful surgical management of basal cell carcinoma of the eyelids. *Am J Ophthalmol*. 1981;91:726-736.
23. Yalçın Tök Ö, Akbaş Kocaoğlu F, Örnek F. Surgery of primary basal cell carcinoma with frozen section controlled excision. *Turk J Ophthalmol*. 2010;40:125-129.
24. Wong VA, Marshall JA, Whitehead KJ, Williamson RM, Sullivan TJ. Management of periocular basal cell carcinoma with modified en face frozen section controlled excision. *Ophthal Plast Reconstr Surg*. 2002;18:430-435.
25. Ho SE, Brown L, Bamford M, Sampath R, Burns J. 5 years review of periocular basal cell carcinoma and proposed follow-up protocol. *Eye (Lond)*. 2013;27:78-83.
26. Gill HS, Moscato EE, Seiff SR. Eyelid margin basal cell carcinoma managed with full-thickness en-face frozen section histopathology. *Ophthal Plast Reconstr Surg*. 2014;30:15-19.
27. Conway RM, Themel S, Holbach LM. Surgery for primary basal cell carcinoma including the eyelid margins with intraoperative frozen section control: comparative interventional study with a minimum clinical follow up of 5 years. *Br J Ophthalmol*. 2004;88:236-238.
28. Taherian K, Shekarchian M, Atkinson PL. Surgical excision of periocular basal cell carcinomas. *Indian J Ophthalmol*. 2007;55:137-138.
29. Akbaş Kocaoğlu F, Yalçın Tök Ö, Burcu A, Örnek F. Kapak malign tümörlerinde dondurulmuş kesit denetimli eksizyon ve kapak rekonstrüksiyonu. *MN Oftalmoloji* 2010;17:46-50.
30. Giordano Resti A, Sacconi R, Baccelli N, Bandello F. Outcome of 110 basal cell carcinomas of the eyelid treated with frozen section-controlled excision: mean follow-up over 5 years. *Eur J Ophthalmol*. 2014;24:476-482.
31. Malhotra R, Huilgol SC, Huynh NT, Selva D. The Australian Mohs database, part II: periocular basal cell carcinoma outcome at 5-year follow-up. *Ophthalmology*. 2004;111:631-636.
32. Mohs FE. Micrographic surgery for the microscopically controlled excision of eyelid cancer: history and development. *Adv Ophthalmic Plast Reconstr Surg*. 1986;5:381-408.
33. Robins P, Rodriguez-Sains R, Rabinovitz H, Rigel D. Mohs surgery for periocular basal cell carcinomas. *J Dermatol Surg Oncol*. 1985;11:1203-1207.
34. Lang PG Jr. Mohs micrographic surgery. Fresh-tissue technique. *Dermatol Clin*. 1989;7:613-626.



# Use of Botulinum Neurotoxin in Ophthalmology

Emel Başar, Ceyhun Arıcı

İstanbul University Cerrahpaşa Faculty of Medicine, Department of Ophthalmology, İstanbul, Turkey

## Summary

Botulinum neurotoxin (BoNT) is the first biological toxin used in the treatment of ophthalmic diseases and to decrease skin wrinkles as an aesthetic agent. When used appropriately, it weakens the force of muscular contraction and/or inhibits glandular secretion. The most common areas for botulinum toxin treatment are the upper face, including the glabella, forehead, brows, and lateral canthal lines, or crow's feet. By relaxing the muscles causing wrinkles, non-permanent results may be achieved with its use. BoNT has gained widespread use in a variety of ophthalmic diseases. The effect of BoNT is temporary, but the therapeutic benefit is usually maintained even after repeated injections. Treatment is usually well tolerated. Complications and side effects associated with the treatment are rare and temporary. Complications occur due to weakness (chemodenervation) of adjacent muscle groups, immunological mechanisms and injection technique. Current therapeutic indications, doses, complications and contraindications of BoNT use in the following disorders related to ophthalmology were investigated: aesthetic use, strabismus, blepharospasm, hemifacial spasm, eyelid retraction, entropion, lacrimal hypersecretion syndrome, and facial paralysis.

**Keywords:** Botulinum toxin, blepharospasm, hemifacial spasm, strabismus

## Introduction

Botulinum neurotoxin (BoNT), which causes the disease botulism in humans, is produced by the spore-forming, anaerobic, gram-positive bacillus bacteria *Clostridium botulinum*. BoNT is the most potent toxin known to humans.<sup>1</sup>

BoNT, the first biotoxin identified, was first applied experimentally in 1973 by Scott et al.<sup>2</sup> to treat strabismus (horizontal muscles) and began to be used in humans in 1980.<sup>3</sup> BoNT type A (BoNT-A) was approved by the U.S. Food and Drug Administration (FDA) in for the treatment of strabismus, blepharospasm and hemifacial spasm in 1989 and later for administration to the glabellar area for esthetic purposes in 2002.<sup>4</sup> In Turkey, the Ministry of Health authorized the use of Botox (Allergan, Inc., Irvine, CA, USA) in 2001 and Dysport (Medicis Pharmaceutical Corp., Scottsdale, AZ, USA) in 2002.

It was noticed that patients treated with BoNT for blepharospasm showed a decrease in facial wrinkles, which

accelerated the research and implementation of BoNT used to treat wrinkles.<sup>5,6</sup> BoNT is now commonly used worldwide for esthetic purposes. Furthermore, the anhidrotic effect of the toxin was noticed after its application in neurologic diseases, and BoNT began to be used in the management of hyperhidrosis in 1994.<sup>7</sup>

## Mechanism of Action - Pharmacology

*Clostridium botulinum* is a gram-positive, anaerobic bacillus with seven antigenically unique serotypes (A-G). The neurotoxins produced by these serotypes differ in molecular size, ranging from 300 to 900 kilodalton (kDa) (Table 1). BoNT consists of a 50 kDa light chain and a 100 kDa heavy chain connected with disulfide bonds.<sup>8</sup> The A, B, E, F and G serotypes cause botulism in humans.<sup>9</sup> Type A is the most potent exotoxin, and is also the BoNT type most commonly used commercially. BoNT's mechanism of action is based on block the release of acetylcholine from the presynaptic nerve terminals. In addition

**Address for Correspondence:** Ceyhun Arıcı MD, İstanbul University Cerrahpaşa Faculty of Medicine, Department of Ophthalmology, İstanbul, Turkey  
Phone: +90 212 572 26 42 E-mail: ceyhundr@gmail.com **Received:** 02.10.2015 **Accepted:** 02.03.2016

©Copyright 2016 by Turkish Ophthalmological Association  
Turkish Journal of Ophthalmology, Published by Galenos Publishing House

to acetylcholine, BoNT also inhibits the release of other chemical stimulants such as noradrenaline, dopamine, serotonin, gamma aminobutyric acid, glycine and methionine-enkephalin peptide.<sup>8</sup>

The diffusion of BoNT is clinically important in terms of the development of side effects to the toxin. Due to their rapid disintegration after injection, the various protein complexes used in BoNT formulations are believed to not influence the diffusion of BoNT. The administration of BoNT in large volumes or at high doses increases the area of diffusion, thereby increasing the potential for side effects.<sup>10</sup>

#### Formulations Used in Clinical Practice

There are currently four commercial preparations of BoNT: Botox (Allergan, Inc., Irvine, CA, USA), Dysport (Medicis Pharmaceutical Corp., Scottsdale, AZ, USA), Myobloc/Neurobloc (Solstice Neurosciences, Inc., Louisville, KY, USA), and Xeomin/Bocouture (Merz Pharmaceuticals, Frankfurt, Germany) (Table 1). There are some differences between BoNT-A products. In 2009, the FDA stated that the potency of each BoNT-A product is determined by its method of preparation. In clinical practice, it is recommended to apply Botox or Dysport at a ratio of 1:2.5-3 units (U).<sup>10,11</sup> This dosage was determined based on safety rather than efficacy.<sup>12</sup> One U of Botox is equivalent to 1 U of Xeomin and 50-100 U of Myobloc.

One vial of Botox contains 100 U, one vial of Dysport contains 500 U, and one vial of Xeomin contains 50 or 100 U (there are two forms available) of BoNT-A. Myobloc is a BoNT-B preparation that comes in 3 different versions containing 2,500-10,000 U/vial. Unlike the other BoNT products, Myobloc requires no dilution and is ready for direct application.<sup>10</sup>

#### Preparation and Storage Conditions

As Botox is more preferred for ophthalmic, dermatologic and cosmetic applications, the discussion of administration and dosage will focus primarily on this product.<sup>4,6,10,11</sup> BoNT-A

preparations are distributed in the form of vials containing lyophilized powder. A Botox vial containing 100 U of BoNT-A is reconstituted with 1-8 mL of sterile saline. The resulting 0.1 mL of Botox solution contains between 1.25 and 10 U of BoNT-A.<sup>13</sup> In clinical practice, the most common dosage is 2.5 U/0.1 mL obtained by reconstituting the Botox vial with 4 mL of sterile saline. A Dysport vial containing 500 U can be reconstituted with 2.5-5 mL of saline (10-20 U/0.1 mL).<sup>14</sup> BoNT is very fragile, and thus care must be taken not to foam or agitate the solution when preparing it for use. The manufacturer recommends using the BoNT solution within 4 hours or reconstitution. BoNT should not be frozen after preparation; the solution must be stored at 2-8 °C and used within 24 hours. Studies have reported that BoNT-A preparations reconstituted with isotonic sodium chloride solution and stored at 2-8 °C can be safely used for up to 2 weeks without any noticeable decrease in clinical efficacy.<sup>11,15,16</sup>

In addition to maintaining efficacy, preserving the preparation's sterility is another important consideration. Alam et al.<sup>17</sup> demonstrated that the sterility of a single vial of BoNT-A was not compromised by injections performed at various times over a period of 7 weeks (of a total of 127 vials, each was used an average of 4.5 times).

#### Duration of Effect

BoNT begins to take effect within 24-72 hours and reaches maximum effect within 7-14 days. Its effect on autonomic nerves (in the treatment of hyperhidrosis, overactive bladder) lasts significantly longer (6-9 months) than its effect on striated muscle (for facial wrinkles; 3-4 months).<sup>13</sup>

#### Administration and Anesthesia

A 1 mL syringe with a 30-gauge needle is preferred for BoNT injection. Prior to injection, the skin should be cleaned with an alcohol-free antiseptic solution and dried. Amide-derivative topical creams containing a combination of lidocaine

Toxin	Onabotulinumtoxin-A	Abobotulinumtoxin-A	Incobotulinumtoxin-A	Rimabotulinumtoxin-B
Trade name	Botox (Allergan Inc.)	Dysport (Medicis Pharmaceutical Corp.)	Xeomin (Merz Pharmaceuticals)	Myobloc/Neurobloc (Solstice Neurosciences, Inc.)
BoNT serotype	A	A	A	B
Molecular weight	900 kD	500-900 kD	150 kD	700 kD
Indication	Blepharospasm, cervical dystonia, primary axillary hyperhidrosis, urinary incontinence, chronic migraine, upper limb spasticity, cosmetic uses (glabellar wrinkles, etc.)	Blepharospasm, cervical dystonia, cosmetic uses (glabellar wrinkles, etc.)	Blepharospasm, cervical dystonia, cosmetic uses (glabellar wrinkles, etc.)	Cervical dystonia
Units/vial	100	500	50, 100	2,500, 5,000, 10,000
Storage prior to opening	2-8 °C	2-8 °C	2-8 °C	2-8 °C
Shelf life (months)	36	24	36	24
Storage after opening	24 hours/2-8 °C	4 hours/2-8 °C	24 hours/2-8 °C	4 hours/2-8 °C

BoNT: Botulinum neurotoxin, kD: Kilodalton

and prilocaine may be used to reduce the sensation of pain. The skin is stretched taut to reveal superficial blood vessels that should be avoided during injection.<sup>18</sup>

#### Areas of Use

BoNT was approved by the FDA for the treatment of strabismus, blepharospasm and hemifacial spasm in 1989 and for esthetic purposes in 2002.<sup>4</sup> Since its approval in 2001 by the Turkish Ministry of Health, it has become widely used in Turkey for esthetic purposes. Besides ophthalmology, BoNT is also used in various branches of medicine for pain management and functional therapy. For both men and women, the ideal age group for the use of BoNT to treat facial wrinkles formed by repeated muscle contraction is 40-60 years old. In ophthalmoplasty, BoNT is also used in deviation and oculoplastic disorders such as strabismus, blepharospasm, hemifacial spasm, upper lid retraction, entropion, lacrimal gland hypersecretion, facial paralysis.

#### Facial Wrinkles

Hereditry, age, environmental factors, and overaction of the facial muscles all play a role in the development of wrinkles.<sup>19,20</sup> Lines that appear during movement or are unnoticeable during rest are called dynamic wrinkles, while lines with a pronounced appearance during rest are called static wrinkles.<sup>21,22</sup> Carruthers and Carruthers<sup>23</sup> noted that BoNT-A applied for cosmetic purposes was effective at lower doses when used in the middle and lower face compared to the upper face. BoNT interferes with muscle contraction and eliminates lines with no major local or systemic complications. The toxin is known to spread to an area of 2.5-3 cm around the facial injection site.<sup>24</sup> Low-volume, high-concentration solutions are used to reduce the spread of BoNT in cosmetic applications.

#### Forehead and Glabellar Wrinkles

The frontal muscle is responsible for wrinkles of the forehead area. When the frontal muscle pulls the muscles higher, horizontal lines appear in the skin of the forehead. The medial fibers of the frontal muscle are usually stronger, thus forming deep wrinkles. The horizontal wrinkles are marked while the frontal muscle is in maximum contraction, then intramuscular injections are done in 6 to 8 places with a dose of 10-15 U for Botox or 20-30 U for Dysport.<sup>18</sup>

The first cosmetic application of BoNT was to glabellar wrinkles. There are two muscles responsible for glabellar wrinkles: the procerus muscle contracts down toward the medial edge of the muscle and causes horizontal lines in the glabella, while the corrugator superciliaris muscle pulls down and in toward the medial end of the muscle, thus creating vertical lines in the area.<sup>25</sup> According to the clinical findings obtained from many studies using different doses, 5 injections are done in a V pattern to the glabellar area with a dose of 20 U Botox<sup>26,27</sup> or 50 U Dysport.<sup>28,29,30</sup> The BoNT-A dosage for men is generally higher due to their thicker muscle mass. In a placebo-controlled, double-blind, randomized study of Botox use, male patients required an initial dose of at least 40 U to treat glabellar wrinkles.<sup>31</sup>

#### Eyebrow Repositioning

Muscle position is determined by the balance of the frontal muscle (elevator), the orbicularis oculi, depressor supercili, corrugator supercilli and proserus (depressor).<sup>25,32</sup>

Intramuscular injection in the superior temporal aspect of the orbicularis oculi at 3 points with a total dose of about 10-15 U Botox or 30-40 U Dysport is recommended.<sup>18</sup> A Botox injection (7-10 U) to the orbicularis oculi muscle, one of the brow depressor muscles, was reported to cause an elevation of about 1 mm in the mid-pupillary area of the brow and about 5 mm in the lateral canthal region.<sup>33</sup> A three-point injection of approximately 6-10 U dose of Botox to the superior temporal orbicularis oculi muscle has been determined effective for lifting the brow.<sup>33,34</sup> The injections are administered to the lateral third of the muscle and 1 cm from the bony margin of the orbit to avoid intraorbital diffusion. BoNT diffusion to surrounding tissues can result in diplopia (lateral rectus muscle), ptosis (levator palpebrae muscle) and excessive brow elevation (lateral frontal muscle).<sup>35</sup>

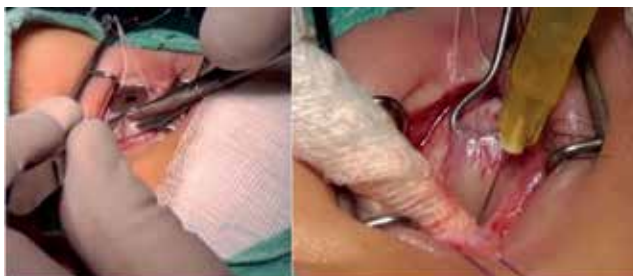#### Periorbital Wrinkles (Crow's Feet)

Crow's feet are wrinkles radiating outward from the lateral canthus due to the action of the orbicularis oculi while smiling.<sup>20</sup> BoNT injection is performed 1 cm from the lateral margin of orbit in order to prevent the diffusion of BoNT to the lateral rectus muscle.<sup>36</sup>

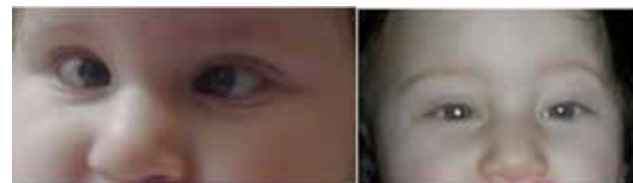Studies have determined that doses of 12 U of Botox<sup>37</sup> or 30-36 U of Dysport<sup>38,39</sup> divided into 3 injections are effective. Injecting BoNT too far above the lateral margin of orbit can cause superior eyelid ptosis, while injection too far below can result in zygomaticus muscle paralysis and lip asymmetry (lip ptosis).<sup>40</sup> Excessive paralysis of the orbicularis oculi muscle can cause weakened eye closing.<sup>24</sup>

#### Strabismus

BoNT was first applied ophthalmically in humans by Alan Scott as an alternative to strabismus surgery.<sup>3</sup> His aim was to



**Figure 1.** In the right eye, a fornix-based conjunctival flap is prepared from the nasal quadrant to expose the medial rectus muscle, then an intramuscular Botulinum neurotoxin injection is administered about 10 mm from the muscle insertion using a 30 gauge needle (from the Başar E. archive)



**Figure 2.** Pre- and post-botulinum neurotoxin-A injection (from the Başar E. archive)

reduce the deviation by weakening the contracting antagonist muscle. BoNT is particularly suitable for complicated cases such as patients who should avoid general anesthesia, patients with paralytic strabismus or postoperative consecutive strabismus, patients with deviations less than 40 diopters, cases of active thyroid orbitopathy, patients with cyclic esotropia, and those who have undergone multiple strabismus surgeries.<sup>41</sup>

Although electromyography is usually used to facilitate the accurate injection of BoNT into the target muscle<sup>42</sup> injection may also be done by an open method directly visualizing the muscle (Figure 1). The average dose for Botox is 1-3 U per muscle. The incidence of complications increases at higher doses (especially >10 U).<sup>41</sup> BoNT-A has been reported to decrease ocular deviation in more than 50% of patients<sup>43,44,45</sup> and yield satisfactory long-term results in infants and children.<sup>46,47</sup>

BoNT-A injection may be used as an alternative to strabismus surgery for pediatric esotropia.<sup>48</sup> Figure 2 shows a patient with infantile esotropia treated with BoNT-A (Botox) injection in our clinic. It can be seen that the patient's esotropia resolved after Botox injection. Tengtrisor et al.<sup>49</sup> administered BoNT-A to esotropic children (mean age 26.8 months) and found that the mean angle of deviation decreased from a baseline of 40.4 prism diopters before the first injection to 24.5 prism diopters before the second injection. They reported that BoNT-A administration yielded a successful outcome in about 73% of the patients. Ruiz et al.<sup>50</sup> observed success in patients older than 18 months after BoNT-A injection but reported failure in patients younger than 18 months old. In contrast, Campos et al.<sup>51</sup> found that BoNT treatment was more successful in infantile esotropia patients younger than 7 months compared to patients over 7 months old. In a series of 29 cases of acute unilateral sixth nerve palsy, complete recovery of eye movements was noted in 76% of patients treated with BoNT injection to the medial rectus muscle a mean of 40 days after the onset of lateral rectus muscle palsy.<sup>52</sup> In a case-control study by Yabaş et al.<sup>53</sup> including 22 patients with acute sixth cranial nerve palsy, 14 patients received BoNT injection in the ipsilateral antagonist muscle and 8 were followed with occlusion therapy. Although the two groups showed comparable cure rates, the BoNT group exhibited more rapid improvement of symptoms. For chronic sixth cranial nerve palsy, transposition surgery and BoNT injection to the medial rectus muscle may be considered as a safe and effective treatment option.<sup>54,55</sup>

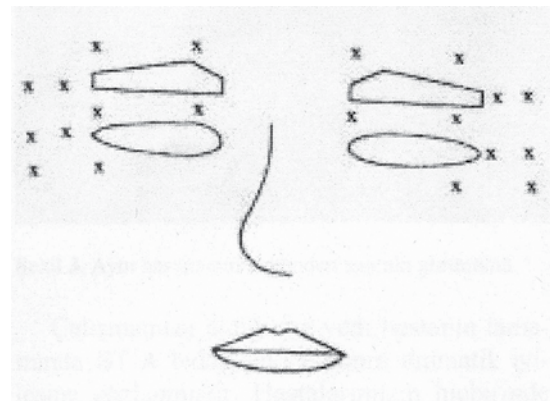
BoNT injection is also utilized as an alternative to surgery in exotropia patients. Sener and Sanac<sup>56</sup> administered BoNT to 25 esotropia patients (mean of 1.6 injections) and 45 exotropia patients (mean of 1.6 injections) with a deviation angle of about 38 prism diopters in both groups. They reported that the angle of deviation decreased to less than 10 prism diopters in 32% of the esotropia patients and 22% of the exotropia patients. Doses of BoNT-A over 10 U were associated with increased incidence of ptosis and vertical deviation. In another study, 1.25-5 U BoNT-A administered to prevent muscle contraction in 12 sensory strabismus patients with an average deviation of 34 prism diopters provided a mean corrective effect of 73%.<sup>57</sup>

Residual deviation and consecutive deviation due to overcorrection are potential complications that can affect the outcomes of strabismus surgery. Various therapeutic methods can be applied in these cases, including occlusion, prismatic correction, orthoptic treatment and eyeglasses. Dawson et al.<sup>58</sup> evaluated patients with consecutive esotropia following exotropia surgery and found that of 36 patients with fusion potential, BoNT-A injection resulted in an acceptable correction of deviation, resolution of diplopia and the development of high-quality stereopsis.

Approximately 80% of patients with infantile esotropia develop dissociated vertical deviation. BoNT-A injections were administered simultaneously to the medial rectus muscles of a total of 54 patients with infantile esotropia with accompanying dissociated vertical deviation divided into 2 groups by age (group 1 <18 months; group 2 >18 months). Complete correction of the horizontal deviation and dissociated vertical deviation was achieved in the over-18-month group.<sup>50</sup>

There are also reports of the benefits of BoNT administration in vertical deviations. Ozkan et al.<sup>59</sup> observed that BoNT-A administered to the inferior rectus muscle in cases of adherence syndrome reduced the need for secondary surgery. BoNT injection to the inferior and superior rectus muscles was determined to effect improvement of vertical deviations in thyroid eye disease.<sup>60</sup>

In addition to strabismus, BoNT is also applied in nystagmus. Application is performed to multiple horizontal rectus muscles or the retrobulbar area. In some cases, retrobulbar BoNT injection causes a significant reduction in nystagmus,<sup>44</sup> though unfavorable results have also been observed using this method.<sup>61</sup> The dosage used in retrobulbar injection is often higher (20-30 U) than that used in intramuscular injection to the recti. Reported side effects include ptosis, diplopia, inferior rectus palsy, and total ophthalmoplegia.<sup>41</sup> Carruthers<sup>62</sup> applied BoNT-A to the horizontal rectus muscles of 4 congenital nystagmus patients and observed acceptable nystagmus correction and visual improvement in 3 of them. Half of the patients received repeated BoNT injections every 3-4 months to maintain their



**Figure 3.** Injection spots for botulinum neurotoxin in the treatment of blepharospasm<sup>58</sup>

visual acuity. None of the patients developed retrobulbar hemorrhage, ptosis or globe perforation.

#### **Benign Essential Blepharospasm**

Essential blepharospasm is a focal cranial dystonia involving the eyelids and forehead muscles. It is characterized by frequent, involuntary contraction of the orbicularis oculi muscle, causing forceful closure of the eyes. Essential blepharospasm can lead to functional blindness due to involuntary eye closure. This can, in turn, have a substantial impact on patients' personal and professional lives.<sup>63</sup> Blepharospasm is more common among females.<sup>64</sup> Other than greater symptom severity and frequency among women, there are no significant differences in symptoms according to gender.<sup>65</sup> BoNT has been used successfully in the treatment of blepharospasm since the 1980s.<sup>4,66,67,68,69,70,71,72,73</sup> BoNT is injected into the orbicularis oculi muscle immediately below the skin. The injection site is often the medial and lateral aspects of the preseptal orbicularis oculi muscle in the upper and lower eyelids in order to reduce the risk of ptosis (Figure 3). The average dose is 12.5-25 U Botox or 50-100 U Dysport for each eye.<sup>4</sup> Some authors have stated that increasing the dose was necessary for repeated BoNT injections over the long term,<sup>14,71,74</sup> whereas other report being able to maintain efficacy with the same dose.<sup>67,75,76</sup>

Local side effects may include ecchymosis, hematoma, ectropion, entropion, loss of facial sensitivity, epiphora, dry eye, lagophthalmus, photophobia, diplopia, ptosis, lip drooping, and nasal discharge. Systematic side effects of nausea, fatigue and generalized itching have been reported.<sup>71,77,78</sup> Of the local side effects, diplopia most disturbs quality of life. Wutthiphpan et al.<sup>79</sup> reported diplopia in 1.7% of a large series of 250 cases. Ptosis is one of the most common complications. Price and O'Day<sup>80</sup> observed ptosis in 12% of their case series.

#### **Hemifacial Spasm**

Hemifacial spasm is the unilateral, repetitive tonic or clonic contraction of the facial muscles innervated by the facial nerve. It usually begins in the fifth to sixth decade and is unilateral. In contrast to blepharospasm, hemifacial spasm continues during sleep. It is not associated with excessive sensory stimulation. Rarely, the condition may manifest bilaterally.<sup>4</sup>

It is treated by 25-35 U Botox<sup>71,81</sup> or 47-92 U Dysport<sup>82,83,84</sup> injection. Of studies with long-term follow-up of BoNT-A injection for hemifacial spasm, Ababneh et al.<sup>71</sup> reported that the mean post-injection duration of effect was 14.1 weeks after 1 year and reached 18.1 weeks after 10 years. Gill and Kraft<sup>85</sup> determined the first 10 injections to be effective for a mean of 12.4 weeks and claimed this mean duration remained stable over the following 10 injections. Akdemir et al.<sup>86</sup> noted no change in duration of effect after BoNT injection in hemifacial spasm (mean follow-up 90.3 months) and increasing duration (16.1 weeks after the first 5 injections, 18.9 weeks after the last 5 injections) in blepharospasm patients (mean follow-up 51.8 months).

#### **Upper Eyelid Retraction**

BoNT can be used for the temporary correction of upper eyelid retraction. Temporary improvement of the palpebral

fissure height has been observed with doses of 2.5-10 U Botox delivered by transconjunctival injection just above the upper tarsal border into the levator-Müller muscle complex.<sup>87,88,89</sup> Salour et al.<sup>90</sup> reported that a single dose of 20 U of Dysport injected transcutaneously at the central superior tarsal border into the levator aponeurosis and Müller muscle was a safe and effective treatment. Ptosis and diplopia may arise as minor complications.

#### **Congenital and Acquired Entropion**

BoNT injection reduces the tone of the pretarsal and preseptal fibers of the orbicularis oculi muscle, thereby providing temporary correction of its inward folding. BoNT-A (Botox) is injected subcutaneously in 5 U doses to each of 3 points approximately 3-4 mm below the lower eyelid margin.<sup>91</sup>

#### **Lacrimal Gland Hypersecretion**

Gustatory (taste-related) lacrimation (crocodile tears syndrome) is an autonomic synkinesia causing excessive tear production. It is often idiopathic or arises secondary to aberrant reinnervation of the lacrimal gland by efferent fibers of the seventh or ninth cranial nerves in patients with history of traumatic facial palsy. A small proportion of patients may require treatment. BoNT-A injection has been shown to be effective.<sup>92</sup> A transconjunctival injection of 2.5 U BoNT-A (Botox) is applied directly to the palpebral lobe of the lacrimal gland. Duration of effect is 6 months.<sup>93,94</sup>

#### **Facial Paralysis**

Instead of tarsorrhaphy or gold weight implants to protect the ocular surface in cases of facial paralysis, corneal damage may be prevented by using BoNT-A injection to the levator palpebrae superioris muscle to induce eyelid ptosis. Due to the proximity of the levator palpebrae superioris muscle to the superior rectus muscle, Naik et al.<sup>95</sup> recommended using a needle half the length of the standard 25 mm needle in order to prevent hypotropia and weakened Bell reflex. Yucel and Arturk<sup>96</sup> injected 7.5 U BoNT-A (Botox) near the midline of the orbital roof and observed a mean duration of effect of 10 weeks.

#### **Complications and Side Effects**

When used appropriately, treatment is generally safe and well tolerated by patients. As the effects of BoNT-A generally begin to fade within 12 weeks, the duration of its side effects is limited.<sup>97</sup> These self-limiting side effects, which are especially common with repeated injections and occur in about 3%, include headache, edema, bruising, mild pain related to the injection and flu-like symptoms.<sup>98,99</sup> Side effects like bruising and hemorrhage can be minimized by discontinuing patients' use of anticoagulants (aspirin, vitamin E, nonsteroid antiinflammatory drugs) two weeks prior to injection. In addition, the treated area should not be massaged for up to two hours after injection in order to accelerate the absorption of the injected BoNT and reduce its spread to surrounding tissues. Patients should be warned of these issues.<sup>24</sup>

Blepharoptosis may occur during treatment of glabellar lines or periorbital wrinkles. Carruthers et al.<sup>100</sup> observed the condition in 5.4% of their cases. It has been recommended to increase the concentration and reduce the volume of BoNT-A injections

to prevent unwanted diffusion to other muscles.<sup>4</sup> Ptosis is one of the common complications. This arises due to diffusion or accidental injection of the toxin into the orbital septum. Ptosis occurs in an average of 13% of cases.<sup>101</sup> In cases of ptosis severe enough to interfere with vision, the use of 0.5% apraclonidine ophthalmic drops to enhance Müller muscle function may be beneficial the levator muscle function returns. According to a meta-analysis of 1003 patients, the most common complication was ptosis (3.4%), followed by dry eye (2.3%), headache (1.6%) and eyebrow ptosis (0.6%).<sup>102</sup> Eyelid ptosis often occurs due to impairment of the levator muscle after injection to the glabellar lines invades the orbital septum. Ptosis emerges as early as 48 hours and up to 2 weeks after injection and can last from 2 to 12 weeks. To avoid eyelid ptosis due to intraorbital diffusion, a high-concentration, low-volume BoNT injection is applied 1 cm from the edge of the orbital bone or more than 1.5 cm laterally from the lateral canthus.<sup>103</sup> Diplopia is a rare complication which usually occurs due to paralysis of the inferior oblique muscle. Dry eye and epiphora are other common complications of BoNT administration. Blurred vision resulting from corneal exposure may occur due to disruption of the eye-closure reflex. There have been rare reports of acute angle closure glaucoma<sup>104,105</sup> and retinal tearing due to globe penetration<sup>106</sup> associated with BoNT injection. To date, reported side effects include pain during injection, local edema, erythema, ecchymosis, alternate muscle weakness, flu-like symptoms and high cost. Between 1989 and 2003, nearly all of the serious complications related to BoNT injection reported to the FDA were a result of therapeutic applications using higher dosages (ratio of therapeutic:cosmetic purposes was 33:1). Of 253 cases with serious complications, 28 deaths were reported, none of which were related to the application of BoNT for cosmetic purposes.<sup>107</sup>

The proteins included in the preparations may cause antibody reaction against BoNT injections. The BoNT agent currently in use (since 1998) has a low protein load and therefore rarely induces an allergic reaction. However, an allergic reaction can occur due to the therapeutic use of high-dose BoNT. Of 1437 BoNT-related adverse events reported to the FDA, nonserious allergic rash occurred in 17 cases of therapeutic use and 29 cases of cosmetic use, while serious allergic reaction/rash occurred in 11 therapeutic users and 2 cosmetic users.<sup>107</sup> Decreasing the dose of BoNT and increasing the intervals between injections can reduce the risk of antibody production. In regards to malpractice, there have been reports to the FDA of side effects due to toxin spreading to surrounding tissues after BoNT injection for cosmetic purposes, but no permanent serious side effects have been reported.<sup>107</sup>

#### Contraindications

BoNT should not be used by pregnant (category C) and breastfeeding mothers (it is not known whether BoNT passes to breast milk); children under 12 years old; individuals with extreme sensitivity to any components of the preparation; or patients with coagulopathies or neuromuscular disease (myasthenia gravis, Lambert-Eaton syndrome, multiple sclerosis, etc.).<sup>24,108</sup>

The skin should not be cleaned with alcohol. Because they reduce the release of acetylcholine, the effect of the toxin is increased by aminoglycosides, cyclosporine, D-penicillamine, quinidine, succinylcholine, magnesium sulfate and lincosamides, whereas aminoquinolones reduce its effect by blocking its cellular uptake.<sup>24,108</sup> Therefore, a detailed medical history must be taken prior to the application of BoNT.

#### Conclusion

The average lifespan is longer than ever before, and the chemical denervation agent BoNT is remarkably effective in reducing the signs of aging around the eyes and face. In addition to its use in oculoplasty, BoNT has various uses in ophthalmology for eyelid and lacrimal system disorders. Furthermore, BoNT has taken its place in medicine as a powerful chemical alternative to strabismus surgery which, especially in pediatric esotropia and most types of paralytic strabismus, can be as effective as surgery without altering the muscular anatomy.

#### Ethics

Peer-review: Externally peer-reviewed.

#### Authorship Contributions

Surgical and Medical Practices: Emel Başar, Concept: Ceyhun Arıcı, Emel Başar, Design: Ceyhun Arıcı, Emel Başar, Data Collection or Processing: Ceyhun Arıcı, Emel Başar, Analysis or Interpretation: Ceyhun Arıcı, Emel Başar, Literature Search: Ceyhun Arıcı, Writing: Ceyhun Arıcı.

Conflict of Interest: No conflict of interest was declared by the authors.

Financial Disclosure: The authors declared that this study received no financial support.

#### References

1. Dhaked RK, Singh MK, Singh P, Gupta P. Botulinum toxin: bioweapon & magic drug. *Indian J Med Res.* 2010;132:489-503.
2. Scott AB, Rosenbaum A, Collins CC. Pharmacologic weakening of extraocular muscles. *Invest Ophthalmol.* 1973;12:924-927.
3. Scott AB. Botulinum toxin injection into extraocular muscles as an alternative to strabismus surgery. *J Pediatr Ophthalmol Strabismus.* 1980;17:21-25.
4. Dutton JJ, Fowler AM. Botulinum toxin in ophthalmology. *Surv Ophthalmol.* 2007;52:13-31.
5. Goodman G. Botulinum toxin for the correction of hyperkinetic facial lines. *Australas J Dermatol.* 1998;39:158-163.
6. Benedetto AV. The cosmetic uses of Botulinum toxin type A. *Int J Dermatol.* 1999;38:641-655.
7. Carruthers A, Kiene K, Carruthers J. Botulinum A exotoxin use in clinical dermatology. *J Am Acad Dermatol.* 1996;34:788-797.
8. de Maio M. Therapeutic uses of botulinum toxin: from facial palsy to autonomic disorders. *Expert Opin Biol Ther.* 2008;8:791-798.
9. Dowell VR, Jr. Botulism and tetanus: selected epidemiologic and microbiologic aspects. *Rev Infect Dis.* 1984;6(Suppl 1):202-207.
10. Walker TJ, Dayan SH. Comparison and overview of currently available neurotoxins. *J Clin Aesthet Dermatol.* 2014;7:31-39.
11. Erickson BP, Lee WW, Cohen J, Grunebaum LD. The role of neurotoxins in the periorbital and midfacial areas. *Facial Plast Surg Clin North Am.* 2015;23:243-255.



12. Kane M, Donofrio L, Ascher B, Hexsel D, Monheit G, Rzany B, Weiss R. Expanding the use of neurotoxins in facial aesthetics: a consensus panel's assessment and recommendations. *J Drugs Dermatol.* 2010;9:7-22.
13. Trindade De Almeida AR, Secco LC, Carruthers A. Handling botulinum toxins: an updated literature review. *Dermatol Surg.* 2011;37:1553-1565.
14. Bentivoglio AR, Fasano A, Ialongo T, Soleti F, Lo Fermo S, Albanese A. Fifteen-year experience in treating blepharospasm with Botox or Dysport: same toxin, two drugs. *Neurotox Res.* 2009;15:224-231.
15. Yang GC, Chiu RJ, Gillman GS. Questioning the need to use Botox within 4 hours of reconstitution: a study of fresh vs 2-week-old Botox. *Arch Facial Plast Surg.* 2008;10:273-279.
16. Hexsel D, Rutowitsch MS, de Castro LC, do Prado DZ, Lima MM. Blind multicenter study of the efficacy and safety of injections of a commercial preparation of botulinum toxin type A reconstituted up to 15 days before injection. *Dermatol Surg.* 2009;35:933-939.
17. Alam M, Yoo SS, Wrone DA, White LE, Kim JY. Sterility assessment of multiple use botulinum A exotoxin vials: a prospective simulation. *J Am Acad Dermatol.* 2006;55:272-275.
18. Stephan S, Wang TD. Botulinum toxin: clinical techniques, applications, and complications. *Facial Plast Surg.* 2011;27:529-539.
19. Guerrissi JO. Intraoperative injection of botulinum toxin A into the orbicularis oculi muscle for the treatment of crow's feet. *Plast Reconstr Surg.* 2003;112:161-163.
20. Kane MA. Classification of crow's feet patterns among Caucasian women: the key to individualizing treatment. *Plast Reconstr Surg.* 2003;112:33-39.
21. Fagien S. Botulinum toxin type A for facial aesthetic enhancement: role in facial shaping. *Plast Reconstr Surg.* 2003;112:6-18.
22. Park MY, Ahn KY. Botulinum toxin a for the treatment of hyperkinetic wrinkle lines. *Plast Reconstr Surg.* 2003;112:148-150.
23. Carruthers J, Carruthers A. Aesthetic botulinum A toxin in the mid and lower face and neck. *Dermatol Surg.* 2003;29:468-476.
24. Klein AW. Complications and adverse reactions with the use of botulinum toxin. *Semin Cutan Med Surg.* 2001;20:109-120.
25. Fagien S. Botox for the treatment of dynamic and hyperkinetic facial lines and furrows: adjunctive use in facial aesthetic surgery. *Plast Reconstr Surg.* 1999;103:701-713.
26. Carruthers JD, Lowe NJ, Menter MA, Gibson J, Eadie N, Botox Glabellar Lines IISG. Double-blind, placebo-controlled study of the safety and efficacy of botulinum toxin type A for patients with glabellar lines. *Plast Reconstr Surg.* 2003;112:1089-1098.
27. Carruthers JA, Lowe NJ, Menter MA, Gibson J, Nordquist M, Mordaunt J, Walker P, Eadie N, Group BGLIS. A multicenter, double-blind, randomized, placebo-controlled study of the efficacy and safety of botulinum toxin type A in the treatment of glabellar lines. *J Am Acad Dermatol.* 2002;46:840-849.
28. Monheit G, Carruthers A, Brandt F, Rand R. A randomized, double-blind, placebo-controlled study of botulinum toxin type A for the treatment of glabellar lines: determination of optimal dose. *Dermatol Surg.* 2007;33:51-59.
29. Kane MA, Brandt F, Rohrich RJ, Narins RS, Monheit GD, Huber MB, Reloxin Investigational G. Evaluation of variable-dose treatment with a new U.S. Botulinum Toxin Type A (Dysport) for correction of moderate to severe glabellar lines: results from a phase III, randomized, double-blind, placebo-controlled study. *Plast Reconstr Surg.* 2009;124:1619-1629.
30. Rzany B, Dill-Muller D, Grablowitz D, Heckmann M, Caird D, German-Austrian Retrospective Study G. Repeated botulinum toxin A injections for the treatment of lines in the upper face: a retrospective study of 4,103 treatments in 945 patients. *Dermatol Surg.* 2007;33:18-25.
31. Carruthers A, Carruthers J. Prospective, double-blind, randomized, parallel-group, dose-ranging study of botulinum toxin type A in men with glabellar rhytids. *Dermatol Surg.* 2005;31:1297-1303.
32. Maas CS, Kim EJ. Temporal brow lift using botulinum toxin A: an update. *Plast Reconstr Surg.* 2003;112:109-112.
33. Ahn MS, Catten M, Maas CS. Temporal brow lift using botulinum toxin A. *Plast Reconstr Surg.* 2000;105:1129-1135.
34. Uygun S, Eryilmaz T, Bulam H, Yavuzer R, Latifoglu O. The quantitative effect of botulinum toxin A over brow height. *J Craniofac Surg.* 2013;24:1285-1287.
35. Blitzer A, Brin MF, Keen MS, Aviv JE. Botulinum toxin for the treatment of hyperfunctional lines of the face. *Arch Otolaryngol Head Neck Surg.* 1993;119:1018-1022.
36. Terzioğlu A, Tuncalı D, Barutçu AY, Başer NT, Aslan G. Botulinum toxin A: Cosmetic Use and literature review. *Türk Plast Rekonstr ve Est Cer Derg.* 2005;13:185-190.
37. Lowe NJ, Ascher B, Heckmann M, Kumar C, Fraczek S, Eadie N, Botox Facial Aesthetics Study T. Double-blind, randomized, placebo-controlled, dose-response study of the safety and efficacy of botulinum toxin type A in subjects with crow's feet. *Dermatol Surg.* 2005;31:257-262.
38. Ascher B, Rzany BJ, Grover R. Efficacy and safety of botulinum toxin type A in the treatment of lateral crow's feet: double-blind, placebo-controlled, dose-ranging study. *Dermatol Surg.* 2009;35:1478-1486.
39. Prager W, Wissmuller E, Kollhorst B, Boer A, Zschocke I. [Treatment of crow's feet with two different botulinum toxin type A preparations in split-face technique]. *Hautarzt.* 2011;62:375-379.
40. Matarasso SL, Matarasso A. Treatment guidelines for botulinum toxin type A for the periocular region and a report on partial upper lip ptosis following injections to the lateral canthal rhytids. *Plast Reconstr Surg.* 2001;108:208-214.
41. Crouch ER. Use of botulinum toxin in strabismus. *Curr Opin Ophthalmol.* 2006;17:435-440.
42. Benabent EC, Garcia Hermosa P, Arrazola MT, Alio y Sanz JL. Botulinum toxin injection without electromyographic assistance. *J Pediatr Ophthalmol Strabismus.* 2002;39:231-234.
43. Flanders M, Tischler A, Wise J, Williams F, Beneish R, Auger N. Injection of type A botulinum toxin into extraocular muscles for correction of strabismus. *Can J Ophthalmol.* 1987;22:212-217.
44. Lennerstrand G, Nordbo OA, Tian S, Eriksson-Derouet B, Ali T. Treatment of strabismus and nystagmus with botulinum toxin type A. An evaluation of effects and complications. *Acta Ophthalmol Scand.* 1998;76:27-27.
45. Petitto VB, Buckley EG. Use of botulinum toxin in strabismus after retinal detachment surgery. *Ophthalmology.* 1991;98:509-512.
46. Gursoy H, Basmak H, Sahin A, Yildirim N, Aydin Y, Colak E. Long-term follow-up of bilateral botulinum toxin injections versus bilateral recessions of the medial rectus muscles for treatment of infantile esotropia. *J AAPOS.* 2012;16:269-273.
47. McNeer KW, Tucker MG, Guerry CH, Spencer RE. Incidence of stereopsis after treatment of infantile esotropia with botulinum toxin A. *J Pediatr Ophthalmol Strabismus.* 2003;40:288-292.
48. Başar E. [Esotropia]. [Eye diseases in children]. İstanbul: Martı Ofset 2009:177-182.
49. Tengtrisorn S, Treyapun N, Tantisarasart T. Botulinum A toxin therapy on esotropia in children. *J Med Assoc Thai.* 2002;85:1189-1197.
50. Ruiz MF, Moreno M, Sanchez-Garrido CM, Rodriguez JM. Botulinum treatment of infantile esotropia with abduction nystagmus. *J Pediatr Ophthalmol Strabismus.* 2000;37:196-205.

51. Campos EC, Schiavi C, Bellusci C. Critical age of botulinum toxin treatment in essential infantile esotropia. *J Pediatr Ophthalmol Strabismus*. 2000;37:328-332.
52. Metz HS, Dickey CF. Treatment of unilateral acute sixth-nerve palsy with botulinum toxin. *Am J Ophthalmol*. 1991;112:381-384.
53. Yabaş Ö, Ziyilan Ş, Zorlutuna N, Doruğa İ. Botulinum toxin in acute sixth nerve palsy. *Turk J Ophthalmol*. 2006;36:276-280.
54. Başar E, Oğuz H, Akova N, Özkan N, Mirzazaş Ç. Comparison of Jensen's procedure combined with recession of antagonist medial rectus muscle or botulinum toxin injection into antagonist medial rectus muscle: Outcome in a patient with bilateral sixth nerve palsy. *Ann Med Sci* 2005;14:8-11.
55. İncili B, Önal S, Demirtaş S, Ögüt MS. Botulinum toxin chemodeneration combined with transposition surgery for chronic sixth nerve palsy: A presentation of three cases. *Turk J Ophthalmol*. 2006;36:321-325.
56. Sener EC, Sanac AS. Efficacy and complications of dose increments of botulinum toxin-A in the treatment of horizontal comitant strabismus. *Eye (Lond)*. 2000;14:873-878.
57. Han SH, Lew H, Jeong CW, Lee JB. Effect of botulinum toxin A chemodeneration in sensory strabismus. *J Pediatr Ophthalmol Strabismus*. 2001;38:68-71.
58. Dawson EL, Marshman WE, Lee JP. Role of botulinum toxin A in surgically overcorrected exotropia. *J AAPOS*. 1999;3:269-271.
59. Ozkan SB, Kir E, Dayanir V, Dundar SO. Botulinum toxin A in the treatment of adherence syndrome. *Ophthalmic Surg Lasers Imaging*. 2003;34:391-395.
60. Wu X, Lin N, Ai LK, Wang JH, Yan LJ. [The application of botulinum toxin A in the treatment of restrictive strabismus in thyroid associated ophthalmopathy]. *Zhonghua Yan Ke Za Zhi*. 2006;42:1063-1067.
61. Tomsak RL, Remler BF, Averbuch-Heller L, Chandran M, Leigh RJ. Unsatisfactory treatment of acquired nystagmus with retrobulbar injection of botulinum toxin. *Am J Ophthalmol*. 1995;119:489-496.
62. Carruthers J. The treatment of congenital nystagmus with Botox. *J Pediatr Ophthalmol Strabismus*. 1995;32:306-308.
63. Başar E, Pazarlı H, Kayıran A. Chemical denervation for the treatment of functional blindness due to essential blepharospasm. *Cerrahpaşa J Med* 2003;34:24-27.
64. Grandas F, Elston J, Quinn N, Marsden CD. Blepharospasm: a review of 264 patients. *J Neurol Neurosurg Psychiatry*. 1988;51:767-772.
65. Lee MS, Johnson M, Harrison AR. Gender differences in benign essential blepharospasm. *Ophthalm Plast Reconstr Surg*. 2012;28:169-170.
66. Dutton JJ. Botulinum-A toxin in the treatment of craniocervical muscle spasms: short- and long-term, local and systemic effects. *Surv Ophthalmol*. 1996;41:51-65.
67. Dutton JJ, Buckley EG. Long-term results and complications of botulinum A toxin in the treatment of blepharospasm. *Ophthalmology*. 1988;95:1529-1534.
68. Cakmur R, Ozturk V, Uzunel F, Donmez B, Idiman E. Comparison of preseptal and pretarsal injections of botulinum toxin in the treatment of blepharospasm and hemifacial spasm. *J Neurol*. 2002;249:64-68.
69. Streitova H, Bares M. Long-term therapy of benign essential blepharospasm and facial hemispasm with botulinum toxin A: retrospective assessment of the clinical and quality of life impact in patients treated for more than 15 years. *Acta Neurol Belg*. 2014;114:285-291.
70. Cysz CN, Burns JA, Petrie TP, Watkins JR, Cahill KV, Foster JA. Long-term botulinum toxin treatment of benign essential blepharospasm, hemifacial spasm, and Meige syndrome. *Am J Ophthalmol*. 2013;156:173-177.
71. Ababneh OH, Cetinkaya A, Kulwin DR. Long-term efficacy and safety of botulinum toxin A injections to treat blepharospasm and hemifacial spasm. *Clin Exp Ophthalmol*. 2014;42:254-261.
72. Aydın P, Çakmakçı Ş. Treatment of blepharospasm and hemifacial spasm with botulinum- a toxin. *Türkiye Klinikleri J Ophthalmol*. 2000;9:122-126.
73. Yüksel D. The Use of Botulinum Toxin in the Treatment of Blepharospasm and Hemifacial Spasm: Review. *Turkiye Klinikleri J Ophthalmol*. 2009;18:256-263.
74. Vogt T, Lussi F, Paul A, Urban P. [Long-term therapy of focal dystonia and facial hemispasm with botulinum toxin A]. *Nervenarzt*. 2008;79:912-917.
75. Gonnering RS. Treatment of hemifacial spasm with botulinum A toxin. Results and rationale. *Ophthalm Plast Reconstr Surg*. 1986;2:143-146.
76. Çiftçi F, Karadayı K, Yıldız T, Akın T, Yıldırım Y, Gülecek O. Effectiveness of chemical denervation with botulinum toxin a in the treatment of blepharospasm and hemifacial spasm. *Turk J Ophthalmol*. 2005;35:84-92.
77. Yağcı A, Köse S, Kayıkçıoğlu Ö, Pamukçu K. Application of Botulinum toxin in patients with essential blepharospasm. *MN Oftalmoloji* 1998;5:138-140.
78. Dutton JJ, Buckley EG. Long-term results and complications of botulinum A toxin in the treatment of blepharospasm. *Ophthalmology*. 1988;95:1529-1534.
79. Wutthiphan S, Kowal L, O'Day J, Jones S, Price J. Diplopia following subcutaneous injections of botulinum A toxin for facial spasms. *J Pediatr Ophthalmol Strabismus*. 1997;34:229-234.
80. Price J, O'Day J. Efficacy and side effects of botulinum toxin treatment for blepharospasm and hemifacial spasm. *Aust N Z J Ophthalmol*. 1994;22:255-260.
81. Flanders M, Chin D, Boghen D. Botulinum toxin: preferred treatment for hemifacial spasm. *Eur Neurol*. 1993;33:316-319.
82. Jitpimolmard S, Tiangkao S, Laopaiboon M. Long term results of botulinum toxin type A (Dysport) in the treatment of hemifacial spasm: a report of 175 cases. *J Neurol Neurosurg Psychiatry*. 1998;64:751-757.
83. Bentivoglio AR, Fasano A, Ialongo T, Soleti F, Lo Fermo S, Albanese A. Outcome predictors, efficacy and safety of Botox and Dysport in the long-term treatment of hemifacial spasm. *Eur J Neurol*. 2009;16:392-398.
84. Van den Bergh P, Francart J, Mourin S, Kollmann P, Laterre EC. Five-year experience in the treatment of focal movement disorders with low-dose Dysport botulinum toxin. *Muscle Nerve*. 1995;18:720-729.
85. Gill HS, Kraft SP. Long-term efficacy of botulinum toxin for blepharospasm and hemifacial spasm. *Can J Neurol Sci*. 2010;37:631-636.
86. Akdemir MO, Uğurbaş CS, Uğurbaş SH. Long-term effect of botulinum toxin in the treatment of benign essential blepharospasm and hemifacial spasm. *Turk J Ophthalmol* 2015;45:1-4.
87. Morgenstern KE, Evanchan J, Foster JA, Cahill KV, Burns JA, Holck DE, Perry JD, Wulc AE. Botulinum toxin type a for dysthyroid upper eyelid retraction. *Ophthalm Plast Reconstr Surg*. 2004;20:181-185.
88. Hekimhan PK. Botulinum toxin applications in periocular pathologies. *Türkiye Klinikleri J Surg Med Sci* 2007;3:56-61.
89. Kaynak P, Karabalut ÖG, Öztürker C, Yıldırım Y, Alagöz N, Akar S, Göküçit B, Demirok A. Upper eyelid retraction management with subconjunctival injection of botulinum toxin type a in patients with thyroid eye disease. *MN Oftalmoloji* 2013;20:272-278.
90. Salour H, Bagheri B, Aletaha M, Babsharif B, Kleshadi M, Abrishami M, Bagheri A. Transcutaneous dysport injection for treatment of upper eyelid retraction associated with thyroid eye disease. *Orbit*. 2010;29:114-118.
91. Deka A, Saikia SP. Botulinum toxin for lower lid entropion correction. *Orbit*. 2011;30:40-42.
92. Baranano DE, Miller NR. Long term efficacy and safety of botulinum toxin A injection for crocodile tears syndrome. *Br J Ophthalmol*. 2004;88:588-589.

93. Nava-Castaneda A, Tovilla-Canales JL, Boulosa V, Tovilla-y-Pomar JL, Monroy-Serrano MH, Tapia-Guerra V, Garfias Y. Duration of botulinum toxin effect in the treatment of crocodile tears. *Ophthal Plast Reconstr Surg*. 2006;22:453-456.
94. Wabbels B, Forl M. [Botulinum toxin treatment for crocodile tears, spastic entropion and for dysthyroid upper eyelid retraction]. *Ophthalmologe*. 2007;104:771-776.
95. Naik MN, Gangopadhyay N, Fernandes M, Murthy R, Honavar SG. Anterior chemodervation of levator palpebrae superioris with botulinum toxin type-A (Botox) to induce temporary ptosis for corneal protection. *Eye (Lond)*. 2008;22:1132-1136.
96. Yucel OE, Arturk N. Botulinum toxin-A-induced protective ptosis in the treatment of lagophthalmos associated with facial paralysis. *Ophthal Plast Reconstr Surg*. 2012;28:256-260.
97. Tsui JK. Botulinum toxin as a therapeutic agent. *Pharmacol Ther*. 1996;72:13-24.
98. Monheit G, Carruthers A, Brandt F, Rand R. A randomized, double-blind, placebo-controlled study of botulinum toxin type A for the treatment of glabellar lines: determination of optimal dose. *Dermatol Surg*. 2007;33:51-59.
99. Kane MA, Brandt F, Rohrich RJ, Narins RS, Monheit GD, Huber MB, Reloxin Investigational G. Evaluation of variable-dose treatment with a new U.S. Botulinum Toxin Type A (Dysport) for correction of moderate to severe glabellar lines: results from a phase III, randomized, double-blind, placebo-controlled study. *Plast Reconstr Surg*. 2009;124:1619-1629.
100. Carruthers JA, Lowe NJ, Menter MA, Gibson J, Nordquist M, Mordaunt J, Walker P, Eadie N, Group BGLIS. A multicenter, double-blind, randomized, placebo-controlled study of the efficacy and safety of botulinum toxin type A in the treatment of glabellar lines. *J Am Acad Dermatol*. 2002;46:840-849.
101. Dutton JJ. Botulinum-A toxin in the treatment of craniocervical muscle spasms: short- and long-term, local and systemic effects. *Surv Ophthalmol*. 1996;41:51-65.
102. Ricci LH, Navajas SV, Carneiro PR, Soderberg SA, Ferraz CA. Ocular adverse effects after facial cosmetic procedures: a review of case reports. *J Cosmet Dermatol*. 2015;14:145-151.
103. Carruthers J, Carruthers A. Complications of botulinum toxin type A. *Facial Plast Surg Clin North Am*. 2007;15:51-54.
104. Zheng L, Azar D. Angle-closure glaucoma following periorbital botulinum toxin injection. *Clin Experiment Ophthalmol* 2014;42:690-693.
105. Corridan P, Nightingale S, Mashoudi N, Williams AC. Acute angle-closure glaucoma following botulinum toxin injection for blepharospasm. *Br J Ophthalmol*. 1990;74:309-310.
106. Liu M, Lee HC, Hertle RW, Ho AC. Retinal detachment from inadvertent intraocular injection of botulinum toxin A. *Am J Ophthalmol*. 2004;137:201-202.
107. Cote TR, Mohan AK, Polder JA, Walton MK, Braun MM. Botulinum toxin type A injections: adverse events reported to the US Food and Drug Administration in therapeutic and cosmetic cases. *J Am Acad Dermatol*. 2005;53:407-415.
108. Rohrich RJ, Janis JE, Fagien S, Stuzin JM. The cosmetic use of botulinum toxin. *Plast Reconstr Surg*. 2003;112:177-188.



# Isolated Schwannoma of the Upper Eyelid Margin in a 50-year-old Male

Mehmet Serdar Dervişoğulları\*, Yüksel Totan\*\*, Ümran Yıldırım\*\*\*

\*Medicana Konya Hospital, Ophthalmology Clinic, Konya, Turkey

\*\*Maya Eye Disease Center, Ankara, Turkey

\*\*\*Düzce University Training and Research Hospital, Pathology Clinic, Düzce, Turkey

## Summary

Schwannomas (neurilemmomas) are benign neurogenic tumours of peripheral nerves. They originate from Schwann cells, which form the neural sheath. Although Schwannomas and neurofibromas are the most common primary peripheral nerve tumours, Schwannomas are rarely observed in ophthalmic areas. When they occur, ocular Schwannomas are usually located in the orbit, uveal tract and conjunctiva. Isolated eyelid Schwannomas are reported infrequently. Herein, we describe a case of eyelid Schwannoma in a 50-year-old man. The diagnosis of Schwannoma was made after the eyelid mass was removed by excisional biopsy, so this entity should be included in the differential diagnosis of eyelid margin tumours.

**Keywords:** Eyelid margin, histopathology, Schwannoma

## Introduction

Schwannomas (neurilemmomas) are benign tumours derived from the Schwann cells of the peripheral nerve sheath. The tumour is a solitary mass that can be located in soft tissues throughout the body. It has a smooth surface and grows slowly. It is mostly asymptomatic and may occur at any age or gender in the general population. Multiple neurofibromas are a distinctive feature of neurofibromatosis (NF) type 1 and bilateral acoustic Schwannomas are a feature of NF type 2. Because of their tendency to occur in spinal nerve roots, sympathetic nerves, cervical nerves and vagus nerves, Schwannomas are mostly seen in the head and neck.<sup>1</sup> They occasionally arise in the orbit and infrequently in the conjunctiva<sup>1</sup>, uveal tract<sup>2</sup> and sclera.<sup>3</sup> Eyelid Schwannomas, especially at the eyelid margin, are uncommon; only 2 cases in adults have been reported to date.

## Case Report

A 50-year-old man was referred to us with a history of a painless nodule that had enlarged slowly on his right upper eyelid for 2 years. He had no history of NF or any other nodules.

Ocular examination was normal but there was a firm, non-tender nodule measuring 3x4x4 mm in the lateral side of the right upper eyelid margin. Clinical findings of NF were not observed. The lesion was thought to be a papilloma and was completely removed by shave excision under local anesthesia.

Pathological studies showed a mass approximately 3 mm in diameter on macroscopic examination. On microscopic examination, histopathologic bundles of spindle cells with no mitotic activity (Figure 1a) were observed. No histopathologic features of malignancy were present. Immunohistochemical analysis revealed a strong positive reaction for S100 protein (Figure 1b). Tumour cells did not react with spinal musculoskeletal atrophy, Desmin or CD34. The final diagnosis was benign Schwannoma of the eyelid margin.

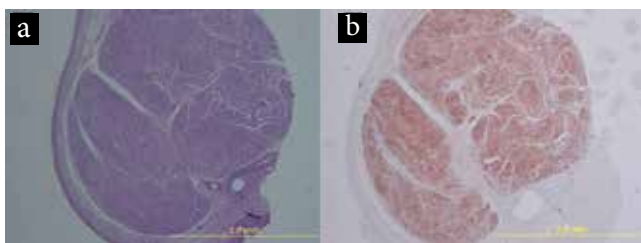
The patient was asymptomatic and there were no symptoms or signs of recurrence one year later (Figure 2).

## Discussion

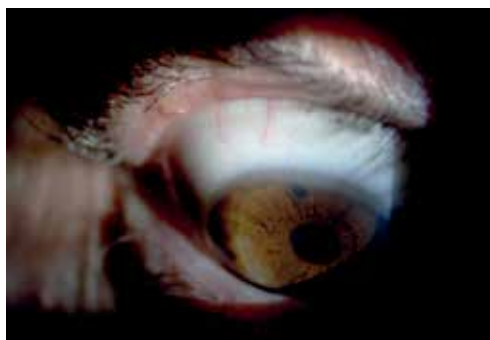Proliferating Schwann cells of peripheral nerve sheaths form Schwannoma (or neurilemmoma). It is a rare, slow-growing, benign, asymptomatic neoplasm and may occur in

**Address for Correspondence:** Mehmet Serdar Dervişoğulları MD, Medicana Konya Hospital, Ophthalmology Clinic, Konya, Turkey  
E-mail: serdarderv@hotmail.com **Received:** 15.01.2015 **Accepted:** 30.03.2015

©Copyright 2016 by Turkish Ophthalmological Association  
Turkish Journal of Ophthalmology, Published by Galenos Publishing House



**Figure 1.** Histologic analysis of an eyelid margin Schwannoma from a 50-year-old male, spindle cells arranged in a palisading fashion in an Antoni A area (Hematoxylin-eosin, x40) (a) S100 positivity in spindle cells (x40) (b)



**Figure 2.** No recurrence was observed 1 year after excision of eyelid margin Schwannoma

any myelinated peripheral or cranial nerve. They occasionally arise in the orbit and infrequently in the conjunctiva<sup>1</sup>, uveal tract<sup>2</sup> and sclera.<sup>3</sup> The reported origins for orbital Schwannomas are oculomotor, ciliary and supraorbital nerves. Eyelid Schwannomas are presumed to originate from supraorbital, supratrochlear and infraorbital nerves. Schwannomas typically manifest as a single benign neoplasm. Multiple Schwannomas in one patient is usually indicative of NF. In Schwannomatosis (neurilemmomatosis), multiple non-vestibular Schwannomas are observed with no other stigmata of NF type 1 or NF type 2.<sup>4</sup> Clinico-pathologic variants of Schwannoma include conventional Schwannoma, cellular Schwannoma, and melanotic Schwannoma.<sup>5</sup> Microscopically, they may demonstrate a biphasic pattern, and areas of highly cellular (Antoni type A) and myxoid matrix (Antoni type B) may be observed.<sup>5</sup> Degenerative changes may occur in time.<sup>6</sup> Prognosis is poor if the cells are fusiform, contain melanin granules, or if epithelioid cells are present.<sup>7</sup> Nevertheless, malignant transformation has not been reported in eyelid Schwannomas and total excision seems to be curative. The most important feature for diagnosis of a Schwannoma is still its strong reactivity to S100 protein in immunohistochemistry.<sup>1,2,3,4,5,6,7</sup>

Schwannoma of the eyelid margin in adults was first reported in 2007 by Lopez-Tizon et al.<sup>8</sup> The second report was in 2012, by Cheng et al.<sup>9</sup> The first reported case of an eyelid margin Schwannoma was a slowly enlarging 0.4 cm nodule, thought to be an inclusion cyst on the right upper eyelid margin for 1 year, which did not recur for 12 years after pentagonal full-thickness excision. The second report was a 35-year-old man who presented with a translucent, painless, cyst-like nodule with a smooth surface located on the right lower eyelid margin, resembling hydrocystoma and treated by shave excision.

Our patient had isolated eyelid Schwannoma with no family history or clinical findings of NF. The mass was located on the lateral half of the eyelid margin and the tumor probably arose from branches of the supraorbital nerve. Schwannomas are rare tumours that can occur in unusual locations, including the eyelid margin, and should be considered in the differential diagnosis of the eyelid margin tumours. Complete surgical excision is necessary to avoid recurrence. Incomplete removal is associated with eventual recurrence and more aggressive behavior.<sup>5,6</sup> The lesion was thought to be a papilloma and shave biopsy was performed. Because histologic diagnosis was Schwannoma, the patient was planned to be followed up closely for any sign of recurrence. There was no recurrence in 3-months follow-up. Malignant transformation has not been reported with eyelid margin Schwannomas.

Schwannomas of ophthalmic interest are rare but may mimic inclusion cysts or chalazia.<sup>8,10,11</sup> They are extremely uncommon at the eyelid margin but should be considered in the differential diagnosis of any solid eyelid margin lesion.

#### Ethics

Informed Consent: It was taken.

Peer-review: Externally peer-reviewed.

#### Authorship Contributions

Surgical and Medical Practices: Mehmet Serdar Dervişoğulları, Yüksel Totan, Ümran Yıldırım, Concept: Mehmet Serdar Dervişoğulları, Yüksel Totan, Ümran Yıldırım, Design: Mehmet Serdar Dervişoğulları, Yüksel Totan, Ümran Yıldırım, Data Collection or Processing: Mehmet Serdar Dervişoğulları, Yüksel Totan, Ümran Yıldırım, Analysis or Interpretation: Mehmet Serdar Dervişoğulları, Yüksel Totan, Ümran Yıldırım, Literature Search: Mehmet Serdar Dervişoğulları, Yüksel Totan, Ümran Yıldırım, Writing: Mehmet Serdar Dervişoğulları, Yüksel Totan, Ümran Yıldırım.

Conflict of Interest: No conflict of interest was declared by the authors.

Financial Disclosure: The authors declared that this study received no financial support.

#### References

1. Le Marc'hadour F, Romanet JP, Fdili A, Peoc'h M, Pinel N. Schwannoma of the bulbar conjunctiva. *Arch Ophthalmol.* 1996;114:1258-1260.
2. Shields JA, Font RL, Eagle RC Jr, Shields CL, Gass JD. Melanotic schwannoma of the choroid. Immunohistochemistry and electron microscopic observations. *Ophthalmology.* 1994;101:843-849.
3. Graham CW, Cartney ACE, Buckley RJ. Intracranial neurilemmoma. *Br J Ophthalmol.* 1989;73:378-381.
4. Kim DH, Hwang JH, Park ST, Shin JH. Schwannomatosis involving peripheral nerves: a case report. *J Korean Med Sci.* 2006;21:1136-1138.
5. Scheithauer BW, Woodruff JM, Erlanson RA. Tumors of the peripheral nervous system. Washington. 1999:105-176.
6. Dahl I. Ancient neurilemmoma (schwannoma). *Acta Pathol Microbiol Scand A.* 1977;85:812-818.
7. Butt Z, Ironside JW. Superficial epithelioid schwannoma presenting as a subcutaneous upper eyelid mass. *Br J Ophthalmol.* 1994;78:586-588.
8. Lopez-Tizon E, Mencia-Gutierrez E, Gutierrez-Diaz E, Ricoy JR. Schwannoma of the eyelid: report of two cases. *Dermatol Online J.* 2007;13:12.
9. Cheng KH, Karres J, Kros JM, Kijlstra A, van Dekken H. Cyst-like schwannoma on the eyelid margin. *J Craniofac Surg.* 2012;23:1215-1216.
10. Shields JA, Guibor P. Neurilemmoma of the eyelid resembling a recurrent chalazion. *Arch Ophthalmol.* 1984;102:1650.
11. Patil SB, Kale SM, Jaiswal S, Khare N. Schwannoma of upper eyelid: A rare differential diagnosis of eyelid swellings. *Indian J Plast Surg.* 2010;43:213-215.



# Cataract Surgery after Retinal Detachment Surgery with Arruga's Sutures: Case Report

Erkan Ünsal\*, Kadir Eltutar\*, Osman Kızılay\*\*, Belma Karini\*

\*İstanbul Training and Research Hospital, Ophthalmology Clinic, İstanbul, Turkey

\*\*Zeynep Kamil Women's and Children's Hospital Training and Research Hospital, Ophthalmology Clinic, İstanbul, Turkey

## Summary

A 56-year old female patient presented to our clinic with a complaint of low vision in her right eye. Twenty-two years earlier she had undergone a scleral buckling operation in her right eye because of retinal detachment. She indicated that vision in her right eye was good after the surgery but had recently been gradually declining. Best-corrected vision acuity was counting fingers at 1 meter in the right eye and 8/10 in the left eye. Anterior segment examination revealed stage 3 nuclear cataract in the right eye. Examination of the right eye was blurred and revealed an area of chorioretinal atrophy posterior to the equator, approximately 3 disc diameters in the peripapillary zone and about 2 disc diameters in the nasal papilla zone. Anteriorly of the equator there was an area of chorioretinal atrophy as well as a narrow, sharply demarcated, shiny 360° suture with high buckling pressure, situated intraretinally but extending into the vitreous in some places. The structure was thought to be made of polyethylene. Around the suture there were retinal atrophic changes. After detailed explanation of the possible surgical complications and after obtaining informed consent, the right eye cataract was removed by phacoemulsification and a foldable intraocular lens was placed into the capsule. During the operation, we worked under low fluid pressure and as atraumatically as possible due to the possibility of intraocular pressure changes and the risk of the suture causing retinal and blood vessel tears or passing completely into the eye and causing intravitreal hemorrhage. A month after an uncomplicated surgery, the posterior segment examination demonstrated a reattached retina and the patient's best corrected visual acuity was 6/10.

**Keywords:** Retinal detachment, scleral buckling, Arruga's suture

## Introduction

Scleral buckling was commonly used in the past and is still utilized today in the treatment of retinal detachment. Although in recent years silicone-based structures have been used as encircling bands, Arruga sutures were also applied in the past.

In this report, we aimed to present a patient whose retinal detachment was treated with an encircling Arruga suture which years later caused intraocular invasion and cataract, necessitating cataract surgery.

## Case Report

A 56-year-old female patient presented to our clinic complaining of reduced vision in her right eye. She reported

undergoing a scleral buckling procedure 22 years earlier due to retinal detachment in her right eye. She stated that her vision had been good after the procedure but had severely decreased recently. On ophthalmologic examination her vision was counting fingers from 1 meter in the right eye and 20/25 in the left eye. Anterior segment examination revealed stage 3 nuclear cataract in the right eye and nuclear sclerosis in the left eye. Intraocular pressure was within normal limits in both eyes. Fundus examination was natural in the left eye, while in the right eye a blurred region of chorioretinal atrophy was observed posterior of the equator and extending approximately 3 disc diameters in the peripapillary area and 2 disc diameters nasal of the papilla (Figure 1). Anteriorly of the equator there were areas of chorioretinal atrophy as well as a narrow, sharply demarcated,

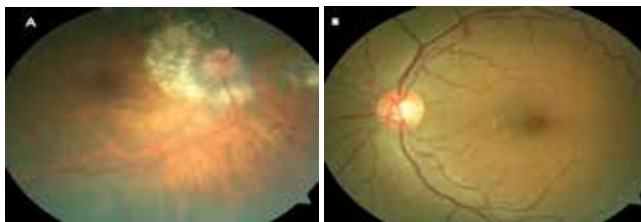**Address for Correspondence:** Erkan Ünsal MD, İstanbul Training and Research Hospital, Ophthalmology Clinic, İstanbul, Turkey

Phone: +90 505 238 22 50 E-mail: erkanunsal@gmail.com **Received:** 15.10.2014 **Accepted:** 15.02.2015

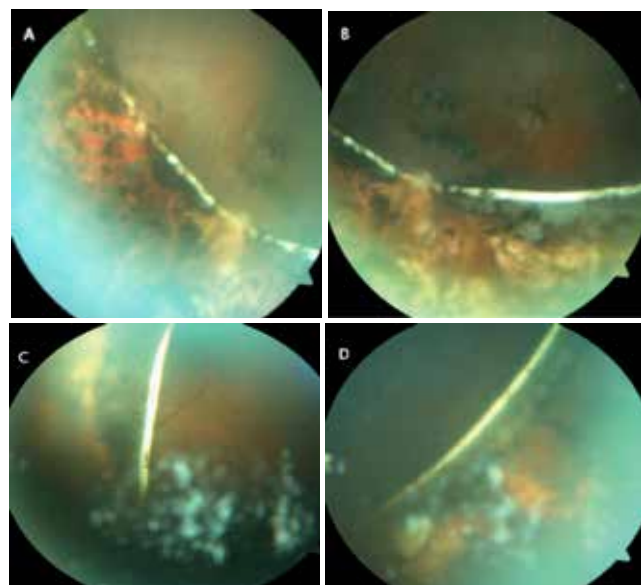
©Copyright 2016 by Turkish Ophthalmological Association  
Turkish Journal of Ophthalmology, Published by Galenos Publishing House

shiny 360° suture with high buckling pressure (Figure 2). The suture was situated intraretinally but extended into the vitreous in some places, and was suspected to be made of polyethylene. Retinal atrophic changes were present surrounding the suture. Ultrasonography revealed a hyperechogenic structure which was believed to originate from Arruga suture that had invaded the vitreous (Figure 3).

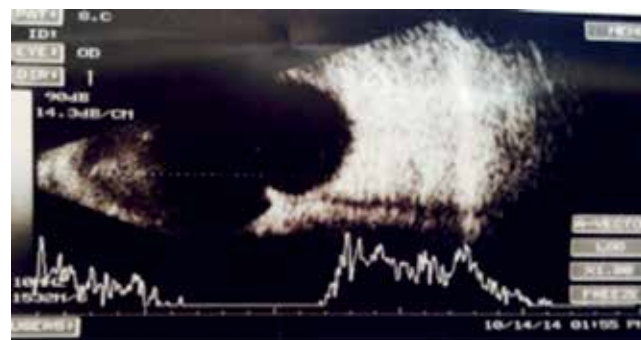
The patient was given detailed information regarding possible complications and informed consent was obtained. Biometry measurements were acquired using partial coherence



**Figure 1.** Posterior segment color photographs from the patient's right (A) and left (B) eyes



**Figure 2.** Appearance on fundus photography of the 360° suture, located anterior to the equator, mainly situated intraretinally but showing some intrusion into the vitreous, believed to be polyethylene, inferotemporal (A), inferior (B), temporal (C) and inferonasal (D) views



**Figure 3.** Ultrasonography of the inferotemporal quadrant showing hyperechogenic appearance of the Arruga suture invading the vitreous

interferometry [intraocular lens (IOL) Master 500, Carl Zeiss Meditec, Germany] and the Sanders-Retzlaff-Kraff theoretic formula.

Anticipating that the patient may undergo other ocular surgeries in the future and because a 3-piece IOL would be more stable in such an event, a 5.5 mm optic diameter, 3-piece hydrophobic acrylic IOL was implanted in the capsule.

During the operation, we worked under low fluid pressure and as atraumatically as possible due to the possibility of intraocular pressure changes and the risk of the suture causing retinal and vascular tears or passing completely into the eye and causing intravitreal hemorrhage.

At 1 month after the uncomplicated procedure, the retina was reattached and the patient's corrected visual acuity was 20/33. During the 3-month postoperative follow-up period, the IOL was centered in the capsule and the retina remained attached. The patient's visual acuity also remained stable.

## Discussion

All of the various techniques utilized in the management of retinal detachment aim to create an adhesion to prevent fluid exchange between the retinal pigment epithelium (RPE) and sensorial retina in the area surrounding the retinal tear, to thus enable RPE active transport and reabsorption of the subretinal fluid, to reduce the effects of vitreoretinal traction, and to prevent new tear formation.<sup>1,2,3,4</sup>

Schepens et al.<sup>5</sup> introduced the scleral buckling procedure for the treatment of retinal detachment. In the procedure, binocular indirect ophthalmoscopy and scleral buckle are used to localize retinal tears. Following lamellar scleral dissection, diathermy is applied to the area of the inner lamella corresponding to the retinal tear. A nonabsorbable, 1.25 mm-wide polyethylene tube is then fixed to the dissected area with a polyethylene/silk suture. After the subretinal fluid drains, the tube is tightened to provide sufficient pressure and the flap is closed over the tube. This lengthy procedure is usually performed under general anesthesia.

The Arruga technique is a dated surgical technique which has become obsolete in the treatment of retinal detachment. This technique, performed under local anesthesia, was used to simplify the scleral buckling method and reduce operation time. After localizing the tear, full-thickness scleral diathermy is applied to the area. In order to make an indentation, a 3-0 nylon, Supramid or Mersilen suture is placed posterior to the equator, stabilized in the four quadrants, and later tightened to provide adequate pressure after the subretinal fluid has drained.

The phenomenon observed in these patients of postoperative intraocular intrusion of the suture has been termed the '*clothesline phenomenon*'.<sup>6</sup> Intraocular invasion of the suture has been associated with various complications including recurrent retinal and vitreous hemorrhage, uveitis or recurrent retinal detachment.<sup>6,7,8,9</sup>

In our patient, it was clear that an Arruga suture which was placed 22 years earlier gradually invaded the sclera and choroid, eventually reaching the inner retinal layers and intravitreal space.

However, despite the prolonged time since the surgery, our patient had not experienced any problems.

### Conclusion

Although the Arruga suture is no longer used in contemporary practice, we may still encounter complications related to this technique in patients who underwent the procedure in the past. With this report we wished to highlight the need to be prepared when faced with complications due to Arruga sutures in patients undergoing ocular procedures for other reasons.

### Ethics

Informed Consent: It was taken.

Peer-review: Externally and internally peer-reviewed.

### Authorship Contributions

Surgical and Medical Practices: Erkan Ünsal, Concept: Erkan Ünsal, Design: Erkan Ünsal, Data Collection or Processing: Erkan Ünsal, Kadir Eltutar, Analysis or Interpretation: Erkan Ünsal, Literature Search: Erkan Ünsal, Osman Kızılay, Writing: Erkan Ünsal, Belma Karini.

Conflict of Interest: No conflict of interest was declared by the authors.

Financial Disclosure: The authors declared that this study received no financial support.

### References

1. Tuncer İ, Kaynak S, Karahan E, Zengin MÖ. Comparison between scleral buckling surgery with and without use of operating microscope in cases of rhegmatogenous retinal detachment. *Türk J Ophthalmol.* 2014;44:175-178.
2. Hasanreisöglü B, Aksünger A, Or M. Klasik dekolman cerrahisinde Nüks nedenleri ve reoperasyon sonuçları. *Retina-Vitreus.* 1996;1:482-487.
3. Eldem B, İlhan B, Elgin U, Saraçbaşı O. Yırtıklı retina dekolmanı hastalarının klinik özellikleri ve tedavi sonuçları. *Retina-Vitreus.* 1998;6:22-31.
4. Williams GA, Aaberg TM. Techniques of scleral buckling. *Retina.* Mosby Company. 1994:1979-2017.
5. Schepens CL, Okamura ID, Brockhurst RJ, Regan CD. Scleral buckling procedures. V. Synthetic sutures and silicone implants. *Arch Ophthalmol.* 1960;64:868-881.
6. Greven CM, Kurup SK, Jacklin HN. Intraocular erosion and intrusion of an Arruga encircling suture. *Retina.* 2011;31:1437-1438.
7. Grunauer-Kloevekorn C, Krause A, Duncker GI. [The "Clothesline Phenomenon" after Cerclage with Arruga's Suture - Is Cutting of the Suture Necessary?]. *Klin Monbl Augenheilkd.* 2004;221:56-58.
8. Kishimoto M. [Removable Arruga suture]. *Nihon Ganka Kiyō.* 1967;18:1160-1165.
9. Tsukahara I. [Erosion of the sclera by cerclage equatorial (Arruga)]. *Nihon Ganka Kiyō.* 1967;18:706-708.





## Focal Choroidal Excavation

Zafer Cebeci, Şerife Bayraktar, Merih Oray, Nur Kır

Istanbul University İstanbul Faculty of Medicine, Department of Ophthalmology, İstanbul, Turkey

### Summary

Focal choroidal excavation is a choroidal pit that can be detected by optical coherence tomography. Central serous chorioretinopathy, choroidal neovascularization and polypoidal choroidal vasculopathy are pathologies associated with focal choroidal excavation. In this article, we present the follow-up and treatment outcomes of three eyes of two patients with focal choroidal excavation.

**Keywords:** Optical coherence tomography, central serous chorioretinopathy, choroidal neovascularization

### Introduction

Focal choroidal excavation is local idiopathic cupping of the choroid which is usually unilateral and not associated with any accompanying systemic disease.<sup>1</sup> In 2006, Jampol et al.<sup>2</sup> first identified the lesion in an asymptomatic patient using optical coherence tomography (OCT). Margolis et al.<sup>3</sup> later used the term focal choroidal excavation for the areas of choroidal pitting observed near the macula on spectral domain (SD)-OCT in patients without posterior staphyloma or scleral ectasia. The condition causes symptoms like decreased vision and metamorphopsia, but its etiology is not fully understood. Studies have documented that focal choroidal excavation may be accompanied by choroidal vascular disorders including central serous chorioretinopathy (CSCR), choroidal neovascularization (CNV) and polypoidal choroidal vasculopathy (PCV), which are responsible for the visual symptoms.<sup>4,5,6,7,8</sup>

In this report we present the treatment and follow-up results of three eyes of two patients with the rare condition of focal choroidal excavation.

### Case Reports

#### Case 1

A 50-year-old female patient presented to the Ophthalmology Department of the İstanbul University İstanbul Faculty of Medicine with an approximately 2-year history of gradual vision

loss in her left eye. Despite progressively decreasing vision in her left eye over the course of 2 years, she had not previously consulted any doctor about the problem. There was nothing extraordinary in the patient's medical or family history. Her vision was 1.0 (decimal) in the right eye and 0.05 in the left eye. Anterior segment examination was normal and intraocular pressure was 15 mmHg in the right eye and 16 mmHg in the left eye. Pigment epithelium changes were observed in both the right and left macula on fundoscopy (Figure 1a). OCT examination revealed extrafoveal inferonasal choroidal excavation in the right eye (Figure 1b), while in the left eye subfoveal focal choroidal excavation was observed, as well as separation of the retinal pigment epithelium (RPE) photoreceptor layer and subretinal fluid in the same area (Figure 1c). Central foveal thickness was 245 µm in the left eye. Fundus fluorescein angiography (FFA) and indocyanine green angiography (ICGA) revealed hyperfluorescence consistent with pigment epithelium window defect in the macula and temporal quadrant of the right eye, and hyperfluorescence starting in the early phase and increasing in the late phases in the left macula (Figure 1d, 1e, 1f, 1g). The patient was diagnosed with chronic CSCR and her left eye was treated with low-fluence photodynamic therapy (PDT) (25 j/cm<sup>2</sup>, 300 mW/cm<sup>2</sup>). The spot size was adjusted targeting the area of choroidal vascular hyperpermeability observed in the ICGA mid-phase from which the subretinal fluid originated.

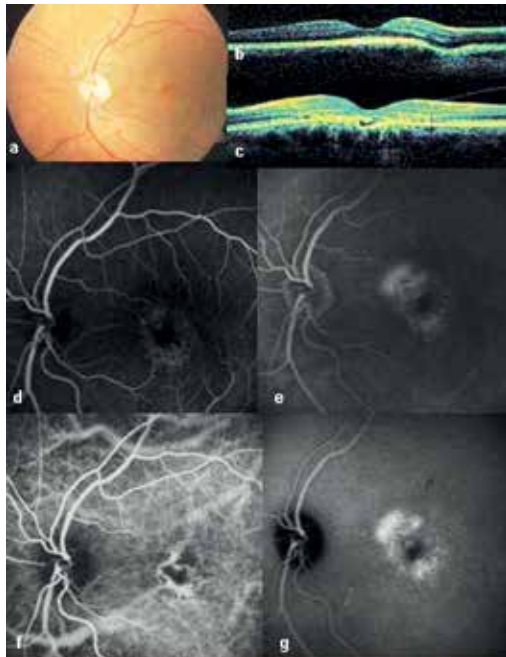
**Address for Correspondence:** Zafer Cebeci MD, İstanbul University İstanbul Faculty of Medicine, Department of Ophthalmology, İstanbul, Turkey  
Phone: +90 532 364 16 49 E-mail: zafaceb@gmail.com **Received:** 07.01.2015 **Accepted:** 02.02.2015

©Copyright 2016 by Turkish Ophthalmological Association  
Turkish Journal of Ophthalmology, Published by Galenos Publishing House

At 1 month after PDT, the subretinal fluid had resolved and visual acuity was 0.3. After 18 months of follow-up, no changes were observed in the lesions in the right eye, visual acuity in the left eye as maintained and there was no recurrence of subretinal fluid. OCT at the final examination showed continuity of the RPE and photoreceptor layer in the area of focal choroidal excavation, and no subretinal fluid was observed (Figure 2a). On FFA, the hyperfluorescence due to RPE window defect was not evident (Figure 2b, 2c) and there was no active leakage apparent on ICGA (Figure 2d, 2e).

**Case 2**

A 28-year-old female patient presented with metamorphopsia in her left eye starting 2 days earlier. There was nothing of note in her medical or family history, and her visual acuity was 1.0 in the right eye and 0.8 with -5.0 D refraction in the left eye. Anterior segment examination was normal. Fundus examination was normal in the right eye, but macular pigmentary alterations were observed in the left eye (Figure 3a). On FFA there was hyperfluorescence beginning in the early phases and increasing in the late phase, which was more suggestive of choroidal neovascular membrane (CNVM) than CSCR (Figure 3b, 3c). Although it is recommended for a definitive diagnosis, ICGA was not done. Despite smooth foveal contours in the left eye on OCT, an area of subfoveal focal choroidal excavation and overlying hyporeflective subretinal fluid were detected (Figure 3d). The lesion in the patient's left eye was accepted as CNVM



**Figure 1.** Case 1 before treatment: left eye fundus photography showing macular pigment epithelium changes (a), right eye optic coherence tomography showing focal choroidal excavation (b), left eye optic coherence tomography showing subfoveal choroidal excavation and subretinal fluid (c), left eye fundus fluorescein angiography showing early stage hyperfluorescence as a window defect (d), left eye fundus fluorescein angiography showing intensified hyperfluorescence in the late phase (e), left eye indocyanine green angiography showing choroidal vessel dilation in the early phase (f), left eye indocyanine green angiography showing late phase hyperfluorescence due to leakage from choroidal vessels (g)

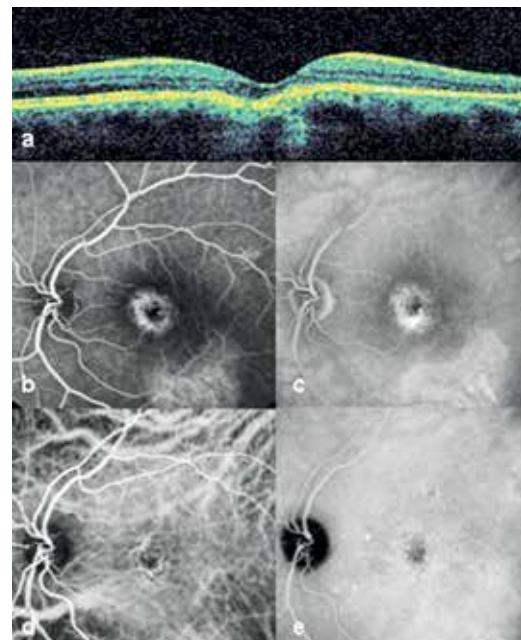
and an intravitreal bevacizumab injection was administered. At follow-up 1 month later, the patient's symptoms had improved, vision in her left eye improved to 0.9 and the hyporeflective area evident on OCT had decreased in size. At 2-year follow-up, visual acuity in the left eye was 0.8 and persistent RPE changes were observed on funduscopy (Figure 3e). Hyperfluorescence which increased slightly in the late phases was observed on FFA of the left eye (Figure 3f, 3g). On OCT, the focal choroidal excavation remained unchanged, the overlying hyporeflective area had resolved and the photoreceptor layer appeared continuous (Figure 3h).

**Discussion**

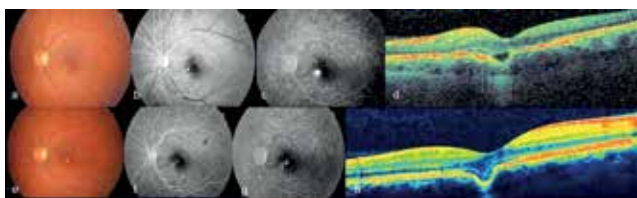
Focal choroidal excavation is a choroidal defect believed to be a congenital condition, though its etiology and pathogenesis are not yet fully understood, and is detectable on SD-OCT.<sup>1</sup> This excavation has been termed 'nonconforming' if photoreceptors are detached from the RPE, or 'conforming' when the RPE follows the contours of the photoreceptor layer.<sup>3</sup> The nonconforming type exhibits a hyporeflective space on SD-OCT which does not appear in the conforming type.

Focal choroidal excavation is generally a stable, unchanging lesion.<sup>1</sup> Our patient with bilateral involvement also had extrafoveal excavation in the fellow eye, but visual acuity was not affected and no complications resulted.

CSCR, CNV and PCV are all pathologies which may accompany focal choroidal excavation.<sup>4,5,6,7,8</sup> It has not been determined whether CSCR leads to focal choroidal excavation or



**Figure 2.** Case 1 at 18 months after photodynamic therapy: focal choroidal excavation and subretinal fluid do not appear on left eye optic coherence tomography (a), left eye fundus fluorescein angiography, early phase (b), left eye fundus fluorescein angiography showing late phase hyperfluorescence due to a window defect (c) left eye indocyanine green angiography showing resolution of choroidal vessel dilation in the early phase (d), late phase hyperfluorescence is no longer apparent on left eye indocyanine green angiography (e)



**Figure 3.** Case 2 pre- and post-treatment appearance: left eye fundus photography showing macular pigment epithelium changes (a), left eye fundus fluorescein angiography, early phase (b), left eye fundus fluorescein angiography showing hyperfluorescence intensifying in the late phase (c), left eye optic coherence tomography showing focal choroidal excavation and an overlying hyporeflective area (d), left eye fundus photograph at 2 years post-treatment showing pigment epithelium changes at the macula (e), left eye fundus fluorescein angiography, early phase at 2 years post-treatment (f), left eye fundus fluorescein angiography at 2 years post-treatment showing hyperfluorescence slightly intensified in the late phase (g), left eye optic coherence tomography at 2 years post-treatment showing conforming excavation and the absence of a hyporeflective area (h)

whether CSCR occurs as a complication of excavation. One of the proposed mechanisms is that excavation is mainly responsible for the pathology, causing atrophy of the overlying RPE and subsequent pump dysfunction, and CSCR occurs as a complication.<sup>7</sup> It has also been proposed that CNV and PCV are both the result of choroidal ischemia in areas of anatomic anomalies.<sup>1</sup>

In a report from Margolis et al.<sup>3</sup> including 12 patients, CSCR was detected in 1 patient who later developed CNV during follow-up. Suzuki et al.<sup>7</sup> evaluated 7 eyes of 6 patients with CSCR and focal choroidal excavation. Although the subretinal fluid resolved in all cases, 3 patients later progressed to nonconforming excavation, which exhibits the same hyporeflectivity on OCT as subretinal fluid. The authors attributed this to persistent subretinal fluid around the lesion. In their series of 41 eyes, Lee et al.<sup>1</sup> detected CSCR in 10 eyes, CNV in 9 eyes and PCV in 1 eye; 2 eyes with CSCR were treated with low-fluence PDT. Despite resolution of the subretinal fluid in these patients, they continued to exhibit separation of the RPE and photoreceptor layer (nonconforming type). The nonconforming type was shown to be significantly associated with visual symptoms and CSCR.<sup>1</sup> This was also true in our two patients, who exhibited nonconforming excavation and experienced visual symptoms. They both reverted to the conforming type, after PDT in the first case and after intravitreal bevacizumab injection in the second case. The resolution of the hyporeflective area evident on OCT in both patients may be related to the decreased choroidal permeability following PDT in the first patient and resolution of the active focal exudation in the retina after intravitreal bevacizumab injection in the second patient. The fact that patients transition between types supports the idea that hyporeflective areas on OCT in the nonconforming type may be due to subretinal fluid. Neither of our patients fully regained their vision after treatment, which may be attributable to the presence of chronic CSCR and subsequent RPE dysfunction.

## Conclusion

In one eye of our first case, focal choroidal excavation remained static over the course of follow-up and did not require treatment. The same patient's other eye was treated with low-fluence PDT and the affected eye of our second case was treated with intravitreal bevacizumab; both eyes showed regression to conforming excavation after treatment. Studies with larger patient numbers and longer follow-up times are needed to better understand the etiology, course and treatment options of focal choroidal excavation.

## Ethics

Informed Consent: It was taken.

Peer-review: Externally and internally peer-reviewed.

## Authorship Contributions

Surgical and Medical Practices: Zafer Cebeci, Nur Kır, Concept: Zafer Cebeci, Şerife Bayraktar, Merih Oray, Nur Kır, Design: Zafer Cebeci, Şerife Bayraktar, Merih Oray, Nur Kır, Data Collection or Processing: Zafer Cebeci, Şerife Bayraktar, Merih Oray, Nur Kır, Analysis or Interpretation: Zafer Cebeci, Şerife Bayraktar, Merih Oray, Nur Kır, Literature Search: Zafer Cebeci, Şerife Bayraktar, Merih Oray, Writing: Zafer Cebeci, Şerife Bayraktar, Merih Oray, Nur Kır.

Conflict of Interest: No conflict of interest was declared by the authors.

Financial Disclosure: The authors declared that this study received no financial support.

## References

1. Lee CS, Woo SJ, Kim YK, Hwang DJ, Kang HM, Kim H, Lee SC. Clinical and spectral-domain optical coherence tomography findings in patients with focal choroidal excavation. *Ophthalmology*. 2014;121:1029-1035.
2. Jampol LM, Shankle J, Schroeder R, Tornambe P, Spaide RF, Hee MR. Diagnostic and therapeutic challenges. *Retina*. 2006;26:1072-1076.
3. Margolis R, Mulkamala SK, Jampol LM, Spaide RF, Ober MD, Sorenson JA, Gentile RC, Miller JA, Sherman J, Freund KB. The expanded spectrum of focal choroidal excavation. *Arch Ophthalmol*. 2011;129:1320-1325.
4. Obata R, Takahashi H, Ueta T, Yuda K, Kure K, Yanagi Y. Tomographic and angiographic characteristics of eyes with macular focal choroidal excavation. *Retina*. 2013;33:1201-1210.
5. Kobayashi W, Abe T, Tamai H, Nakazawa T. Choroidal excavation with polypoidal choroidal vasculopathy: a case report. *Clin Ophthalmol*. 2012;6:1373-1376.
6. Xu H, Zeng F, Shi D, Sun X, Chen X, Bai Y. Focal choroidal excavation complicated by choroidal neovascularization. *Ophthalmology*. 2014;121:246-250.
7. Suzuki M, Gomi F, Hara C, Sawa M, Nishida K. Characteristics of central serous chorioretinopathy complicated by focal choroidal excavation. *Retina*. 2014;34:1216-1222.
8. Say EA, Jani PD, Appenzeller MF, Houghton OM. Focal choroidal excavation associated with polypoidal choroidal vasculopathy. *Ophthalmic Surg Lasers Imaging Retina*. 2013;44:409-411.



# A Baseline Algorithm for Molecular Diagnosis of Genetic Eye Diseases: Ophthalmologist's Perspective

Hande Taylan Şekeroğlu\*, Gülen Eda Utine\*\*, Mehmet Alikışıfoğlu\*\*\*

\*Hacettepe University Faculty of Medicine, Department of Ophthalmology, Ankara, Turkey

\*\*Hacettepe University Faculty of Medicine, Department of Pediatrics, Division of Pediatric Genetics, Ankara, Turkey

\*\*\*Hacettepe University Faculty of Medicine, Department of Medical Genetics, Ankara, Turkey

## To the Editor:

Genetic eye diseases constitute a large and heterogeneous group. Individual diseases may cause multiple structural/functional anomalies and developmental features. Family history may be suggestive; however, it may also be challenging, particularly in late-onset conditions or in cases of variable expression.

In the current era of genetic advances, diagnosis of a genetic eye disease is facilitated by well-established collaboration between ophthalmologists and geneticists, as increasingly more patients will be asking for genetic counseling and prenatal diagnosis in addition to ophthalmologic management. Molecular investigation of a genetic eye disease requires customized analysis and advanced technology in addition to the requisite detailed family history and accurate ophthalmological diagnosis. A common indication for genetic testing is the validation of a preliminary diagnosis made in clinical practice. The need to determine the prognostic implications of the genotype, assessment of the recurrence risk and in particular, the possibility of specific gene therapy in the near future encourages clinicians to pursue genetic research.

We present here a baseline algorithm covering common genetic mechanisms in order to outline a basic molecular approach for ophthalmologists. The first step of the flow chart, a prudent clinical examination with complete description of the phenotype, is indispensable for making a precise and accurate preliminary diagnosis (Figure 1). If the phenotype is pathognomonic, Sanger sequencing is preferred for confirmation.<sup>1</sup> A previously established genotype-phenotype correlation may add to the

value, either by providing accurate prognostic information or by indicating which particular mutation to look for. One such example may be electroretinographic supranormal rod response, indicating KCNV2 mutation type cone dystrophy, which can be precisely detected by Sanger sequencing or qPCR.<sup>2</sup>

Conventional karyotyping reveals microscopically visible abnormalities in chromosome number and structure, as well as translocations and large indels, and is appropriate as the first-tier test in multisystemic congenital abnormalities. Although conventional cytogenetic analysis may be considered as a screening test in such patients, microscopic diagnosis sometimes requires preliminary clinical diagnosis, designed in order to unveil specific deletions or duplications. A classic example is the small 11p interstitial deletion in Wilms tumor and aniridia, which could only be shown via fluorescence *in situ* hybridization or multiplex ligation-dependent probe amplification.

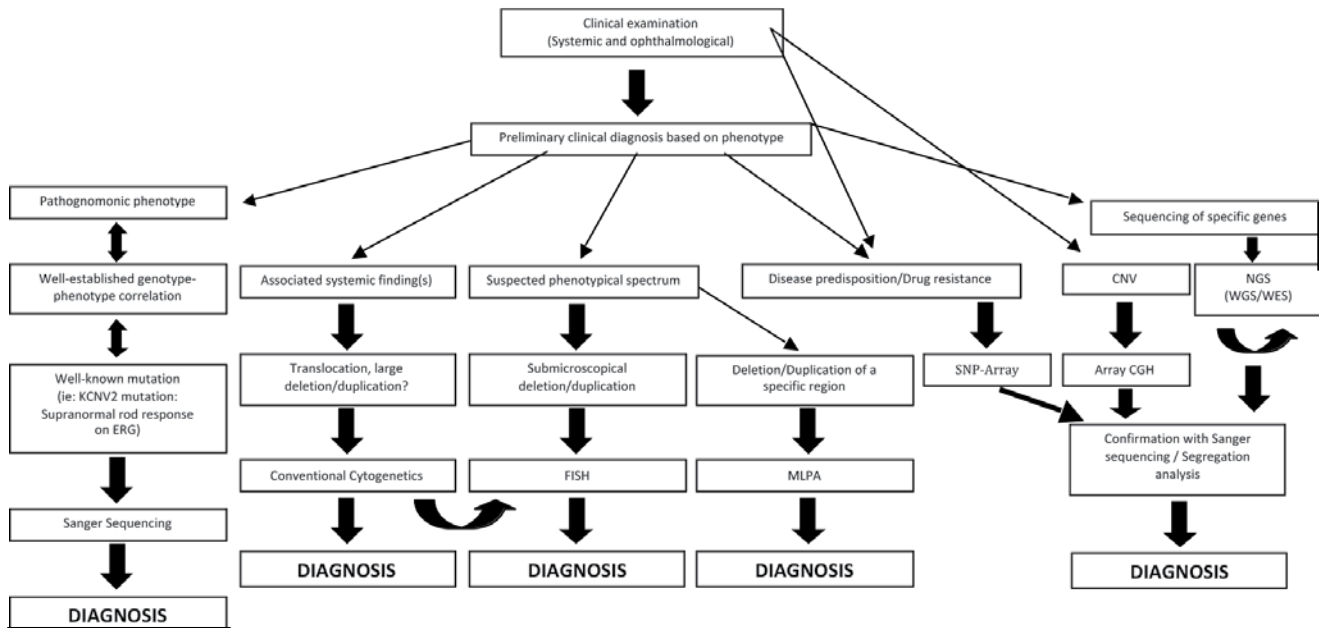
Array comparative genomic hybridization methods are preferred for genetic eye diseases involving copy number variations. One such example is congenital cataract, which has a very complicated phenotype-genotype correlation and shows clinical heterogeneity. Responsible mutations in crystallins, transcription factors and membrane proteins have been reported.<sup>3</sup> Furthermore, single nucleotide polymorphism array may enable the detection of disease predisposition or drug resistance (e.g. age-related macular degeneration).

Next generation sequencing is the most current technology allowing parallel sequencing of many genes and may cover either a spectrum of known genes or all exons of all genes, allowing the discovery of new causative genes. The latter is called whole exome

**Address for Correspondence:** Hande Taylan Şekeroğlu MD, Hacettepe University Faculty of Medicine, Department of Ophthalmology, Ankara, Turkey

Phone: +90 312 305 31 33 E-mail: h\_taylan@yahoo.com **Received:** 08.09.2015 **Accepted:** 23.10.2015

©Copyright 2016 by Turkish Ophthalmological Association  
Turkish Journal of Ophthalmology, Published by Galenos Publishing House



**Figure 1.** A baseline algorithm for the diagnosis of genetic eye diseases. CGH: Comparative genomic hybridization, CNV: Copy number variations, ERG: Electroretinogram, FISH: Fluorescence in situ hybridization, MLPA: Multiplex ligation-dependent probe amplification, NGS: Next generation sequencing, SNP: Single nucleotide polymorphism, WGS: Whole genome sequencing, WES: Whole exome sequencing

sequencing, and is a popular and practical investigation tool for developmental diseases.<sup>1</sup> Genetic testing, theoretically, can also reveal the underlying ocular problem in cases with subnormal vision but otherwise normal ophthalmological examination (i.e. inherited retinal dystrophies), or it can define the high-risk group for an ocular disease and factors that prevent/delay any poor prognosis (i.e. early-onset glaucoma).<sup>4</sup>

The ultimate aim is to treat the condition. This is crucial in genetic disorders, in which modern treatment suggestions involve replacement of the missing molecular element. Many ongoing trials regarding gene therapies appear to have promising results for future treatment options.<sup>5</sup> Ophthalmologists would benefit from a practical flow chart based on *a priori* assumption of genetic basis for each genetic eye disease. This would not only save time and money but may also lead to practical advances in diagnosis and management.

**Keywords:** Genetic eye diseases, molecular diagnosis, gene therapy

### References

1. Prokudin I, Simons C, Grigg JR, Storen R, Kumar V, Phua ZY, Smith J, Flaherty M, Davila S, Jamieson RV. Exome sequencing in developmental eye disease leads to identification of causal variants in GJA8, CRYGC, PAX6 and CYP1B1. *Eur J Hum Genet.* 2014;22:907-915.
2. Grigg JR, Holder GE, Billson FA, Korsakova M, Jamieson RV. The importance of electrophysiology in revealing a complete homozygous deletion of KCNV2. *J AAPOS.* 2013;17:641-643.
3. Huang B, He W. Molecular characteristics of inherited congenital cataracts. *Eur J Med Genet.* 2010;53:347-357.
4. Wiggs JL, Pierce EA. Genetic testing for inherited eye disease: who benefits? *JAMA Ophthalmol.* 2013;131:1265-1266.
5. Dalkara D, Sahel JA. Gene therapy for inherited retinal degenerations. *C R Biol.* 2014;337:185-192.

## 2016 Referee Index

A. Baki Mudun	H. Zeki Büyükyıldız	Nilüfer Alparslan
Afsun Şahin	Halil Ateş	Nilüfer Gözüm
Ahmet Özer	Halit Pazarlı	Nilüfer Koçak
Ali Aydın	Hande Taylan Şekeroğlu	Nilüfer Yalçındağ
Ali Bülent Çankaya	Hasan Basri Çakmak	Nur Kır
Ali Hakan Durukan	Hayyam Kıratlı	Nuray Akyol
Ali Osman Saatçi	Hikmet Başmak	Nurşen Yüksel
Alp Alaluf	Huban Atilla	Nurten Ünlü
Alper Yarangümeli	Hülya Güngel	Osman Şevki Arslan
Altuğ Çetinkaya	Hürkan Kerimoğlu	Öner Gelişken
Anıl Kubaloğlu	Hüseyin Bayramlar	Özcan Ocakoğlu
Ayça Sarı	Hüseyin Gürsoy	Özlem Evren Kemer
Ayça Yılmaz	İlgaz Yalvaç	Pınar Çakar Özdal
Ayşe Yağcı	İbrahim Koçer	Raciha Beril Küçümen
Banu Bozkurt	İlker Eser	Rana Altan Yayıoğlu
Banu Turgut Öztürk	İmren Akkoyun	Reha Ersöz
Bekir Sıtkı Aslan	Jale Menteş	Remzi Avcı
Bengü İkinci Köktekir	Kadir Eltutar	Samuray Tuncer
Canan Aslı Utine	Kemal Gündüz	Sevda Aydın Kurna
Cemil Kadri Apaydın	Koray Gümüş	Sibel Çalışkan Kadayıfçılar
Cenap Güler	M. Necdet Cinhüseyinoğlu	Sibel Kocabeyoğlu
Dilaver Erşanlı	Mehmet Baykara	Sinan Tatlıpınar
Doğan Ceyhan	Mehmet Cem Mocan	Süleyman Kaynak
Esin Başer	Melih Ünal	Şeyda Karadeniz Uğurlu
Fevzi Şentürk	Melis Palamar Onay	Tamer Takmaz
Feyza Önder	Merih Soylu	Ulviye Yiğit
Figen Batioğlu	Muhittin Taşkapılı	Umut Aslı Dinç
Filiz Afrashi	Murat Karaçorlu	Ümit Aykan
Firdevs Örnek	Murat Tunç	Ümit Kamış
Füsun Uzunoğlu	Mustafa Ünal	Üzeyir Günenç
Günhan Erbakan	Müslime Akbaba	Yılmaz Özyazgan
Gürsel Yılmaz	Nazmi Zengin	Yonca Aydın Akova
Güzin İskeleli	Nazmiye Erol	

## 2016 Author Index

Abdullah Beyođlu.....	182	Çađlar Öktem.....	73
Abdullah İlhan .....	144	Çiđdem Altan.....	169
Abdurrahman Bařcı.....	47	Deniz Çalıřkan.....	68
Abdülvahit Demir .....	200	Deniz Marangoz.....	251
Adem Gül.....	205	Derya Öztuna .....	68
Ahmet Akman.....	58,87,255,274	Dorukcan Akınciođlu .....	144
Ahmet Demirok.....	47,200	Duygu Er.....	11
Ahmet Ergin.....	109,270	Ebru Esen .....	186
Ahmet Musmul .....	175	Ebru Evren.....	25
Ahmet Özkađnıcı .....	190	Eda Bengi Yılmaz.....	148
Ahmet Taylan Yazıcı .....	221	Elif Erdem .....	83
Ahmet Yađmur Bař .....	114,209	Emel Bařar.....	282
Ali Demircan.....	47	Emine Esra Karaca.....	104
Ali Kurt.....	73	Emine řen.....	25,95
Ali Küçüködük.....	58	Emre Hekimođlu.....	114,209
Almila Sarıgöl Sezenöz .....	255,274	Emrullah Beyazyıldız.....	237
Alper Ađca.....	47,200	Engin Bilge Özgürhan .....	47,200
Arif Taylan Öztürk.....	11	Enver řimřek .....	237
Aslıhan Esra Omay .....	156	Eray Atalay .....	7
Aslıhan Uzun.....	248	Erbil Seven.....	205
Ayça Sarı.....	194	Ercüment Bozkurt .....	169
Ayhan Özyurt.....	11	Erdem Dinç .....	148,194
Aysun İdil.....	68,118	Erdinç Nayir.....	148
Ayře Ayça Sarı .....	148	Erhan Yumuřak .....	21
Ayře Karabıçak Acer.....	73	Erkan Ünsal.....	293
Banu řatana .....	169	Erol Özer .....	244
Banu Turgut Öztürk .....	182	Ertuđrul Can.....	205
Baran Gencer .....	264	Esra Kardeř.....	109
Barıř Malbora .....	62	Esra Vatansever .....	194
Belma Karini .....	293	Faruk Öztürk.....	237
Berçin Tarlan.....	123	Fatih Çakır Gündođan.....	144
Berker Bakbak.....	182	Fatih Mehmet Mutlu.....	21
Berna Bařarır .....	169	Fatih Özcura .....	99
Berna řahan .....	277	Fatma Merve Bozkurt.....	148
Berna Yüce .....	38	Ferda Çiftçi.....	251,277
Betül İlkay Sezgin Akçay.....	109	Ferda Özkan .....	277
Betül Orhan.....	62	Feyzahan Uzun .....	104
Betül Tuđcu .....	232	Fırat Helvacıođlu.....	99
Beyza Özcan .....	209	Filiz Kibar .....	83
Burcu Çelik .....	221	Gökhan Gülkılık .....	161
Bülent Aliođlu.....	62	Göktuđ Demirci .....	161
Celal Yeter .....	99	Gülen Eda Utine .....	299
Cengiz Alagöz.....	47,169,200,221	Gülřah Tanrıřıkı .....	274
Ceren Yeřilkaya.....	169	Günhal řatırtav.....	190
Ceyhun Arıcı .....	7,197,282	Gürkan Erdođan .....	270
Cihan Ünlü.....	109,170	Hacı Murat Sađdıık .....	99

## 2016 Author Index

Hakan Özdemir.....	16,91,138,232	Merih Oray.....	77,296
Halil Ateş.....	38	Mert Şimşek.....	52
Halil İbrahim Demirkale.....	221	Merve Özbek.....	161
Haluk Esgin.....	41	Meryem Donbaloglu.....	190
Hande Taylan Şekeroğlu.....	299	Mine Barış.....	165
Hanife Tuba Akçam.....	104	Muhammed Batur.....	205
Hasan Ali Tufan.....	264	Muhammet Altınışık.....	30
Hatice Akraş.....	244	Muhittin Taşkapılı.....	169,221
Hayyam Kıratlı.....	123	Murat Doğan İşcanlı.....	248
Hürkan Kerimoğlu.....	190	Murat Hasanreisoğlu.....	44
Hüseyin Güzel.....	182	Murat Karaçorlu.....	16,91,138
Hüseyin Yetik.....	197	Murat Kocamaz.....	221
Işıl Sayman Muslubaş.....	16,91,138	Murat Küçükevcilioğlu.....	21
Işın Doğan Ekici.....	251	Mustafa Aksoy.....	255
İbrahim Arif Koytak.....	30	Mustafa Değer Bilgeç.....	7
İbrahim Tuncer.....	7,197	Mustafa Eliaçık.....	161
İkbal Seza Petriçli.....	118	Mustafa Eroğlu.....	264
İlkay Kılıç Müftüoğlu.....	1,241	Mustafa Gök.....	248
İlknur Tuğal-Tutkun.....	77	Mustafa Özsütçü.....	161
İnci Elif Erbahçeci.....	179	Mustafa Vatansver.....	148,194
İsmail Erşan.....	264	Mümin Hocaoğlu.....	16,91,138
Jale Karakaya.....	209	Nadir Koçak.....	182
Jale Menteş.....	165	Namık Özbek.....	62
Kadir Eltutar.....	244,293	Neşe Alagöz.....	169
Kansu Bozkurt.....	109	Nihal Demircan.....	186
Kemal Örnek.....	179	Nihal Demirel.....	209
Kemal Tekin.....	95	Nilgün Yıldırım.....	175
Leyla Asena.....	87,255	Nilüfer Koçak.....	11
Leyla Niyaz.....	175	Nur Kır.....	215,226,296
Mahmut Kaya.....	11	Nurgül Örnek.....	179
Mahmut Odabaşı.....	161	Nurşen Öncel Acır.....	151
Mehmet Ali Şekeroğlu.....	114,209	Oktay Diner.....	21
Mehmet Alikasıfoğlu.....	299	Onur Gökmen.....	87
Mehmet Aşık.....	264	Onur Ölçücü.....	47,200
Mehmet Borazan.....	151	Onur Polat.....	259
Mehmet Hakan Özdemir.....	30	Osman Kızılay.....	293
Mehmet Hakan Tırhış.....	156	Osman Murat Uyar.....	244
Mehmet Özveren.....	200	Ökkeş Baz.....	221
Mehmet Selim Kocabora.....	161	Özdemir Özdemir.....	118
Mehmet Serdar Dervişoğulları.....	291	Özkan Kocamış.....	73
Mehmet Serhat Mangan.....	7,197	Özlem Yıldırım.....	148
Mehmet Tetikoğlu.....	99	Pelin Yılmazbaş.....	25,95,156
Mehmet Yılmaz.....	264	Pembe Oltulu.....	190
Melike Balıkoğlu Yılmaz.....	25	Pınar Çakar Özdal.....	52
Meltem Yağmur.....	83	Pınar Nalçacıoğlu.....	52
Meriç Çolak.....	58	Refik Oltulu.....	190



## 2016 Author Index

Reha Ersöz .....	83
Samuray Tuncer .....	215,226
Sedat Arıkan .....	264
Sedat Taşdemir .....	73
Selçuk Kara .....	264
Selçuk Sızmaz .....	83,186
Serdar Aktaş .....	99,244
Serhad Nalçacı .....	165
Serkan Özcan .....	259
Serra Arf .....	16,91,138
Sevil Karaman Erdur .....	161
Sevim Kavuncu .....	156
Sezin Akça Bayar .....	62
Sibel Bingöllü .....	83
Sibel İnan .....	259
Sirel Gür Güngör .....	58,87,241,255,274
Soner Koltaş .....	83
Süleyman Kaynak .....	11
Şansal Gedik .....	182
Şengül Özdek .....	44,104
Şeref Kinyas .....	41
Şerife Bayraktar .....	215,226,296
Taha Sezer .....	30
Tansu Ulukavak Çiftçi .....	104
Tekin Yaşar .....	205
Tuba Kara .....	148,194

Tuğba Aydoğan Gezginaslan .....	109, 270
Tuncay Küsbeci .....	38
Tülay Şimşek .....	95,237
Ufuk Adıgüzel .....	44
Ufuk Elgin .....	25,95
Uğur Çiçek .....	221
Umut Duygu Uzunel .....	38
Ülker Çelik .....	114
Ümit Übeyt İnan .....	259
Ümit Yolcu .....	21,144
Ümrân Yıldırım .....	291
Vildan Öztürk .....	277
Yasemin Dere .....	215
Yonca Aydın Akova .....	1,241
Yusuf Cem Yılmaz .....	226
Yusuf Kale .....	114
Yusuf Yıldırım .....	47,169,200,221
Yüksel Totan .....	291
Zafer Cebeci .....	215,226,296
Zafer Öztaş .....	165
Zekai Avcı .....	62
Zeki Baysal .....	259
Zeynep Aktaş .....	44
Zeynep Dadacı .....	151
Zeynep Kunt .....	186
Zuhal Özen Tunay .....	68,118

## 2016 Subject Index

23-gauge transconjunctival sutureless technique.....	11	Eyelid margin.....	291
Acanthamoeba.....	83	Eyelid reconstruction.....	277
Aladdin.....	259	Familial microspherophakia.....	237
Alcaligenes.....	83	Frozen section.....	277
Anterior chamber depth.....	161,255	Fuchs' uveitis syndrome.....	52
Anterior segment parameters.....	95,259	Fundus autofluorescence.....	165
Anterior uveitis.....	190	Fundus fluorescein angiography.....	244
Antimetabolites.....	77	Geriatric.....	118
Antitubercular therapy.....	186	Gestational age.....	114
Aphakia.....	38	Glaucoma.....	38,44,237
Arruga's suture.....	293	Granulomatous keratic precipitates.....	109
Astigmatism.....	99	Hemifacial spasm.....	282
Autofluorescence.....	165	Hemorrhage.....	215
Behçet's disease.....	87	Herpetic anterior uveitis.....	109
Biaxial microincision cataract surgery.....	99	Herpetic keratouveitis.....	87
Bietti crystalline dystrophy.....	144	Heterochromia.....	52
Binocular B class driving license.....	73	Hidrocystoma.....	251
Biologic agents.....	77	High myopia.....	200
Birth weight.....	114	High-order aberrations.....	200
Bladder carcinoma.....	190	Histiocytosis.....	194
Blepharospasm.....	282	Histopathology.....	291
Blunt eye trauma.....	197	Hyperbaric oxygen therapy.....	244
Botulinum toxin.....	282	Hyperhomocysteinemia.....	182
Branching vascular network.....	165	Imaging methods.....	232
Bullous keratopathy.....	156	Individuals over the age of 50.....	73
Canaliculitis.....	25	Inferior oblique myectomy.....	21
Canaliculotomy.....	25	Inferior oblique overaction.....	21
Cataract.....	52,95	Infliximab.....	87
Cataract surgery.....	7	Insulin resistance.....	264
Central serous chorioretinopathy.....	296	Interferon.....	41
Central serous retinopathy.....	30	Intermediate uveitis.....	41
Childhood.....	194	Intracameral triamcinolone acetonide.....	169
Children.....	62	Intraocular lens.....	161
Choroid.....	30	Intraocular lens exchange.....	156
Choroidal neovascularization.....	296	Intraocular lens subluxation.....	156
Cilioretinal artery occlusion.....	244	Intraocular pressure.....	52
Coats' disease.....	226	Intravitreal bevacizumab.....	16,221,270
Complications.....	1,52	Iris atrophy.....	109
Conjunctivitis.....	25	Juvenile idiopathic arthritis.....	77
Crimean Congo hemorrhagic fever.....	248	Keratitis.....	83
Cryotherapy.....	226	Laser photocoagulation.....	114,209,226
Cup area.....	175	Learning curve.....	7
Curettage.....	25	Lens anterior capsule rupture.....	197
Cyclosporine.....	1	Lenticular myopia.....	237
Degenerative myopia.....	30	Leukemia.....	62
Dexamethasone implant.....	179	Low vision.....	68,118
Disc area.....	175	Low vision rehabilitation.....	68,118
Dry eye.....	104	Lyme disease.....	241
Eccrine gland.....	251	Macular burn.....	138
Electroretinography.....	144	Macular edema.....	179,270
Elevated intraocular pressure.....	109	Mean absolute error.....	255
Eye.....	123	Metastasis.....	148
Eyelid.....	248	Methylenetetrahydrofolate reductase mutation.....	182

## 2016 Subject Index

Microperimetry.....	91	Proptosis.....	194
Microspherophakia.....	237	Pseudoexfoliation.....	156
Migration.....	44	Pseudoexfoliation glaucoma.....	95
Multifocal electroretinogram.....	91	Pseudoexfoliation syndrome.....	255
Multifocal electroretinography.....	144	Pseudomonas.....	83
Multiple myeloma.....	148	Recurrent basal cell carcinoma.....	277
Multiple sclerosis.....	41	Remifentanyl.....	209
Myopia.....	47	Retinal detachment.....	293
Neoplasm.....	123	Retinal ganglion cell layer.....	264
Nonmedical laser.....	138	Retinal nerve fiber layer.....	58,274
Obstructive sleep apnea syndrome.....	104	Retinal pigment epithelial detachment.....	215
Occult macular dystrophy.....	91	Retinal vasculitis.....	241
Ocular rosacea.....	1	Retinitis pigmentosa.....	179
Ocular surface health.....	104	Retinopathy of prematurity.....	114,209
Ophthalmologic findings.....	62	School-age children.....	68
Optic cup.....	175	Schwannoma.....	291
Optic disc.....	175	Sclera buckling.....	293
Optic disc drusen.....	232	Scleral buckle.....	44
Optical biometer.....	95,259	Silicone oil removal.....	11
Optical coherence tomography.....	30,58,91,232,274,296	Sirius.....	259
Optic nerve head.....	58	Small incision lenticule extraction.....	47,200
Oral acyclovir.....	109	Split nerve fiber layer bundles.....	274
Orbita.....	148	Steroid.....	186
Orbital cystic mass.....	251	Strabismus.....	282
Orbital mass.....	194	Superior oblique palsy.....	21
Pain.....	151	Surgical success.....	169
Papillophlebitis.....	182	Tick.....	248
Paradoxical worsening.....	186	Topical anesthesia.....	151
Paraneoplastic syndrome.....	190	Trabeculectomy.....	87,169
Pars plana vitrectomy.....	226	Transpupillary argon laser cyclophotocoagulation.....	38
Pediatric cataract.....	205	Traumatic aniridia.....	38
Periodic ophthalmological examination.....	73	Traumatic cataract.....	197
Peripheral vasculitis.....	41	Treatment.....	1
Phacoemulsification.....	7,99,151	Triplet.....	114
Phacoemulsification surgery.....	255	Tubercular choroiditis.....	186
Phacovitrectomy.....	161	Type 2 idiopathic macular telangiectasia.....	270
Photodynamic therapy.....	16	Uveal melanoma.....	123
Photorefractive keratectomy.....	47	Uveitis.....	77,241
Plasmacytoma.....	148	Verbal pain scale.....	151
Polypoid.....	165	Visual analog scale.....	151
Polypoidal choroidal vasculopathy.....	16,165	Visual field.....	244
Posterior capsular opacification.....	205	Vitreoretinal surgery.....	138
Posterior capsulotomy.....	205	Vitreous hemorrhage.....	221
Postoperative refractive outcomes.....	161	White dot syndromes.....	241
Primary open-angle glaucoma.....	95		
Proliferative diabetic retinopathy.....	221		

## 2016 - 2017 INTERNATIONAL CONGRESSES

**American Association for Pediatric Ophthalmology and Strabismus (AAPOS)/Strabismus and Pediatric Ophthalmological Society of India (SPOSD) Joint Conference: An Intercontinental Perspective of Pediatric Ophthalmology & Strabismus**  
2-4 December 2016 - Jaipur, India  
[http://www.aapos.org/meeting/2016\\_joint\\_meeting\\_jaipur\\_india/](http://www.aapos.org/meeting/2016_joint_meeting_jaipur_india/)

**TOA Winter Symposium**  
13-15 January 2017, Bursa, Turkey  
<http://todnet.org/kissempozyumu2017/>

**AAPOS 43<sup>rd</sup> Annual Meeting**  
2-6 April 2017, Nashville, TN, USA

**1<sup>st</sup> Balkan Ophthalmology Meeting**  
21-23 April 2017, Sarajevo, Bosnia and Herzegovina

**ASCRS 2017 Annual Meeting**  
5-9 May 2017, Los Angeles, CA, USA  
<http://www.ascrs.org/>

**ARVO**  
7-11 May 2017, Baltimore, MD, USA  
<http://www.arvo.org/>

**Euretina 2017**  
7-10 September 2017, Barcelona, Spain

**2017 ESA/AAPOS Joint Meeting**  
13-16 September 2017, Porto, Portugal  
<http://esa2017.com>

**EVER 2017**  
27-30 September 2017, Nice, France

**ESCRS**  
7-11 October 2017, Lisbon, Portugal  
<http://www.escrs.org/>

**An International Perspective of Pediatric Ophthalmology and Strabismus AAPOS/CAPOS Joint Meeting**  
12-15 October 2017, Shanghai, China

**AAO**  
11-14 November 2017, New Orleans, LA, USA  
<http://www.aao.org/annual-meeting>

## 2016 - 2017 NATIONAL CONGRESSES

**TOA 50<sup>th</sup> National Congress**  
9-13 November 2016 - Antalya, Turkey

**TOA Winter Symposium**  
13-15 January 2017, Bursa, Turkey  
<http://todnet.org/kissempozyumu2017/>

**TOA March Symposium**  
18-20 March 2017, Erzurum, Turkey

**TOA April Course**  
7-9 April 2017, Ankara, Turkey

**TOA Spring Symposium**  
26-28 May 2017, İstanbul, Turkey

**TOA Live Surgery**  
16-18 June 2017, İstanbul, Turkey

**TOA Summer Symposium**  
22-24 September 2017, İzmir, Turkey

# TURKISH JOURNAL OF OPHTHALMOLOGY

TJO



Avrupa Konutları Kale, Maltepe Mah. Yedikule Çırpıcı Yolu Sk.9.Blok No:2 Kat.1 Ofis:1 Zeytinburnu-İstanbul-Turkey  
Phone: +90 212 801 44 36 -37 Fax: +90 212 801 44 39 E-mail: dergi@oftalmoloji.org

## Copyright Transfer Form

Corresponding author: .....

Registered number: .....

Title of Article: .....

We, the undersigned authors, accept that the Turkish Journal of Ophthalmology bears no responsibility for the manuscript concerned prior to its acceptance to the Journal. We guarantee that the submitted paper is original, has not previously been published in any other journal, and that, in the event that it is accepted for publication, in whole or in part, the Turkish Journal of Ophthalmology has obtained all permission necessary for publication, and the original copyright form has been submitted to the responsible directorship of publication of the Turkish Journal of Ophthalmology. By signing this form, we transfer copyright of the manuscript to the Turkish Journal of Ophthalmology.

The Turkish Journal of Ophthalmology follows the criteria defined by the International Committee of Medical Journal Editors for authorship of scientific articles; we hereby acknowledge the requirement that each and every person listed in this work should have made a considerable contribution during the creation of this work (such as study design; gathering, analyzing and interpreting the data; or in the writing and scientific review of the article). By signing the Copyright Transfer Form, we hereby declare that all persons identified within the list of authors below have fulfilled the above-mentioned criteria.

The authors reserve the following rights:

1. All proprietary rights, apart from copyright, such as patent rights, etc.
2. The right to use the manuscript in whole or in part in any future work such as books and lectures, free of charge.
3. The right to copy the manuscript for personal use, provided it is not offered for sale.

**Note:** When used as stated above, a complete reference should be given indicating that the manuscript has been published in the Turkish Journal of Ophthalmology.

All authors sign as follows

Name - Surname	Signature	Date
Name - Surname	Signature	Date
Name - Surname	Signature	Date
Name - Surname	Signature	Date
Name - Surname	Signature	Date
Name - Surname	Signature	Date

Address for Correspondence:

Phone:

Fax:

E-mail:

This form should be filled out completely, including original signatures, scanned and submitted electronically together with your manuscript. If you are unable to upload the file, e-mail it as an attachment to dergi@oftalmoloji.org within three days of manuscript submission.

## Distance Visual Acuity Measurements Equivalency Table

ETDRS Standard Line Number						<i>Spatial Frequency</i>
	Qualitative Measurements	Decimal	Snellen	LogMAR	Angle of Resolution	Cycle per Degree
-3		2.00	20/10	-0.30	0.5	60.00
-2		1.60	20/12.5	-0.20	0.625	48.00
-1		1.25	20/16	-0.10	0.8	37.50
0		1.00	20/20	0.00	1	30.00
		0.90		0.05		27.00
1		0.80	20/25	0.10	1.25	24.00
		0.70		0.15		21.00
2		0.63	20/32	0.20	1.6	18.75
		0.60		0.22		18.00
3		0.50	20/40	0.30	2	15.00
4		0.40	20/50	0.40	2.5	12.00
		0.30		0.52		9.00
5		0.32	20/63	0.50	3.15	9.52
6		0.25	20/80	0.60	4	7.50
7		0.20	20/100	0.70	5	6.00
8		0.16	20/125	0.80	6.25	4.80
9		0.13	20/160	0.90	8	3.75
10	CF from 6 m	0.10	20/200	1.00	10	3.00
11	CF from 5 m	0.08	20/250	1.10	12.5	2.40
12	CF from 4 m	0.06	20/320	1.20	16	1.88
13	CF from 3 m	0.05	20/400	1.30	20	1.50
14		0.04	20/500	1.40	25	1.20
15	CF from 2 m	0.03	20/640	1.51	32	0.94
16		0.025	20/800	1.60	40	0.75
17		0.020	20/1000	1.70	50	0.60
18	CF from 1 m	0.016	20/1250	1.80	62.5	0.48
21	CF from 50 cm	0.008	20/2500	2.10	125	0.24
31	HM from 50 cm	0.0008	20/25000	3.10	1250	0.02

Abbreviations:

CF: Counting fingers, HM: Perception of hand motions, m= meter, cm= centimeter

Equations of conversions for Microsoft Excel:

- Log10 (Decimal Acuity)= LogMAR Equivalent

Power (10; -Logmar Equivalent)= Decimal Acuity (for English version of Microsoft Excel)

Kuvvet (10; -Logmar Equivalent)= Decimal Acuity (for Turkish version of Microsoft Excel)

Reference

Eğrilmez S, Akkın C, Erakgün T, Yağcı A. Standardization in evaluation of visual acuity and a comprehensive table of equivalent. Turk J Ophthalmol. 2002;32:132-136.