



www.ofthalmoloji.org

ISSN 2149-8695

# TURKISH JOURNAL OF OPHTHALMOLOGY

**TJO**

## Original Articles

*Early Postoperative Effects of Cataract Surgery on Anterior Segment Parameters in Primary Open-Angle Glaucoma and Pseudoexfoliation Glaucoma*

Ufuk Elgin et al; Ankara, Eskişehir, Turkey

*Effect of Corneal Incision Enlargement on Surgically Induced Astigmatism in Biaxial Microincision Cataract Surgery*

Mehmet Tetikoğlu et al; Kütahya, İstanbul, Turkey

*Evaluation of Ocular Surface Health in Patients with Obstructive Sleep Apnea Syndrome*

Emine Esra Karaca et al; Yozgat, Çankırı, Rize, Ankara, Turkey

*Clinical Features and Prognosis of Herpetic Anterior Uveitis*

Esra Kardeş et al; İstanbul, Turkey

*Retinopathy of Prematurity in Triplets*

Mehmet Ali Şekeroğlu et al; Ankara, Turkey

*Low Vision Rehabilitation in Older Adults*

Zuhal Özen Tunay, et al; Ankara, Turkey

## Review

*Uveal Melanoma: Current Trends in Diagnosis and Management*

Berçin Tarlan and Hayyam Kıratlı; Ankara, Turkey

## Case Reports

*Macular Burns from Nonmedical Lasers*

Işıl Sayman Muslubaş et al; İstanbul, Turkey

*Objective Determination of Retinal Function in Bietti Crystalline Retinopathy*

Dorukcan Akıncioğlu et al; Ankara, Siirt, Erzurum, Turkey

*Orbital Metastasis of Multiple Myeloma: Case Report*

Mustafa Vatansever et al; Mersin, Turkey

galenos

May  
June **2016**  
**46** Volume  
Issue **3**

# TURKISH JOURNAL OF OPHTHALMOLOGY



www.ofthalmoloji.org

TJO

## Editor-in-Chief

### Murat İRKEÇ, MD

Hacettepe University Faculty of Medicine, Department of Ophthalmology, Ankara, Turkey  
Areas of Interest: Cornea and Ocular Surface Disease, Glaucoma, Allergy and Immunology  
E-mail: mirkec@hacettepe.edu.tr

## Associate Editors

### Tomris ŞENGÖR, MD

Istanbul Bilim University Faculty of Medicine, Department of Ophthalmology, Istanbul, Turkey  
Areas of Interest: Cornea and Ocular Surface Disease, Contact Lens  
E-mail: tomris.sengor@gmail.com

### Sait EĞRİLMEZ, MD

Ege University Faculty of Medicine, Department of Ophthalmology, Izmir, Turkey  
Areas of Interest: Cornea and Ocular Surface Disease, Contact Lens, Refraction, Cataract and Refractive Surgery  
E-mail: saitegrilmez@gmail.com

### Özlem YILDIRIM, MD

Mersin University Faculty of Medicine, Department of Ophthalmology, Mersin, Turkey  
Areas of Interest: Uveitis, Medical Retina, Glaucoma  
E-mail: dryildirimoz@hotmail.com

### Banu BOZKURT, MD, FEBO

Selçuk University Faculty of Medicine, Department of Ophthalmology, Konya, Turkey  
Areas of Interest: Cornea and Ocular Surface Disease, Glaucoma, Allergy and Immunology  
E-mail: drbanubozkurt@yahoo.com

## Statistical Board

### Ahmet DİRİCAN

Istanbul University Istanbul Faculty of Medicine, Department of Biostatistics and Medical Informatics, Istanbul, Turkey

## Language Editor

Jacqueline Renee GUTENKUNST, Maryland, USA



## Publishing House

Molla Gürani Mah. Kaçamak Sokak No: 21, 34093  
Fındıkzade-Istanbul-Türkiye  
Tel.: +90 212 621 99 25 Fax: +90 212 621 99 27  
E-mail: info@galenos.com.tr

Printed at: Özgün Ofset Ticaret Ltd. Şti. Yeşilce Mah. Aytekin Sk. No: 21 34418 4. Levent / İSTANBUL  
Tel: 0212 280 00 09 Sertifika No: 13837

Date of printing: June 2016

International scientific journal published bimonthly.

ISSN 2149-8695

Online ISSN: 2149-8709

## Advisory Board

### Yonca Aydın Akova,

Bayındır Kavaklıdere Hospital, Ophthalmology Clinic, Ankara, Turkey

### Gürsoy Alagöz,

Sakarya University Faculty of Medicine, Department of Ophthalmology, Sakarya, Turkey

### Mehmet Baykara,

Uludağ University Faculty of Medicine, Department of Ophthalmology, Bursa, Turkey

### Jose M. Benitez-del-Castillo,

Universidad Complutense de Madrid, Hospital Clinico San Carlos, Department of Ophthalmology, Madrid, Spain

### Özlem Budakoğlu,

Ulucanlar Eye Research and Training Hospital, Department of Ophthalmology, Ankara, Turkey

### Güngör Sobacı,

Hacettepe University Faculty of Medicine, Department of Ophthalmology, Ankara, Turkey

### Bülent Gürler,

Fatih University Faculty of Medicine, Department of Ophthalmology, Istanbul, Turkey

### Murat Doğru,

Keio University Faculty of Medicine, Department of Ophthalmology, Tokyo, Japan

### Kadircan Keskinbora,

Ophthalmology, Independent Practitioner, Istanbul, Turkey

### Anastasio G.P. Konstas,

Aristotle University of Thessaloniki, Department of Ophthalmology, Thessaloniki, Greece

### Anat Loewenstein,

Tel Aviv University Sackler Faculty of Medicine, Department of Ophthalmology, Tel Aviv, Israel

### Ahmet Maden,

Dokuz Eylül University Faculty of Medicine, Department of Ophthalmology, Izmir, Turkey

### Jale Menteş,

Ege University Faculty of Medicine, Department of Ophthalmology, Izmir, Turkey

### Mehmet Cem Mocan,

Hacettepe University Faculty of Medicine, Department of Ophthalmology, Ankara, Turkey

### Mehmet Okka,

Necmettin Erbakan University Meram Faculty of Medicine, Department of Ophthalmology, Konya, Turkey

### Sibel Oto,

Başkent University Faculty of Medicine, Department of Ophthalmology, Ankara, Turkey

### Pınar Çakar Özdal,

Ulucanlar Eye Research and Training Hospital, Department of Ophthalmology, Ankara, Turkey

### Hakan Özdemir,

Bezmialem Vakıf University Faculty of Medicine, Department of Ophthalmology, Istanbul, Turkey

### Afsun Şahin,

Osmangazi University Faculty of Medicine, Department of Ophthalmology, Eskişehir, Turkey

### İlknur Tuğal Tutkun,

Istanbul University Istanbul Faculty of Medicine, Department of Ophthalmology, Istanbul, Turkey

### Ahmet Tuncer Özmen,

Uludağ University Faculty of Medicine, Department of Ophthalmology, Bursa, Turkey

### Ayşen Topalkara,

Cumhuriyet University Faculty of Medicine, Department of Ophthalmology, Ankara, Turkey

### Murat Tuğç,

Ankara Numune Research and Training Hospital, Department of Ophthalmology, Ankara, Turkey

### Zeliha Yazar,

Ankara Research and Training Hospital, Department of Ophthalmology, Ankara, Turkey;  
Kafkas University Faculty of Medicine, Department of Ophthalmology, Kars, Turkey

## The Turkish Journal of Ophthalmology is an official journal of the Turkish Ophthalmological Association.

On Behalf of Turkish Ophthalmological Association Owner

### T. Reha Ersöz,

Çukurova University Faculty of Medicine, Department of Ophthalmology, Adana, Turkey

# TURKISH JOURNAL OF OPHTHALMOLOGY



www.ofthalmoloji.org

TJO

## ABOUT US

The Turkish Journal of Ophthalmology (TJO) is the only scientific periodical publication of the Turkish Ophthalmological Association and has been published since January 1929. In its early years, the journal was published in Turkish and French. Although there were temporary interruptions in the publication of the journal due to various challenges, the Turkish Journal of Ophthalmology has been published continually from 1971 to the present.

The Turkish Journal of Ophthalmology is currently published in Turkish and English languages. TJO is an independent international periodical journal based on single-blind peer-review principle. TJO is regularly published six times a year and special issues are occasionally released. The aim of TJO is to publish original research papers of the highest scientific and clinical value at an international level. Furthermore, review articles, case reports, editorial comments, letters to the editor, educational contributions and congress/meeting announcements are released.

The target audience includes specialists and physicians in training in ophthalmology in all relevant disciplines.

The editorial policies are based on the "Recommendations for the Conduct, Reporting, Editing, and Publication of Scholarly Work in Medical Journals (ICMJE Recommendations)" by the International Committee of Medical Journal Editors (2013, archived at <http://www.icmje.org/>) rules.

The Turkish Journal of Ophthalmology is indexed in the **Emerging Sources Citation Index (ESCI), Directory of Open Access Journals (DOAJ), Gale/Cengage Learning, Index Copernicus, EBSCO Database, Scopus, Turkish Medline-National Citation Index, Turk Medline, Cinahl, Proquest, TUBITAK/ULAKBIM and Turkish Citation Index** databases.

### Open Access Policy

This journal provides immediate open access to its content on the principle that making research freely available to the public supports a greater global exchange of knowledge.

Open Access Policy is based on the rules of the Budapest Open Access Initiative (BOAI) <http://www.budapestopenaccessinitiative.org/>. By "open access" to peer-reviewed research literature, we mean its free availability on the public internet, permitting any users to read, download, copy, distribute, print, search, or link to the full texts of these articles, crawl them for indexing, pass them as data to software, or use them for any other lawful purpose, without financial, legal, or technical barriers other than those inseparable from gaining access to the internet itself. The only constraint on reproduction and distribution, and the only role for copyright in this domain, should be to give authors control over the integrity of their work and the right to be properly acknowledged and cited.

### Subscription Information

TJO is sent free of charge to subscribers. Address changes should be immediately reported to the affiliates and to the managing editor. Subscribers who do not receive the journal in the relevant time period should contact the managing editor. All published volumes in full text can be reached free of charge through the website [www.ofthalmoloji.org](http://www.ofthalmoloji.org). Requests for subscription should be addressed to the Turkish Ophthalmological Association.

Manuscripts can only be submitted electronically through the Journal Agent website (<http://journalagent.com/tjo/>) after creating an account. This system allows online submission and review.

### Membership Procedures

#### Turkish Ophthalmological Association

Bank Account: Yapı Kredi Bankası, Şehremini Şubesi 65774842

IBAN: TR10 0006 7010 0000 0065 7748 42

Annual Subscription: Domestic: 100.-TL (Tax Incl)

Abroad: 100 USD (Tax Incl.)

#### Correspondence Address

Editor-in-Chief, Murat İrkeç, MD, Professor in Ophthalmology  
Hacettepe University Faculty of Medicine, Department of Ophthalmology  
06100 Sıhhiye-Ankara-Turkey

Phone: +90 212 621 99 25 Fax: +90 212 621 99 27

E-mail: [mirkec@hacettepe.edu.tr](mailto:mirkec@hacettepe.edu.tr)

Secretary, Arzu Sevdasız

E-mail: [dergi@ofthalmoloji.org](mailto:dergi@ofthalmoloji.org) - [sekreter@ofthalmoloji.org](mailto:sekreter@ofthalmoloji.org)

Millet Cad. Gülşen Apt. B Blok No: 21/7 Aksaray-Istanbul-Turkey

Phone: +90 212 632 99 98 Fax: +90 212 529 78 30

Web Page: [www.ofthalmoloji.org](http://www.ofthalmoloji.org)

#### Permissions

Requests for permission to reproduce published material should be sent to the editorial office.

Editor-in-Chief: Murat İrkeç, MD, Professor in Ophthalmology

Address: Millet Cad. Gülşen Apt. B Blok No: 21/7

Aksaray-Istanbul-Turkey

Phone: +90 212 632 99 98 Fax: +90 212 529 78 30

Web Page: [www.ofthalmoloji.org](http://www.ofthalmoloji.org)

E-mail: [dergi@ofthalmoloji.org](mailto:dergi@ofthalmoloji.org) - [sekreter@ofthalmoloji.org](mailto:sekreter@ofthalmoloji.org)

#### Advertisement

Applications for advertisement should be addressed to the editorial office.

Address: Millet Cad. Gülşen Apt. B Blok No: 21/7 Aksaray-Istanbul-Turkey

Phone: +90 212 632 99 98 Fax: +90 212 529 78 30

Web Page: [www.ofthalmoloji.org](http://www.ofthalmoloji.org)

E-mail: [dergi@ofthalmoloji.org](mailto:dergi@ofthalmoloji.org) - [sekreter@ofthalmoloji.org](mailto:sekreter@ofthalmoloji.org)

#### Publisher Corresponding Address

Publisher: Erkan Mor

Galenos Yayınevi Tic. Ltd. Şti.

Address: Molla Gürani Mah. Kaçamak Sk. No: 21, 34093

Fındıkzade-Istanbul-Turkey

Phone: +90 212 621 99 25 Fax: +90 212 621 99 27

E-mail: [info@galenos.com.tr](mailto:info@galenos.com.tr)

#### Instructions for Authors

Instructions for authors are published in the journal and on the website [www.ofthalmoloji.org](http://www.ofthalmoloji.org)

#### Material Disclaimer

The author(s) is (are) responsible for the articles published in the Turkish Journal of Ophthalmology.

The editor, editorial board and publisher do not accept any responsibility for the articles.

The journal is printed on acid-free paper.

This work is licensed under a Creative Commons Attribution-NonCommercial-NoDerivatives 4.0 International License.

## INSTRUCTIONS TO AUTHORS

The Turkish Journal of Ophthalmology is an official peer-reviewed publication of the Turkish Ophthalmological Association. Accepted manuscripts are published in both Turkish and English languages.

Manuscripts written in Turkish should be in accordance with the Turkish Dictionary and Writing Guide ("Türkçe Sözlüğü ve Yazım Kılavuzu") of the Turkish Language Association. Turkish forms of ophthalmology-related terms should be checked in the TODNET Dictionary ("TODNET Sözlüğü" <http://www.todnet.org/v3/sozluk/default.asp>) and used accordingly.

The Turkish Journal of Ophthalmology does not charge any article submission or processing charges.

A manuscript will be considered only with the understanding that it is an original contribution that has not been published elsewhere.

Reviewed and accepted manuscripts are translated either from Turkish to English or from English to Turkish by the Journal through a professional translation service. Prior to printing, the translations are submitted to the authors for approval or correction requests, to be returned within 7 days. If no response is received from the corresponding author within this period, the translation is checked and approved by the editorial board. The abbreviation of the Turkish Journal of Ophthalmology is TJO, however, it should be denoted as Turk J Ophthalmol when referenced. In the international index and database, the name of the journal has been registered as Turkish Journal of Ophthalmology and abbreviated as Turk J Ophthalmol.

The scientific and ethical liability of the manuscripts belongs to the authors and the copyright of the manuscripts belongs to the Turkish Journal of Ophthalmology. Authors are responsible for the contents of the manuscript and accuracy of the references. All manuscripts submitted for publication must be accompanied by the Copyright Transfer Form [copyright transfer]. Once this form, signed by all the authors, has been submitted, it is understood that neither the manuscript nor the data it contains have been submitted elsewhere or previously published and authors declare the statement of scientific contributions and responsibilities of all authors.

All manuscripts submitted to the Turkish Journal of Ophthalmology are screened for plagiarism using the 'iThenticate' software. Results indicating plagiarism may result in manuscripts being returned or rejected.

Experimental, clinical and drug studies requiring approval by an ethics committee must be submitted to the Turkish Journal of Ophthalmology with an ethics committee approval report confirming that the study was conducted in accordance with international agreements and the Declaration of Helsinki (revised 2008) (<http://www.wma.net/en/30publications/10policies/b3/>). The approval of the ethics committee and the fact that informed consent was given by the patients should be indicated in the Materials and Methods section. In experimental animal studies, the authors should indicate that the procedures followed were in accordance with animal rights as per the Guide for the Care and Use of Laboratory Animals (<http://oacu.od.nih.gov/regs/guide/guide.pdf>) and they should obtain animal ethics committee approval. Authors must provide disclosure/acknowledgment of financial or material support, if any was received, for the current study. If the article includes any direct or indirect commercial links or if any institution provided material support to the study, authors

must state in the cover letter that they have no relationship with the commercial product, drug, pharmaceutical company, etc. concerned; or specify the type of relationship (consultant, other agreements), if any.

Authors must provide a statement on the absence of conflicts of interest among the authors and provide authorship contributions.

The Turkish Journal of Ophthalmology is an independent international journal based on single-blind peer-review principles. The manuscript is assigned to the Editor-in-Chief, who reviews the manuscript and makes an initial decision based on manuscript quality and editorial priorities. Manuscripts that pass initial evaluation are sent for external peer review, and the Editor-in-Chief assigns an Associate Editor. The Associate Editor sends the manuscript to three reviewers (internal and/or external reviewers). The reviewers must review the manuscript within 21 days. The Associate Editor recommends a decision based on the reviewers' recommendations and returns the manuscript to the Editor-in-Chief. The Editor-in-Chief makes a final decision based on editorial priorities, manuscript quality, and reviewer recommendations. If there are any conflicting recommendations from reviewers, the Editor-in-Chief can assign a new reviewer.

The scientific board guiding the selection of the papers to be published in the Journal consists of elected experts of the Journal and if necessary, selected from national and international authorities. The Editor-in-Chief, Associate Editors, biostatistics expert and English language consultant may make minor corrections to accepted manuscripts that do not change the main text of the paper.

In case of any suspicion or claim regarding scientific shortcomings or ethical infringement, the Journal reserves the right to submit the manuscript to the supporting institutions or other authorities for investigation. The Journal accepts the responsibility of initiating action but does not undertake any responsibility for an actual investigation or any power of decision.

The Editorial Policies and General Guidelines for manuscript preparation specified below are based on "Recommendations for the Conduct, Reporting, Editing, and Publication of Scholarly Work in Medical Journals (ICMJE Recommendations)" by the International Committee of Medical Journal Editors (2013, archived at <http://www.icmje.org/>).

Preparation of research articles, systematic reviews and meta-analyses must comply with study design guidelines:

CONSORT statement for randomized controlled trials (Moher D, Schulz KF, Altman D, for the CONSORT Group. The CONSORT statement revised recommendations for improving the quality of reports of parallel group randomized trials. *JAMA* 2001; 285: 1987-91) (<http://www.consort-statement.org/>);

PRISMA statement of preferred reporting items for systematic reviews and meta-analyses (Moher D, Liberati A, Tetzlaff J, Altman DG, The PRISMA Group. Preferred Reporting Items for Systematic Reviews and Meta-Analyses: The PRISMA Statement. *PLoS Med* 2009; 6(7): e1000097.) (<http://www.prisma-statement.org/>);

STARD checklist for the reporting of studies of diagnostic accuracy (Bossuyt PM, Reitsma JB, Bruns DE, Gatsonis CA, Glasziou PP, Irwig LM, et al., for the STARD Group. Towards complete and accurate reporting of studies of diagnostic

accuracy: the STARD initiative. *Ann Intern Med* 2003;138:40-4.) (<http://www.stard-statement.org/>);

STROBE statement, a checklist of items that should be included in reports of observational studies (<http://www.strobe-statement.org/>);

MOOSE guidelines for meta-analysis and systemic reviews of observational studies (Stroup DF, Berlin JA, Morton SC, et al. Meta-analysis of observational studies in epidemiology: a proposal for reporting Meta-analysis of observational Studies in Epidemiology (MOOSE) group. *JAMA* 2000; 283: 2008-12).

### GENERAL GUIDELINES

Manuscripts can only be submitted electronically through the Journal Agent website (<http://journalagent.com/tjo/>) after creating an account. This system allows online submission and review.

The manuscripts are archived according to ICMJE, Index Medicus (Medline/PubMed) and Ulakbim-Turkish Medicine Index Rules.

Format: Manuscripts should be prepared using Microsoft Word, size A4 with 2.5 cm margins on all sides, 12 pt Arial font and 1.5 line spacing.

**Abbreviations:** Abbreviations should be defined at first mention and used consistently thereafter. Internationally accepted abbreviations should be used; refer to scientific writing guides as necessary.

**Cover letter:** The cover letter should include statements about manuscript type, single-journal submission affirmation, conflict of interest statement, sources of outside funding, equipment (if applicable), approval of language for articles in English and approval of statistical analysis for original research articles.

### REFERENCES

Authors are solely responsible for the accuracy of all references.

**In-text citations:** References should be indicated as a superscript immediately after the period/full stop of the relevant sentence. If the author(s) of a reference is/are indicated at the beginning of the sentence, this reference should be written as a superscript immediately after the author's name. If relevant research has been conducted in Turkey or by Turkish investigators, these studies should be given priority while citing the literature.

Presentations presented in congresses, unpublished manuscripts, theses, Internet addresses, and personal interviews or experiences should not be indicated as references. If such references are used, they should be indicated in parentheses at the end of the relevant sentence in the text, without reference number and written in full, in order to clarify their nature.

**References section:** References should be numbered consecutively in the order in which they are first mentioned in the text. All authors should be listed regardless of number. The titles of journals should be abbreviated according to the style used in the Index Medicus.

### Reference Format

**Journal:** Last name(s) of the author(s) and initials, article title, publication title and its original abbreviation, publication date, volume, the inclusive page numbers. Example: Collin JR, Rathbun JE. Involitional entropion: a review with evaluation of a procedure. *Arch Ophthalmol*. 1978;96:1058-1064.



## INSTRUCTIONS TO AUTHORS

**Book:** Last name(s) of the author(s) and initials, chapter title, book editors, book title, edition, place of publication, date of publication and inclusive page numbers of the extract cited.

**Example:** Herbert L. The Infectious Diseases (1st ed). Philadelphia; Mosby Harcourt; 1999:11;1-8.

**Book Chapter:** Last name(s) of the author(s) and initials, chapter title, book editors, book title, edition, place of publication, date of publication and inclusive page numbers of the cited piece.

**Example:** O'Brien TP, Green WR. Periocular Infections. In: Feigin RD, Cherry JD, eds. Textbook of Pediatric Infectious Diseases (4th ed). Philadelphia; W.B. Saunders Company; 1998:1273-1278.

**Books in which the editor and author are the same person:** Last name(s) of the author(s) and initials, chapter title, book editors, book title, edition, place of publication, date of publication and inclusive page numbers of the cited piece.

**Example:** Solcia E, Capella C, Kloppel G. Tumors of the exocrine pancreas. In: Solcia E, Capella C, Kloppel G, eds. Tumors of the Pancreas. 2nd ed. Washington: Armed Forces Institute of Pathology; 1997:145-210.

### TABLES, GRAPHICS, FIGURES, AND IMAGES

All visual materials together with their legends should be located on separate pages that follow the main text.

**Images:** Images (pictures) should be numbered and include a brief title. Permission to reproduce pictures that were published elsewhere must be included. All pictures should be of the highest quality possible, in

JPEG format, and at a minimum resolution of 300 dpi.

**Tables, Graphics, Figures:** All tables, graphics or figures should be enumerated according to their sequence within the text and a brief descriptive caption should be written. Any abbreviations used should be defined in the accompanying legend. Tables in particular should be explanatory and facilitate readers' understanding of the manuscript, and should not repeat data presented in the main text.

### BIOSTATISTICS

To ensure controllability of the research findings, the study design, study sample, and the methodological approaches and applications should be explained and their sources should be presented.

The "P" value defined as the limit of significance along with appropriate indicators of measurement error and uncertainty (confidence interval, etc.) should be specified. Statistical terms, abbreviations and symbols used in the article should be described and the software used should be defined. Statistical terminology (random, significant, correlation, etc.) should not be used in non-statistical contexts.

All results of data and analysis should be presented in the Results section as tables, figures and graphics; biostatistical methods used and application details should be presented in the Materials and Methods section or under a separate title.

### MANUSCRIPT TYPES

#### Original Articles

Clinical research should comprise clinical observation, new techniques or laboratories studies. Original research articles should include title, structured abstract, keywords relevant to the content of the article, introduction, materials and methods,

results, discussion, study limitations, conclusion, references, tables/figures/images and acknowledgement sections. Title, abstract and key words should be written in both Turkish and English. The manuscript should be formatted in accordance with the above-mentioned guidelines and should not exceed sixteen A4 pages.

**Title Page:** This page should include the title of the manuscript, short title, name(s) of the authors and author information. The following descriptions should be stated in the given order:

1. Title of the manuscript (Turkish and English), as concise and explanatory as possible, including no abbreviations, up to 135 characters
2. Short title (Turkish and English), up to 60 characters
3. Name(s) and surname(s) of the author(s) (without abbreviations and academic titles) and affiliations
4. Name, address, e-mail, phone and fax number of the corresponding author
5. The place and date of scientific meeting in which the manuscript was presented and its abstract published in the abstract book, if applicable

**Abstract:** A summary of the manuscript should be written in both Turkish and English. References should not be cited in the abstract. Use of abbreviations should be avoided as much as possible; if any abbreviations are used, they must be taken into consideration independently of the abbreviations used in the text. For original articles, the structured abstract should include the following sub-headings:

**Objectives:** The aim of the study should be clearly stated.

**Materials and Methods:** The study and standard criteria used should be defined; it should also be indicated whether the study is randomized or not, whether it is retrospective or prospective, and the statistical methods applied should be indicated, if applicable.

**Results:** The detailed results of the study should be given and the statistical significance level should be indicated.

**Conclusion:** Should summarize the results of the study, the clinical applicability of the results should be defined, and the favorable and unfavorable aspects should be declared.

**Keywords:** A list of minimum 3, but no more than 5 key words must follow the abstract. Key words in English should be consistent with "Medical Subject Headings (MESH)" ([www.nlm.nih.gov/mesh/MBrowser.html](http://www.nlm.nih.gov/mesh/MBrowser.html)). Turkish key words should be direct translations of the terms in MESH.

#### Original research articles should have the following sections:

**Introduction:** Should consist of a brief explanation of the topic and indicate the objective of the study, supported by information from the literature.

**Materials and Methods:** The study plan should be clearly described, indicating whether the study is randomized or not, whether it is retrospective or prospective, the number of trials, the characteristics, and the statistical methods used.

**Results:** The results of the study should be stated, with tables/figures given in numerical order; the results should be evaluated according to the statistical analysis methods applied. See General Guidelines for details about the preparation of visual material.

**Discussion:** The study results should be discussed in terms of their favorable and unfavorable aspects and they should be compared with the literature. The conclusion of the study should be highlighted.

**Study Limitations:** Limitations of the study should be discussed. In addition, an evaluation of the implications of the obtained findings/results for future research should be outlined.

**Conclusion:** The conclusion of the study should be highlighted.

**Acknowledgements:** Any technical or financial support or editorial contributions (statistical analysis, English/Turkish evaluation) towards the study should appear at the end of the article.

**References:** Authors are responsible for the accuracy of the references. See General Guidelines for details about the usage and formatting required.

#### Case Reports

Case reports should present cases which are rarely seen, feature novelty in diagnosis and treatment, and contribute to our current knowledge. The first page should include the title in Turkish and English, an unstructured summary not exceeding 150 words, and key words. The main text should consist of introduction, case report, discussion and references. The entire text should not exceed 5 pages (A4, formatted as specified above).

#### Review Articles

Review articles can address any aspect of clinical or laboratory ophthalmology. Review articles must provide critical analyses of contemporary evidence and provide directions of or future research. Most review articles are commissioned, but other review submissions are also welcome. Before sending a review, discussion with the editor is recommended.

Reviews articles analyze topics in depth, independently and objectively. The first chapter should include the title in Turkish and English, an unstructured summary and key words. Source of all citations should be indicated. The entire text should not exceed 25 pages (A4, formatted as specified above).

#### Letters to the Editor

Letters to the Editor should be short commentaries related to current developments in ophthalmology and their scientific and social aspects, or may be submitted to ask questions or offer further contributions in response to work that has been published in the Journal. Letters do not include a title or an abstract; they should not exceed 1,000 words and can have up to 5 references.

#### CORRESPONDENCE

All correspondence should be directed to the TJO editorial board:

**Post:** Turkish Ophthalmological Association

Millet Cad. Gülşen Apt. B Blok No: 21/7 Aksaray-Istanbul-Turkey

**Phone:** +90 212 632 99 98 / Fax: +90 212 529 78 30

**Web Page:** [www.ofthalmoloji.org](http://www.ofthalmoloji.org)

**E-mail:** [dergi@ofthalmoloji.org](mailto:dergi@ofthalmoloji.org) / [sekreter@ofthalmoloji.org](mailto:sekreter@ofthalmoloji.org)

# TURKISH JOURNAL OF OPHTHALMOLOGY



TJO

## CONTENTS

### Original Articles

- 95 Early Postoperative Effects of Cataract Surgery on Anterior Segment Parameters in Primary Open-Angle Glaucoma and Pseudoexfoliation Glaucoma  
Ufuk Elgin, Emine Şen, Tülay Şimşek, Kemal Tekin, Pelin Yılmazbaş
- 99 Effect of Corneal Incision Enlargement on Surgically Induced Astigmatism in Biaxial Microincision Cataract Surgery  
Mehmet Tetikoğlu, Celal Yeter, Fırat Helvacıoğlu, Serdar Aktaş, Hacı Murat Sağdıç, Fatih Özcüra
- 104 Evaluation of Ocular Surface Health in Patients with Obstructive Sleep Apnea Syndrome  
Emine Esra Karaca, Hanife Tuba Akçam, Feyzahan Uzun, Şengül Özdek, Tansu Ulukavak Çiftçi
- 109 Clinical Features and Prognosis of Herpetic Anterior Uveitis  
Esra Kardeş, Kansu Bozkurt, Betül İlkay Sezgin Akçay, Cihan Ünlü, Tuğba Aydoğan Gezginaslan, Ahmet Ergin
- 114 Retinopathy of Prematurity in Triplets  
Mehmet Ali Şekeroğlu, Emre Hekimoğlu, Ülker Çelik, Yusuf Kale Ahmet Yağmur Baş
- 118 Low Vision Rehabilitation in Older Adults  
Zuhal Özen Tunay, Aysun İdil, İkbal Seza Petriçli, Özdemir Özdemir

### Review

- 123 Uveal Melanoma: Current Trends in Diagnosis and Management  
Berçin Tarlan, Hayyam Kıratlı

### Case Reports

- 138 Macular Burns from Nonmedical Lasers  
Işıl Sayman Muslubaş, Mümin Hocaoğlu, Serra Arf, Hakan Özdemir, Murat Karaçorlu
- 144 Objective Determination of Retinal Function in Bietti Crystalline Retinopathy  
Doruçkan Akıncıoğlu, Ümit Yolcu, Abdullah İlhan, Fatih Çakır Gündoğan
- 148 Orbital Metastasis of Multiple Myeloma: Case Report  
Mustafa Vatanserver, Fatma Merve Bozkurt, Erdem Dinç, Eda Bengi Yılmaz, Erdiñç Nayir, Ayşe Ayça Sarı, Özlem Yıldırım, Tuba Kara



# Early Postoperative Effects of Cataract Surgery on Anterior Segment Parameters in Primary Open-Angle Glaucoma and Pseudoexfoliation Glaucoma

Ufuk Elgin\*, Emine Şen\*, Tülay Şimşek\*\*, Kemal Tekin\*, Pelin Yılmazbaş\*

\*Ulucanlar Eye Research and Training Hospital, Ophthalmology Clinic, Ankara, Turkey

\*\*Osmangazi University Faculty of Medicine, Department of Ophthalmology, Eskişehir, Turkey

## Summary

**Objectives:** To compare the effect of cataract surgery on anterior segment parameters measured by optical biometry in primary open-angle glaucoma (POAG) and pseudoexfoliation glaucoma (PXG).

**Materials and Methods:** Twenty-five eyes of 25 patients with POAG and 29 eyes of 29 patients with PXG who had uncomplicated phacoemulsification and posterior chamber intraocular lens implantation surgery were included to our prospective study. Central corneal thickness (CCT), anterior chamber depth (ACD) and axial length (AL) were measured with an optical biometer preoperatively and at 1 month postoperatively. The pre- and postoperative values of intraocular pressure (IOP) and the anterior segment parameters and the differences between POAG and PXG were compared statistically by paired t, independent t and chi-square tests.

**Results:** The mean values of preoperative CCT ( $p=0.042$ ) and ACD ( $p=0.012$ ) were significantly lower in the PXG than in the POAG group. In the PXG group, IOP decreased ( $p=0.001$ ) but CCT ( $p=0.03$ ) and ACD ( $p=0.001$ ) increased significantly postoperatively; AL did not change significantly. In the POAG group, IOP decreased ( $p=0.01$ ) and ACD ( $p=0.004$ ) increased significantly postoperatively, while AL and CCT did not change significantly. There were no significant differences in the pre- to postoperative changes in IOP ( $p=0.76$ ), AL ( $p=0.44$ ) and CCT ( $p=0.52$ ) values between the two groups. However, the postoperative increase in ACD was larger in the PXG group ( $p=0.03$ ).

**Conclusion:** Cataract surgery may cause some changes in IOP and anterior segment parameters like ACD and CCT postoperatively in eyes with POAG and PXG, and these changes may differ between eyes with PXG and POAG.

**Keywords:** Cataract, primary open-angle glaucoma, pseudoexfoliation glaucoma, optical biometer, anterior segment parameters

## Introduction

Cataract surgery lowers intraocular pressure (IOP) and reduces the need for anti-glaucomatous drugs, especially in patients with lens-induced glaucoma, angle-closure glaucoma and pseudoexfoliation glaucoma (PXG).<sup>1,2,3,4,5,6</sup> Hayashi et al.<sup>3</sup> found that cataract surgery lowered IOP in primary open-angle glaucoma (POAG) and angle-closure glaucoma, and reported a greater decrease in cases of narrow-angle glaucoma. The reduction in IOP is the result of increased anterior chamber depth (ACD) and widening of the iridocorneal angle following cataract surgery.<sup>2,6,7,8,9,10</sup>

Noncontact optical biometers use diode lasers and low-coherence reflectometry to allow the measurement of anterior segment parameters such as central corneal thickness (CCT), ACD, lens thickness and axial length (AL).<sup>11,12,13</sup> The aim

of this study was to determine the early effects of cataract surgery on IOP and anterior segment parameters such as CCT, ACD and AL measured at postoperative 1 month by optical biometry (Haag-Streit LENSTAR® LS 900 Optical Biometer, Switzerland) in POAG and PXG patients and to compare these effects between the two different types of glaucoma.

## Materials and Methods

Twenty-five eyes of 25 patients with POAG and 29 eyes of 29 patients with PXG who underwent phacoemulsification and posterior chamber intraocular lens implantation in our hospital between September 2013 and December 2014 were included in this prospective study. The study was approved by the Ankara Numune Training and Research Hospital Ethics Committee and informed consent was obtained from all patients.

**Address for Correspondence:** Ufuk Elgin MD, Ulucanlar Eye Research and Training Hospital, Ophthalmology Clinic, Ankara, Turkey

Phone: +90 312 312 62 61 E-mail: ufukelgin@superonline.com **Received:** 16.06.2015 **Accepted:** 07.08.2015

This article is also published in Turkish under doi:10.4274/tjo.92604 pages 2016;46:95-98.

Pre- and postoperatively all patients underwent corrected visual acuity assessment using the Snellen chart, anterior and posterior segment examination, IOP measurement by Goldmann applanation tonometry, preoperative iridocorneal gonioscopy using a Goldmann three-mirror lens, optic disc and retinal nerve fiber layer evaluation by spectral-domain optical coherence tomography (OCT) and CCT measurement by ultrasonic pachymetry.

The exclusion criteria of the study were as follows: age less than 40 years old; presence of an active intraocular infection; previous ocular surgery or ocular trauma; history of uveitis; and glaucoma types other than PXG and POAG. Patients with diabetes mellitus were excluded due to possible effects on lens thickness. Furthermore, patients exhibiting widespread pterygium, leukoma, nebula, keratoconus or other corneal degeneration and dystrophies of the cornea on ophthalmologic examination, patients with elevated IOP or other glaucomatous findings refractory to medical treatment, and patients with any intra- or postoperative complications of the phacoemulsification procedure were not included in the study.

Patients over 40 years old were included in the study. Other inclusion criteria for POAG patients were as follows: being followed under anti-glaucomatous medical treatment in our glaucoma clinic; unmedicated IOP  $\geq 22$  mmHg; grade III-IV open iridocorneal angle according to the Shaffer classification; absence of glaucomatous findings at the optic disc (e.g. cup-to-disc ratio  $\geq 0.3$ , localized neuroretinal rim notching, peripapillary choroidal atrophy, and splinter hemorrhage); and absence of glaucomatous visual field findings such as nasal step, arcuate scotoma or Seidel's scotoma in the patient's medical records. In addition to the inclusion criteria stated for POAG patients, the presence of pseudoexfoliation material at the pupillary margin and/or the lens surface was required for PXG patients. PXG patients with Shaffer grade I and II were not included in the study.

In addition to the detailed ophthalmologic examination, CCT, AL and ACD measurements were performed by optic biometry preoperatively and at the first postoperative month by the same experienced physician (K.T.).

The surgery was performed under topical anesthesia (Alcaine 0.5% ophthalmic solution, Alcon) beginning with a 2.8 mm clear corneal incision in the superotemporal quadrant, followed by phacoemulsification with torsional phaco technology (Infiniti, Alcon Laboratories Inc.) and single-piece hydrophobic posterior chamber IOL implantation (AcrySof® SA 30AL, Alcon), concluding with an intracameral cefuroxime (1 mg/0.1 ml) injection. In the postoperative period, patients received topical moxifloxacin hydrochloride (Vigamox® 0.5% ophthalmic solution, Alcon) four times a day for one week and topical prednisolone acetate (Predforte® 1% ophthalmic solution, Allergan) four times a day for one month. The t test, independent samples t test and chi-square test were used in statistical analyses.

## Results

The POAG group consisted of 25 (12 female and 13 male) patients with a mean age of  $64.9 \pm 8.5$  (range, 46-75) years; the PXG group consisted of 29 (15 female and 14 male) patients with a mean age of  $69.6 \pm 6.3$  (range, 60-77) years. The gender distributions of the groups were statistically equivalent, but the PXG group was statistically older than the POAG group ( $p=0.32$  and  $p=0.043$ , respectively) (Table 1).

Preoperative IOL, AL, CCT and ACD values are summarized in Table 2. All patients' glaucoma was medically controlled; therefore there was no significant difference between groups in terms of IOL achieved with medication ( $p=0.84$ ). Preoperative number of anti-glaucomatous drugs used was  $1.15 \pm 0.5$  in the POAG group and  $1.4 \pm 0.5$  in the PXG group. Preoperative mean CCT and ACD were found to be significantly lower in PXG eyes compared with POAG eyes ( $p=0.04$  and  $p=0.01$ , respectively); no significant difference was detected in AL between the groups ( $p=0.21$ ) (Table 2).

Pre- and postoperative IOP and other anterior segment parameter values, as well as the postoperative changes in these parameters are presented in Table 3. In PXG eyes, IOP decreased postoperatively ( $p=0.001$ ) while CCT and ACD values increased ( $p=0.029$  and  $p=0.001$ , respectively). There was no significant difference in AL ( $p=0.44$ ). In POAG eyes, IOP decreased postoperatively ( $p=0.01$ ) while ACD values increased ( $p=0.04$ ). However, no difference was observed in CCT or AL values ( $p=0.31$  and  $p=0.42$ , respectively). The number of anti-glaucomatous drugs used postoperatively was  $1.1 \pm 0.6$  in the POAG group and  $1.2 \pm 0.6$  in the PXG group.

Comparison of the surgically induced anterior segment changes between PXG and POAG eyes revealed no significant

Table 1. Demographic characteristics of the patients			
	POAG group	PXG group	p value
Age, years (mean $\pm$ SD, minimum-maximum)	$64.9 \pm 8.5$ (46-75)	$69.6 \pm 6.3$ (60-77)	$p=0.043^*$
Gender (n,%)	12 female (48%) 13 male (52%)	15 female (51.7%) 14 male (48.3%)	$p=0.32$
POAG: Primary open-angle glaucoma, PXG: Pseudoexfoliation glaucoma, SD: Standard deviation			
*Statistically significant			

Table 2. Preoperative mean intraocular pressure, central corneal thickness, axial length and anterior chamber depth values			
	POAG group	PXG group	p value
IOP (mmHg)	$18.2 \pm 1.3$	$18.3 \pm 2.5$	$p=0.84$
CCT ( $\mu$ m)	$542.7 \pm 21.6$	$520.5 \pm 16.8$	$p=0.042^*$
AL (mm)	$23.04 \pm 0.7$	$23.22 \pm 0.35$	$p=0.21$
ACD (mm)	$3.32 \pm 0.16$	$3.12 \pm 0.15$	$p=0.012^*$
POAG: Primary open-angle glaucoma, PXG: Pseudoexfoliation glaucoma, IOP: Intraocular pressure, CCT: Central corneal thickness, AL: Axial length, ACD: Anterior chamber depth			
*Statistically significant			



differences in IOP (p=0.76), AL (p=0.44) or CCT (p=0.52) changes, whereas the postoperative increase in ACD was significantly greater in PXG eyes (p=0.03) (Table 3).

### Discussion

In both glaucomatous and normal eyes, cataract surgery increases ACD and widens the iridocorneal angle, thereby decreasing IOP.<sup>1,2,3,4,5,6,14</sup> Huang et al.<sup>14</sup> used anterior segment OCT to investigate ACD and anterior chamber angle in angle-closure glaucoma and open-angle glaucoma patients after cataract surgery and found that cases with narrow angles in particular showed larger reduction in IOP. The current study included POAG and open-angle PXG patients in order to determine the effects of cataract surgery on IOP and anterior segment parameters such as CCT, ACD and AL in these two groups of patients with open angles.

Cataract surgery is the main surgical treatment method for primary angle-closure glaucoma (PACG) patients and is preferred by many practitioners over trabeculectomy.<sup>7,15</sup> Zhao et al.<sup>7</sup> analyzed 85 PACG patients by Pentacam imaging 3 months after cataract surgery and found a significant IOP reduction as well as increased anterior chamber volume and wider anterior chamber angle.

Although these effects may be more pronounced in patients with angle-closure glaucoma, cataract surgery may also lead to a drop in IOP and changes in anterior segment parameters in patients with open-angle glaucoma.<sup>3</sup> Because all of the subjects in our study had open-angle glaucoma, a secondary aim of our study was to evaluate the effect of another variable, pseudoexfoliation, on these parameters.

Dooley et al.<sup>9</sup> used the Pentacam to evaluate the effects of uncomplicated cataract surgery on anterior segment morphology

in normal, nonglaucomatous eyes and observed that IOP decreased by an average of 3.2 mmHg while anterior chamber angle, depth and volume increased postoperatively. They also showed that the preoperative IOP/ACD ratio fell postoperatively in proportion to the decrease in IOP.<sup>9</sup> We also observed significant increases in ACD after cataract surgery in both POAG and PXG patients, with a greater increase in PXG patients. Ciliary zonular laxity is a probable cause of the shallower anterior chamber in PXG patients.<sup>16</sup> Doganay et al.<sup>17</sup> showed that PXG patients have relatively shallower anterior chambers than control subjects. Consistent with the literature, in the current study the preoperative ACD was significantly shallower in PXG patients than POAG patients. Furthermore, the postoperative increase in ACD was larger in PXG patients compared to POAG patients. Although IOP declined significantly in both of our study groups, there was no significant difference between the groups. In addition, we detected no significant pre- to postoperative changes in CCT. As in the current study, Dooley et al.<sup>9</sup> examined CCT changes in the sixth week after cataract surgery and also found no significant differences.

Our results revealed no significant differences between pre- and postoperative AL. In contrast, Seok et al.<sup>18</sup> found that AL increased significantly after cataract surgery. In a Turkish study, Bilak et al.<sup>19</sup> reported a significant decrease in AL values at 1 month after cataract surgery in healthy subjects. AL may also decrease after trabeculectomy.<sup>20</sup> Brown<sup>20</sup> demonstrated that AL values decreased in proportion to the fall in IOP following trabeculectomy. Unlike both of those studies, we detected no significant change in AL values postoperatively.

### Conclusion

Uncomplicated phacoemulsification with posterior chamber IOL implantation surgery in POAG and PXG patients can lead to significant changes such as lower IOP and greater ACD. To the best of our knowledge, there are no reports in the literature comparing the effects of cataract surgery on anterior segment parameters measured by optical biometry in patients with POAG and PXG. The larger postoperative increase in the ACD values of PXG patients is likely related to ciliary zonular laxity in these patients. Future studies are being planned to include larger patient numbers and a wider variety of glaucoma types and to utilize different imaging methods like anterior segment OCT and Pentacam.

### Ethics

Ethics Committee Approval: Our presentation was approved by Ethics Committee of Ankara Numune Training and Research Hospital, Informed Consent: The study was approved by the Ankara Numune Training and Research Hospital ethics committee and informed consent was obtained from all patients.

Peer-review: Externally and internally peer-reviewed.

### Authorship Contributions

Surgical and Medical Practices: Ufuk Elgin, Emine Şen, Tülay Şimşek, Kemal Tekin, Pelin Yılmazbaş, Concept: Ufuk Elgin, Emine Şen, Tülay Şimşek, Kemal Tekin, Pelin Yılmazbaş, Design:

**Table 3. Preoperative and 1 month postoperative intraocular pressure, central corneal thickness, axial length and anterior chamber depth values**

	POAG group	PXG group	p value (intergroup difference)
IOL (mmHg)	Preop: 18.2±1.3 Postop: 16.3±1.5 p=0.01*	Preop: 18.3±2.5 Postop: 15.2±1.2 p=0.001*	p=0.76
CCT (µm)	Preop: 542.7±21.6 Postop: 545.2±30.2 p=0.21	Preop: 520.5±16.8 Postop: 525.0±17.9 p=0.029*	p=0.52
AL (mm)	Preop: 23.04±0.7 Postop: 23.05±0.65 p=0.42	Preop: 23.22±0.35 Postop: 23.22±0.28 p=0.44	p=0.44
ACD (mm)	Preop: 3.32±0.16 Postop: 3.51±0.21 p=0.004*	Preop: 3.12±0.15 Postop: 3.58±0.19 p=0.001*	p=0.03*

POAG: Primary open-angle glaucoma, PXG: Pseudoexfoliation glaucoma, IOP: Intraocular pressure, CCT: Central corneal thickness, AL: Axial length, ACD: Anterior chamber depth, Preop: Preoperative, Postop: Postoperative  
\*Statistically significant

Ufuk Elgin, Emine Şen, Tülay Şimşek, Kemal Tekin, Pelin Yılmazbaş, Data Collection or Processing: Ufuk Elgin, Emine Şen, Tülay Şimşek, Kemal Tekin, Pelin Yılmazbaş, Analysis or Interpretation: Ufuk Elgin, Emine Şen, Tülay Şimşek, Kemal Tekin, Pelin Yılmazbaş, Literature Search: Ufuk Elgin, Emine Şen, Tülay Şimşek, Kemal Tekin, Pelin Yılmazbaş, Writing: Ufuk Elgin, Emine Şen, Tülay Şimşek, Kemal Tekin, Pelin Yılmazbaş.

Conflict of Interest: No conflict of interest was declared by the authors.

Financial Disclosure: The authors declared that this study received no financial support.

## References

1. Shrivastava A, Singh K. The effect of cataract extraction on intraocular pressure. *Curr Opin Ophthalmol*. 2010;21:118-122.
2. Kronberg BP, Rhee DJ. Anterior segment imaging and the intraocular pressure lowering effect of cataract surgery for open and narrow angle glaucoma. *Semin Ophthalmol*. 2012;27:149-154.
3. Hayashi K, Hayashi H, Nakao F, Hayashi F. Effect of cataract surgery on intraocular pressure control in glaucoma patients. *J Cataract Refract Surg*. 2001;27:1779-1786.
4. Poley BJ, Lindstrom RL, Samuelson TW, Schulze R Jr. Intraocular pressure reduction after phacoemulsification with intraocular lens implantation in glaucomatous and nonglaucomatous eyes: evaluation of a causal relationship between the natural lens and open-angle glaucoma. *J Cataract Refract Surg*. 2009;35:1946-1955.
5. Mansberger SL, Gordon MO, Jampel H, Bhorade A, Brandt JD, Wilson B, Kass MA; Ocular Hypertension Treatment Study Group. Reduction in intraocular pressure after cataract extraction: the Ocular Hypertension Treatment Study. *Ophthalmology*. 2012;119:1826-1831.
6. Huang G, Gonzalez E, Lee R, Chen YC, He M, Lin SC. Association of biometric factors with anterior chamber angle widening and intraocular pressure reduction after uneventful phacoemulsification for cataract. *J Cataract Refract Surg*. 2012;38:108-116.
7. Zhao Q, Li N, Zhong X. Determination of anterior segment changes with Pentacam after phacoemulsification in eyes with primary angle-closure glaucoma. *Clin Experiment Ophthalmol*. 2012;40:786-791.
8. Uçakhan OO, Ozkan M, Kanpolat A. Anterior chamber parameters measured by the Pentacam CES after uneventful phacoemulsification in normotensive eyes. *Acta Ophthalmol*. 2009;87:544-548.
9. Dooley I, Charalampidou S, Malik A, Loughman J, Molloy L, Beatty S. Changes in intraocular pressure and anterior segment morphometry after uneventful phacoemulsification cataract surgery. *Eye (Lond)*. 2010;24:519-526.
10. Yang HS, Lee J, Choi S. Ocular biometric parameters associated with intraocular pressure reduction after cataract surgery in normal eyes. *Am J Ophthalmol*. 2013;156:89-94.
11. Doğan M, Polat O, Karadaş M, Küspeci T, Yavaş G, İnan S, İnan Ü. Kataraktı olan gözlerde göz içi lens gücü hesaplanmasında parsiyel kohorens interferometri ile optik düşük kohorens reflektometri yöntemlerinin karşılaştırılması. *Turk J Ophthalmol*. 2014;44:419-423.
12. Çankaya C, Doğanay S. Göz içi lens gücü hesaplaması ve optik biometri. *Glo-Kat*. 2011;6:207-214.
13. Shen P, Ding X, Congdon NG, Zheng Y, He M. Comparison of anterior ocular biometry between optical low-coherence reflectometry and anterior segment optical coherence tomography in an adult Chinese population. *J Cataract Refract Surg*. 2012;38:966-970.
14. Huang G, Gonzalez E, Peng PH, Lee R, Leungurasatien T, He M, Porco T, Lin SC. Anterior chamber depth, iridocorneal angle width, and intraocular pressure changes after phacoemulsification: narrow versus open iridocorneal angles. *Arch Ophthalmol*. 2011;129:1283-1290.
15. Tarongoy P, Ho CL, Walton DS. Angle-closure glaucoma: the role of the lens in the pathogenesis, prevention and treatment. *Surv Ophthalmol*. 2009;54:211-225.
16. Crichton AC, Oryschak AF, McWhae JA, Kirker AW, Chacon-Andrade H. Postmortem microscopic evaluation and clinical correlation of a pseudophakic eye with and loss of zonular support. *J Cataract Refract Surg*. 2007;33:162-165.
17. Doganay S, Tasar A, Cankaya C, Firat PG, Yologlu S. Evaluation of Pentacam-Scheimpflug imaging of anterior segment parameters in patients with pseudoexfoliation syndrome and pseudoexfoliative glaucoma. *Clin Exp Optom*. 2012;95:218-222.
18. Seok JY, Lee D, Kyung H, Kim JM. Axial length change after implantable collamer lens implantation. *J Korean Ophthalmol Soc*. 2013;54:1675-1679.
19. Bilak S, Simsek A, Capkin M, Guler M, Bilgin B. Biometric and intraocular pressure change after cataract surgery. *Optom Vis Sci*. 2015;92:464-470.
20. Brown SVL. To evaluate change in axial length measurement after successful glaucoma filtering surgery. *Ophthalmology*. 1999;106:2311.



# Effect of Corneal Incision Enlargement on Surgically Induced Astigmatism in Biaxial Microincision Cataract Surgery

Mehmet Tetikoğlu\*, Celal Yeter\*\*, Fırat Helvacıoğlu\*\*\*, Serdar Aktaş\*, Hacı Murat Sağdıç\*, Fatih Özcura\*

\*Dumlupınar University Faculty of Medicine, Department of Ophthalmology, Kütahya, Turkey

\*\*Başakşehir State Hospital, Ophthalmology Clinic, İstanbul, Turkey

\*\*\*Maltepe University Faculty of Medicine, Department of Ophthalmology, İstanbul, Turkey

## Summary

**Objectives:** To evaluate surgically induced astigmatism (SIA) in biaxial microincision cataract surgery with enlargement of one corneal incision during intraocular lens implantation (IOL).

**Materials and Methods:** Data from 683 eyes with cataract that underwent biaxial microincision cataract surgery and IOL were retrospectively analyzed. The operated eyes were divided into 4 groups defined by final corneal incision length after IOL implantation. There were 83 eyes with 1.6 mm corneal incisions (group 1) and 200 eyes in each of the 2, 2.4, and 2.8 mm corneal incision groups (groups 2, 3 and 4, respectively). SIA was assessed using preoperative and postoperative keratometric values at one month.

**Results:** The mean magnitude of SIA was  $0.83 \pm 0.4$  D in group 1,  $0.93 \pm 0.5$  D in group 2,  $1.03 \pm 0.6$  D in group 3 and  $1.04 \pm 0.7$  D in group 4. The SIA showed statistically significant differences between the four groups ( $p=0.05$ ). Pairwise group comparisons revealed significant differences between groups 1 and 3 and groups 1 and 4 ( $p=0.005$ ).

**Conclusion:** Biaxial microincision cataract surgery with an incision size of 1.6 mm resulted in the least SIA. Enlargement of the corneal incision beyond 2.0 mm during IOL implantation led to significant increases in SIA. We believe that with the development and dissemination of IOLs which can be inserted through small corneal incisions, biaxial microincision cataract surgery will be the best choice to prevent SIA and increase visual acuity.

**Keywords:** Astigmatism, biaxial microincision cataract surgery, phacoemulsification

## Introduction

Modern cataract surgery and improved lens technology have allowed emulsification of the nucleus by phacoemulsification and implantation of intraocular lenses (IOLs) through smaller incisions. Creating smaller incisions minimizes damage to tissues and reduces postoperative pain and inflammation, providing rapid and stable visual rehabilitation. It also minimizes surgically induced astigmatism (SIA), one of the main factors influencing vision quality after cataract surgery.<sup>1,2,3,4,5</sup> Microincision cataract surgery (MICS) can be performed with either micro-coaxial or biaxial phacoemulsification. With the microaxial procedure, the size of the corneal incision is reduced from 3.2 mm to 2.2 mm, while in biaxial phacoemulsification (B-MICS) the cornea incision is between 0.9 and 1.5 mm.<sup>6,7,8</sup>

Although B-MICS was first described by Shearing et al.<sup>9</sup> in 1985, it did not begin to gain acceptance among surgeons

until much later due to the development of microincision techniques for phacoemulsification. The use of an unsleeved phacoemulsification tip in B-MICS separates irrigation and aspiration. The procedure is performed by making two 1.2-1.5 mm corneal incisions, one for the unsleeved phaco tip, the other for an irrigating chopper.<sup>10,11,12</sup>

One of the major problems in B-MICS is IOL implantation, mainly because it is difficult to insert the lens through the smaller incisions. After surgery with 1.4 mm incisions, there are three approaches to IOL implantation: one of the two existing corneal incisions can be enlarged, a third incision can be created, or the IOL can be implanted without enlarging the microincisions.<sup>13,14,15,16,17</sup>

The aim of this study was to investigate how widening a corneal incision during IOL implantation in B-MICS affects astigmatism.

**Address for Correspondence:** Mehmet Tetikoğlu MD, Dumlupınar University Faculty of Medicine, Department of Ophthalmology, Kütahya, Turkey

E-mail: drtetikoglu@yahoo.com.tr **Received:** 29.11.2014 **Accepted:** 30.06.2015

This article is also published in Turkish under doi:10.4274/tjo.52386 pages 2016;46:99-103.

## Materials and Methods

Data from 683 eyes with cataract that underwent B-MICS in Başakşehir State Hospital and the Dumlupınar University Faculty of Medicine, Department of Ophthalmology between January 2011 and April 2014 were analyzed retrospectively. Patients with any preoperative corneal pathologies or intraoperative complications were excluded from the study.

Nuclear hardness was evaluated using the Lens Opacities Classification System II. To investigate the correlation between nuclear hardness and SIA, nuclear hardness grades I-II were evaluated as one group and grades III-IV as another group. Peribulbar anesthesia consisting of 4 ml of 0.0125 mg/ml epinephrine and 2 g/ml lidocaine (Jetokaine®) were administered to all patients. Superior and temporal corneal incisions were made. Sodium hyaluronate (3.0%) and sodium chondroitin sulfate (4.0%) were used to maintain the anterior chamber and protect the corneal endothelium. Capsulorhexis of 5.0-5.5 mm diameter was performed with Utrata forceps. In cases without visible fundus reflex due to severe cataract, capsulorhexis was completed after staining the anterior lens capsule with 0.1% trypan blue. The quick-chop phacoemulsification technique was used with balanced salt solution hydrodissection and hydrodelineation. The IOL was implanted through the temporal incision, which was not used for phacoemulsification, after it was widened to accommodate the lens. The incision was closed by stromal hydration. Eyes with Eyecryl micro 262 IOLs implanted through 1.6 mm corneal incisions comprised group 1; eyes with Optiflex MO/F-13 IOLs implanted through corneal incisions widened to 2.0 mm comprised group 2. Group 3 consisted of eyes with 2.4 mm corneal incisions and Acriva UD 613, Zaracomm Focus Force Basic IOLs, while in group 4 the corneal incisions were widened to 2.8 mm for Alcon SN60AT IOLs. Postoperatively all patients were administered ofloxacin (Exocin 0.3%) and 1% prednisolone acetate (Pred-Forte) five times a day. In both clinics keratometry (K) values were measured preoperatively and 1 month postoperatively using an autorefractometer/keratometer (Nidek ARK-510A), followed by evaluation of SIA based on the method developed by Holladay et al.<sup>18</sup>

Statistical analyses were performed using Statistical Package for the Social Sciences version 16.0. One-way ANOVA was used to compare the four groups. Post hoc analysis was used for pairwise comparisons.

## Results

Table 1 presents patient age, sex, nuclear hardness grades, and pre- and postoperative mean K values of 683 eyes in 4 groups based on corneal incision size during biaxial microincision phacoemulsification surgery. SIA was  $0.83 \pm 0.4$  diopter (D) in group 1,  $0.93 \pm 0.5$  D in group 2,  $1.03 \pm 0.6$  D in

group 3 and  $1.04 \pm 0.7$  D in group 4. Comparison of the four groups revealed a statistically significant difference ( $p=0.05$ ). In pairwise group comparisons, group 1 was significantly different than groups 3 and 4 (Figure 1, Table 2).

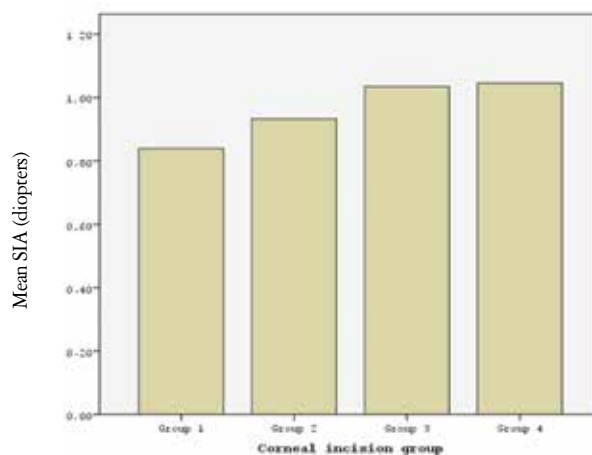
Each group was divided into tertiles according to preoperative K values. In group 1, the mean SIA was  $0.93 \pm 0.4$  D in the highest K tertile versus  $0.79 \pm 0.4$  D in the lower two tertiles ( $p=0.216$ ). These values were  $1.00 \pm 0.7$  D and  $0.89 \pm 0.5$  D in group 2 ( $p=0.251$ ),  $1.08 \pm 0.7$  D and  $1.00 \pm 0.5$  D in group 3 ( $p=0.436$ ), and  $0.97 \pm 0.6$  D and  $1.07 \pm 0.8$  D in group 4 ( $p=0.384$ ).

In each group, mean SIA values in eyes with grade I-II nuclear hardness and grade III-IV nuclear hardness were compared. In group 1, SIA was  $0.75 \pm 0.4$  D in grade I-II versus  $0.92 \pm 0.5$  D in grade III-IV ( $p=0.129$ ). These values were  $0.83 \pm 0.5$  D and  $1.01 \pm 0.5$  D in group 2 ( $p=0.032$ ),  $0.96 \pm 0.6$  D and  $1.07 \pm 0.7$  D in group 3 ( $p=0.265$ ), and  $1.00 \pm 0.7$  D and  $1.08 \pm 0.8$  D in group 4 ( $p=0.470$ ).

## Discussion

With the steady reduction of corneal incision sizes and the realization that astigmatism may be corrected during the procedure, cataract surgery is increasingly accepted as a refractive surgery as well as a sight-restoring operation. Accordingly, patients' expectations of having excellent uncorrected near and distance vision postoperatively are increasing. However, SIA impacts both best visual acuity and visual rehabilitation time and continues to be a major concern for surgeons, who have attempted to minimize the problem by adjusting the location and size of the corneal incisions.

In the B-MICS procedure, the number of corneal incisions was reduced from the traditional three to two, and their size was reduced from the 2.2-3.2 mm range to 1.5 mm or less. B-MICS provides better anterior chamber stabilization and



**Figure 1.** Comparison of the surgically induced astigmatic changes in the study groups. SIA: Surgically induced astigmatism



**Table 1. Demographic and clinical characteristics of the patients by group**

	Group 1	Group 2	Group 3	Group 4	p
Corneal incision length (mm)	1.6	2.0	2.4	2.8	
Number of patients/eyes	75/83	180/200	179/200	187/200	
Age (years, mean ± SD)	61.5±9.45	61.4±9.39	62.8±8.9	62.9±8.9	0.283
Sex (Female/Male)	33/42	83/97	91/88	99/87	
Preop mean K (D)	43.5±1.59	43.7±1.53	44.02±1.57	43.67±1.72	0.076
Postop mean K (D)	43.4±1.55	43.7±1.54	44.02±1.59	43.7±1.84	0.033
SIA (D)	0.83±0.4	0.93±0.5	1.03±0.6	1.04±0.7	0.05
Nuclear hardness					
Grade I (n, %)	4 (4.8%)	7 (3.5%)	12 (6%)	6 (3%)	
Grade II (n, %)	38 (45.8%)	86 (43%)	68 (34%)	87 (43.5%)	
Grade III (n, %)	30 (36.1%)	88 (44%)	102 (51%)	95 (47.5%)	
Grade IV (n, %)	11 (13.3%)	19 (9.5%)	18 (9%)	12 (6%)	

SD: Standard deviation, K: Keratometry value, Preop: Preoperative, Postop: Postoperative, SIA: Surgically induced astigmatism, D: Diopter

**Table 2. Pairwise comparisons of surgically induced astigmatic changes in groups with different corneal incision lengths (mm)**

	P <sub>1.6≈2.0</sub>	P <sub>1.6≈2.4</sub>	P <sub>1.6≈2.8</sub>	P <sub>2.0≈2.4</sub>	P <sub>2.0≈2.8</sub>	P <sub>2.4≈2.8</sub>
SIA p value	0.681	0.049	0.046	0.650	0.690	0.737

SIA: Surgically induced astigmatism

faster healing. The procedure also creates less damage to tissues adjacent to the cornea and substantially reduces SIA and corneal aberrations.<sup>19,20</sup> Despite the studies that have reported successful outcomes with IOLs that can be implanted through small incisions, these lenses may not be practical due to their excessive cost or lack of multifocal or toric versions. Therefore, corneal incision enlargement may be necessary after B-MICS, which poses a limitation to this method.<sup>8,17</sup>

In this study we evaluated how enlarging the corneal incision not used for phacoemulsification in order to implant the IOL after benefiting from the advantages of B-MICS affects SIA. Masket and Tennen<sup>21</sup> observed corneal curvature stabilization in postoperative week 2 in patients with corneal incisions ≤3 mm. Using this study as a reference, in the current study we used K values from postoperative 1 month to calculate SIA.

Wang et al.<sup>22</sup> evaluated astigmatism resulting from microincision and small incision cataract surgery and found astigmatism values of 0.5±0.5 D for 2.2 mm incisions, 0.6±0.5 D for 2.6 mm incisions and 0.9±0.9 D for 3.0 mm incisions. Although the difference between 2.2 and 2.6 mm was insignificant, there was a significant difference

between 2.2 mm and 3.0 mm. In the same study, the authors concluded that 2.2 mm and 2.6 mm incisions lead to lower SIA and earlier refractive stabilization, thus allowing for more rapid visual rehabilitation. In a study by Can et al.<sup>23</sup> comparing coaxial, micro-coaxial and biaxial MICS, based on the final incision length after IOL implantation, 2.83 mm incision caused astigmatism of 0.46 D, 2.26 mm caused 0.24 D and 1.89 mm caused 0.13 D astigmatism, which was a statistically significant difference. Kaya et al.<sup>24</sup> found that in 25 cases, enlarging the corneal incision from 1.5 mm to 2.0 mm for IOL implantation after phacoemulsification resulted in astigmatism of 0.44±0.36 D. In the present study, although we did not detect a significant difference between the amount of induced astigmatism in eyes that underwent 1.6 mm B-MICS and eyes with incisions enlarged to 2.0 mm, there were significant differences between eyes with 1.6 mm incisions and those with 2.4 mm and 2.8 mm incisions.

Although there are studies reporting no difference between B-MICS, MICS and standard phacoemulsification procedures in terms of effective phaco time, total phaco time and total surgery time, some studies have demonstrated shorter effective phaco time and longer phaco time in B-MICS.<sup>25,26,27,28</sup>

Effective phaco time is shorter and total phaco time is longer with hard cataracts, but no significant differences emerged in our analysis of the association between SIA and cataract severity. Furthermore, we found no significant difference between SIA in eyes with the highest K values versus eyes with lower K values.

## Conclusion

In summary, enlarging corneal incisions up to 2.00 mm to implant the IOL after B-MICS does not significantly increase SIA. However, as incision size increases to 2.8 mm, the difference in SIA becomes significant. Regardless of the need to enlarge small incisions to accommodate IOLs during implantation, having two small incisions in B-MICS provides better control of the anterior chamber and therefore can reduce intraoperative complications. Despite an SIA difference of up to 0.21 D, B-MICS is preferable due to its faster postoperative visual rehabilitation. We believe that the development and widespread availability of IOLs implantable through microincisions will increase the value of B-MICS in cataract surgery.

## Ethics

Ethics Committee Approval: Retrospective study, Informed Consent: Retrospective study.

Peer-review: Externally and internally peer-reviewed.

## Authorship Contributions

Surgical and Medical Practices: Mehmet Tetikoğlu, Celal Yeter, Fırat Helvacıoğlu, Serdar Aktaş, Hacı Murat Sağdıç, Fatih Özcura, Concept: Mehmet Tetikoğlu, Celal Yeter, Fırat Helvacıoğlu, Serdar Aktaş, Hacı Murat Sağdıç, Fatih Özcura, Design: Mehmet Tetikoğlu, Celal Yeter, Fırat Helvacıoğlu, Serdar Aktaş, Hacı Murat Sağdıç, Fatih Özcura, Data Collection or Processing: Mehmet Tetikoğlu, Celal Yeter, Fırat Helvacıoğlu, Serdar Aktaş, Hacı Murat Sağdıç, Fatih Özcura, Analysis or Interpretation: Mehmet Tetikoğlu, Celal Yeter, Fırat Helvacıoğlu, Serdar Aktaş, Hacı Murat Sağdıç, Fatih Özcura, Literature Search: Mehmet Tetikoğlu, Celal Yeter, Fırat Helvacıoğlu, Serdar Aktaş, Hacı Murat Sağdıç, Fatih Özcura, Writing: Mehmet Tetikoğlu, Celal Yeter, Fırat Helvacıoğlu, Serdar Aktaş, Hacı Murat Sağdıç, Fatih Özcura.

Conflict of Interest: No conflict of interest was declared by the authors.

Financial Disclosure: The authors declared that this study received no financial support.

## References

- Jiang HZ. Refraction of cataract surgery with IOL implantation. *Int J Ophthalmol.* 2003;27:293-298.
- Rainer G, Menapace R, Vass C, Annen D, Findl O, Schmetterer K. Corneal shape changes after temporal and superolateral 3.0 mm clear corneal incisions. *J Cataract Refract Surg.* 1999;25:1121-1126.
- Lundstrom M. Endophthalmitis and incision construction. *Curr Opin Ophthalmol.* 2006;17:68-71.
- Dupont-Monod S, Labbe A, Fayol N, Chassignol A, Bourges JL, Baudouin C. In vivo architectural analysis of clear corneal incisions using anterior segment optical coherence tomography. *J Cataract Refract Surg.* 2009;35:444-450.
- Dick HB, Schwenn O, Krummenauer F, Krist R, Pfeiffer N. Inflammation after sclerocorneal versus clear corneal tunnel phacoemulsification. *Ophthalmology.* 2000;107:241-247.
- Wang Y, Xia Y, Liu X, Zheng D, Luo L, Liu Y. Comparison of bimanual and micro-coaxial phacoemulsification with torsional ultrasound. *Acta Ophthalmol.* 2012;90:184-187.
- Agarwal A, Agarwal A, Agarwal S, Narang P, Narang S. Phakonit: phacoemulsification through a 0.9 mm corneal incision. *J Cataract Refract Surg.* 2001;27:1548-1552.
- Cinhüseynoglu N, Celik L, Yaman A, Arikan G, Kaynak T, Kaynak S. Microincisional cataract surgery and Thinoptx rollable intraocular lens implantation. *Graefes Arch Clin Exp Ophthalmol.* 2006;244:802-807.
- Shearing S, Relyea R, Louiza A, Sem A. Routine phacoemulsification through a one-millimeter non-sutured incision. *Cataract.* 1985;2:6-11.
- Socia W, Howard JG, Olson RJ. Microphacoemulsification with WhiteStar: a wound-temperature study. *J Cataract Refract Surg.* 2002;28:1044-1046.
- Donnenfeld ED, Olson RJ, Solomon R, Finger PT, Biser SA, Perry HD, Doshi S. Efficacy and wound-temperature gradient of whitestar phacoemulsification through a 1.2 mm incision. *J Cataract Refract Surg.* 2003;29:1097-1100.
- Olson RJ. Clinical experience with 21-gauge manual microphacoemulsification using Sovereign WhiteStar technology in eyes with dense cataract. *J Cataract Refract Surg.* 2004;30:168-172.
- Tsuneoka H, Shiba T, Takahashi Y. Ultrasonic phacoemulsification using a 1.4 mm incision: clinical result. *J Cataract Refract Surg.* 2002;28:81-86.
- Alio JL Rodriguez-Pratz JL, Vianello A, Galal A. Visual outcome of microincision cataract surgery with implantation of an Acri. Smart lens. *J Cataract Refract Surg.* 2005;31:1549-1556.
- Tsuneoka H, Hayama A, Takahama M. Ultrasmall-incision bimanual phacoemulsification and Acrysoft SA30AL implantation through a 2.2 mm incision. *J Cataract Refract Surg.* 2003;29:1070-1076.
- Fine IH, Hoffman RS, Packer M. Optimizing refractive lens exchange with bimanual microincision phacoemulsification. *J Cataract Refract Surg.* 2004;30:550-554.
- Can İ, Takmaz T, Nacaroglu ŞA, Genç İ, Soyugelen G. Bimanuel küçük kesili katarakt cerrahisi. *Glo-Kat.* 2007;2:227-235.
- Holladay JT, Moran JR, Kezirian GM. Analysis of aggregate surgically induced refractive change, prediction error and intraocular astigmatism. *J Cataract Refract Surg.* 2001;27:61-79.

19. El Kady B, Alió J, Ortiz D, Montalbán R. Corneal aberrations after microincision cataract surgery. *J Cataract Refract Surg.* 2008;34:40-45.
20. Jiang Y, Le Q, Yang J, Lu Y. Changes in corneal astigmatism and high order aberrations after clear corneal tunnel phacoemulsification guided by corneal topography. *J Refract Surg.* 2006;22(Suppl 9):1083-1088.
21. Masket S, Tennen DG. Astigmatic stabilization of 3.0 mm temporal clear corneal cataract incisions. *J Cataract Refract Surg.* 1996;22:1451-1455.
22. Wang J, Zhang EK, Fan WY, Ma JX, Zhao PF. The effect of micro-incision and small-incision coaxial phaco-emulsification on corneal astigmatism. *Clinical and Experimental Ophthalmology.* 2009;37:664-669.
23. Can İ, Takmaz T, Yıldız Y, Bayhan HA, Soyugelen G, Bostancı B. Coaxial, microcoaxial and biaxial microincision cataract surgery: prospective comparative study. *J Cataract Refract Surg.* 2010;36:740-746.
24. Kaya V, Oztürker ZK, Oztürker C, Yaşar O, Sivrikaya H, Ağca A, Yılmaz OE. ThinOptX vs AcrySof: comparison of visual and refractive results, contrast sensitivity, and the incidence of posterior capsule opacification. *Eur J Ophthalmol.* 2007;17:307-314.
25. Kahraman G, Amon M, Franz C, Prinz A, Abela-Formanek C. Intraindividual comparison of surgical trauma after bimanual microincision and conventional small-incision coaxial phacoemulsification. *J Cataract Refract Surg.* 2007;33:618-622.
26. Alio J, Rodriguez-Prats JL, Galal A, Ramzy M. Outcomes of microincision cataract surgery versus coaxial phacoemulsification. *Ophthalmology.* 2005;112:1997-2003.
27. Crema AS, Walsh A, Yamane Y, Nose W. Comparative study of coaxial phacoemulsification and microincision cataract surgery one year follow-up. *J Cataract Refract Surg.* 2007;33:1014-1018.
28. Kurz S, Krummenauer F, Gabriel P, Pfeiffer N, Dick HB. Biaxial microincision versus coaxial small-incision clear cornea cataract surgery. *Ophthalmology.* 2006;113:1818-1826.



# Evaluation of Ocular Surface Health in Patients with Obstructive Sleep Apnea Syndrome

Emine Esra Karaca\*, Hanife Tuba Akçam\*\*, Feyzahan Uzun\*\*\*, Şengül Özdek\*\*\*\*, Tansu Ulukavak Çiftçi\*\*\*\*\*

\*Sorgun State Hospital, Ophthalmology Clinic, Yozgat, Turkey

\*\*Çankırı State Hospital, Ophthalmology Clinic, Çankırı, Turkey

\*\*\*Recep Tayyip Erdoğan University Faculty of Medicine, Department of Ophthalmology, Rize, Turkey

\*\*\*\*Gazi University Faculty of Medicine, Department of Ophthalmology, Ankara, Turkey

\*\*\*\*\*Gazi University Faculty of Medicine, Department of Pulmonary Diseases, Ankara, Turkey

## Summary

**Objectives:** To evaluate ocular surface health in obstructive sleep apnea syndrome (OSAS) and to investigate the tendency of these patients toward dry eyes.

**Materials and Methods:** Fifty patients who underwent polysomnography and were diagnosed with OSAS and 50 normal control subjects were compared with respect to ocular surface disease index (OSDI), Schirmer I test and tear film break-up time (TBUT) values.

**Results:** Patients were grouped as mild (n=15, 30%), moderate (n=15, 30%) and severe (n=20, 40%) according to apnea-hypopnea index values. The right eyes of patients were included in both groups. OSDI values were as follows: control group,  $18.7 \pm 8.5$ ; mild OSAS group,  $40.2 \pm 2.8$ ; moderate OSAS group,  $48.5 \pm 2.2$  and severe OSAS group,  $62.7 \pm 2.3$  ( $p < 0.001$ ). TBUT values were as follows: control group,  $12.3 \pm 4.9$ ; mild OSAS group,  $8.2 \pm 4.7$ ; moderate OSAS group,  $5.8 \pm 2.1$  and severe OSAS group,  $4.2 \pm 3.7$  ( $p < 0.001$ ). Schirmer values were as follows: control group,  $18 \pm 6.1$  mm; mild OSAS group,  $12.9 \pm 6.7$  mm; moderate OSAS group,  $8.5 \pm 5.2$  mm and severe OSAS group,  $7.9 \pm 4.7$  mm ( $p < 0.001$ ).

**Conclusion:** Patients with OSAS seem to have a tendency toward dry eyes. Clinicians should be aware of dry eye development in these patients.

**Keywords:** Dry eye, obstructive sleep apnea syndrome, ocular surface health

## Introduction

Obstructive sleep apnea syndrome (OSAS) is characterized by repeated episodes of complete or partial obstruction of the upper respiratory tract during sleep.<sup>1</sup> Left untreated, OSAS can lead to many medical complications and even death.<sup>2</sup> The gold standard in OSAS diagnosis is polysomnography (PSG). Studies have demonstrated associations between OSAS and Floppy eyelid syndrome (FES), nonarteritic ischemic optic neuropathy, glaucoma, pseudotumor cerebri and various corneal problems.<sup>3,4,5,6,7,8,9</sup> OSAS patients have been observed to exhibit FES, papillary conjunctivitis, punctate corneal epitheliopathy, recurrent corneal erosion, keratitis and keratoconus.<sup>3,4,5,9,10</sup> FES has been the focus of many studies, which attributed

the development of dry eye to the inflammatory etiology of OSAS.<sup>4,11</sup> The aim of this study was to investigate the ocular surface health of patients with OSAS and evaluate their tendency toward dry eyes.

## Materials and Methods

Eighty patients who presented to the Gazi University Department of Chest Diseases Sleep Center outpatient clinic for snoring and excessive daytime sleepiness underwent an overnight PSG test and ophthalmological examination. Fifty patients with apnea-hypopnea index (AHI) values over 5 based on their PSG results were included in the study group. Individuals with no complaints like excessive daytime sleepiness, snoring, or obstructive apnea<sup>12</sup> and no known systemic or ocular diseases

**Address for Correspondence:** Emine Esra Karaca MD, Sorgun State Hospital, Ophthalmology Clinic, Yozgat, Turkey

Phone: +90 536 878 22 36 E-mail: emineesra@yahoo.com **Received:** 01.06.2015 **Accepted:** 13.08.2015

This article is also published in Turkish under doi:10.4274/tjo.57778 pages 2016;46:104-108.



were chosen for the control group. The study was approved by the Gazi University Faculty of Medicine Ethics Committee. Aside from apnea, patients in the OSAS group had no systemic or ocular diseases. Twenty-five patients with FES and 5 patients with systemic or ocular disease were excluded from the study. A total of 50 OSAS patients and 50 control subjects were included in the study. OSAS severity was determined based on PSG results as follows: mild, AHI values of 5-15; moderate, AHI values of 15-30; severe, AHI values  $\geq 30$ .

Before starting continuous positive airway pressure (CPAP) treatment, patients underwent a complete ophthalmological examination including visual acuity assessment, slit-lamp examination, intraocular pressure (IOP) measurement and funduscopy. In addition to the routine eye exam, patients responded to the ocular surface disease index (OSDI) questionnaire, and their Schirmer I test scores and tear film break-up times (TBUT) were recorded. The study participants' right eyes were included for both groups.

The OSDI questionnaire consists of three main sections concerning ocular symptoms, visual function and environmental factors.<sup>13</sup> Each item on the questionnaire is scored from 0 to 4 points. The OSDI score is obtained by summing the points received from the 12 items, multiplying by 25, then dividing by the number of questions answered.<sup>14</sup>

The Schirmer I test was performed by placing a 5x35 mm strip of standard filter paper in the lower eyelid one-third of the distance from the lateral canthus and recording the distance wetted in mm after 5 minutes. TBUT was evaluated by examining the fluorescein-stained tear film with biomicroscope with cobalt blue light and measuring the time between a blink and the first appearance of a dry spot.

All statistical analyses and calculations were done with SPSS version 15.0 (SPSS Inc., Chicago, IL, USA) software package. Descriptive statistics are expressed as mean  $\pm$  standard deviation. The Shapiro-Wilk test to determine normality of distribution showed the data were not normally distributed. The chi-square test was used in comparisons of qualitative data; the Mann-Whitney U test was used in comparisons of quantitative data. Spearman correlation analysis was used to detect associations between variables. Results of all statistical analyses were evaluated within a 95% confidence interval and p values less than 0.05 were accepted as significant.

## Results

Of the 50 OSAS patients in the study, 39 (78%) were male, 11 (22%) were female and the mean age was  $48.01 \pm 10.8$  (range, 19-68) years. Of the 50 control subjects, 28 (56%) were male, 22 (44%) were female and the mean age was  $46.9 \pm 12.2$  (range, 32-75) years. There were no significant differences between the groups in terms of age or sex ( $p=0.07$ , Kruskal-Wallis H test;  $p=0.06$ , Pearson chi-square test, respectively). According to AHI scores, OSAS was mild in 15 patients (30%), moderate in 15 patients (30%) and severe in 20 patients (40%) (Table 1).

The mean OSDI scores, TBUTs and Schirmer test values of the OSAS and control groups are presented in Table 2. OSDI score was  $18.7 \pm 8.5$  in the control group versus  $40.2 \pm 2.8$  in mild OSAS,  $48.5 \pm 2.2$  in moderate OSAS and  $62.7 \pm 2.3$  in severe OSAS groups; the difference between groups was significant ( $p < 0.001$ ).

TBUT values were  $12.3 \pm 4.9$  s in the control group and  $8.2 \pm 4.7$  s,  $5.8 \pm 2.1$  s and  $4.2 \pm 3.7$  s in the mild, moderate and severe OSAS groups, respectively; the difference between groups was significant ( $p < 0.001$ ). Schirmer test values were  $18 \pm 6.1$  mm in the control group versus  $12.9 \pm 6.7$  mm,  $8.5 \pm 5.2$  mm and  $7.9 \pm 4.7$  mm in the mild, moderate and severe OSAS groups, respectively; this intergroup difference was also significant ( $p < 0.001$ ).

Body mass index (BMI), AHI severity, and mean oxygen saturation, lowest oxygen saturation and arousal index scores acquired during PSG were significantly correlated with OSDI scores, TBUT and Schirmer test values ( $p < 0.001$ ) (Table 3).

## Discussion

The tear film layer has a complex structure, and normal functioning of the various lacrimal functional unit components is necessary for a healthy tear film layer and ocular surface.<sup>15,16</sup> Both local and systemic diseases can affect normal tear function and lead to dry eye. The systemic diseases most often accompanied by dry eye are Sjögren's syndrome and rheumatoid arthritis.<sup>17,18</sup> Besides autoimmune diseases, dry eye can also be caused by many other systemic diseases including diabetes mellitus, multiple sclerosis and vitamin A deficiency.<sup>19,20</sup> In the present study we applied the OSDI, Schirmer test and TBUT analysis in order to evaluate the tendency of OSAS patients toward dry eyes.

Dry eye increases with age and is among the diseases that limit daily activities and seriously impact quality of life due to visual impairment and ocular discomfort.<sup>21</sup> In dry eye, increased tear osmolarity and inflammation cause ocular surface damage.<sup>22</sup> The lacrimal functional unit consists of the main and accessory lacrimal glands, cornea and conjunctival epithelium, eyelids and meibomian glands; dysfunction in any one of these components can lead to reduced tear production, tear film layer instability and increased tear osmolarity, resulting in ocular surface damage characterized by ocular discomfort and inflammation.<sup>21</sup> Inflammation plays a key role in the pathogenesis of dry eye, which is an inflammatory disease of the lacrimal glands and ocular surface.<sup>22,23</sup> The ocular surface inflammation seen in dry eye typically develops as a result of increased tear osmolarity, accumulation of proinflammatory cytokines secreted by the lacrimal glands on the ocular surface and delayed clearing by tears.<sup>21</sup> In OSAS, levels of proinflammatory cytokines like tumor necrosis factor alpha, interleukin-1 and interleukin-6 are elevated due to chronic intermittent hypoxia.<sup>24</sup> Cytokines released from dilated conjunctival vessels and damaged epithelium cells create a continual state of inflammation.<sup>25</sup> As OSAS patients' AHI increases, so do mechanical tissue stress, hypoxia levels and ocular surface inflammation, which in turn cause meibomian and goblet

**Table 1. Patients' demographic, polysomnographic and ophthalmologic characteristics according to apnea-hypopnea index**

		Control (n=50)	Mild OSAS (n=15)	Moderate OSAS (n=15)	Severe OSAS (n=20)	p value
Gender (n, %)	Female	22 (44)	6 (40)	2 (13)	3 (15)	0.06 <sup>a</sup>
	Male	28 (56)	9 (60)	13 (87)	17 (85)	
Age (years)		46.9±12.2 (32-75)	42.1±10.8 (19-64)	52.6±10.6 (29-68)	49.1±9.2 (35-65)	0.07 <sup>b</sup>
BMI		25.9±3.6 (20-35)	26.5±3.2 (22-33)	31.1±4.5 (24-39)	32.7±4.9 (28-48)	<0.001 <sup>b</sup>
AHI		2.38±1.3 (0-4.7)	12.1±3.3 (6-15)	26.7±3.7 (20-30)	62.2±20.5 (38-106)	<0.001 <sup>b</sup>
mSO <sub>2</sub>		93.7±1.9 (90-97)	93.1±1.5 (91-96)	90.8±2.8 (86-96)	89.3±3.9 (76-93)	<0.001 <sup>b</sup>
LSAT		89.3±2.4 (83-94)	85.2±4.6 (75-92)	79.4±7.2 (66-91)	72.6±10.8 (46-84)	<0.001 <sup>b</sup>
TBUT (s)		12.3±4.9 (5-18)	8.2±4.7 (1-16)	5.8±2.1 (2-8)	4.2±3.7 (1-12)	<0.001 <sup>b</sup>
Schirmer test (mm)		18±6.1 (8-27)	12.9±6.7 (3-26)	8.5±5.2 (5-25)	7.9±4.7 (3-15)	<0.001 <sup>b</sup>
OSDI Score		18.7±8.5 (6-58)	40.2±2.8 (2-90)	48.5±2.2 (4-75)	62.7±2.3 (11-88)	<0.001 <sup>b</sup>

<sup>a</sup>Pearson's chi-square test, <sup>b</sup>Kruskal-Wallis H test  
 OSAS: Obstructive sleep apnea syndrome, n: Number of patients, BMI: Body mass index, AHI: Apnea-hypopnea index, mSO<sub>2</sub>: Mean oxygen saturation, LSAT: Lowest oxygen saturation, TBUT: Tear film break-up time, OSDI: Ocular surface disease index

**Table 2. Statistical differences between groups**

	Mild OSAS-control	Moderate OSAS-control	Severe OSAS-control	Mild-moderate OSAS	Mild-severe OSAS	Moderate-severe OSAS
TBUT (s)	0.007	<0.001	<0.001	0.23	0.009	0.04
Schirmer test (mm)	0.02	<0.001	<0.001	0.04	0.02	0.61
OSDI score	0.02	<0.001	<0.001	0.23	0.01	0.05

Mann-Whitney U test with Bonferroni correction; p<0.016 was accepted as statistically significant  
 OSAS: Obstructive sleep apnea syndrome, TBUT: Tear film break-up time, OSDI: Ocular surface disease index

**Table 3. Correlation coefficients and significance values between obstructive sleep apnea syndrome and dry eye parameters**

	TBUT		Schirmer test		OSDI score	
	ρ	p <sup>a</sup>	ρ	p <sup>a</sup>	ρ	p <sup>a</sup>
Gender	-0.19	0.06	-0.16	0.09	0.23	0.03
Age	-0.22	0.02	-0.17	0.08	0.13	0.19
BMI	-0.38	<0.001	-0.35	<0.001	0.41	<0.001
AHI	-0.56	<0.001	-0.52	<0.001	0.64	<0.001
mSO <sub>2</sub>	0.41	<0.001	0.46	<0.001	-0.48	<0.001
LSAT	0.52	<0.001	0.49	<0.001	-0.59	<0.001
Arousal index	-0.41	<0.001	-0.35	<0.001	0.53	<0.001

<sup>a</sup>Spearman's correlation; p<0.016 was accepted as statistically significant, ρ (rho): Correlation coefficient, p: p value  
 TBUT: Tear film break-up time, OSDI: Ocular surface disease index, BMI: Body mass index, AHI: Apnea-hypopnea index, mSO<sub>2</sub>: Mean oxygen saturation, LSAT: Lowest oxygen saturation

cell function loss, decreased corneal sensitivity and reduced tear production in response to stimulation to the lacrimal glands.<sup>11</sup> The loss of meibomian glands and conjunctival goblet cells is reflected clinically as a deterioration in tear film quality.<sup>11</sup>

The OSDI questionnaire is easily applied and is one of the standard methods for symptom assessment and diagnosis in dry eye syndrome.<sup>13,26</sup> The Turkish translation of the OSDI is reliable<sup>27</sup> and is currently used in practice and research. In

the present study, OSDI scores were significantly higher in the moderate and severe OSAS groups compared to the control group ( $p < 0.001$ ). In the only other study conducted on this topic, Acar et al.<sup>11</sup> also found significantly higher OSDI scores in the severe OSAS group. In their study, the high OSDI scores were associated with reduced TBUT.<sup>11</sup> Similarly, we found that all OSAS severity groups exhibited significantly shorter TBUT compared to controls ( $p < 0.016$ ). Mojon et al.<sup>4</sup> investigated eyelid, conjunctival and corneal findings in 72 OSAS patients and observed reductions in the TBUT of OSAS patients. We also found that Schirmer test results were significantly lower in the moderate and severe OSAS groups compared to the control group ( $p < 0.001$ ). Furthermore, significant positive correlations emerged between OSDI score and both AHI and BMI. As AHI and BMI increased, TBUT and Schirmer values fell significantly.

The assessment of eyelid problems and ocular surface health in OSAS patients has attracted the attention of some researchers. In particular, the frequency of FES in OSAS patients and the pronounced dry eye symptoms that occur in these patients have led to research focusing on OSAS patients with FES.<sup>28,29,30</sup> Mojon et al.<sup>4</sup> detected a positive correlation between respiratory distress index and the frequency of FES. Similarly, Acar et al.<sup>11</sup> found that increasing AHI was positively correlated with frequency of FES. Some studies have reported OSAS and FES coinciding at very low rates (4.5-5%).<sup>30,31</sup> In order to avoid FES as a confounding factor in our study, we excluded these patients.

This study focused on patients newly diagnosed with OSAS and included only patients who were not being treated with CPAP. Patients undergoing CPAP therapy may experience ocular complications such as dryness and irritation due to air escaping from the mask.<sup>32</sup> Furthermore, air exposure through the mouth and nose can lead to bacterial conjunctivitis.<sup>33</sup>

A novel aspect of this study is the exclusion of patients with FES, which frequently accompanies OSAS. Even without FES, our results indicate that OSAS patients have a tendency toward dry eyes. Therefore, clinicians should be aware of the possibility of dry eye development in OSAS patients. Studies with larger patient groups are necessary to further our understanding of the pathogenesis of the disease.

#### Ethics

Ethics Committee Approval: The study was approved by the Gazi University Faculty of Medicine Ethics Committee, Informed Consent: It was taken.

Peer-review: Externally peer-reviewed.

#### Authorship Contributions

Surgical and Medical Practices: Emine Esra Karaca, Hanife Tuba Akçam, Feyzahan Uzun, Şengül Özdek, Tansu Ulukavak Çiftçi, Concept: Emine Esra Karaca, Hanife Tuba Akçam, Feyzahan Uzun, Şengül Özdek, Tansu Ulukavak Çiftçi, Design: Emine Esra Karaca, Hanife Tuba Akçam, Feyzahan Uzun, Şengül Özdek, Tansu Ulukavak Çiftçi, Data Collection or Processing: Emine Esra Karaca, Hanife Tuba Akçam, Feyzahan Uzun, Şengül Özdek, Tansu Ulukavak Çiftçi, Analysis or Interpretation:

Emine Esra Karaca, Hanife Tuba Akçam, Feyzahan Uzun, Şengül Özdek, Tansu Ulukavak Çiftçi, Literature Search: Emine Esra Karaca, Hanife Tuba Akçam, Feyzahan Uzun, Şengül Özdek, Tansu Ulukavak Çiftçi, Writing: Emine Esra Karaca, Hanife Tuba Akçam, Feyzahan Uzun, Şengül Özdek, Tansu Ulukavak Çiftçi.

Conflict of Interest: No conflict of interest was declared by the authors.

Financial Disclosure: The authors declared that this study received no financial support.

#### References

1. Olson EJ, Park JG, Morgenthaler TI. Obstructive sleep apnea-hypopnea syndrome. *Prim Care*. 2005;32:329-359.
2. Guilleminault C, Abad VC. Obstructive sleep apnea syndromes. *Med Clin North Am*. 2004;88:611-630.
3. Culbertson WW, Ostler HB. The floppy eyelid syndrome. *Am J Ophthalmol*. 1981;92:568-575.
4. Mojon DS, Goldblum D, Fleischhauer J, Chiou AG, Frueh BE, Hess CW, Gugger M, Bassetti C, Boehnke M, Mathis J. Eyelid, conjunctival, and corneal findings in sleep apnea syndrome. *Ophthalmology*. 1999;106:1182-1185.
5. Waller EA, Bendel RE, Kaplan J. Sleep disorders and the eye. *Mayo Clin Proc*. 2008;83:1251-1261.
6. Li J, McGwin G Jr, Vaphiades MS, Owsley C. Non-arteritic anterior ischaemic optic neuropathy and presumed sleep apnoea syndrome screened by the Sleep Apnea scale of the Sleep Disorders Questionnaire (SA-SDQ). *Br J Ophthalmol*. 2007;91:1524-1527.
7. Mojon DS, Hess CW, Goldblum D, Fleischhauer J, Koerner F, Bassetti C, Mathis J. High prevalence of glaucoma in patients with sleep apnea syndrome. *Ophthalmology*. 1999;106:1009-1012.
8. Jindal M, Hiam L, Raman A, Rejali D. Idiopathic intracranial hypertension in otorhinolaryngology. *Eur Arch Otorhinolaryngol*. 2009;266:803-806.
9. Culbertson WW, Tseng SC. Corneal disorders in floppy eyelid syndrome. *Cornea*. 1994;13:33-42.
10. Negrís R. Floppy eyelid syndrome associated with keratoconus. *J Am Optom Assoc*. 1992;63:316-319.
11. Acar M, Firat H, Acar U, Ardic S. Ocular surface assessment in patients with obstructive sleep apnea-hypopnea syndrome. *Sleep Breath*. 2013;17:583-588.
12. Lin PW, Friedman M, Lin HC, Chang HW, Pulver TM, Chin CH. Decreased retinal nerve fiber layer thickness in patients with obstructive sleep apnea/hypopnea syndrome. *Graefes Arch Clin Exp Ophthalmol*. 2011;249:585-593.
13. Schiffman RM, Christianson MD, Jacobsen G, Hirsch JD, Reis BL. Reliability and validity of the ocular surface disease index. *Arch Ophthalmol*. 2000;118:615-621.
14. Walt J. Ocular surface disease index (OSDI) administration and scoring manual. Irvine, CA: Allergan; Inc; 2004.
15. Rolando M, Zierhut M. The ocular surface and tear film and their dysfunction in dry eye disease. *Surv Ophthalmol*. 2001;45(Suppl 2):203-210.
16. Tseng SC, Tsubota K. Important concepts for treating ocular surface and tear disorders. *Am J Ophthalmol*. 1997;124:825-835.
17. Akpek EK, Klimava A, Thorne JE, Martin D, Lekhanont K, Ostrovsky A. Evaluation of patients with dry eye for presence of underlying Sjogren syndrome. *Cornea*. 2009;28:493-497.
18. McCluskey P, Powell RJ. The eye in systemic inflammatory diseases. *Lancet*. 2004;364:2125-2133.
19. Viso E, Rodriguez-Ares MT, Gude F. Prevalence of and associated factors for dry eye in a Spanish adult population (the Salnes Eye Study). *Ophthalmic Epidemiol*. 2009;16:15-21.
20. Wang TJ, Wang JJ, Hu CC, Lin HC. Comorbidities of dry eye disease: a nationwide population-based study. *Acta Ophthalmol*. 2012;90:663-668.

21. Bozkurt B, İrkeç M. Kuru gözün fizyopatolojisi. *Turkiye Klinikleri J Ophthalmol Special Topics*. 2013;6:1-7.
22. No authors listed. The definition and classification of dry eye disease: report of the Definition and Classification Subcommittee of the International Dry Eye Workshop. *Ocul Surf*. 2007;5:75-92.
23. Pflugfelder SC, Solomon A, Stern ME. The diagnosis and management of dry eye: a twenty-five-year review. *Cornea*. 2000;19:644-649.
24. Ciftci TU, Kokturk O, Bukan N, Bilgihan A. The relationship between serum cytokine levels with obesity and obstructive sleep apnea syndrome. *Cytokine*. 2004;28:87-91.
25. Stern ME, Gao J, Schwalb TA, Ngo M, Tieu DD, Chan CC, Reis BL, Whitcup SM, Thompson D, Smith JA. Conjunctival T-cell subpopulations in Sjögren's and non-Sjögren's patients with dry eye. *Invest Ophthalmol Vis Sci*. 2002;43:2609-2614.
26. Ozcura F, Aydin S, Helvacı MR. Ocular surface disease index for the diagnosis of dry eye syndrome. *Ocul Immunol Inflamm*. 2007;15:389-393.
27. Irkeç M. Reliability and validity of Turkish translation of the Ocular Surface Disease Index (OSDI) in dry eye syndrome. *Invest Ophthalmol Vis Sci*. 2007;48:408-610.
28. McNab AA. The eye and sleep apnea. *Sleep Med Rev*. 2007;11:269-276.
29. Bilenchi R, Poggiali S, Pisani C, De Aloe G, Motolese PA, Motolese E, Rottoli P, Lombardi C, Rocchi R, Firmiani M. Floppy eyelid syndrome associated with obstructive sleep apnoea. *Br J Dermatol*. 2004;151:706.
30. McNab AA. Floppy eyelid syndrome and obstructive sleep apnea. *Ophthalm Plast Reconstr Surg*. 1997;13:98-114.
31. Karger RA, White WA, Park WC, Rosales AG, McLaren JW, Olson EJ, Woog JJ. Prevalence of floppy eyelid syndrome in obstructive sleep apnea-hypopnea syndrome. *Ophthalmology*. 2006;113:1669-1674.
32. Hayirci E, Yagci A, Palamar M, Basoglu OK, Veral A. The effect of continuous positive airway pressure treatment for obstructive sleep apnea syndrome on the ocular surface. *Cornea*. 2012;31:604-608.
33. Stauffer JL, Fayter N, MacLurg BJ. Conjunctivitis from nasal CPAP apparatus. *Chest*. 1984;86:802.





# Clinical Features and Prognosis of Herpetic Anterior Uveitis

Esra Kardeş, Kansu Bozkurt, Betül İlkey Sezgin Akçay, Cihan Ünlü, Tuğba Aydoğan Gezginaslan, Ahmet Ergin  
Ümraniye Training and Research Hospital, Ophthalmology Clinic, İstanbul, Turkey

## Summary

**Objective:** To evaluate clinical features, complications, visual outcomes and treatment modalities in patients clinically diagnosed with herpetic anterior uveitis (AU).

**Materials and Methods:** We retrospectively reviewed the medical records of 67 patients seen at the Ümraniye Training and Research Hospital, Ophthalmology Clinic, Uveitis and Cornea Department from January 2009 to June 2013.

**Results:** Thirty-seven patients (55.2%) were female and 30 (44.7%) patients were male. The average follow-up period was  $12.9 \pm 10.6$  months (range: 1-45 months). The most common ocular findings were granulomatous keratic precipitates (KPs) (82.2%), corneal involvement (62.6%), iris atrophy (41.7%) and transient elevated intraocular pressure (IOP) (40.2%). Recurrences were observed in 46.2% of the eyes and the median recurrence rate was 1.0 during the follow-up period. Topical steroids and oral antiviral (acyclovir) therapy were applied to all patients during active episodes. Long-term oral acyclovir was used in 29.8% of the patients. Recurrence rates were significantly lower in patients who used oral acyclovir for more than 6 months, whereas complications rates and final visual acuity did not show any difference between groups. Final visual acuity was better than 20/40 in 61.1% of eyes, and visual impairment was due to corneal scarring or cataract formation.

**Conclusion:** Herpetic AU can present with or without corneal involvement. Granulomatous KPs, iris atrophy and elevated IOP are important clinical findings for the diagnosis of cases without corneal involvement. Long-term oral acyclovir treatment (more than 6 months) and is important to decrease recurrence rates and possible complications. Visual prognosis is favorable in cases without corneal scarring.

**Keywords:** Elevated intraocular pressure, granulomatous keratic precipitates, herpetic anterior uveitis, iris atrophy, oral acyclovir

## Introduction

Herpetic anterior uveitis (AU) is a major cause of infectious AU in both developed and developing countries<sup>1</sup> and accounts for 5% to 10% of all uveitis cases seen at referral centers.<sup>2,3,4</sup> Several molecular techniques have been used to identify causative agents, which include herpes simplex virus, varicella zoster virus and cytomegalovirus (CMV).<sup>5,6,7</sup> However for both accessibility and economic reasons, characteristic clinical findings give the most important clues in the diagnosis of herpetic AU. It is possible to decrease recurrences and prevent vision-threatening complications such as keratitis, glaucoma and cataract in herpetic AU with an early and accurate diagnosis. In the present study, we describe the clinical findings which are helpful in the diagnosis of herpetic AU and analyze its complications,

treatment modalities and visual outcomes in a tertiary referral center.

## Materials and Methods

We retrospectively analyzed the medical records of 67 patients clinically diagnosed with herpetic AU at the Uveitis and Cornea Service of the Ümraniye Training and Research Hospital from January 2009 to June 2013. Institutional Review Board approval and informed consent from each patient was obtained for the study.

A detailed ocular and medical history was obtained from all patients. A complete ocular examination including best-corrected Snellen visual acuity, slit-lamp biomicroscopy, tonometry and indirect ophthalmoscopy was performed at each visit. Anterior

**Address for Correspondence:** Esra Kardeş MD, Ümraniye Training and Research Hospital, Ophthalmology Clinic, İstanbul, Turkey

Phone: +90 532 775 25 54 E-mail: esrakardes13@gmail.com **Received:** 30.01.2015 **Accepted:** 06.07.2015

This article is also published in Turkish under doi:10.4274/tjo.92053 pages 2016;46:109-113.

segment photography was performed when indicated. SUN criteria were used for reporting our clinical data.<sup>8</sup> In patients without corneal disease, the diagnosis of herpetic AU was based on clinical findings such as recurrent unilateral inflammatory attacks in the same eye, acute elevation of the intraocular pressure (IOP) (IOP>22 mmHg) during inflammatory episodes, diffusely distributed or localized granulomatous keratic precipitates (KPs), patchy or sectoral iris atrophy with or without transillumination defects and distorted pupil or spiraling of the iris.<sup>9</sup>

Other causes of infectious or non-infectious uveitis were excluded in patients who did not have corneal involvement or the typical iris atrophy at presentation. A diagnostic workup including complete blood count, liver and kidney function tests, human leukocyte antigen-B27 typing, syphilis serology, chest X-ray, tuberculin skin test and serum angiotensin converting enzyme assay was performed on each patient.

During active AU episodes, patients received oral antiviral treatment (acyclovir), topical anti-inflammatory treatment (topical prednisolone acetate) and/or topical mydriatic agents (tropicamide 1%, cyclopentolate 1% eye drops). Anti-glaucomatous therapy, including topical beta-blockers, alpha-adrenergic agonists and topical or oral carbonic anhydrase inhibitors was initiated in indicated patients. Patients clinically diagnosed with herpetic AU were treated with oral acyclovir 800 mg 3-5 times per day during the active episode and oral acyclovir dosage was maintained at 800 mg daily after the first attack. Once the inflammation was under control, topical corticosteroids were gradually tapered over several months. In order to control inflammation, a long-term, low dose topical steroid (one drop every other day) was continued in patients who showed recurrences after drug cessation. Topical acyclovir ointment was administered to patients with active dendritic keratitis and topical corticosteroids were initiated after epithelial keratitis healed.

Patient demographic features, ocular findings, complications, treatment regimens, recurrences, visual acuity and follow-up period were retrospectively analyzed.

Data were analyzed with SPSS version 22 statistical analysis software (SPSS Inc., Chicago, USA) Student's t-test was used for comparisons between two groups of parameters showing normal distribution and the Mann Whitney U-test was used for those parameters not showing normal distribution. In the comparison of qualitative data, Fisher's exact test and Yates Continuity Correction test were used. Levels of significance were accepted as  $p < 0.05$ .

## Results

Our study included 67 eyes of 67 patients. Thirty-seven patients (55.2%) were female and 30 (44.8%) patients were male. The mean age at presentation was  $38.5 \pm 18.1$  years (range: 3-82 years). The average follow-up period was  $14.9 \pm 8.6$  months (range: 6-45 months). All patients had unilateral involvement. At presentation and during follow-up, 25 eyes (37.3%) had AU without corneal involvement and 42 eyes (62.6%) had AU with

corneal involvement. Of these 42 eyes, 25 (59.5%) exhibited stromal keratitis or endotheliitis, 10 (23.8%) had corneal scarring, 5 (11.9%) had epithelial keratitis and 2 (4.7%) had limbal vasculitis. Of the 67 patients, 30 had been diagnosed with uveitis elsewhere and herpetic AU had been diagnosed in 11 (36.6%) of these before referral to our clinic. Corneal involvement was present in all patients who were referred with the correct diagnosis.

During the follow-up period, a total 120 acute episodes (67 at presentation and 53 during follow-up) were recorded in 67 eyes. The clinical findings at each visit were recorded from patient charts. Granulomatous KPs were the most common findings and were recorded in 55 eyes (82%) at least once during follow-up. Granulomatous KPs are medium to large size (mutton fat) (Figure 1) and scattered diffusely or localized under corneal lesions. Fine KPs were observed in the remaining 12 eyes during follow-up. An IOP higher than 21 mmHg during at least one visit was observed in 27 eyes (40.2%). Short-term anti-inflammatory and anti-glaucomatous therapy was applied and IOP was normalized in 19 eyes. Continuous anti-glaucomatous therapy was required in the remaining 8 eyes (11.9%) and 2 of them underwent trabeculectomy. At the final visit, patchy or sectoral iris atrophy was seen in 28 eyes (41.7%) and transillumination defects (Figure 2) were present in 10 eyes (14.9%). Pupil distortion without posterior synechiae was observed in 24 eyes (35.8%). Posterior synechiae were noted in 9 eyes (13.4%) and posterior subcapsular cataract developed in 7 eyes (10.4%) (Table 1).

The median recurrence rate during the follow-up period was 1.0. There was no recurrence in 36 eyes during the follow-up period, while 31 eyes (46.2%) had a total of 53 recurrences. Of the 53 recurrences, 31 (58.4%) exhibited AU, 16 (30.1%) keratouveitis, and 6 (11.3%) keratitis.

Topical corticosteroids were administered to all patients and maintained in 20 patients at very low doses for more than 6 months. The patients with active dendritic keratitis were treated first with topical acyclovir; if uveitis was present, topical steroids were added after the epithelial lesions healed. One patient with dense mutton fat granulomatous KPs received

**Table 1. Ocular findings and complications in 67 eyes clinically diagnosed with herpetic anterior uveitis**

Findings/complications	Number (%) of eyes
Granulomatous keratic precipitates	55 (82.2%)
Corneal involvement	42 (62.6%)
Iris atrophy ± transillumination	28 (41.7%)
Transient IOP elevation	27 (40.2%)
Pupil distortion without synechia	24 (35.8%)
Posterior synechia	9 (13.4%)
Permanent IOP elevation	8 (11.9%)
Posterior subcapsular cataract	7 (10.4%)
IOP: Intraocular pressure	

short-term oral corticosteroid therapy. Oral acyclovir treatment was administered to all patients during active keratouveitis and uveitis episodes and was used for more than 6 months in 20 patients (29.8%). Recurrence rates, complication rates, and final visual acuity were compared between patients who were under oral acyclovir treatment for shorter and longer than 6 months. Recurrence rates were significantly lower in patients who used oral acyclovir for more than 6 months, whereas complication rates and final visual acuity did not show any differences between groups (Table 2). Oral acyclovir treatment was discontinued in 8 patients who showed no recurrences during at least 1 year of treatment. Five of these patients experienced recurrences after drug cessation.

Visual acuity at the initial visit was >20/40 in 28 eyes (41.7%), whereas visual acuity at the final visit was >20/40 in 41 eyes (61.1%). Visual acuity less than 20/40 was due to corneal scars in 19 eyes and lens opacity in 7 eyes.

We did not find statistically significant differences in complications and recurrence rates when we compared herpetic AU eyes with or without corneal involvement ( $p>0.05$ ) (Table 3).

**Table 2. Comparison of recurrence rates, complication rates and visual improvement between patients who were under oral acyclovir treatment for shorter or longer than 6 months**

	Oral acyclovir treatment		p value†
	>6 months (n=20) (%)	<6 months (n=47) (%)	
Transient IOP elevation	7 (35%)	20 (42.5%)	0.564
Iris atrophy ± transillumination	5 (25%)	23 (48.9%)	0.069
Pupil distortion without synechia	5 (25%)	19 (40.4%)	0.228
Posterior synechia	2 (10%)	7 (14.8%)	0.590
Persistent IOP elevation	2 (10%)	6 (12.7%)	0.749
Posterior subcapsular cataract	3 (15%)	4 (8.5%)	0.426
Recurrence	5 (25%)	26 (55.3%)	0.022*
Final visual acuity ≥20/40	13 (65%)	28 (59.5%)	0.676

†: Fisher's exact test, \*: Statistically significant, IOP: Intraocular pressure

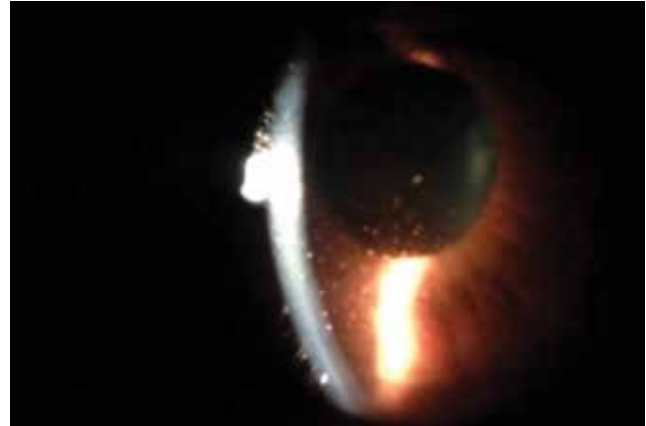**Table 3. Complications in eyes with or without corneal involvement**

	With corneal involvement (n=45)	Without corneal involvement (n=22)	p values
Recurrence rate, mean ± SD (median)	1.23±0.96 (1)	1.37±0.59 (1)	10.336
Complications, n (%)			
Iris atrophy ± transillumination	16 (38%)	12 (48%)	20.138
Pupil distortion without synechia	16 (38%)	8 (32%)	21.000
Posterior synechia	6 (14.2%)	3 (12%)	21.000
Secondary glaucoma	4 (9.5%)	5 (20%)	20.161
Posterior subcapsular cataract	5 (11.9%)	2 (8%)	30.664


n: Number, SD: Standard deviation, 1: Mann-Whitney U test, 2: Continuity correction (Yates') test, 3: Fisher's exact test

## Discussion

Although herpetic eye disease may occur as a result of primary or recurrent infection, herpetic AU usually occurs as a recurrent infection. Viral replication and immunologic response may both have roles in the pathogenesis of herpetic AU.<sup>10,11</sup> Herpetic AU is a clinical diagnosis. Confirmation of the diagnosis relies on



**Figure 1.** Slit-lamp photograph shows large granulomatous keratic precipitates of a patient with herpetic anterior uveitis



**Figure 2.** Slit-lamp photograph shows a transillumination defect in the left eye of a patient with herpetic anterior uveitis

polymerase chain reaction analyses of intraocular fluids, but in clinical practice characteristic clinical features are important for early diagnosis and treatment.

In the current study, corneal involvement was detected in more than half of the patients with herpetic AU and was present in all of the accurately diagnosed referral patients. This result shows that corneal involvement is an important clinical feature that facilitates the diagnosis. However, the large proportion of referred cases without corneal involvement emphasizes the importance of recognition of the other diagnostic clinical features of herpetic AU. In such cases, other clinical findings of the anterior segment should be indicative of herpetic AU. In this study, the most common ocular findings and complications during follow-up were granulomatous KPs, transient IOP elevation and iris atrophy.

The most frequently encountered ocular finding was granulomatous KPs, which were present in 82% of eyes. These granulomatous KPs were scattered diffusely on the posterior surface of the cornea or remained localized under the corneal lesions. Recently two separate publications from Turkey reported different rates of granulomatous KPs. Nalcacioglu-Yüksekkaya et al.<sup>12</sup> found a 38% rate of granulomatous KPs, whereas Tugal-Tutkun et al.<sup>13</sup> found granulomatous KPs in 93% of their patients, which supports our finding.

Inflammation of the trabecular meshwork may lead to a transient increase in IOP. However, long-term use of topical steroids and trabecular meshwork scarring due to chronic and frequent inflammation can cause a persistent increase in IOP. Transient IOP increase was found in 40.2% of our cases and treated with short-term topical anti-glaucomatous therapy. Secondary glaucoma developed in 13.4% of cases and was treated with continuous topical anti-glaucomatous therapy. Glaucoma surgery was performed on two of the secondary glaucoma cases. Different results have been reported from other publications. Van der Lelij et al.<sup>14</sup> reported elevated IOP in 90% of their cases. However, it is not specified whether this elevation was transient or persistent. Although Tugal-Tutkun et al.<sup>13</sup> reported transient IOP elevation in 51% of their cases, only 1.8% of them progressed to secondary glaucoma. In a recent Turkish study, secondary glaucoma was found in 31.8% of subjects.<sup>12</sup> Different approaches in long-term steroid regimens might be an explanation for the variation in the rate of secondary glaucoma in the aforementioned reports.

Patchy or sectoral iris atrophy in herpetic uveitis is associated with transillumination defects. Tugal-Tutkun et al.<sup>13</sup> reported iris atrophy in 48% of patients and Nalcacioglu-Yüksekkaya et al.<sup>12</sup> reported it in 49%, both of which are similar to our rate of 41.7%. There are also other uveitic entities associated with iris atrophy. Diffuse iris atrophy causing loss of the corrugated texture of the iris stroma may develop in Fuchs' Uveitis syndrome (FUS).<sup>15</sup> The chronic course of FUS and diffusely scattered KPs with stellate extensions may be helpful in the differential diagnosis. CMV-related AU may also cause sectoral iris atrophy with recurrent hypertensive attacks. Unlike herpetic AU, refractory glaucoma tends to develop more commonly in CMV AU.<sup>16</sup> Distorted pupils are another clinical feature seen in

herpetic AU. In the current study pupil distortion was observed in 35.8% of cases. Distorted pupils were reported in 20.3% of cases by Nalcacioglu-Yüksekkaya et al.<sup>12</sup> and 25% of cases by Tugal-Tutkun et al.<sup>13</sup>

Oral antiviral agents and topical steroids are the currently used treatment modalities for patients with herpetic AU. The efficacy of prophylactic oral acyclovir is evidenced by a decrease in the number of recurrences of herpetic eye disease.<sup>17</sup> Sudesh and Laibson<sup>18</sup> recommended a daily maintenance dose of acyclovir for a minimum of two years after the first uveitis attack. Similarly, in the current study prophylactic oral acyclovir was initiated in all patients after the first uveitis attack. Nearly half (46.2%) of the patients showed recurrences during a mean follow-up period of 12.9 months. However, we found that recurrence rates were significantly lower in patients who used oral acyclovir treatment for longer than 6 months. Topical steroids were also initiated in all patients with uveitis attacks and tapered very gradually to prevent severe rebound attacks. We tried to find a threshold steroid dosage to maintain remission in some patients and used this low dose regimen as a long-term treatment.

Visual prognosis was favorable in spite of the frequent recurrence rate. In our series, the visual outcome of herpetic AU was  $\geq 20/40$  in 61.1% of eyes. This is similar to the results reported by Nalcacioglu-Yüksekkaya et al.<sup>12</sup> Visual impairment in the current study was associated with corneal scars and lens opacity. In addition, the present study reports the outcomes of both primary diagnoses of herpetic AU in our clinic (37 out of 67) and referred patients with uveitis of unknown etiology (30 out of 67). As a result, we could not include the recurrences and survey of referred patients until the diagnosis. This finding may be evaluated as a weak point of the study since the follow-up period and recurrence rate reported might not represent the real-life experience of patients with herpetic AU.

## Conclusion

Herpetic AU is usually associated with corneal involvement. However, in patients without corneal involvement, other anterior segment findings are sufficient to make an early and accurate diagnosis. Unilateral and diffusely distributed granulomatous KPs associated with elevated IOP and iris atrophy have a high clinical diagnostic value for herpetic AU. Although the disease has a recurrent nature, visual prognosis is favorable in cases without corneal scarring. Long-term oral acyclovir treatment (more than 6 months) and close follow-up are important to decrease recurrence rates and possible complications.

## Ethics

Ethics Committee Approval: Retrospective study, Informed Consent: It was taken.

Peer-review: Externally and internally peer-reviewed.

## Authorship Contributions

Surgical and Medical Practices: Esra Kardeş, Kansu Bozkurt, Betül İlkey Sezgin Akçay, Cihan Ünlü, Tuğba Aydoğan Gezginaslan, Ahmet Ergin, Concept: Esra Kardeş, Kansu Bozkurt, Betül İlkey Sezgin Akçay, Cihan Ünlü, Tuğba Aydoğan

Gezginaslan, Ahmet Ergin, Design: Esra Kardeş, Kansu Bozkurt, Betül İlkey Sezgin Akçay, Cihan Ünlü, Tuğba Aydoğan Gezginaslan, Ahmet Ergin, Data Collection or Processing: Esra Kardeş, Kansu Bozkurt, Betül İlkey Sezgin Akçay, Cihan Ünlü, Tuğba Aydoğan Gezginaslan, Ahmet Ergin, Analysis or Interpretation: Esra Kardeş, Kansu Bozkurt, Betül İlkey Sezgin Akçay, Cihan Ünlü, Tuğba Aydoğan Gezginaslan, Ahmet Ergin, Literature Search: Esra Kardeş, Kansu Bozkurt, Betül İlkey Sezgin Akçay, Cihan Ünlü, Tuğba Aydoğan Gezginaslan, Ahmet Ergin, Writing: Esra Kardeş, Kansu Bozkurt, Betül İlkey Sezgin Akçay, Cihan Ünlü, Tuğba Aydoğan Gezginaslan, Ahmet Ergin.

Conflict of Interest: No conflict of interest was declared by the authors.

Financial Disclosure: The authors declared that this study received no financial support.

## References

- Rathinam SR, Namperumalsamy P. Global variation and pattern changes in epidemiology of uveitis. *Indian J Ophthalmol.* 2007;55:173-183.
- Cunningham ET Jr. Diagnosing and treating herpetic anterior uveitis. *Ophthalmology.* 2000;107:2129-2130.
- Gaynor BD, Margolis TP, Cunningham ET Jr. Advances in diagnosis and management of herpetic uveitis. *Int Ophthalmol Clin.* 2000;40:85-109.
- Guney E, Akçay BI, Erdogan G, Unlu C, Akcali G, Bayramlar H. The etiologic features of anterior uveitis in a Turkish population. *Clin Ophthalmol.* 2012;6:845-849.
- de Schyver I, Rozenberg F, Cassouz N, Michelson S, Kestelyn P, Lehoang P, Davis JL, Bodaghi B. Diagnosis and treatment of cytomegalovirus iridocyclitis without retinal necrosis. *Br J Ophthalmol.* 2006;90:852-855.
- Usui M, Usui N, Goto H, Minoda H, Rai T. Polymerase chain reaction for diagnosis of herpetic intraocular inflammation. *Ocul Immunol Inflamm.* 1993;1:105-112.
- Yamamoto S, Pavan-Langston D, Kinoshita S, Nishida K, Shimomura Y, Tano Y. Detecting herpesvirus DNA in uveitis using the polymerase chain reaction. *Br J Ophthalmol.* 1996;80:465-468.
- Jabs DA, Nussenblatt RB, Rosenbaum JT. Standardization of Uveitis Nomenclature (SUN) Working Group. Standardization of uveitis nomenclature for reporting data: results of first international workshop. *Am J Ophthalmol.* 2005;140:509-516.
- Siverio Júnior CD, Imai Y, Cunningham ET Jr. Diagnosis and management of herpetic anterior uveitis. *Int Ophthalmol Clin.* 2002;42:43-48.
- Liesegang TJ. Classification of herpes virus keratitis and anterior uveitis. *Cornea.* 1999;18:127-143.
- Liesegang TJ. Ocular herpes simplex infection: pathogenesis and current therapy. *Mayo Clin Proc.* 1988;63:1092-1105.
- Nalcacioglu-Yüksekkaya P, Ozdal PC, Teke MY, Kara C, Ozturk F. Presumed herpetic anterior uveitis: a study with retrospective analysis of 79 cases. *Eur J Ophthalmol.* 2014;1:14-20.
- Tugal-Tutkun I, Otük-Yasar B, Altinkurt E. Clinical features and prognosis of herpetic anterior uveitis: a retrospective study of 111 cases. *Int Ophthalmol.* 2010;30:559-565.
- Van der Lelij A, Ooijman FM, Kijlstra A, Rothova A. Anterior uveitis with sectoral iris atrophy in the absence of keratitis: a distinct clinical entity among herpetic eye diseases. *Ophthalmology.* 2000;107:1164-1170.
- Jones NP. Fuchs' heterochromic uveitis: an update. *Surv Ophthalmol.* 1993;37:253-272.
- van Boxtel LA, van der Lelij A, van der Meer J, Los LI. Cytomegalovirus as a cause of anterior uveitis in immunocompetent patients. *Ophthalmology.* 2007;114:1358-1362.
- Young RC, Hodge DO, Liesegang TJ, Baratz KH. Incidence, recurrence, and outcomes of herpes simplex virus eye disease in Olmsted County, Minnesota, 1976-2007: the effect of oral antiviral prophylaxis. *Arch Ophthalmol.* 2010;128:1178-1183.
- Sudesh S, Laibson PR. The impact of the herpetic eye disease studies on the management of herpes simplex virus ocular infections. *Curr Opin Ophthalmol.* 1999;10:230-233.



## Retinopathy of Prematurity in Triplets

Mehmet Ali Şekeroğlu\*, Emre Hekimoğlu\*\*, Ülker Çelik\*\*\*, Yusuf Kale\*\*\*, Ahmet Yağmur Baş\*\*\*

\*Ulucanlar Eye Training and Research Hospital, Ophthalmology Clinic, Ankara, Turkey

\*\*Zübeyde Hanım Maternity and Research Hospital, Ophthalmology Clinic, Ankara, Turkey

\*\*\*Zübeyde Hanım Maternity and Research Hospital, Neonatology Clinic, Ankara, Turkey

### Summary

**Objectives:** To investigate the incidence, severity and risk factors of retinopathy of prematurity (ROP) in triplets.

**Materials and Methods:** The medical records of consecutive premature triplets who had been screened for ROP in a single maternity hospital were analyzed and presence and severity of ROP; birth weight, gender, gestational age of the infant; route of delivery and the mode of conception were recorded.

**Results:** A total of 54 triplets (40 males, 14 females) who were screened for ROP between March 2010 and February 2013 were recruited for the study. All triplets were delivered by Caesarean section and 36 (66.7%) were born following an assisted conception. During follow-up, seven (13%) of the infants developed ROP of any stage and two (3.7%) required laser photocoagulation. The mean gestational age of triplets with ROP was  $27.6 \pm 1.5$  (27-31) weeks whereas it was  $32.0 \pm 1.5$  (30-34) weeks in those without ROP ( $p=0.002$ ). The mean birth weights of triplets with and without ROP were  $1290.0 \pm 295.2$  (970-1600) g and  $1667.5 \pm 222.2$  (1130-1960) g, respectively ( $p<0.001$ ). The presence of ROP was not associated with gender ( $p=0.358$ ) or mode of conception ( $p=0.674$ ).

**Conclusion:** ROP in triplets seems to be mainly related to low gestational age and low birth weight. Further prospective randomized studies are necessary to demonstrate risk factors of ROP in triplets and to determine if and how gemelarity plays a role in the development of ROP.

**Keywords:** Birth weight, gestational age, laser photocoagulation, retinopathy of prematurity, triplet

### Introduction

Retinopathy of prematurity (ROP) is one of the major causes of preventable childhood blindness.<sup>1</sup> Since the most significant risk factors are low birth weight and low gestational age, the number of infants at risk for ROP started to increase after the improvement of survival of extremely premature infants.<sup>2</sup> Other proposed risk factors for ROP include respiratory distress syndrome, prolonged mechanical ventilation, blood transfusion, sepsis, assisted conception and multiple births.<sup>3,4,5,6</sup> However, the association between multiple births and the incidence and severity of ROP is still contradictory.<sup>7,8</sup> The aim of the present study was to assess the incidence, severity and risk factors of ROP in triplets.

### Materials and Methods

This retrospective study was carried out in a single maternity and research hospital in full accord with the principles laid out in the Declaration of Helsinki, upon approval of Institutional Review Board. The data was obtained by chart review. The medical files of premature infants admitted for routine ROP screening examination were reviewed and consecutive triplets who were followed for at least 6 months were recruited to the study. The rendered data included the presence and severity of ROP; birth weight, gender, gestational age of the infant; route of delivery and the mode of conception (assisted or natural conception). The timing of the initial screening examination, frequency of follow-up examinations and when to discontinue screening examinations

**Address for Correspondence:** Mehmet Ali Şekeroğlu MD, Ulucanlar Eye Training and Research Hospital, Ophthalmology Clinic, Ankara, Turkey

Phone: +90 532 740 19 60 E-mail: msekeroglu@yahoo.com **Received:** 09.04.2015 **Accepted:** 06.07.2015

This article is also published in Turkish under doi:10.4274/tjo.94815 pages 2016;46:114-117.



was determined according to the recommendations of the American Academy of Pediatrics, American Academy of Ophthalmology, and American Association for Pediatric Ophthalmology and Strabismus.<sup>9</sup> Screening was performed by one of two experienced pediatric ophthalmologists (MAŞ and EH). Prior to examination, pupillary dilation was induced with 2.5% phenylephrine and 0.5% tropicamide, after which the topical anesthetic proparacaine was instilled and an eyelid speculum was applied. Each infant underwent a binocular indirect ophthalmoscopy examination for each eye with a 28 D condensing lens and scleral depression. Treatment decisions were made according to 'The Early Treatment of Retinopathy of Prematurity study' criteria.<sup>10</sup> Statistical analysis was performed using SPSS software for Windows 15.0 (Statistical Package for the Social Sciences, SPSS, Inc., Chicago, IL, USA). Median and range were given as descriptive statistics for quantitative data. Categorical data were summarized using frequency and percentages. Independent samples t test was used to compare two independent groups with normal distribution of quantitative data and Mann-Whitney U test was used for abnormal distributions. Results were accepted as statistically significant when p was <0.05.

## Results

A total of 54 triplets (40 males, 14 females) who were screened for ROP between March 2010 and February 2013 were included in the study. Gestational age of the infants at birth ranged from 27 to 34 weeks with a mean gestational age of  $31.4 \pm 2.1$  weeks. Birth weight ranged from 970 to 1.960 g with a mean of  $1.618.5 \pm 262.9$  g. All triplets were delivered by Caesarean section and 36 (66.7%) were born following an assisted conception. Seven (13%) of the infants developed ROP of any stage and two (3.7%) required transpupillary diode laser photocoagulation during follow-up. The two infants who required laser treatment were siblings. Their third sibling had zone II stage 2 ROP which spontaneously regressed without any treatment. Infants requiring treatment for ROP were those with the lowest gestational age (27 weeks) and lowest birth weight (970 and 980 g) among the whole study population. The distribution of ROP according to gestational age groups are shown in Table 1. The mean gestational age of triplets with ROP was  $27.6 \pm 1.5$  (27-31) weeks and  $32.0 \pm 1.5$  (30-34) weeks in those without ROP ( $p=0.002$ ). The mean

birth weight of triplets with ROP was  $1,290.0 \pm 295.2$  (970-1,600) g compared to  $1,667.5 \pm 222.2$  (1,130-1,960) g in those without ROP ( $p<0.001$ ). The presence of ROP was not associated with gender ( $p=0.358$ ) or mode of conception ( $p=0.674$ ).

## Discussion

The incidence of multiples pregnancies has increased, possibly because of higher maternal age and the increased use of assisted conception methods such as ovulation induction and in vitro fertilization.<sup>11</sup> These are known to be associated with maternal and neonatal complications which are directly related to the number of fetuses in utero. A large study reported that 15% of singletons, 48% of twins and 78% of higher order multiples require neonatal intensive care unit (NICU) admission.<sup>12</sup> The higher rate of neonatal complications is mostly due to prematurity. However, the relationship between multiple pregnancies and ROP is still controversial.<sup>7,8,13</sup> Some investigators assume multiple gestation is an independent risk factor for ROP,<sup>14,15</sup> but others do not.<sup>13,16</sup>

Triplet birth is a rare occurrence. The incidence of triplets increased after the introduction of assisted conception methods, but started to decline again after limitation of the number of embryos transferred.<sup>17</sup> In a study investigating NICU admissions, the proportion of triplets reported to be decreased from 5.0 to 3.3 per 100 NICU admissions.<sup>18</sup> Preterm labor and prematurity were the commonest complications of triplet gestations. Chibber et al.<sup>19</sup> reported the rate of prematurity as 84% in their large triplet series. In a study investigating fetomaternal outcome in triplet pregnancy, mean birth weights of 1<sup>st</sup>, 2<sup>nd</sup> and 3<sup>rd</sup> triplets were 1.651, 1.640 and 1.443 g respectively.<sup>20</sup> Zanconato<sup>21</sup> reported the incidence of preterm labor as 78.6% and ROP as 6.5% in triplet pregnancies. The incidence of any stage of ROP was 13% and the rate of ROP requiring treatment was 3.7% in our series.

The relationship between triplet pregnancies and ROP is also controversial. Tomazzoli et al.<sup>8</sup> found no increased risk for ROP when they compared premature triplets with premature singletons, and concluded that multiple gestation adds no risk beyond that due to prematurity. Assisted conception methods also did not appear to be an independent risk factor for ROP in our study, similar to previous studies in the literature.<sup>7,17,19</sup> Nevertheless, gynecologists should be aware of possible

**Table 1. The distribution of retinopathy of prematurity according to gestational age groups in triplets**

		Treatment-requiring ROP	Spontaneously regressed ROP	No ROP	Total
Gestational age (weeks)	≤28	2 (33.3%)	4 (66.7%)	0 (0%)	6
	29-32	0 (0%)	1 (4.2%)	23 (95.8%)	24
	>32	0 (0%)	0 (0%)	24 (100%)	24

ROP: Retinopathy of prematurity, results are denoted as number (percent within gestational age groups)

neonatal outcomes of triplet pregnancies and the higher risk of prematurity in order to follow proper infertility management strategies and avoid iatrogenic multiple gestations.

We evaluated triplets for certain clinical and demographical features including birth weight, gestational age, gender, route of delivery and mode of conception, and found birth weight and gestational age were related to ROP. The two siblings who required treatment for ROP in our study population were extremely premature (with the lowest gestational age and birth weights of the study population). Gender, route of delivery and mode of conception were not associated with ROP. Maayan-Metzger et al.<sup>16</sup> compared triplet and singleton preterm infants and found no differences between two groups in terms of perinatal parameters, respiratory parameters and neonatal complications, including ROP. We did not investigate some other proposed risk factors such as respiratory distress syndrome, septicemia, number of blood transfusions and duration of mechanical ventilation.

The present study should be viewed in context of some limitations. First of all, the limited number of triplets may influence the power of statistical outcomes. Regression analysis for risk factors could not be performed because of the small number of infants with ROP. Secondly, other ROP risk factors such as respiratory distress syndrome, duration of mechanical ventilation, septicemia, and blood transfusion were not included in the study parameters. Thirdly, the study was retrospective, which limited the data available. Finally, there was a lack of control group such as singleton or twin gestations for comparing outcome data. Despite these limitations, the current study has important implications regarding the incidence, severity and risk factors of ROP in triplets. In light of the present data, as the most important risk factors are low birth weight and low gestational age for ROP in triplets, we can suggest that an ROP screening protocol similar to that used for singletons can be applied in triplets.

## Conclusion

Triplet pregnancies usually result in prematurity. ROP in triplet infants seems to be mainly related to low gestational age and low birth weight. Larger prospective randomized studies are necessary to demonstrate risk factors of ROP in triplets and to determine if and how gemelarity plays a role in the occurrence of ROP.

## Ethics

Ethics Committee Approval: The study was approved by the Zübeyde Hanım Gynecology Training and Research Hospital of Local Ethics Committee, Informed Consent: Consent form was filled out by all participants.

Peer-review: Externally peer-reviewed.

## Authorship Contributions

Surgical and Medical Practices: Mehmet Ali Şekeroğlu, Emre Hekimoğlu, Ülker Çelik, Yusuf Kale, Ahmet Yağmur Baş, Concept: Mehmet Ali Şekeroğlu, Emre Hekimoğlu, Design: Mehmet Ali Şekeroğlu, Emre Hekimoğlu, Data Collection or Processing: Mehmet Ali Şekeroğlu, Emre Hekimoğlu, Analysis or Interpretation: Mehmet Ali Şekeroğlu, Emre Hekimoğlu, Literature Search: Mehmet Ali Şekeroğlu, Emre Hekimoğlu, Writing: Mehmet Ali Şekeroğlu.

Conflict of Interest: No conflict of interest was declared by the authors.

Financial Disclosure: The authors declared that this study received no financial support.

## References

- Steinkuller PG, Du L, Gilbert C, Foster A, Collins ML, Coats DK. Childhood blindness. *JAAPOS*. 1999;3:26-32.
- Gilbert C, Rahi J, Eckstein M, O'Sullivan J, Foster A. Retinopathy of prematurity in middle-income countries. *Lancet*. 1997;350:12-14.
- Alpay A, Uğurbaş SH. Incidence and risk factors for retinopathy of prematurity in the West Black Sea region, Turkey. *Turk J Pediatr*. 2012;54:113-118.
- Küçükkevcilioğlu M, Mutlu FM, Sarıcı SU, Ceylan OM, Altınsöy HI, Kılıç S, Çekmez F. Frequency, risk factors and outcomes of retinopathy of prematurity in a tertiary care hospital in Turkey. *Turk J Pediatr*. 2013;55:467-474.
- Avery GB, Glass P. Retinopathy of prematurity: what causes it? *Clin Perinatol*. 1988;15:917-928.
- Cooke RW, Clark D, Hickey-Dwyer M, Weindling AM. The apparent role of blood transfusions in the development of retinopathy of prematurity. *Eur J Pediatr*. 1993;152:833-836.
- Friling R, Axer-Siegel R, Hersocovici Z, Weinberger D, Sirota L, Snir M. Retinopathy of prematurity in assisted versus natural conception and singleton versus multiple births. *Ophthalmology*. 2007;114:321-324.
- Tomazzoli L, Renzi G, Mansoldo C. Ophthalmologic follow-up of premature twins and triplets. *Eur J Ophthalmol*. 2003;13:439-444.
- Fierson WM; American Academy of Pediatrics Section on Ophthalmology; American Academy of Ophthalmology; American Association for Pediatric Ophthalmology and Strabismus; American Association of Certified Orthoptists. *Pediatrics*. 2013;131:189-195.
- Phelps DL; ETROP Cooperative Group. The Early Treatment for Retinopathy of Prematurity study: better outcomes, changing strategy. *Pediatrics*. 2004;114:490-491.
- Fell DB, Joseph K. Temporal trends in the frequency of twins and higher-order multiple births in Canada and the United States. *BMC Pregnancy Childbirth*. 2012;12:103.
- Callahan TL, Hall JE, Ettner SL, Christiansen CL, Greene ME, Crowley WF Jr. The economic impact of multiple-gestation pregnancies and the contribution of assisted-reproduction techniques to their incidence. *N Engl J Med*. 1994;331:244-249.
- Riazi-Esfahani M, Alizadeh Y, Karkhaneh R, Mansouri MR, Kadivar M, Nili Ahmadabadi M, Nayeri F. Retinopathy of Prematurity: Single versus Multiple-Birth Pregnancies. *J Ophthalmic Vis Res*. 2008;3:47-51.
- Dos Santos Motta MM, Fortes Filho JB, Coblentz J, Fiorot CA. Multiple pregnancies and its relationship with the development of retinopathy of prematurity (ROP). *Clin Ophthalmol*. 2011;5:1783-1787.
- Sood V, Chellani H, Arya S, Guliani BP. Changing spectrum of retinopathy of prematurity (ROP) and variations among siblings of multiple gestation. *Indian J Pediatr*. 2012;79:905-910.

16. Maayan-Metzger A, Naor N, Sirota L. Comparative outcome study between triplet and singleton preterm newborns. *Acta Paediatr.* 2002;91:1208-1211.
17. Funnell CL, Dabbs TR. Assisted conception and retinopathy of prematurity: 8-year follow-up study. *Eye (Lond).* 2007;21:383-386.
18. Bassil KL, Shah PS, Barrington KJ, Harrison A, da Silva OP, Lee SK; Canadian Neonatal Network. The changing epidemiology of preterm twins and triplets admitted to neonatal intensive care units in Canada, 2003 to 2008. *Am J Perinatol.* 2012;29:237-244.
19. Chibber R, Fouda M, Shishtawy W, Al-Dossary M, Al-Hijji J, Amen A, Mohammed AT. Maternal and neonatal outcome in triplet, quadruplet and quintuplet gestations following ART: a 11-year study. *Arch Gynecol Obstet.* 2013;288:759-767.
20. Mazhar SB, Rahim F, Furukh T. Fetomaternal outcome in triplet pregnancy. *J Coll Physicians Surg Pak.* 2008;18:217-221.
21. Zanconato G, Poggi S, Ruffo R, Gazzoni A, Padovani EM, Franchi M. Antepartum management and neonatal outcome of triplet pregnancies. *Arch Gynecol Obstet.* 2005;271:320-324.



## Low Vision Rehabilitation in Older Adults

Zuhal Özen Tunay\*, Aysun İdil\*\*, İkbal Seza Petriçli\*\*\*, Özdemir Özdemir\*

\*Zekai Tahir Burak Women's Health Training and Research Hospital, Ophthalmology Clinic, Ankara, Turkey

\*\*Ankara University Faculty of Medicine, Department of Ophthalmology, Low Vision Rehabilitation and Research Center, Ankara, Turkey

\*\*\*Zübeyde Hanım Women's Health Training and Research Hospital, Ophthalmology Clinic, Ankara, Turkey

### Summary

**Objectives:** To evaluate the diagnosis distribution, low vision rehabilitation methods and utilization of low vision rehabilitation in partially sighted persons over 65 years old.

**Materials and Methods:** One hundred thirty-nine partially sighted geriatric patients aged 65 years or older were enrolled to the study between May 2012 and September 2013. Patients' age, gender and the distribution of diagnosis were recorded. The visual acuity of the patients both for near and distance were examined with and without low vision devices and the methods of low vision rehabilitation were evaluated.

**Results:** The mean age of the patients was 79.7 years and the median age was 80 years. Ninety-six (69.1%) of the patients were male and 43 (30.9%) were female. According to the distribution of diagnosis, the most frequent diagnosis was senile macular degeneration for both presenile and senile age groups. The mean best corrected visual acuity for distance was  $0.92 \pm 0.37$  logMAR and  $4.75 \pm 3.47$  M for near. The most frequently used low vision rehabilitation methods were telescopic glasses (59.0%) for distance and hyperocular glasses (66.9%) for near vision. A significant improvement in visual acuity both for distance and near vision were determined with low vision aids.

**Conclusion:** The causes of low vision in presenile and senile patients in our study were similar to those of patients from developed countries. A significant improvement in visual acuity can be achieved both for distance and near vision with low vision rehabilitation in partially sighted geriatric patients. It is important to guide them to low vision rehabilitation.

**Keywords:** Geriatric, low vision, low vision rehabilitation

### Introduction

According to the World Health Organization's VISION 2020 report, the prevention and rehabilitation of low vision is among the primary global objectives. The legal definitions of 'low vision' and 'blindness' specified by the World Health Organization are based on visual acuity and visual field. Low vision is defined as visual acuity in the better eye after refractive correction between 20/70 (0.3) and 20/400 (0.05, 3 mps) or a visual field less than 20 degrees.<sup>1,2</sup> In low vision, the degree of vision loss is less than in blindness and the individual benefits from vision enhancement aids.<sup>3,4</sup>

Low vision significantly impacts a person's quality of life and is a major socioeconomic problem for both individuals and the public. As the elderly population increases and age-related vision problems become more common, the importance of low vision rehabilitation is also growing. Due to demographic, socioeconomic and cultural differences, it is important that each community investigate the distribution of diagnoses, determine preventable causes and use these data in health planning for its own population.<sup>3,5,6</sup>

The aim of this study was to evaluate and contribute to our national body of knowledge regarding the causes of low vision, methods of vision enhancement, and utilization of low vision

**Address for Correspondence:** Zuhal Özen Tunay MD, Zekai Tahir Burak Women's Health Training and Research Hospital, Ophthalmology Clinic, Ankara, Turkey

Phone: +90 505 757 18 74 E-mail: zuhaltunay@gmail.com **Received:** 05.03.2015 **Accepted:** 02.06.2015

This article is also published in Turkish under doi:10.4274/tjo.68878 pages 2016;46:118-122.

rehabilitation in presenile and senile individuals presenting for low vision rehabilitation.

### Materials and Methods

One hundred thirty-nine patients aged 65 years or older who presented to our clinic for the first time between May 2012 and September 2013 were enrolled in the study. A detailed medical history was obtained from each partially sighted subject and the areas in which they experienced difficulty due to near and distance visual function were identified. Near and distance best corrected visual acuity (BCVA) were determined. Color vision and intraocular pressure were evaluated and anterior and posterior examinations were conducted. Subjects were evaluated in terms of age at presentation, gender, distribution of diagnoses in the presenile (65-74 years old) and senile (75 years and older) age groups, near and distance visual acuity, and low vision aids (LVAs) used for near and distance.

All subjects' near and distance visual acuity were determined after correcting refractive errors. Distance vision was measured using the ETDRS chart from 4, 2 or 1 meter(s) depending on the subject's vision level and was recorded in logMAR. Near vision was determined using the MNREAD near reading chart and vision levels from 25 cm were reported as "M" values.

The patients were asked about their priorities for low vision rehabilitation. Low vision enhancement devices used were Keplerian and Galilean telescopic and electro-optical systems for distance and magnifiers, hyperocular lenses, labo-clip glasses, telemicroscopes and electro-optical systems for near vision.

Considering the patients' visual acuity, visual field analysis, binocular vision status, and visual needs and expectations, required magnification power was calculated with the Kestenbaum formula and appropriate low vision enhancement methods were determined. Patients' visual acuity using the LVA was assessed and they were informed on the use of the LVA.

The study was conducted in accordance with the Declaration of Helsinki and was approved by the Ankara University Ethics Committee. Informed consent was obtained from all study participants.

SPSS for Windows version 16.0 (Statistical Package for the Social Sciences Inc., Chicago, IL, USA) software was used for statistical analyses. Data are presented as minimum (min), maximum (max), mean, standard deviation (SD), number (n) or percentage (%). Vision levels with and without LVA use were compared using a paired-samples t test. The level of significance was accepted as  $\alpha=0.05$ .

### Results

The mean age of the patients was 79.7 years (65-101 years), the median age was 80; 69.1% (n=96) were male and 30.9% (n=43) were female.

The mean BCVA of the better eye was  $0.92 \pm 0.37$  (0.20-1.60) logMAR for distance and  $4.75 \pm 3.47$  (1.00-16.00) M for near vision.

The most common diagnosis was age-related macular degeneration (Table 1).

The priority of the patients presenting for low vision rehabilitation was to improve their near vision; 62.5% (87 patients) stated that they required low vision rehabilitation primarily for near vision, while 37.5% expressed that they had more difficulty with distance vision.

The distribution of LVAs chosen for near and distance vision is shown in Tables 2 and 3. Spectacles alone provided adequate improvement in distance vision for 47 patients (33.8%), while 92 (66.2%) of the patients were prescribed an LVA. Telescopic lenses were the most common method (59.0%) chosen for distance. Of the 92 patients who did not achieve adequate distance vision with conventional glasses and were prescribed an LVA, 89% (82 patients) used telescopic lenses.

A total of 182 LVAs for near vision were prescribed for the 139 patients in the study; 30.9% of the study participants used more than one LVA. Hyperocular glasses were the most common LVA used for near vision (66.9%). Of the patients using spectacles as an LVA for near, 30.9% were also prescribed a magnifier for specific daily activities.

The near and distance vision levels attained by the study participants using LVAs are shown in Table 4. Mean distance vision improved from 0.92 logMAR to 0.24 logMAR and near vision improved from 4.75 M to 1.44 M with LVA use. The differences were significant for both near and distance (paired-samples t test,  $p=0.001$ ).

At 1 year follow-up, 91.4% (n=127) of the patients reported that they continued to use the LVA. Of the 12 patients (8.6%) who did not continue LVA use, it was determined that

Age group	Diagnosed cause of low vision	n	%
Presenile (65-74 years)	Age-related macular degeneration	24	51.1
	Diabetic retinopathy	11	23.4
	Hereditary retinal diseases	7	14.9
	Other (optic atrophy, cortical visual impairment)	5	10.6
Senile (75 years or over)	Age-related macular degeneration	79	85.9
	Glaucoma	5	5.4
	Diabetic retinopathy	5	5.4
	Other (optic atrophy, cortical visual impairment)	3	3.3
Total		139	100.0

Distance LVA	n	%
Telescopic systems	82	59.0
Keppler type	69	49.6
Galilei type	13	9.4
Electro-optic systems	10	7.2
Eyeglasses only	47	33.8
Total	139	100.0

LVA: Low vision aid

Near LVA (first choice)	n	%
Eyeglasses-type LVA		
Hyperocular lenses	89	64.0
Telemicroscope	22	15.8
Labo-clip	14	10.1
Magnifiers		
Handheld magnifier	1	0.7
Stand magnifier	9	6.5
Electro-optic systems	4	2.9
Total	139	100.0

LVA: Low vision aid

	Without LVA Mean $\pm$ SD (min-max)	With LVA Mean $\pm$ SD (min-max)	p*
Distance (logMAR)	0.92 $\pm$ 0.37 (0.20-1.60)	0.24 $\pm$ 0.26 (0.0-1.2)	0.001
Near (25 cm) (M)	4.75 $\pm$ 3.47 (1.0-16.0)	1.44 $\pm$ 1.38 (1.0-10.0)	0.001

LVA: Low vision aid, SD: Standard deviation, min: Minimum, max: Maximum, p\*: Paired-samples t test

further decline in vision level due to underlying ophthalmic pathology necessitated a new LVA system.

## Discussion

Aging is a physiological process that affects every system of the body. With longer life expectancy and the resulting rise in the elderly population, old age has increasing importance as a physiological stage of life. Vision is one of the functions most severely affected in the geriatric age group.<sup>7</sup> This study investigated the clinical characteristics and low vision rehabilitation methods applied in low vision patients in the senile and presenile groups.

The advantage of this type of study conducted on individuals presenting to clinics is the more reliable and detailed ophthalmologic data included.<sup>8</sup> However, the main disadvantage is that the data cannot be generalized to the general public. The Ankara University Low Vision Rehabilitation and Research Center is a university-based center that serves patients from every region of Turkey. Therefore, these data should contribute both in terms of referring patients with low vision to rehabilitation services and to the planning and implementation of low vision rehabilitation services.

There was quite a wide age range among the patients presenting for low vision rehabilitation, with the oldest being 101 years old. We believe this demonstrates that there is no age limit for low vision rehabilitation in the senile group and that individuals at every age have the potential for low vision rehabilitation depending on their individual needs and expectations. Data from Western countries show similar wide age ranges, whereas data from developing countries indicates that low vision rehabilitation services are not widespread and a higher proportion of patients are in the presenile age group.<sup>5,6,9,10</sup>

Consistent with gender distributions reported in the literature, there were more males (69.1%) presenting in this age group.<sup>9,10,11</sup> This may be attributable to two factors. First, in society men may have greater need for visual function for economical and social reasons; second, men may have fewer esthetic concerns and may therefore be more willing to use low vision enhancement methods.

The most common diagnosis in our study group was age-related macular degeneration. The second and third most common diagnoses were diabetic retinopathy and hereditary retinal disease in the presenile group versus glaucoma-related vision loss and diabetic retinopathy in the senile group. In a 2008 study, Recep et al.<sup>12</sup> reported that among all age groups, 22% of patients were enrolled in the low vision rehabilitation program with a diagnosis of age-related macular degeneration, and a high proportion of patients with this diagnosis benefited from telescopic lenses. In Western countries, the diagnostic groups most commonly requiring low vision rehabilitation in the senile group are age-related macular degeneration and diabetic retinopathy. In contrast, in developing countries, the diagnosis distribution of this age group is dominated by patients requiring cataract surgery.<sup>8,9,10</sup>

For distance vision, spectacles alone provided sufficient improvement for 33.8% of our patients. This indicates that accurately determining refractive error and current visual function is one of the most crucial steps in a low vision examination.<sup>11,13,14</sup> Furthermore, the small increase in visual acuity provided by the complete and accurate correction of



refractive errors may result in lighter and more effective LVAs for the patient and increase their use of the device.<sup>4</sup>

Among all the patients in our study, the LVA most frequently used for distance was telescopic glasses (59%). Among patients prescribed an LVA for distance vision, this rate was 89%. These systems are preferred because they are portable and more economical than electro-optical systems. The main disadvantage of telescopic glasses is that they may be difficult for some individuals to accept due to esthetic concerns. However, the utilization rate increases in the presenile and senile age groups as people in this group are generally less concerned with appearances. In the literature, the most commonly utilized LVA is telescopic glasses. In Turkey, Petriçli et al.<sup>11</sup> reported that 70% of patients in the low vision rehabilitation group used telescopic glasses. In a study by Altınbay<sup>15</sup> 74% of the patients were prescribed telescopic glasses, although only 54% reported purchasing them. Recep et al.<sup>12</sup> and Bakbak et al.<sup>16</sup> reported that all of the patients in their studies used telescopic glasses. Compared to data from Western countries, our study indicates that electro-optical systems were less commonly used. The higher cost of electro-optical systems compared to telescopic systems is the biggest reason they are not utilized more in low vision rehabilitation.

We determined that improving near vision was the priority of most patients presenting for low vision rehabilitation. The most common LVA for near vision in our study was hyperocular eyeglasses (followed by telemicroscopes and labo-clip glasses), consistent with the literature.<sup>9,11</sup> Using magnifiers is not the first choice among this age group, and they are prescribed to many patients as an auxiliary LVA especially for certain daily activities and reading.<sup>9,11,14</sup> In the current study, 30.6% of the patients needed more than one type of LVA for near vision. We believe that it is important to keep in mind that individuals may require more than one low vision rehabilitation method for their daily activities such as reading, cooking, and self-care needs.

After 1 year, 91.4% of the patients in our study reported that they were still using their LVA. In the few patients who did not continue using the LVA, we determined that further decline in vision level due to underlying ophthalmic pathology necessitated a new LVA system. The reason for our high compliance rate compared to previous studies may be that our patients began using the LVAs after being trained in their use, and frequent follow-up maintained high motivation.<sup>17</sup> This reinforces the fact that low vision rehabilitation is not limited to LVA utilization, but should entail adaptations that encompass all aspects of the patient's life.

In summary, low vision rehabilitation may be necessary in geriatric patients due to serious ophthalmologic and

neurologic problems. Optimizing the visual abilities of partially sighted patients makes their day-to-day lives easier, increases life quality, and allows them to continue to be self-sufficient, productive and independent individuals. Therefore, we would like to emphasize the importance of referring partially sighted patients to low vision rehabilitation during the course of their clinical follow-up.

#### Ethics

Ethics Committee Approval: Ankara University Ethics Committee, Informed Consent: It was taken.

Peer-review: Externally peer-reviewed.

#### Authorship Contributions

Surgical and Medical Practices: Zuhall Özen Tunay, Aysun İdil, İkbâl Seza Petriçli, Concept: Zuhall Özen Tunay, Aysun İdil, Design: Zuhall Özen Tunay, Aysun İdil, Data Collection or Processing: Zuhall Özen Tunay, Aysun İdil, İkbâl Seza Petriçli, Özdemiir Özdemiir, Analysis or Interpretation: Zuhall Özen Tunay, Aysun İdil, İkbâl Seza Petriçli, Özdemiir Özdemiir, Literature Search: Zuhall Özen Tunay, Aysun İdil, İkbâl Seza Petriçli, Özdemiir Özdemiir, Writing: Zuhall Özen Tunay, Aysun İdil.

Conflict of Interest: No conflict of interest was declared by the authors.

Financial Disclosure: The authors declared that this study received no financial support.

#### References

1. Pizzarello L, Abiose A, Ffytche T, Duerksen R, Thulasiraj R, Taylor H, Faal H, Rao G, Kocur I, Resnikoff S. VISION 2020: The Right to Sight: a global initiative to eliminate avoidable blindness. *Arch Ophthalmol*. 2004;122:615-620.
2. Topalkara A. Az Görme Nedir? Yasal Mevzuat, Az görenlerde Yaşam Kalitesi ve Sosyal Sorunlar. Örnek F, Kemer ÖE, Elgin U, Koloğlu SA, Atilla H, Kıratlı H. 30. Ulusal Oftalmoloji Kursu Optik Refraksiyon ve Rehabilitasyon, Ankara; Pasifik Yayınevi; 2010:121-124.
3. Dye C, Boerma T, Evans D, Harries A, Lienhardt C, McManus J, Pang T et al. *World Health Report 2013*. Luxembourg; WHO Press; 2014:80-91.
4. Ceyhan D. Maküla hastalıklarında görme rehabilitasyonu. *Ret-Vit*. 2010;18:151-157.
5. Ramezani A, Pardis M, Rafati N, Kazemi-Moghaddam M, Katibeh M, Rostami P, Dehghan MH, Javadi MA, Rabbanikhah Z. Causes of visual impairment among patients referred to a visual rehabilitation clinic in Iran. *Korean J Ophthalmol*. 2012;26:80-83.
6. Kim JH, Joo KS, Moon NJ. Characteristics of 681 low vision patients in Korea. *J Korean Med Sci*. 2010;25:1217-1221.
7. Büken NÖ, Büken E. Yaşlanma olgusu ve tıp etiği. *Geriatrici*. 2003;6:75-79.
8. Olusanya B, Onoja G, Ibraheem W, Bekibele C. Profile of patients presenting at a low vision clinic in a developing country. *BMC Ophthalmology*. 2012;12:31.
9. Faye EE, Chan-O'Connell L, Fischer M, Freed B, Pang L, Rosenthal B. *The lighthouse clinician's guide to low vision practice*. New York; Lighthouse international; 2011:83-99.
10. Pascolini D, Mariotti SP. Global estimates of visual impairment. *Br J Ophthalmol*. 2010;10:1-5.

11. Petriçli İS, Merdođan Aİ, Özen Tunay Z, Özdemir Ö. Herediter retina distrofilili olgularda az görme rehabilitasyonu. Turk J Ophthalmol. 2015;45:25-30.
12. Recep ÖF, Erdoğan S, Hasırıpı H. Az gören hastalarda görsel rehabilitasyonun deđerlendirilmesi. Türkiye Klinikleri J Ophthalmol. 2008;17:80-83.
13. Furtado JM, Lansingh VC, Winthrop KL, Spivey B. Training of an ophthalmologist in concepts and practice of community eye health. Indian J Ophthalmol. 2012;60:365-367.
14. Idil A, Ozen M, Atak N, Elhan A, Pehlivan S. Validity and reliability study of Turkish version on low vision with quality of life questionnaire. Int J Ophthalmol. 2011;4:546-551.
15. Altınbay D. Az görenlere yardım cihazı uygulamaları ve teleskopik gözlük kullanma oranları. Turk J Ophthalmol. 2013;43:427-431.
16. Bakbak B, Gedik Ş, Güzel H. Az görenlere yardım cihazı uygulamaları ve klinik sonuçlarımız. Ret-Vit. 2011;19:246-249.
17. Chiang PP, Xie J, Keeffe JE. Identifying the critical success factors in the coverage of low vision services using the classification analysis and regression tree methodology. Invest Ophthalmol Vis Sci. 2011;52:2790-2795.



# Uveal Melanoma: Current Trends in Diagnosis and Management

Berçin Tarlan\*, Hayyam Kıratlı\*\*

\*Private Practice, Ophthalmology, Ankara, Turkey

\*\*Hacettepe University Faculty of Medicine, Department of Ophthalmology, Ankara, Turkey

## Summary

Uveal melanoma, which is the most common primary intraocular malignancy in adults, arises from melanocytes within the iris, ciliary body and choroid. The diagnosis is based principally on clinical examination of the tumor with biomicroscopy and indirect ophthalmoscopy and confirmed by diagnostic techniques such as ultrasonography, fundus fluorescein angiography and optical coherence tomography. The clinical diagnosis of posterior uveal melanomas can be made when the classical appearance of a pigmented dome-shaped mass is detected on dilated fundus exam. Uveal melanomas classically show low to medium reflectivity on A-scan ultrasonography and on B-scan ultrasonography the tumor appears as a hyperechoic, acoustically hollow intraocular mass. Management of a suspicious pigmented lesion is determined by its risk factors of transforming into a choroidal melanoma, such as documentation of growth, thickness greater than 2 mm, presence of subretinal fluid, symptoms and orange pigment, margin within 3 mm of the optic disc, and absence of halo and drusen. Advances in the diagnosis and local and systemic treatment of uveal melanoma have caused a shift from enucleation to eye-conserving treatment modalities including transpupillary thermotherapy and radiotherapy over the past few decades. Prognosis can be most accurately predicted by genetic profiling of fine needle aspiration biopsy of the tumor before the treatment, and high-risk patients can now be identified for clinical trials that may lead to target-based therapies for metastatic disease and adjuvant therapy which aims to prevent metastatic disease.

**Keywords:** Eye, neoplasm, uveal melanoma

## Introduction

### Epidemiologic Characteristics

Melanoma is a malignant tumor arising from melanocytes and may originate from the skin (91%), the eye and tissues surrounding the eye (5%) or the mucosa (1%).<sup>1</sup> In 2% of patients, the source cannot be identified.<sup>1</sup> Ophthalmic melanomas can arise in the uvea (85%), eyelid/orbita (10%) and conjunctiva (5%).<sup>1,2</sup> Uveal melanoma is the most common primary intraocular malignancy in adults, and most uveal melanomas originate in the choroid (90%), followed by the ciliary body (7%) and the iris (2%).<sup>3</sup> The mean age at diagnosis is 60 years and the prevalence is estimated as 4.9 per million men and 3.7 per million women.<sup>4,5,6,7</sup>

Although the treatment approach has shifted from enucleation toward more eye-conserving therapies over the last 20 years, the 5-year survival rate has remained stable (about 81.6%). In addition to an increasing preference for therapeutic

modalities that conserve the eye, there is also a growing trend toward early treatment of tumors classified as small melanomas instead of monitoring.<sup>4,7</sup>

### Predisposing Factors

Both host and environmental factors influence the development of uveal melanoma.

### Host Factors

Significant risk factors for uveal melanoma include white race, fair skin and light iris color.<sup>8</sup>

### Melanocytic Lesions Associated with Melanoma

**Choroidal nevus:** Choroidal nevi are found in 3% of individuals over 30 years old and studies indicate that annual rates of malignant transformation can vary from 1 in 4,300 to 1 in 8,845.<sup>9,10</sup>

**Ocular/Oculodermal melanocytosis:** Ocular or oculodermal melanocytosis is a condition characterized by hyperpigmentation of the episclera, uvea and skin, and is more common in black, Hispanic and Asian populations. Its

prevalence in whites is 0.04%, and 1 in 400 cases develops uveal melanoma.<sup>11</sup>

**Cutaneous nevus:** Case-control studies have shown that cutaneous nevi may be a risk factor for uveal melanoma and that patients with dysplastic nevus syndrome have a higher incidence of uveal melanoma.<sup>12,13</sup> This highlights the need for dermatologic evaluation in uveal melanoma patients.

**Familial uveal melanoma:** Recently, an autosomal dominant hereditary cancer syndrome has been described in some patients with germline *BAP1* mutation. Patients with this mutation have higher incidences of uveal melanoma, cutaneous melanoma, atypical Spitz tumors, mesothelioma, meningioma, adenocarcinoma of the lung and many other cancer types.<sup>14,15</sup>

#### Environmental Factors

**Sunlight:** In contrast to cutaneous melanomas, ultraviolet light has not been shown to play a role in the development of uveal melanoma, except as a result of occupational exposure, as with arc welders.<sup>13,16</sup>

**Diet, smoking and alcohol consumption:** To date there are no studies showing that dietary factors, cigarette use or alcohol consumption have an effect on the incidence of uveal melanoma.

#### Diagnostic Methods in Uveal Melanoma

The diagnosis of uveal melanoma is based primarily on clinical examination by biomicroscopy and indirect ophthalmoscopy. In contrast to the basic principles of oncology, histological or cytologic evaluation is not routinely used in the diagnosis of intraocular neoplastic lesions. Ancillary tests including color fundus photography, ultrasonography (USG), fundus fluorescein angiography (FFA), indocyanine green angiography (ICGA), optical coherence tomography (OCT), fundus autofluorescence (FAF) and ultrasound biomicroscopy (UBM) can be used in order to confirm diagnosis. Fine-needle aspiration biopsy (FNAB) of the tumor can be performed when the clinical diagnosis is unclear, and the diagnosis can be clarified by the evaluation of an experienced ocular pathologist. There are currently no clear indications regarding the surveillance and initiation of treatment for small choroidal melanocytic lesions and with the recent understanding that cytogenic findings are among the main prognostic factors for uveal melanoma patients in terms of metastatic disease, biopsies are increasingly performed following diagnosis.<sup>17,18</sup>

Studies of delays in the diagnosis of uveal melanoma found that 28-37% of these lesions were not detected in the first examination. Therefore, it is imperative that patients exhibiting any symptoms suggestive of posterior segment pathology, such as photopsia, metamorphopsia or vision loss, undergo a dilated fundus examination.<sup>19,20,21,22</sup>

The classic appearance of posterior uveal melanoma (ciliary body and choroidal melanoma) is a brown, dome-shaped mass, but it may also appear as mushroom-shaped (20%) or diffuse type (5%). While 55% of the tumors are pigmented, 15% are nonpigmented and 30% include both pigmented and nonpigmented areas.<sup>3,23</sup>

Iris melanomas occur most frequently in the inferior quadrant (45%), are pigmented in 82% of cases and show one of three growth patterns: nodular, diffuse or tapioca.<sup>24</sup>

Unlike iris melanomas, which are clearly visible on clinical examination, ciliary body melanomas may be hidden behind the iris and be difficult to detect, especially when small. Similarly, choroidal melanomas may escape notice without a careful dilated fundoscopic examination. Documenting the size and location of the tumor by color fundus photography is crucial during follow-up in order to evaluate signs of malignant transformation, primarily documented growth.

Posterior uveal melanomas are generally graded based on tumor thickness in research and clinical settings. In this grading system, small tumors are those up to 3 mm thick with a base diameter not exceeding 16 mm, medium tumors are 3.1-8 mm thick with a base diameter not exceeding 16 mm, and large tumors are thicker than 8 mm and have a base diameter larger than 16 mm.<sup>23,25</sup> It has been established that the risk of metastasis increases 5% with each 1 mm increase in tumor thickness as measured by USG.<sup>23</sup> Cancer staging classifies the extent of disease based on clinical, pathologic and genetic factors. In the American Joint Committee on Cancer (AJCC) tumor node metastasis staging system, tumor size is evaluated and defined in the T category (1-4), lymph node involvement in the N category (NX, N0, N1) and presence of distant metastases in the M category (MX, M0, M1a, M1b, M1c) (Table 1). For posterior uveal melanoma, T is classified based on tumor basal width and thickness (T1, T2, T3, T4) and then divided into subgroups reflecting ciliary body involvement and extrascleral extension of the tumor (a, b, c, d, e). Studies have showed that this classification system can predict prognosis, and 5-year survival rate of iris melanoma patients was estimated to be 100% for patients with T1 tumors, 90.4% for patients with T2 tumors, 63.6% for patients with T2a tumors and 50% for patients with iris melanomas classified as T3, T3a or T4.<sup>26</sup> The metastasis rate of posterior uveal melanoma at 10 years was found as 15% for T1 tumors, 25% for T2 tumors, 49% for T3 tumors and 63% for T4 tumors.<sup>27</sup>

Small melanomas may present as flat or dome-shaped tumors. With time the melanoma ruptures Bruch's membrane and forms its pathognomonic mushroom shape, which can be easily visualized on USG. Vitreous hemorrhage may also be evident if the tumor has infiltrated the retina after Bruch's membrane rupture.<sup>28</sup>

USG is the auxiliary method most often used clinically in the diagnosis of uveal melanoma. The tumor typically shows low to medium internal reflectivity on A-mode USG and appears as an acoustically hollow mushroom- or dome-shaped choroidal mass on B-mode USG. In A-mode, the low to medium internal reflectivity of the tumor decreases toward the sclera. This allows discrimination from hemangioma, which typically shows high reflectivity in this mode. In B-mode, tumors appear as a hyper-echoic mass with lower reflectivity than the surrounding choroid, thus giving an acoustically hollow appearance. Choroidal excavation may also be evident, which is more common in large

tumors, and orbital shadowing may be observed as well.<sup>29,30</sup> USG is also useful in the evaluation of extraocular extension; areas of hyporeflectivity compared to normal orbital tissue are considered orbital extension of the tumor.<sup>28</sup>

UBM is useful for the evaluation of tumors which originate from the ciliary body. This technique allows the visualization and evaluation of hyporeflective plaques on the tumor surface, tumor-specific vasculature, internal reflectivity and, if present, extraocular extension.<sup>31</sup> Anterior segment OCT is a newer technique used in the imaging of iris and ciliary body melanoma, but it does not yield the same results as USG due to the lack of penetration into deeper tissues.<sup>32</sup> In the absence of these auxiliary imaging methods, transillumination, gonioscopy, and oblique biomicroscopy, which allows the visualization of the tumor while the patient looks in the direction of the lesion, can assist visualization of ciliary body melanomas.<sup>28</sup>

Uveal melanomas feature intrinsic tumor circulation as well as choroidal circulation. The observation of this double circulation pattern or leakage from tumoral vasculature is occasionally necessary in order to confirm the diagnosis. FFA, which can visualize these features, is an important technique during the differential diagnosis from other lesions. FFA is also used in the detection and follow-up of complications arising after brachytherapy such as radiation retinopathy and radiation maculopathy.

OCT can be utilized in ocular oncology as an auxiliary test in diagnosis, treatment planning and evaluating treatment response. Spectral domain OCT (SD-OCT) allows the detailed evaluation of changes in the retina and retinal pigment epithelium overlying lesions in choroidal melanoma. Choroidal melanomas are usually easily distinguished from choroidal nevi based on size, but this distinction may be difficult with lesions less than 3 mm thick. In such cases, OCT can facilitate the detection of features like subretinal fluid, which is considered one of the high-risk features predicting transformation into melanoma.<sup>33,34,35</sup> With newly developed imaging methods such as enhanced depth imaging it is now possible to examine deeper tissues like the choroid and sclera. With this technique, choroidal nevi appear as dome-shaped or flat lesions causing deep choroidal shadowing

depending on the pigmentation of the tumor. The retinal pigment epithelium overlying the mass may be atrophied or absent, with choriocapillaris compression and photoreceptor loss in this area. Although choroidal melanomas may exhibit all of these characteristics, studies have demonstrated that shaggy photoreceptors and subretinal fluid are indicative of choroidal melanoma in the differential between nevus and melanoma (Figure 1).<sup>33,34,35</sup>

On FAF imaging, pigmented tumors exhibit moderate hypoautofluorescence, whereas nonpigmented (amelanotic) tumors show moderate hyperautofluorescence. In both types of tumors, the areas of hyperautofluorescence can be seen due to the presence of orange pigment, drusen and subretinal fluid overlying the tumor. Presence of orange pigment can be confirmed by comparing these hyperautofluorescent areas to the suspicious lesions seen in fundoscopic examination. This method may also reveal hypoautofluorescent retinal pigment epithelium defects, such as hyperplasia, atrophy and fibrous metaplasia, or hyperautofluorescent drusen, both of which indicate chronic stable nevus.<sup>36</sup>

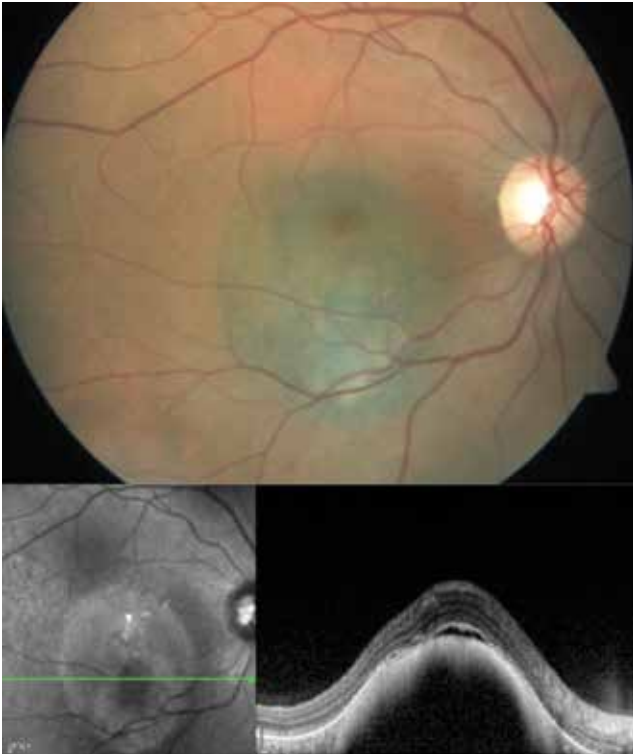Computed tomography (CT) and magnetic resonance imaging (MRI) can be utilized when tumor visualization by clinical examination presents a challenge, as in patients with media opacities like cataract, vitreous hemorrhage or retinal detachment. Patients with unilateral cataract in particular should be carefully evaluated for uveal melanoma, keeping in mind that ciliary body melanoma may cause unilateral or asymmetric cataract via pressure exerted on the lens.<sup>30</sup> In patients with unilateral hypermature cataract, it should be kept in mind that dense cataract can resemble ciliary body melanoma on oblique imaging of the lens. Pseudomelanoma due to hypermature cataract can be identified using USG by the presence of an echodense cortex forming anterior and posterior borders, lack of contiguity with the uvea, and ring melanoma-like visibility in all four quadrants.<sup>37</sup> USG is the first choice when a mass cannot be visually evaluated due to media opacity; CT and MRI can be utilized if a differential diagnosis is still not possible after USG. These imaging methods also have an important role in the evaluation of extraocular extension. On CT

**Table 1. American Joint Committee on Cancer staging of uveal melanoma based on extent of tumor-node- metastasis**

Stage	T (Extent of tumor)	N (Lymph node involvement)	M (Distant metastasis)
I	T1a	N0	M0
IIA	T1b-d, T2a	N0	M0
IIB	T2b, T3a	N0	M0
IIIA	T2c-d, T3b-c, T4a	N0	M0
IIIB	T3d, T4b-c	N0	M0
IIIC	T4d-e	N0	M0
IV	Any T	N1	M0
	Any T	Any N	M1a-c

T: Tumor, N: Node, M: Metastasis

Source: Edge SB, Byrd DR, Compton CC. Malignant Melanoma of the Uvea. In: American Joint Committee on Cancer Staging Manual (7th ed). New York, NY: Springer; 2010:547-560.



**Figure 1.** Color fundus photograph and spectral domain-optical coherence tomography image of choroidal melanoma in the posterior pole of the right eye before treatment

it appears as a hyperdense mass with mild/moderate contrast and distinct margins. On MRI, the tumor characteristically returns a hyperintense signal on T1-weighted images and hypointense signal on T2-weighted images. However, this can also be observed in the subacute phase of a limited hemorrhage, causing it to mimic an intraocular mass. Circumscribed choroidal hemangioma is also included in the differential diagnosis, especially of amelanotic melanomas. Like choroidal melanoma, hemangiomas have a hyperintense signal in T1-weighted MRI, but on T2-weighted images they are isointense to the vitreous. These imaging methods are not strictly necessary in the diagnosis stage, but are a requirement in the planning stage of proton beam therapy or stereotactic radiotherapy (SRT).<sup>28</sup>

Intraocular tumors can be biopsied by several methods. Anterior segment tumors can be evaluated by aqueous humour sampling, incisional or excisional biopsy. FNAB (transscleral, transvitreal or transcameral), vitrectomy biopsy, incisional or excisional biopsy (endoresection or transscleral resection) can be done in order to evaluate posterior segment intraocular tumors.<sup>38</sup>

Studies on tumor doubling time of choroidal melanoma indicate that micrometastases occur several years before diagnosis.<sup>39,40</sup> Unlike cutaneous melanoma, uveal melanoma spreads via the blood and not via the lymphatic system, unless there is invasion of the conjunctiva by the tumor. Extraocular extension occurs hematogenously by penetration into the vortex veins and emissary channels.<sup>41</sup> Small melanomas are usually preexisting small nevi monitored for growth, and

6-8% of diagnosed uveal melanomas originate from nevi.<sup>21,28</sup> Considering that most patients never undergo an ophthalmologic examination prior to their uveal melanoma diagnosis, the actual rate of nevus to melanoma transformation is certainly higher. Singh et al.<sup>42</sup> found malignant transformation of choroidal nevus at a rate of 1 in 8,845 patients. Therefore, clinicians should monitor existing choroidal nevi in consideration of established risk factors predictive of tumor growth. High-risk factors predictive of growth of suspicious pigmented choroidal lesions into melanoma include presence of symptoms, tumor thickness greater than 2 millimeters, presence of subretinal fluid and orange pigment, tumor margin within 3 mm of the optic disc, ultrasonographic hollowness, and absence of halo.<sup>43,44,45</sup>

Posterior uveal melanoma can be confused with many lesions of the retina, retinal pigment epithelium and choroid. According to studies and case reports, the most commonly confused lesions are, in order of frequency, choroidal nevus, peripheral exudative hemorrhagic chorioretinopathy, congenital retinal pigment epithelium hypertrophy, hemorrhagic detachment retinal or retinal pigment epithelium, circumscribed choroidal hemangioma and age-related macular degeneration (AMD).<sup>46</sup> AMD, extramacular disciform lesions, spontaneous subretinal hemorrhage, polypoidal choroidal vasculopathy and various lesions such as arterial macroaneurysm that present with hemorrhage may simulate choroidal melanoma. During clinical examination, it should be kept in mind that patients with AMD may exhibit macular changes in the fellow eye, and tests such as FFA and ICGA may aid differential diagnosis by revealing intrinsic tumor circulation of choroidal melanoma.<sup>46</sup>

Clinical prognostic factors in uveal melanoma include older age, male gender, increased tumor size, tumor location, diffuse growth pattern of the tumor, presence of extraocular extension, and progression of tumor stage according to AJCC classification. Histopathological risk factors related to prognosis include epithelioid cell type, increased mitotic activity, increased tumor infiltrating macrophages and lymphocytes, expression of human leukocyte antigen and insulin-like growth factor receptor-1, and types of extravascular matrix patterns.<sup>3,23,47,48</sup> In 1931, Callender<sup>49</sup> first classified uveal melanoma by histologic cell type as spindle type A, spindle type B, fascicular, epithelioid, and mixed.<sup>50</sup> That classification system was later modified by McLean et al.<sup>50</sup> and uveal melanoma is currently histologically classified as one of three histologic subtypes: spindle cell, epithelioid cell, and mixed cell types. It is generally accepted that epithelioid cell melanoma is associated with the worst prognosis and spindle cell melanoma with the best.<sup>49,50,51</sup>

In their study evaluating metastatic death in 847 uveal melanoma patients, Coupland et al.<sup>52</sup> reported tumor base width, epithelioid cells, mitotic rate and extraocular extension as the clinical and histopathologic factors with prognostic value. Eskelin et al.<sup>53</sup> studied tumor doubling time and found that clinically detectable metastases appear at most 5 years after treatment, but claimed that metastases may be observed up to 25 years later because micrometastases begin forming years before treatment.



Studies utilizing immunohistochemical techniques to better understand tumor and microenvironmental characteristics have demonstrated that chemokine receptor CCR7 is strongly expressed in uveal melanoma cells and is associated with systemic metastasis.<sup>54,55</sup>

#### Differential Diagnosis

Uveal melanoma is divided into iris, ciliary body and choroidal melanoma, and certain lesions should be considered in the differential diagnosis of these subtypes. Possible diagnoses of a suspicious iris lesion other than iris melanoma include iris nevus, iris pigment epithelial cyst, iris stromal cyst, metastatic tumor of the iris, melanocytoma, iris atrophy and Cogan-Reese syndrome. In addition to melanoma, the differential diagnosis of ciliary body tumors should include staphyloma, medulloepithelioma and leiomyoma. The majority of uveal melanomas are choroidal melanoma, which can be simulated by a variety of lesions. Among these are choroidal tumors, especially choroidal nevus, metastatic tumors, choroidal hemangioma, and osteoma; hemorrhagic conditions like AMD and hemorrhagic choroidal detachment; retinal tumors such as congenital retinal pigment epithelium hypertrophy and retinal pigment epithelium adenocarcinoma; and inflammatory lesions like posterior scleritis.

#### Systemic Metastasis in Uveal Melanoma

In a study of 8,033 uveal melanoma patients, Shields et al.<sup>24</sup> found systemic metastasis rates of 8%, 15% and 25% at 3, 5 and 10 years, respectively. In relation to tumor size, metastases were seen in 12% of small melanoma, 26% of medium melanoma and 49% of large melanoma at 10 years follow-up. In the Collaborative Ocular Melanoma Study (COMS), the 5- and 10-year metastasis rates in choroidal melanoma patients were 25% and 34%, respectively, independently of tumor size.<sup>56</sup> Examination of the link between age and metastasis rates revealed systemic metastasis at 10 years in 10% of uveal melanoma patients 11-20 years old, 21% in patients 41-50 years old, and 30% in patients 71-80 years old. These results support the opinion that the systemic metastasis rate increases with advancing age in uveal melanoma.<sup>3</sup> Systemic metastases are most commonly observed in the liver (93%), lungs (24%) and bones (16%).<sup>56</sup> After the formation of metastasis, survival time depends on the location of the metastasis. Patients with liver metastases survive for an average of 4-6 months, with a 1-year survival rate of 10-15%. Reported survival time for patients with other metastases is 19-28 months.<sup>57,58</sup>

#### Prognosis of Uveal Melanoma

Although tumor size is currently considered the primary factor affecting prognosis, the importance of histopathologic factors and, in recent years, genetic factors has also gained recognition.

#### Genetic Indicators

##### Cytogenetic and Molecular Cytogenetic

Despite advances in diagnosis and treatment, uveal melanoma continues to be a life-threatening malignancy, and systemic metastasis is seen in approximately half of patients during long-term follow-up.<sup>23</sup> Studies in the last 20 years have concentrated on mutations and their molecular basis which may

have a role in the pathogenesis of uveal melanoma and formation of systemic metastasis. Genetic alterations in uveal melanoma are investigated using methods such as karyotyping, single nucleotide polymorphism, fluorescent in situ hybridization, microsatellite analysis and comparative genomic hybridization at the deoxyribonucleic acid (DNA) level, and with gene expression profiling (GEP) at the ribonucleic acid (RNA) level.<sup>59,60,61,62,63</sup>

The first reported chromosomal alteration to be associated with poor prognosis in uveal melanoma was chromosome 3 monosomy.<sup>64,65,66</sup> In subsequent studies, this chromosomal abnormality was found to be associated with epithelioid cell type, presence of microvascular loops, tumor base diameter, ciliary body involvement and cancer-related death caused by metastasis.<sup>59,60</sup> Chromosome 3 loss is usually accompanied by gain in chromosome 8 (8q).<sup>64,66,67</sup> Gain in chromosome 8q, especially together with monosomy 3, has been shown to be associated with high metastasis risk.<sup>68,69</sup> In a study including 452 choroidal melanoma patients, Damato et al.<sup>68</sup> used multiplex ligation-dependent probe amplification to compare patients with disomy 3, monosomy 3 and both monosomy 3 and 8q gain, and reported 10-year melanoma-related mortality rates of 0%, 55% and 71% in the three groups, respectively.

Other genetic abnormalities that have been described include loss of chromosome 1p and gains in chromosome 6q and chromosome 8p.<sup>70</sup> Patients without chromosome 3 abnormalities usually exhibit gain of chromosome 6p, and this finding is associated with good prognosis.<sup>71,72</sup> A study evaluating histopathologic characteristics by karyotype analysis demonstrated that the addition of chromosome 3 loss and chromosome 8q gain to extraocular extension (extrascleral) significantly decreases metastasis-free survival.<sup>73</sup>

#### Molecular Genetic

In RNA-based GEP studies evaluating the messenger RNA (mRNA) expression of many genes, uveal melanoma could be divided into two groups: patients with low metastasis risk (class 1) and patients with high metastasis risk (class 2).<sup>62,63,74</sup> This classification was proposed by Onken et al.,<sup>63</sup> who determined 8-year survival rates as 95% in class 1 and 31% in class 2. They later transferred their GEP technique to a polymerase chain reaction-based assay analyzing mRNA expression of 12 discriminator genes and 2 control genes in order to create a more clinically feasible standardized test.<sup>63,75</sup> Trolet et al.<sup>76</sup> performed array-based comparative genomic hybridization on 86 patients with uveal melanoma and 66 patients with liver metastasis; one of their important findings was that liver metastases were found in 14% of patients determined as class 1.

A variety of steps, such as tumor suppression, G-protein mediated signal transduction, adhesion molecule expression and retinoic acid response, have been investigated in order to elucidate the molecular pathways involved in uveal melanoma. Although less than 1% of all uveal melanoma cases are familial, studies have demonstrated that these patients carry many mutations, primarily germline mutation of *BAP1*, and have suggested that these mutations may be responsible for transmission in families.<sup>14,15</sup>

Activation of the mitogen activity protein kinase (MAPK) pathway plays a role in the development of many cancers, especially melanocytic neoplasms.<sup>77</sup> This pathway can be activated by various mechanisms, and activation via *RAS* and *B-RAF* gene mutations is common in cutaneous melanoma. Although MAPK pathway activation has also been reported in uveal melanoma, *B-RAF* or *RAS* mutations are rare. However, some studies have attributed this to limitations in the techniques used and claim to have detected *B-RAF* mutations in uveal melanoma.<sup>77,78,79</sup>

G protein-coupled receptors function with G proteins, which have various alpha ( $\alpha$ ) subunits. One of these subunits, called  $G_q$  or  $G_{q/11}$ , is encoded by the *GNAQ* and *GNA11* genes. Daniels et al.<sup>80</sup> found that 91% of patients with large melanoma had *GNAQ* (47%) or *GNA11* (44%) mutations, and Van Raamsdonk et al.<sup>81</sup> detected *GNAQ* mutations in patients with Nevus of Ota and uveal melanoma. Somatic mutations in *GNAQ* or *GNA11* activate mitogen-activated kinase (MEK), phosphoinositide 3-kinase/protein kinase B, protein kinase C and yes-associated protein related pathways, which has led to an increasing number of clinical trials targeting these pathways for patients with metastatic uveal melanoma. These oncogenic mutations are seen in the early stages of tumorigenesis, as in benign uveal nevi, and are not associated with molecular class (class 1 or 2) or with metastasis.<sup>81,82,83,84,85</sup> Clinical studies have demonstrated improved survival of metastatic uveal melanoma patients with selumetinib, a MEK pathway inhibitor, compared to temozolomide.<sup>86</sup>

The BRCA-1 associated protein-1 (*BAP1*) tumor suppressor gene, located on chromosome 3p21, codes the ubiquitin carboxy-terminal hydrolase enzyme which is among the enzymes responsible for tumor-suppressing activity in cancer cells, and regulates the activity of some proteins through deubiquitination. For example, histone H2A regulates the expression of certain genes; deubiquitination of the *BAP1* region is a critical step in tumor-suppressing function. Somatic mutation in this gene is observed in many cancers including breast, lung and mesothelioma and germline mutations have been found in familial uveal melanoma and mesothelioma cases.<sup>86,87</sup> It has been shown that *BAP1* mutation appears in the late stages of tumorigenesis, causes changes in phenotype, and is associated with metastatic behavior and class 2 genetic structure in 84% of patients.<sup>88,89</sup> Mutation of one allele is usually accompanied by loss of the other entire copy of chromosome 3.

In contrast to the previously described mutations, splicing factor 3b subunit 1 (*SF3B1*) gene mutations have been found at a rate of 19% in uveal melanomas and are associated with good prognosis.<sup>90</sup> Mutations in this gene also occur later in tumor progression and are relatively specific to class 1 tumors. However, it was shown that patients with disomy 3 tumors and *SF3B1* mutations have increased risk of metastatic disease at a longer follow-up time (Koopmans AE, Prognostic implications of acquired genetic changes in uveal melanoma. Unpublished data, Erasmus University, Rotterdam, Netherlands).

Another mutation associated with good prognosis is the eukaryotic translation initiation factor 1A (*EIF1AX*) gene mutation, which has been reported in 24% of uveal melanomas.<sup>91</sup>

#### Therapeutic Approaches in Uveal Melanoma

Treatment for uveal melanoma is initiated at the time of diagnosis and is not limited to the intraocular tumor alone. Management of uveal melanoma also includes the assessment of prognostic factors currently used in clinical practice and, when necessary, the planning of adjuvant therapies targeting systemic disease; post-treatment monitoring and control of recurrence and possible treatment-related ocular side effects; visual function assessment and visual rehabilitation using appropriate treatment options; routine systemic evaluation for metastasis risk; and psychiatric evaluation. Neglecting any one of these steps may lead to treatment failure ending in mortality, despite successful treatment of the tumor.

The currently accepted and clinically applied understanding of tumor management begins with a proper evaluation of prognostic factors, after which one or more therapies are chosen in consideration of these factors to both control the tumor and minimize impact to healthy tissues. Decisions regarding which treatment options are appropriate and applicable are made based on tumor size, location and extension and take into consideration the patient's preferences and expectations.

Overall prognosis should be evaluated as a combination of prognosis determined by host genetic factors and ocular and systemic prognosis according to treatment options administered.

The two main treatment options for uveal melanoma patients without systemic metastasis are eye-conserving therapies and enucleation. Studies have demonstrated that despite developments in treatment methods and the increasing tendency toward eye-sparing therapies over the last 30 years, survival rates have remained constant. This indicates that successful local treatment of the eye does not affect survival. Therefore, identifying patients at risk of metastasis and referring them to adjuvant therapies in addition to local treatment is crucial.

#### Primary Tumor Treatment

##### Should every tumor be treated?

To date, the traditional approach when faced with a small, pigmented choroidal tumor has been monitoring the lesion until findings on color fundus photography indicate growth. However, as it is impossible to know whether a tumor will become metastatic before it reaches a size requiring treatment, delaying treatment may result in metastatic spread. On the other hand, considering that 30-40% of small melanomas are in close proximity to the optic disc and macula, treating all suspicious choroidal tumors would result in unnecessary ocular morbidity and vision loss.<sup>92</sup>

Therefore, small tumors should be evaluated in the context of factors identified in the literature as indicating malignant transformation, and decisions should be made after fully informing patients of the benefits and risks involved in treatment.<sup>43,44,45,87</sup> Instead of observation, the current opinion favors initiating treatment when risk factors are present; observation at regular intervals is still considered appropriate in a small minority of cases.

In the COMS, tumors with thickness less than 3 mm and basal diameter up to 16 mm tumors were classified as small melanomas, and 204 choroidal melanoma cases were evaluated in the small melanoma arm of the study. During follow-up, 21% of these patients required treatment at 2 years, 33% at 5 years, and 38% at 7 years. Melanoma-related mortality was 1% at 5 years and 3.7% at 8 years.<sup>93,94</sup> Enucleation and local treatment of the tumor by brachytherapy are controversial because of their impact on visual acuity as well as the low rate of melanoma-related mortality in the long term with small melanomas.

### Eye-Conserving Therapies

#### Photocoagulation

Photocoagulation was frequently used in the past to treat small choroidal melanoma, first with xenon arc and later with argon laser photocoagulation. Despite superior tumor control with xenon arc photocoagulation, the argon laser results in fewer complications.<sup>95</sup> Today, small tumors less than 3 mm thick and located more than 3 mm from the fovea are treated with transpupillary thermotherapy (TTT).<sup>96,97,98</sup>

#### Transpupillary Thermotherapy

TTT is a diode laser-based method used to treat small and medium-sized melanomas (tumor thickness less than 4 mm).<sup>96,97,98,99</sup> In their meta-analysis, Singh et al.<sup>100</sup> found an average recurrence rate after primary TTT in small melanoma patients of 17% (8-56%) and reported that 7% of these recurrences involved extrascleral extension. In brief, patients undergoing TTT alone for uveal melanoma should be selected carefully, keeping in mind that although visual prognosis is good, there remains the long-term possibility of recurrence with high metastatic risk (Figure 2).

#### Radiotherapy

Radiotherapy is currently the most common treatment for uveal melanoma, especially posterior uveal melanoma. In clinical application, radiotherapy can be administered in the form of radioactive plaque, external beam radiotherapy or SRT.

Brachytherapy is the direct irradiation of a tumor via the application of a radioactive source (radioisotope) to the tumor surface or interior.<sup>101</sup> There are two types of radioactive sources used in brachytherapy, gamma- or X-ray emitting isotopes and beta-particle-emitting isotopes. Of the isotopes most commonly used in ophthalmic radioactive, Cobalt-60, Palladium-103 and Iodine-125 are gamma sources and Ruthenium-106 (Ru-106) is a beta-particle source. Ru-106 plaques have been found effective for small and medium tumors (basal diameter up to 16 mm and thickness up to 8 mm) when applied alone or in combination with TTT (Figure 3).<sup>102</sup>

The medium tumor arm of the COMS included tumors 2.5-10 mm thick with a basal diameter less than 16 mm and compared patients treated by I-125 plaque brachytherapy versus enucleation.<sup>103</sup> There was no significant difference between the two groups in 10-year mortality. Melanoma-related mortality rates at 5, 10 and 12 years were 10%, 18% and 21% in the brachytherapy group, versus 11%, 17% and 17% in the enucleation group.

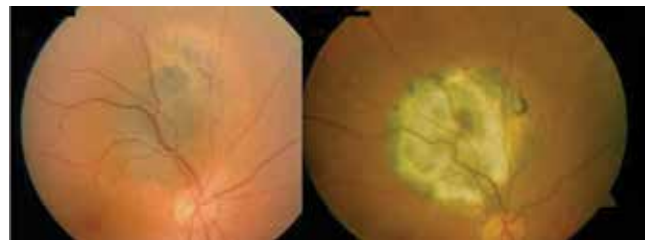Finger et al.<sup>104</sup> treated 400 uveal melanoma patients with Palladium-103 and found a metastasis rate of 6% after 51 months of follow-up. They also estimated the 5- and 10-year survival rates as 7.3% and 13.4%. Another study evaluating patients treated with Ru-106 plaques observed local tumor recurrence in 3.9% and reported estimated metastasis rates at 5 and 10 years of 30.9% and 68.2%.<sup>102</sup> Studies using Ru-106 plaques have shown that this isotope carries an increased risk of local recurrence with tumors with thickness over 5 mm.<sup>106</sup> For tumor thicknesses between 5 and 8 mm (with basal diameter not exceeding 16 mm), Ru-106 plaque brachytherapy can be utilized but should be supported by the application of TTT to the tumor apex (Figure 4).<sup>102,105,106</sup>

#### External Beam Therapy

External beam therapy is the irradiation of a tumor with charged particles such as proton and helium ion beams or with stereotactic methods.<sup>107</sup> This modality can be used to treat tumors up to 14 mm thick with a basal diameter up to 28 mm.

#### Proton Beam Therapy

Unlike brachytherapy and fractionated SRT, proton beam therapy delivers a homogenous dose of radiation to the entire tumor and due to the Bragg effect the radiation dissipates quickly beyond the edge of the target.<sup>108,109</sup> This allows the delivery of a high dose of radiation to the tumor while preserving adjacent normal tissue; however, tissues in the path of the beam as it enters the body and targets the tumor also receive a high dose of radiation. In theory, all uveal melanomas could be treated by proton beam therapy but for large melanomas the visual prognosis and eye conservation rates remain low.<sup>110</sup> The first choice of treatment for large tumors located in the superotemporal quadrant should be radioactive plaque radiotherapy in order to spare the lacrimal glands. In a series of 2,413 melanoma patients treated with proton beam therapy, Desjardins et al.<sup>111</sup> reported 5- and 10-year metastasis rates of 18.5% and 26.6%, respectively. Local recurrence was observed in 4% of the patients at 5 years and 10% at 10 years, with most occurring in the first 3 years after treatment. After a follow-up period of about 8 years, complications noted were loss of eyelashes in 12%, retinal detachment in 8.5%, glaucoma in 23.4%, dry eye in 6%, cataract requiring surgery in 15%, optic neuropathy in 18% and maculopathy in 37% of the patients. TTT was used as an adjuvant therapy when the tumor was close to the macula or to decrease the likelihood of neovascular glaucoma, and recurrence was not observed in these patients.



**Figure 2.** Color fundus photographs of choroidal melanoma before and after treatment with transpupillary thermotherapy

### Stereotactic Radiotherapy

SRT is the irradiation of a tumor with a photon beam. In SRT the radiation is delivered as a single dose, while in fractionated SRT the total dose is delivered as smaller equal doses. An advantage of treating with a stereotactic photon beam is that no surgical procedure is required to determine the tumor's location, the tumor borders are determined by MRI and CT.<sup>112,113</sup> Although proton beam therapy (charged particle therapy) is theoretically superior in terms of sparing healthy tissue from the effects of radiation, stereotactic radiosurgery might be more advantageous in certain cases since it does not require preoperative surgical marking and is more cost-effective.<sup>114,115</sup>

The devices used in stereotactic photon beam irradiation are the Gamma Knife, linear accelerator, and the CyberKnife. Ocular immobilization is required for both stereotactic radiosurgery and SRT techniques. This can be achieved with retrobulbar anesthesia or vacuum-assisted immobilization frame for the Gamma Knife and the cameras used to monitor eye movements for the linear accelerator.<sup>113</sup>

#### Gamma Knife

First applied in the treatment of brain tumors, the Gamma Knife has since been used to treat uveal melanomas with successful results.<sup>116,117</sup> However, it is not a preferred treatment modality due to high reported rates of radiation retinopathy and neovascular glaucoma (8.6-64%).<sup>118,119,120,121</sup> The main problem with this technique is ocular fixation. Zehetmayer et al.<sup>122</sup> used the Gamma Knife to treat 62 uveal melanoma patients unsuitable for Ru-106 plaque brachytherapy and reported higher morbidity with tumors larger than 8 mm and a dose of 10 Gy/fraction was a high risk factor for radiation-induced inflammation.

#### CyberKnife

CyberKnife radiosurgery was also first used in brain surgery and is currently utilized to treat uveal melanoma. Zorlu et

al.<sup>123</sup> used CyberKnife to treat 5 patients who were not eligible for plaque radiotherapy or local resection and reported that 3 patients showed reduction in tumor size at 8-month follow-up. In the same center, 163 uveal melanoma patients were treated with CyberKnife (stereotactic radiosurgery/fractionated SRT). During the follow-up period of mean 24.2 months (range, 2-79 months), local control was achieved in 74% of patients and progression was observed in 17.2% (Yazıcı et al., submitted for publication) (Figure 5).

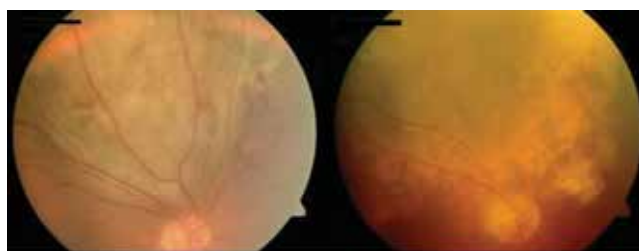
**Linear accelerator:** The linear accelerator is used to treat uveal melanoma by stereotactic hypofractionated radiotherapy. The advantages of this approach are less radiation exposure to the healthy tissues adjacent to the tumor and avoidance of long-term effects. Noninvasive fixation systems designed for use with linear accelerators have increased patient comfort and compliance with treatment.<sup>113</sup>

### Complications of Radiotherapy

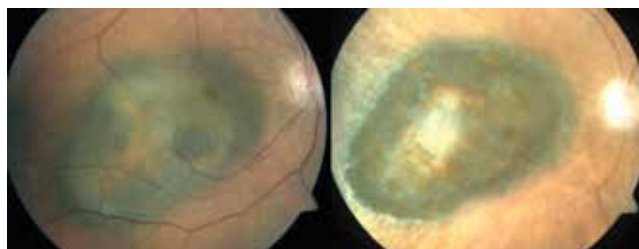
#### Radiation Retinopathy

Radiation retinopathy is a chronic, progressive vasculopathy of the retinal capillaries resulting from radiotherapy-induced damage to the vascular endothelium.<sup>124</sup> This damage causes capillary dilation, increased vascular permeability, thrombosis, retinal exudate and hemorrhage, eventually leading to full thickness retinal atrophy (Figure 6). Capillary non-perfusion is evident on FFA, the gold standard in the diagnosis of radiation retinopathy.<sup>125</sup> Radiation retinopathy is observed in 42% of patients 5 years after brachytherapy, and usually occurs in the first 2 years after treatment.<sup>126</sup> The first sign may be a decrease in visual acuity due to subclinical macular edema, and in fact the detection of macular edema on OCT is an indicator that radiation maculopathy may develop an average of 5 months later.<sup>127,128</sup> Retinopathy is dependent on the total radiotherapy dose received and the area of the retina irradiated. It is generally accepted that retinopathy develops rarely with radiation doses under 35 Gy and it occurs in about half of patients receiving 65 Gy or more.<sup>129</sup> Ischemic retinopathy can often progress to proliferative retinopathy, which may be observed at an average of 2.5 years after plaque radiotherapy, and vitreous hemorrhage may occur in 15.1% of patients at 5 years after treatment.<sup>130,131</sup> Guyer et al.<sup>132</sup> reported the incidence of radiation maculopathy after proton beam radiotherapy as 90%.

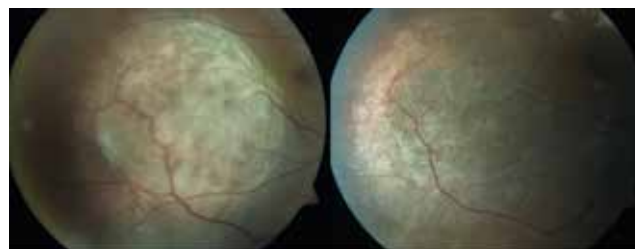
Treatment options include panretinal or focal laser photocoagulation, photodynamic therapy, intravitreal or periocular triamcinolone injection, oral pentoxifylline,



**Figure 3.** Color fundus photographs of choroidal melanoma before and after treatment with radioactive plaque brachytherapy (Iodine-125)



**Figure 4.** Color fundus photographs of choroidal melanoma before and after treatment with radioactive plaque brachytherapy (Ruthenium-106)



**Figure 5.** Color fundus photographs of choroidal melanoma before and after treatment with CyberKnife (stereotactic radiosurgery)

hyperbaric oxygen, intravitreal anti-vascular endothelial growth factor (anti-VEGF) and intravitreal silicone application prior to brachytherapy.<sup>133,134,135</sup> Missotten et al.<sup>136</sup> showed that VEGF-A levels are higher in the aqueous humour of both treated and untreated uveal melanoma patients. Taking into account that VEGF levels are elevated in uveal melanoma and further elevated in radiation retinopathy, Shah et al.<sup>137</sup> administered intravitreal bevacizumab (Avastin) injections for 2 years to 292 of 418 patients treated with plaque radiotherapy and observed the other 126 patients without further treatment. They observed lower rates of OCT-evident macular edema and radiation retinopathy during follow-up in the patients treated with bevacizumab.

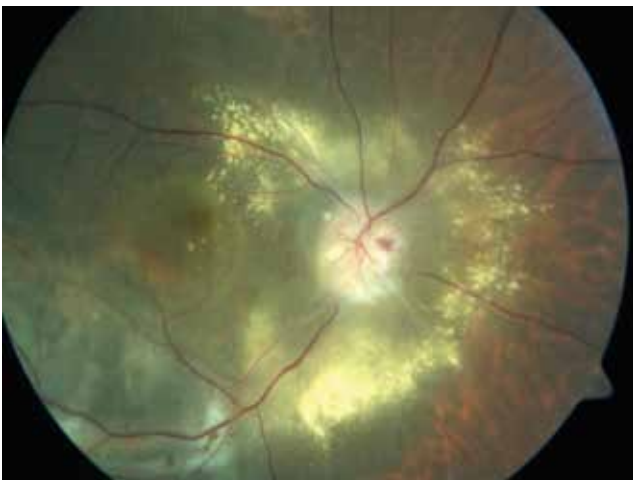#### Radiation-Induced Optic Neuropathy

Radiation-induced optic neuropathy typically causes sudden, painless, unilateral vision loss starting as early as 3 months or up to 8 years after radiation exposure.<sup>138,139</sup> Since the pathogenesis of the optic nerve damage is not fully understood, radiation-induced optic neuropathy is considered to be radionecrosis of the optic nerve and chiasm. This presents clinically as optic disc edema with lipid accumulation and hemorrhages; later, optic atrophy with ghost vessels are observed. Systemic and intravitreal corticosteroids, hyperbaric oxygen therapy, anticoagulant therapy, and intravitreal anti-VEGF therapy have been used in treatment.<sup>139,140,141,142</sup> Finger and Chin<sup>139</sup> treated 14 choroidal melanoma patients who developed radiation-induced optic neuropathy after radioactive plaque therapy with intravitreal anti-VEGF injections (at least 2 injections at 6-8 week intervals) and reported regression of optic disc edema and improvement of papillary hemorrhage.

#### Surgery

##### Enucleation, Exenteration, Local Resection

Although enucleation was the most common treatment choice in the past, it is currently reserved for cases with the worst visual prognosis, such as patients with large uveal melanoma (tumoral thickness greater than 8 mm), with choroidal melanoma surrounding the optic nerve, or presenting with severe



**Figure 6.** Color fundus photograph of a choroidal melanoma patient with radiation retinopathy and maculopathy

hemorrhage, retinal detachment or vitreous hemorrhage. There is no consensus on the maximum tumor thickness that can be treated by radiotherapy. If the COMS is accepted as a guide, the plaque applied should exceed the tumor margins by 2 mm. In practice, episcleral application of a plaque larger than 25 mm is not possible, limiting the use of plaque radiotherapy to tumors with a maximum basal diameter of 21 mm. Only medium melanomas were treated with plaque radiotherapy in the COMS; for large melanomas, enucleation alone or in combination with preoperative external beam therapy were applied. There was no significant difference in the 10-year survival rate between the group that received preoperative radiotherapy and the group that did not.<sup>143</sup> Studies in which large tumors (basal diameter over 16 mm and thickness greater than 8 mm) were treated with plaque radiotherapy have reported poor visual prognosis even when the eye is spared.<sup>144,145</sup>

In terms of survival, many studies have demonstrated no significant difference in mortality between eye-conserving and surgical treatment approaches. Comparison of the COMS medium uveal melanoma patients treated with plaque brachytherapy and those that underwent enucleation revealed no significant difference in long-term survival.<sup>145,146</sup> Therefore, in recent years eye-conserving treatments have gained favor over enucleation.

Local resection is an alternative treatment choice for choroidal melanoma patients which spares the eye and, more importantly, allows a detailed histopathologic and cytogenetic analysis. The procedure is more preferred in cases of iris and ciliary body melanoma. Iridectomy is currently the first choice for iris tumors, and is indicated in tumors covering up to a third of the iris but not extending to the angle.<sup>147</sup> However, proton beam therapy may be preferable to iridectomy in order to avoid the resulting surgical coloboma.<sup>148</sup> Iridocyclectomy is indicated for tumors with angle or ciliary body involvement.<sup>147</sup> Choroidectomy is currently only performed by a small number of surgeons due to the technical challenges. Tumors can be surgically removed via a transretinal (endoresection) or transscleral (exoresection) route. Plaque radiotherapy is recommended as an adjuvant to exoresection to prevent tumor recurrence, though the preventative application of plaque radiotherapy before endoresection is still controversial.<sup>149,150</sup> Major complications such as retinal detachment and vitreous hemorrhage have been reported with both techniques. Tumor location within one disc diameter of the optic disc has been reported as the most important risk factor for severe vision loss following local resection.<sup>151</sup>

Exoresection is recommended in cases of toxic tumor syndrome, a condition in which the irradiated tumor becomes ischemic and exudative, resulting in macular edema, exudation, serous retinal detachment, uveitis, rubeosis iridis and neovascular glaucoma.<sup>151</sup>

#### Systemic Evaluation

There is no definitive guideline or even a consensus regarding screening tests for systemic metastasis in uveal melanoma. In particular, clinical examinations for the presence of subcutaneous nodules and organomegaly are imperative. Liver function tests include gamma-glutamyl-transpeptidase,



lactate dehydrogenase, alkaline phosphate, aminotransferases and bilirubin levels. Because abnormal liver function test results have lower sensitivity and specificity compared to radiographic investigation, these tests should only be used as a complement to radiography.<sup>152</sup> Metastases undetectable by liver function tests may be evident on USG.<sup>153,154</sup> Contrast MRI is the most sensitive method for liver imaging; CT is highly sensitive but its ability to discriminate from benign lesions is weak.<sup>155,156</sup>

Just as in deciding the course of treatment, it is important to determine the best clinical approach in order to provide individualized patient care and risk stratification for a patient diagnosed with uveal melanoma. The clinical and histopathologic prognostic factors can be used to separate patients into general risk categories, but they are not accurate enough to be used for individualized patient care. Furthermore, chromosomal alterations including chromosome 1p loss, chromosome 3 loss, chromosome 8q gain and chromosome 6p gain might be used for clinical prognostification, but it was shown that they need to be considered together with clinical and histologic risk factors.<sup>68</sup>

As mentioned above, GEP of uveal melanoma allows the accurate discrimination of primary tumors at low metastatic risk (class 1 signature) and high metastatic risk (class 2 signature). The gene expression test was developed for routine clinical use and has been validated in a prospective, multi-center study which reported that the GEP test had prognostic accuracy that was superior to clinicopathologic staging and monosomy 3.<sup>157,158,159</sup> Field and Harbour<sup>158</sup> recommended annual liver imaging for patients in class 1A (low-risk) based on GEP analysis, evaluation every 6 months alternating between liver imaging and liver function tests for class 1B (intermediate-risk) patients, and evaluation every 3 months alternating between liver imaging and liver function tests for class 2 (high-risk) patients.

#### Adjuvant Therapies

Despite advances in the diagnosis and treatment of uveal melanoma, the general mortality remains high due to metastatic disease. It is therefore extremely important to identify patients at high risk for metastasis, and many studies have investigated this topic in recent years. On the other hand, studies of tumor doubling rate have provided evidence that uveal melanomas metastasize before diagnosis. Detection of circulating tumor cells in the bloodstream at time of diagnosis further support this.<sup>39,160,161,162</sup> Metastatic uveal melanoma is resistant to treatment, and there is no evidence that current treatment is able to extend survival. The efficacy of systemic treatment could be improved with adjuvant therapies that target micrometastases instead of macrometastases.

Adjuvant therapies consist of radiotherapy and systemic therapy, which currently target clinically identified macrometastases. Systemic treatment options include chemotherapy, immunotherapy, hormone therapy, biologic therapy and targeted therapy. Unlike other tumors, there are still few studies regarding uveal melanoma. Non-randomized studies conducted so far have utilized dacarbazine, bacilli Calmette-Guerin and systemic interferon, but have not reported

promising results.<sup>163,164,165</sup> Uveal melanoma patients were treated with systemic interferon alpha-2a subcutaneously 3 times a week for 2 years, but there was no significant difference in mortality.<sup>163</sup> Studies of sunitinib, valproic acid, dacarbazine, systemic interferon alpha-2b, vaccination with dendritic cells and ipilimumab as adjuvant therapies are ongoing, and results have yet to be reported.<sup>166</sup> Fotemustine, an alkali cytotoxic chemotherapeutic agent, has been used to treat patients with liver metastasis as both intravenous chemotherapy and as intra-arterial hepatic chemotherapy. Intra-arterial hepatic administration resulted in better tumor response than systemic administration but did not increase survival in the long term.<sup>167</sup> The MAPK pathway, activated by *GNAQ* mutations plays an important role in the pathogenesis of uveal melanoma. Although the MEK-inhibitor selumetinib did not improve survival in cutaneous melanoma, when administered to uveal melanoma patients with *GNAQ* mutation it extended progression-free survival.<sup>168,169</sup> The main limitation of MAPK inhibitors is that the drug is effective for an average of 6-10 months and it is believed this leads to more aggressive recurrences.

Studies on preventing metastasis and extending survival in high-risk uveal melanoma patients are currently in progress. Ipilimumab is being evaluated as a systemic adjuvant therapy following treatment of the primary tumor in patients identified as class 2 by RNA analysis, exhibiting monosomy 3 on DNA analysis, or having a tumor over 8 mm in thickness.<sup>170</sup> Patient enrollment has concluded for a clinical trial evaluating treatment response to dacarbazine and recombinant interferon alpha-2b in patients who exhibit monosomy 3 or 8q gain without any metastasis, but results have not been published yet.<sup>171</sup> Similarly, the c-Ros oncogene inhibitor crizotinib is being administered to patients with genetic class 2 tumors in a phase 2 clinical trial, but the patient recruitment is ongoing and no results have been published.<sup>172</sup> A clinical trial of sunitinib and valproic acid in genetically high metastasis risk uveal melanoma patients is in progress and currently recruiting participants.<sup>173</sup> The inhibition of the hypoxia-inducible factor pathway by arylsulfonamides is another area of continuing research.<sup>174</sup>

In recent years, proteomics and secretomics studies aiming to enable the early detection of metastasis have gained importance. Osteopontin, S100, MIA (melanoma inhibitory activity), VEGF and TPS (tissue polypeptide specific antigen) are among the proteomic markers shown to be elevated in the serum of metastatic uveal melanoma patients. Elevated expression of S100, MCAM, NKI-C3, E-cadherin, c-Met and MIA has been demonstrated in the tissue of metastatic melanomas.<sup>175</sup>

In conclusion, despite advances in the diagnosis of uveal melanoma and treatment for localized disease, up to half of patients will develop fatal metastatic disease. With progress in understanding the molecular landscape of the tumor and the development of treatments targeting the pathways involving *GNAQ/GNA11*, *BAP1*, *EIF1AX*, *SF3B1* mutations and epigenetic mechanisms, in the near future it may be possible to prevent the progression of micrometastases.



## Ethics

Peer-review: Externally and internally peer-reviewed.

## Authorship Contributions

Surgical and Medical Practices: Berçin Tarlan, Hayyam Kıratlı, Concept: Berçin Tarlan, Hayyam Kıratlı, Design: Berçin Tarlan, Hayyam Kıratlı, Data Collection or Processing: Berçin Tarlan, Hayyam Kıratlı, Analysis or Interpretation: Berçin Tarlan, Hayyam Kıratlı, Literature Search: Berçin Tarlan, Hayyam Kıratlı, Writing: Berçin Tarlan, Hayyam Kıratlı.

Conflict of Interest: No conflict of interest was declared by the authors.

Financial Disclosure: The authors declared that this study received no financial support.

## References

- Chang AE, Karnell LH, Menck HR. The National Cancer Data Base report on cutaneous and noncutaneous melanoma: a summary of 84,836 cases from the past decade. The American College of Surgeons Commission on Cancer and the American Cancer Society. *Cancer*. 1998;83:1664-1678.
- Shields CL, Kels JG, Shields JA. Melanoma of the eye: revealing hidden secrets, one at a time. *Clin Dermatol*. 2015;33:183-196.
- Shields CL, Kaliki S, Furuta M, Mashayekhi A, Shields JA. Clinical spectrum and prognosis of uveal melanoma based on age at presentation in 8,033 cases. *Retina*. 2012;32:1363-1372.
- Virgili G, Gatta G, Ciccolallo L, Capocaccia R, Biggeri A, Crocetti E, Lutz JM, Paci E; EUROCARE Working Group. Incidence of uveal melanoma in Europe. *Ophthalmology*. 2007;114:2309-2315.
- Isager P, Osterlind A, Engholm G, Heegaard S, Lindegaard J, Overgaard J, Storm HH. Uveal and conjunctival malignant melanoma in Denmark, 1943-97: incidence and validation study. *Ophthalmic Epidemiol*. 2005;12:223-232.
- Singh AD, Topham A. Incidence of uveal melanoma in the United States: 1973-1997. *Ophthalmology*. 2003;110:956-961.
- Singh AD, Turell ME, Topham AK. Uveal melanoma: trends in incidence, treatment, and survival. *Ophthalmology*. 2011;118:1881-1885.
- Weis E, Shah CP, Lajous M, Shields JA, Shields CL. The association between host susceptibility factors and uveal melanoma: a meta-analysis. *Arch Ophthalmol*. 2006;124:54-60.
- Singh AD, Kalyani P, Topham A. Estimating the risk of malignant transformation of a choroidal nevus. *Ophthalmology*. 2005;112:1784-1789.
- Sumich P, Mitchell P, Wang JJ. Choroidal nevi in a white population: the Blue Mountains Eye Study. *Arch Ophthalmol*. 1998;116:645-650.
- Shields CL, Kaliki S, Livesey M, Walker B, Garoon R, Bucci M, Feinstein E, Pesch A, Gonzalez C, Lally SE, Mashayekhi A, Shields JA. Association of ocular and oculodermal melanocytosis with the rate of uveal melanoma metastasis: analysis of 7872 consecutive eyes. *JAMA Ophthalmol*. 2013;131:993-1003.
- Grin JM, Grant-Kels JM, Grin CM, Berke A, Kels BD. Ocular melanomas and melanocytic lesions of the eye. *J Am Acad Dermatol*. 1998;38:716-730.
- Seddon JM, Gragoudas ES, Glynn RJ, Egan KM, Albert DM, Blitzer PH. Host factors, UV radiation, and risk of uveal melanoma. A case-control study. *Arch Ophthalmol*. 1990;108:1274-1280.
- Martorano LM, Winkelman RR, Cebulla CM, Abdel-Rahman MH, Campbell SM. Ocular melanoma and the BAP1 hereditary cancer syndrome: implications for the dermatologist. *Int J Dermatol*. 2014;53:657-663.
- Wiesner T, Obenaus AC, Murali R, Fried I, Griewank KG, Ulz P, Windpassinger C, Wackernagel W, Loy S, Wolf I, Viale A, Lash AE, Pirun M, Succi ND, Rütten A, Palmedo G, Abramson D, Offit K, Ott A, Becker JC, Cerroni L, Kutzner H, Bastian BC, Speicher MR. Germline mutations in BAP1 predispose to melanocytic tumors. *Nat Genet*. 2011;43:1018-1021.
- Shah CP, Weis E, Lajous M, Shields JA, Shields CL. Intermittent and chronic ultraviolet light exposure and uveal melanoma: a meta-analysis. *Ophthalmology*. 2005;112:1599-1607.
- Pereira PR, Odashiro AN, Lim LA, Miyamoto C, Blanco PL, Odashiro M, Maloney S, De Souza DF, Burnier MN Jr. Current and emerging treatment options for uveal melanoma. *Clin Ophthalmol*. 2013;7:1669-1682.
- Coupland SE. Analysis of intraocular biopsies. *Dev Ophthalmol*. 2012;49:96-116.
- Ah-Fat FG, Damato BE. Delays in the diagnosis of uveal melanoma and effect on treatment. *Eye (Lond)*. 1998;12:781-782.
- Bove R, Char DH. Nondiagnosed uveal melanomas. *Ophthalmology*. 2004;111:554-557.
- Eskelin S, Kivelä T. Mode of presentation and time to treatment of uveal melanoma in Finland. *Br J Ophthalmol*. 2002;86:333-338.
- Damato BE. Time to treatment of uveal melanoma in the United Kingdom. *Eye (Lond)*. 2001;15:155-158.
- Diener-West M, Earle JD, Fine SL, Hawkins BS, Moy CS, Reynolds SM, Schachat AP, Straatsma BR; Collaborative Ocular Melanoma Study Group. The COMS randomized trial of iodine 125 brachytherapy for choroidal melanoma, II: characteristics of patients enrolled and not enrolled. *COMS Report No. 17. Arch Ophthalmol*. 2001;119: 951-965.
- Shields CL, Furuta M, Thangappan A, Nagori S, Mashayekhi A, Lally DR, Kelly CC, Rudich DS, Nagori AV, Wakade OA, Mehta S, Forte L, Long A, Dellacava EF, Kaplan B, Shields JA. Metastasis of uveal melanoma millimeter-by-millimeter in 8033 consecutive eyes. *Arch Ophthalmol*. 2009;127:989-998.
- Shields CL, Kaliki S, Shah SU, Luo W, Furuta M, Shields JA. Iris melanoma: features and prognosis in 317 children and adults. *J AAPOS*. 2012;16:10-16.
- Khan S, Finger PT, Yu GP, Razaq L, Jager MJ, de Keizer RJ, Sandkuil P, Seregard S, Gologorsky D, Scheffler AC, Murray TG, Kivelä T, Giuliani GP, McGowan H, Simpson ER, Corviveau C, Coupland SE, Damato BE. Clinical and pathologic characteristics of biopsy-proven iris melanoma: a multicenter international study. *Arch Ophthalmol*. 2012;130:57-64.
- Shields CL, Kaliki S, Furuta M, Fulco E, Alarcon C, Shields JA. American Joint Committee on Cancer classification of posterior uveal melanoma (tumor size category) predicts prognosis in 7731 patients. *Ophthalmology*. 2013;120:2066-2071.
- Kivelä T. Diagnosis of uveal melanoma. *Dev Ophthalmol*. 2012;49:1-15.
- Shields JA, Shields CL. *Posterior Uveal Melanoma: Diagnostic Approaches*. In: *Intraocular Tumors: An Atlas and Textbook* (2nd ed). Philadelphia PA; Lippincott Williams & Wilkins; 2008:128-138.
- Collaborative Ocular Melanoma Study Group, Boldt HC, Byrne SF, Gilson MM, Finger PT, Green RL, Straatsma BR, Simpson ER, Hawkins BS. Baseline echographic characteristics of tumors in eyes of patients enrolled in the Collaborative Ocular Melanoma Study: COMS report no. 29. *Ophthalmology*. 2008;115:1390-1397.
- Giuliani GP, McGowan HD, Pavlin CJ, Heathcote JG, Simpson ER. Ultrasound biomicroscopic imaging of iris melanoma: a clinicopathologic study. *Am J Ophthalmol*. 2011;151:579-585.
- Bianciotto C, Shields CL, Guzman JM, Romanelli-Gobbi M, Mazzuca D Jr, Green WR, Shields JA. Assessment of anterior segment tumors with ultrasound biomicroscopy versus anterior segment optical coherence tomography in 200 cases. *Ophthalmology*. 2011;118:1297-1302.
- Espinoza G, Rosenblatt B, Harbour JW. Optical coherence tomography in the evaluation of retinal changes associated with suspicious choroidal melanocytic tumors. *Am J Ophthalmol*. 2004;137:90-95.
- Sayanagi K, Pelayes DE, Kaiser PK, Singh AD. 3D Spectral domain optical coherence tomography findings in choroidal tumors. *Eur J Ophthalmol*. 2011;21:271-275.
- Shields CL, Kaliki S, Rojanaporn D, Ferenczy SR, Shields JA. Enhanced depth imaging optical coherence tomography of small choroidal melanoma: comparison with choroidal nevus. *Arch Ophthalmol*. 2012;130:850-856.
- Almeida A, Kaliki S, Shields CL. Autofluorescence of intraocular tumours. *Curr Opin Ophthalmol*. 2013;24:222-232.
- Shields CL, Pellegrini M, Kligman BE, Bianciotto C, Shields JA. Ciliary body and choroidal pseudomelanoma from ultrasonographic imaging of hypermature cataract in 20 cases. *Ophthalmology*. 2013;120:2546-2451.

38. Midena E, Parrozzani R. Biopsies in uveal melanoma. *Dev Ophthalmol*. 2012;49:81-95.
39. Eskelin S, Pyrhönen S, Summanen P, Hahka-Kemppinen M, Kivelä T. Tumor doubling times in metastatic malignant melanoma of the uvea: tumor progression before and after treatment. *Ophthalmology*. 2000;107:1443-1449.
40. Singh AD. Uveal melanoma: implications of tumor doubling time. *Ophthalmology*. 2001;108:829-831.
41. Kivelä T, Kujala E. Prognostication in eye cancer: the latest tumor, node, metastasis classification and beyond. *Eye (Lond)*. 2013;27:243-252.
42. Singh AD, Kalyani P, Topham A. Estimating the risk of malignant transformation of a choroidal nevus. *Ophthalmology*. 2005;112:1784-1789.
43. Shields CL, Shields JA, Kiritli H, De Potter P, Cater JR. Risk factors for growth and metastasis of small choroidal melanocytic lesions. *Ophthalmology*. 1995;102:1351-1361.
44. Shields CL, Furuta M, Berman EL, Zahler JD, Hoberman DM, Dinh DH, Mashayekhi A, Shields JA. Choroidal nevus transformation into melanoma: analysis of 2514 consecutive cases. *Arch Ophthalmol*. 2009;127:981-987.
45. Gass JD. Problems in the differential diagnosis of choroidal nevi and malignant melanoma. XXXIII Edward Jackson Memorial lecture. *Trans Sect Ophthalmol Am Acad Ophthalmol Otolaryngol*. 1977;83:19-48.
46. Shields JA, Mashayekhi A, Ra S, Shields CL. Pseudomelanomas of the posterior uveal tract: the 2006 Taylor R. Smith Lecture. *Retina*. 2005;25:767-771.
47. Singh AD, Shields CL, Shields JA. Prognostic factors in uveal melanoma. *Melanoma Res*. 2001;11:255-263.
48. Augsburger JJ, Gamel JW. Clinical prognostic factors in patients with posterior uveal malignant melanoma. *Cancer*. 1990;66:1596-1600.
49. Callender GR. Malignant melanotic tumors of the eye: a study of histologic types in 111 cases. *Trans Am Acad Ophthalmol Otolaryngol*. 1931;36:131-142.
50. McLean IW, Foster WD, Zimmerman LE, Gamel JW. Modifications of Callender's classification of uveal melanoma at the Armed Forces Institute of Pathology. *Am J Ophthalmol*. 1983;96:502-509.
51. Herwig MC, Grossniklaus HE. Pathology of Choroidal melanoma. In: Ryan SJ, Schachar AP, Wilkinson CP, Hinton DR, Sadda SR, Wiedemann P, eds. *Retina* (5th ed). China; Elsevier; 2013:2254-2266.
52. Coupland SE, Campbell I, Damato B. Routes of extraocular extension of uveal melanoma: risk factors and influence on survival probability. *Ophthalmology*. 2008;115:1778-1785.
53. Eskelin S, Pyrhönen S, Summanen P, Hahka-Kemppinen M, Kivelä T. Tumor doubling times in metastatic malignant melanoma of the uvea: tumor progression before and after treatment. *Ophthalmology*. 2000;107:1443-1449.
54. Dobner BC, Riechardt AI, Joussem AM, Englert S, Bechrakis NE. Expression of haematogenous and lymphogenous chemokine receptors and their ligands on uveal melanoma in association with liver metastasis. *Acta Ophthalmol*. 2012;90:638-644.
55. van den Bosch T, Koopmans AE, Vaarwater J, van den Berg M, de Klein A, Verdijk RM. Chemokine receptor CCR7 expression predicts poor outcome in uveal melanoma and relates to liver metastasis whereas expression of CXCR4 is not of clinical relevance. *Invest Ophthalmol Vis Sci*. 2013;54:7354-7361.
56. Diener-West M, Reynolds SM, Agugliaro DJ, Caldwell R, Cumming K, Earle JD, Hawkins BS, Hayman JA, Jaiyesimi I, Jampol LM, Kirkwood JM, Koh WJ, Robertson DM, Shaw JM, Straatsma BR, Thoma J; Collaborative Ocular Melanoma Study Group. Development of metastatic disease after enrollment in the COMS trials for treatment of choroidal melanoma: Collaborative Ocular Melanoma Study Group Report No. 26. *Arch Ophthalmol*. 2005;123:1639-1643.
57. Gragoudas ES, Egan KM, Seddon JM, Glynn RJ, Walsh SM, Finn SM, Munzenrider JE, Spar MD. Survival of patients with metastases from uveal melanoma. *Ophthalmology*. 1991;98:383-389.
58. Singh AD, Borden EC. Metastatic uveal melanoma. *Ophthalmol Clin North Am*. 2005;18:143-150.
59. Scholes AG, Damato BE, Nunn J, Hiscott P, Grierson I, Field JK. Monosomy 3 in uveal melanoma: correlation with clinical and histologic predictors of survival. *Invest Ophthalmol Vis Sci*. 2003;44:1008-1011.
60. Damato BE, Duke C, Coupland SE, Hiscott P, Smith PA, Campbell I, Douglas A, Howard P. Cytogenetics of uveal melanoma: a 7-year clinical experience. *Ophthalmology*. 2007;114:1925-1931.
61. Tschentscher F, Prescher G, Zeschnigk M, Horsthemke B, Lohmann DR. Identification of chromosomes 3, 6, and 8 aberrations in uveal melanoma by microsatellite analysis in comparison to comparative genomic hybridization. *Cancer Genet Cytogenet*. 2000;122:13-17.
62. Tschentscher F, Hüsing J, Hölter T, Kruse E, Dresen IG, Jöckel KH, Anastassiou G, Schilling H, Bornfeld N, Horsthemke B, Lohmann DR, Zeschnigk M. Tumor classification based on gene expression profiling shows that uveal melanomas with and without monosomy 3 represent two distinct entities. *Cancer Res*. 2003;63:2578-2784.
63. Onken MD, Worley LA, Ehlers JP, Harbour JW. Gene expression profiling in uveal melanoma reveals two molecular classes and predicts metastatic death. *Cancer Res*. 2004;64:7205-7209.
64. Prescher G, Bornfeld N, Becher R. Nonrandom chromosomal abnormalities in primary uveal melanoma. *J Natl Cancer Inst*. 1990;82:1765-1769.
65. Prescher G, Bornfeld N, Hirche H, Horsthemke B, Jöckel KH, Becher R. Prognostic implications of monosomy 3 in uveal melanoma. *Lancet*. 1996;347:1222-1225.
66. Horsman DE, Sroka H, Rootman J, White VA. Monosomy 3 and isochromosome 8q in a uveal melanoma. *Cancer Genet Cytogenet*. 1990;45:249-253.
67. Sisley K, Rennie IG, Cottam DW, Potter AM, Potter CW, Rees RC. Cytogenetic findings in six posterior uveal melanomas: involvement of chromosomes 3, 6, and 8. *Genes Chromosomes Cancer*. 1990;2:205-209.
68. Damato BE, Dopierala JA, Coupland SE. Genotypic profiling of 452 choroidal melanomas with multiplex ligation-dependent probe amplification. *Clin Cancer Res*. 2010;16:6083-6092.
69. Sisley K, Rennie IG, Parsons MA, Jacques R, Hammond DW, Bell SM, Potter AM, Rees RC. Abnormalities of chromosomes 3 and 8 in posterior uveal melanoma correlate with prognosis. *Genes Chromosomes Cancer*. 1997;19:22-28.
70. Kilic E, Naus NC, van Gils W, Klaver CC, van Til ME, Verbiest MM, Stijnen T, Mooy CM, Paridaens D, Beverloo HB, Luyten GP, de Klein A. Concurrent loss of chromosome arm 1p and chromosome 3 predicts a decreased disease-free survival in uveal melanoma patients. *Invest Ophthalmol Vis Sci*. 2005;46:2253-2257.
71. Damato BE, Dopierala J, Klaasen A, van Dijk M, Sibbring J, Coupland SE. Multiplex ligation-dependent probe amplification of uveal melanoma: correlation with metastatic death. *Invest Ophthalmol Vis Sci*. 2009;50:3048-3055.
72. White VA, Chambers JD, Courtright PD, Chang WY, Horsman DE. Correlation of cytogenetic abnormalities with the outcome of patients with uveal melanoma. *Cancer*. 1998;83:354-359.
73. van Beek JG, Koopmans AE, Vaarwater J, de Rooi JJ, Paridaens D, Naus NC, de Klein A, Verdijk RM, Kilic E. The prognostic value of extraocular extension in relation to monosomy 3 and gain of chromosome 8q in uveal melanoma. *Invest Ophthalmol Vis Sci*. 2014;55:1284-1291.
74. Harbour JW. The genetics of uveal melanoma: an emerging framework for targeted therapy. *Pigment Cell Melanoma Res*. 2012;25:171-181.
75. Onken MD, Worley LA, Tuscan MD, Harbour JW. An accurate, clinically feasible multi-gene expression assay for predicting metastasis in uveal melanoma. *J Mol Diagn*. 2010;12:461-468.
76. Trolet J, Hupé P, Huon I, Lebigot I, Decraene C, Delattre O, Sastre-Garau X, Saule S, Thiéry JP, Plancher C, Asselain B, Desjardins L, Mariani P, Piperno-Neumann S, Barillot E, Couturier J. Genomic profiling and identification of high-risk uveal melanoma by array CGH analysis of primary tumors and liver metastases. *Invest Ophthalmol Vis Sci*. 2009;50:2572-2580.
77. Maat W, Kilic E, Luyten GP, de Klein A, Jager MJ, Gruijs NA, Van der Velden PA. Pyrophosphorolysis detects B-RAF mutations in primary uveal melanoma. *Invest Ophthalmol Vis Sci*. 2008;49:23-27.
78. Zuidervaart W, van Nieuwpoort F, Stark M, Dijkman R, Packer L, Borgstein AM, Pavey S, van der Velden P, Out C, Jager MJ, Hayward NK, Gruijs NA. Activation of the MAPK pathway is a common event in uveal melanomas although it rarely occurs through mutation of BRAF or RAS. *Br J Cancer*. 2005;92:2032-2038.

79. Weber A, Hengge UR, Urbanik D, Markwart A, Mirmohammadsaegh A, Reichel MB, Wittkeind C, Wiedemann P, Tannapfel A. Absence of mutations of the BRAF gene and constitutive activation of extracellular-regulated kinase in malignant melanomas of the uvea. *Lab Invest.* 2003;83:1771-1776.
80. Daniels AB, Lee JE, MacConaill LE, Palescandolo E, Van Hummelen P, Adams SM, DeAngelis MM, Hahn WC, Gragoudas ES, Harbour JW, Garraway LA, Kim IK. High throughput mass spectrometry-based mutation profiling of primary uveal melanoma. *Invest Ophthalmol Vis Sci.* 2012;53:6991-6996.
81. Van Raamsdonk CD, Bezrookove V, Green G, Bauer J, Gaugler L, O'Brien JM, Simpson EM, Barsh GS, Bastian BC. Frequent somatic mutations of GNAQ in uveal melanoma and blue naevi. *Nature.* 2009;457:599-602.
82. Shoushtari AN, Carvajal RD. GNAQ and GNA11 mutations in uveal melanoma. *Melanoma Res.* 2014;24:525-534.
83. Onken MD, Worley LA, Long MD, Duan S, Council ML, Bowcock AM, Harbour JW. Oncogenic mutations in GNAQ occur early in uveal melanoma. *Invest Ophthalmol Vis Sci.* 2008;49:5230-5234.
84. Koopmans AE, Vaarwater J, Paridaens D, Naus NC, Kilic E, de Klein A; Rotterdam Ocular Melanoma Study group. Patient survival in uveal melanoma is not affected by oncogenic mutations in GNAQ and GNA11. *Br J Cancer.* 2013;109:493-496.
85. Ambrosini G, Musi E, Ho AL, de Stanchina E, Schwartz GK. Inhibition of mutant GNAQ signaling in uveal melanoma induces AMPK-dependent autophagic cell death. *Mol Cancer Ther.* 2013;12:768-776.
86. Murali R, Wiesner T, Scolyer RA. Tumours associated with BAP1 mutations. *Pathology.* 2013;45:116-126.
87. Jensen DE, Proctor M, Marquis ST, Gardner HP, Ha SI, Chodosh LA, Ishov AM, Tommerup N, Vissing H, Sekido Y, Minna J, Borodovsky A, Schultz DC, Wilkinson KD, Maul GG, Barlev N, Berger SL, Prendergast GC, Rauscher FJ 3rd. BAP1: a novel ubiquitin hydrolase which binds to the BRCA1 RING finger and enhances BRCA1-mediated cell growth suppression. *Oncogene.* 1998;16:1097-1112.
88. Harbour JW, Onken MD, Roberson ED, Duan S, Cao L, Worley LA, Council ML, Matattall KA, Helms C, Bowcock AM. Frequent mutation of BAP1 in metastasizing uveal melanomas. *Science.* 2010;330:1410-1413.
89. Matattall KA, Agapova OA, Onken MD, Worley LA, Bowcock AM, Harbour JW. BAP1 deficiency causes loss of melanocytic cell identity in uveal melanoma. *Cancer.* 2013;13:371.
90. Harbour JW, Roberson ED, Anbunathan H, Onken MD, Worley LA, Bowcock AM. Recurrent mutations at codon 625 of the splicing factor SF3B1 in uveal melanoma. *Nat Genet.* 2013;45:133-135.
91. Martin M, Maßhöfer L, Temming P, Rahmann S, Metz C, Bornfeld N, van de Nes J, Klein-Hitpass L, Hinnebusch AG, Horsthemke B, Lohmann DR, Zeschne M. Exome sequencing identifies recurrent somatic mutations in EIF1AX and SF3B1 in uveal melanoma with disomy 3. *Nat Genet.* 2013;45:933-936.
92. Damato BE. Treatment selection for uveal melanoma. *Dev Ophthalmol.* 2012;49:16-26.
93. No authors listed. Mortality in patients with small choroidal melanoma. COMS report no. 4. The Collaborative Ocular Melanoma Study Group. *ARC Ophthalmol.* 1997;115:886-893.
94. No authors listed. Factors predictive of growth and treatment of small choroidal melanoma: COMS Report No. 5. The Collaborative Ocular Melanoma Study Group. *Arch Ophthalmol.* 1997;115:1537-1544.
95. Shields JA, Glazer LC, Mieler WF, Shields CL, Gottlieb MS. Comparison of xenon arc and argon laser photocoagulation in the treatment of choroidal melanomas. *Am J Ophthalmol.* 1990;109:647-655.
96. Mashayekhi A, Shields CL, Rishi P, Atalay HT, Pellegrini M, McLaughlin JP, Patrick KA, Morton SJ, Remmer MH, Parendo A, Schlitt MA, Shields JA. Primary transpupillary thermotherapy for choroidal melanoma in 391 cases: importance of risk factors in tumor control. *Ophthalmology.* 2015;122:600-609.
97. Shields CL, Shields JA, Perez N, Singh AD, Cater J. Primary transpupillary thermotherapy for small choroidal melanoma in 256 consecutive cases: outcomes and limitations. *Ophthalmology.* 2002;109:225-234.
98. Shields CL, Shields JA, Cater J, Lois N, Edelstein C, Gündüz K, Mercado G. Transpupillary thermotherapy for choroidal melanoma: tumor control and visual results in 100 consecutive cases. *Ophthalmology.* 1998;105:581-590.
99. Turcotte S, Bergeron D, Rousseau AP, Mouriaux F. Primary transpupillary thermotherapy for choroidal indeterminate melanocytic lesions. *Can J Ophthalmol.* 2014;49:464-467.
100. Singh AD, Kivelä T, Seregard S, Robertson D, Bena JE. Primary transpupillary thermotherapy of "small" choroidal melanoma: is it safe? *Br J Ophthalmol.* 2008;92:727-728.
101. Houston SK, Boldt CH, Markoe AM, Murray TG. Brachytherapy for Choroidal Melanoma. In: Ryan SJ, Schachat AP, Wilkinson CP, Hinton DR, Sadda SR, Wiedemann P, eds. *Retina* (5th ed). China; Elsevier; 2013:2275-2289.
102. Verschuere KM, Creutzberg CL, Schalijs-Delfos NE, Ketelaars M, Klijnsen FL, Haeseker BI, Ligtenberg SM, Keunen JE, Marijnen CA. Long-term outcomes of eye-conserving treatment with Ruthenium(106) brachytherapy for choroidal melanoma. *Radiother Oncol.* 2010;95:332-338.
103. Diener-West M, Earle JD, Fine SL, Hawkins BS, Moy CS, Reynolds SM, Schachat AP, Straatsma BR; Collaborative Ocular Melanoma Study Group. The COMS randomized trial of iodine 125 brachytherapy for choroidal melanoma, III: initial mortality findings. COMS Report No. 18. *Arch Ophthalmol.* 2001;119:969-982.
104. Finger PT, Chin KJ, Duvall G; Palladium-103 for Choroidal Melanoma Study Group. Palladium-103 ophthalmic plaque radiation therapy for choroidal melanoma: 400 treated patients. *Ophthalmology.* 2009;116:790-796.
105. Papageorgiou KI, Cohen VM, Bunce C, Kinsella M, Hungerford JL. Predicting local control of choroidal melanomas following <sup>106</sup>Ru plaque brachytherapy. *Br J Ophthalmol.* 2011;95:166-170.
106. Bartlema YM, Oosterhuis JA, Journée-De Korver JG, Tjho-Heslinga RE, Keunen JE. Combined plaque radiotherapy and transpupillary thermotherapy in choroidal melanoma: 5 years' experience. *Br J Ophthalmol.* 2003;87:1370-1373.
107. Gragoudas SE, Lane AM, Kim IK. Charged-particle irradiation of Uveal Melanoma. In: Ryan SJ, Schachat AP, Wilkinson CP, Hinton DR, Sadda SR, Wiedemann P, eds. *Retina* (5th ed). China; Elsevier; 2013:2290-2295.
108. Gragoudas ES. The Bragg peak of proton beams for treatment of uveal melanoma. *Int Ophthalmol Clin.* 1980;20:123-133.
109. Nauraye C, Mazal A, Delacroix S, Bridier A, Chavaudra J, Rosenwald JC. An experimental approach to the design of a scattering system for a proton therapy beam line dedicated to ophthalmological applications. *Int J Radiat Oncol Biol Phys.* 1995;32:1177-1183.
110. Conway RM, Poothullil AM, Daftari IK, Weinberg V, Chung JE, O'Brien JM. Estimates of ocular and visual retention following treatment of extra-large uveal melanomas by proton beam radiotherapy. *Arch Ophthalmol.* 2006;124:838-843.
111. Desjardins L, Lumbroso-Le Rouic L, Levy-Gabriel C, Cassoux N, Dendale R, Mazal A, Delacroix S, Sastre X, Plancher C, Asselain B. Treatment of uveal melanoma by accelerated proton beam. *Dev Ophthalmol.* 2012;49:41-57.
112. Dunavoelgyi R, Dieckmann K, Gleiss A, Sacu S, Kircher K, Georgopoulos M, Georg D, Zehetmayer M, Poetter R. Local tumor control, visual acuity, and survival after hypofractionated stereotactic photon radiotherapy of choroidal melanoma in 212 patients treated between 1997 and 2007. *Int J Radiat Oncol Biol Phys.* 2011;81:199-205.
113. Zehetmayer M. Stereotactic photon beam irradiation of uveal melanoma. *Dev Ophthalmol.* 2012;49:58-65.
114. Höcht S, Stark R, Seiler F, Heufelder J, Bechrakis NE, Cordini D, Marnitz S, Kluge H, Foerster MH, Hinkelbein W. Proton or stereotactic photon irradiation for posterior uveal melanoma? A planning intercomparison. *Strahlenther Onkol.* 2005;181:783-788.
115. Zytovicz A, Daftari I, Phillips TL, Chuang CF, Verhey L, Petti PL. Peripheral dose in ocular treatments with CyberKnife and Gamma Knife radiosurgery compared to proton radiotherapy. *Phys Med Biol.* 2007;52:5957-5971.
116. Langmann G, Pendl G, Müllner K, Feichtinger KH, Papaefthymiou G. High-compared with low-dose radiosurgery for uveal melanomas. *J Neurosurg.* 2002;97:640-643.
117. Dunavoelgyi R, Zehetmayer M, Gleiss A, Geitzenauer W, Kircher K, Georg D, Schmidt-Erfurth U, Poetter R, Dieckmann K. Hypofractionated stereotactic photon radiotherapy of posteriorly located choroidal melanoma with five fractions at ten Gy-clinical results after six years of experience. *Radiother Oncol.* 2013;108:342-347.

118. Langmann G, Pendl G, Klaus-Müllner, Papaefthymiou G, Guss H. Gamma knife radiosurgery for uveal melanomas: an 8-year experience. *J Neurosurg.* 2000;93:184-188.
119. Fakiris AJ, Lo SS, Henderson MA, Witt TC, Worth RM, Danis RP, Des Rosiers PM, Timmerman RD. Gamma-knife-based stereotactic radiosurgery for uveal melanoma. *Stereotact Funct Neurosurg.* 2007;85:106-112.
120. Simonová G, Novotný J Jr, Liscák R, Pilbauer J. Leksell gamma knife treatment of uveal melanoma. *J Neurosurg.* 2002;97(Suppl 5):635-639.
121. Modorati G, Miserocchi E, Galli L, Picozzi P, Rama P. Gamma knife radiosurgery for uveal melanoma: 12 years of experience. *Br J Ophthalmol.* 2009;93:40-44.
122. Zehetmayer M, Kitz K, Menapace R, Ertl A, Heinzl H, Ruhswurm I, Georgopoulos M, Dieckmann K, Pötter R. Local tumor control and morbidity after one to three fractions of stereotactic external beam irradiation for uveal melanoma. *Radiother Oncol.* 2000;55:135-144.
123. Zorlu F, Seleik U, Kiratli H. Initial results of fractionated CyberKnife radiosurgery for uveal melanoma. *J Neurooncol.* 2009;94:111-117.
124. Seregard S, Pelayes DE, Singh AD. Radiation therapy: posterior segment complications. *Dev Ophthalmol.* 2013;52:114-123.
125. Horgan N, Shields CL, Mashayekhi A, Shields JA. Classification and treatment of radiation maculopathy. *Curr Opin Ophthalmol.* 2010;21:233-238.
126. Gündüz K, Shields CL, Shields JA, Cater J, Freire JE, Brady LW. Radiation retinopathy following plaque radiotherapy for posterior uveal melanoma. *Arch Ophthalmol.* 1999;117:609-614.
127. Horgan N, Shields CL, Mashayekhi A, Teixeira LF, Materin MA, Shields JA. Early macular morphological changes following plaque radiotherapy for uveal melanoma. *Retina.* 2008;28:263-273.
128. Mashayekhi A, Schönbach E, Shields CL, Shields JA. Early subclinical macular edema in eyes with uveal melanoma: association with future cystoid macular edema. *Ophthalmology.* 2015;122:1023-1029.
129. Emami B, Lyman J, Brown A, Coia L, Goitein M, Munzenrider JE, Shank B, Solin LJ, Wesson M. Tolerance of normal tissue to therapeutic irradiation. *Int J Radiat Oncol Biol Phys.* 1991;21:109-122.
130. Bianciotto C, Shields CL, Pirondini C, Mashayekhi A, Furuta M, Shields JA. Proliferative radiation retinopathy after plaque radiotherapy for uveal melanoma. *Ophthalmology.* 2010;117:1005-1012.
131. Bianciotto C, Shields CL, Pirondini C, Mashayekhi A, Furuta M, Shields JA. Vitreous hemorrhage after plaque radiotherapy for uveal melanoma. *Retina.* 2012;32:1156-1164.
132. Guyer DR, Mukai S, Egan KM, Seddon JM, Walsh SM, Gragoudas ES. Radiation maculopathy after proton beam irradiation for choroidal melanoma. *Ophthalmology.* 1992;99:1278-1285.
133. Giuliani GP, Sadaka A, Hinkle DM, Simpson ER. Current treatments for radiation retinopathy. *Acta Oncol.* 2011;50:6-13.
134. Singh AD, Pabon S, Aronow ME. Management of radiation maculopathy. *Ophthalmic Res.* 2012;48(Suppl 1):26-31.
135. Ahuja Y, Kapoor KG, Thomson RM, Furutani KM, Shultz RW, Stafford SL, Dev S, Abu-Yaghi NE, Reynolds D, Pulido JS. The effects of intraocular silicone oil placement prior to iodine 125 brachytherapy for uveal melanoma: a clinical case series. *Eye (Lond).* 2012;26:1487-1489.
136. Missotten GS, Notting IC, Schlingemann RO, Zijlmans HJ, Lau C, Eilers PH, Keunen JE, Jager MJ. Vascular endothelial growth factor in eyes with uveal melanoma. *Arch Ophthalmol.* 2006;124:1428-1434.
137. Shah SU, Shields CL, Bianciotto CG, Iturralde J, Al-Dahmash SA, Say EA, Badal J, Mashayekhi A, Shields JA. Intravitreal bevacizumab at 4-month intervals for prevention of macular edema after plaque radiotherapy of uveal melanoma. *Ophthalmology.* 2014;121:269-275.
138. Danesh-Meyer HV. Radiation-induced optic neuropathy. *J Clin Neurosci.* 2008;15:95-100.
139. Finger PT, Chin KJ. Antivascular endothelial growth factor bevacizumab for radiation optic neuropathy: secondary to plaque radiotherapy. *Int J Radiat Oncol Biol Phys.* 2012;82:789-798.
140. Levy RL, Miller NR. Hyperbaric oxygen therapy for radiation-induced optic neuropathy. *Ann Acad Med Singapore.* 2006;35:151-157.
141. Shields CL, Demirci H, Marr BP, Mashayekhi A, Dai VV, Materin MA, Shields JA. Intravitreal triamcinolone acetonide for acute radiation papillopathy. *Retina.* 2006;26:537-544.
142. Danesh-Meyer HV, Savino PJ, Sergott RC. Visual loss despite anticoagulation in radiation-induced optic neuropathy. *Clin Experiment Ophthalmol.* 2004;32:333-335.
143. Hawkins BS; Collaborative Ocular Melanoma Study Group. The Collaborative Ocular Melanoma Study (COMS) randomized trial of pre-enucleation radiation of large choroidal melanoma: IV. Ten-year mortality findings and prognostic factors. COMS report number 24. *Am J Ophthalmol.* 2004;138:936-951.
144. Shields CL, Naseripour M, Cater J, Shields JA, Demirci H, Youseff A, Freire J. Plaque radiotherapy for large posterior uveal melanomas (> or =8-mm thick) in 354 consecutive patients. *Ophthalmology.* 2002;109:1838-1849.
145. Puusaari I, Heikkonen J, Summanen P, Tarkkanen A, Kivelä T. Iodine brachytherapy as an alternative to enucleation for large uveal melanomas. *Ophthalmology.* 2003;110:2223-2234.
146. Diener-West M, Earle JD, Fine SL, Hawkins BS, Moy CS, Reynolds SM, Schachat AP, Straatsma BR; Collaborative Ocular Melanoma Study Group. The COMS randomized trial of iodine 125 brachytherapy for choroidal melanoma, III: initial mortality findings. COMS Report No. 18. *Arch Ophthalmol.* 2001;119:969-982.
147. Damato BE. Local resection of uveal melanoma. *Dev Ophthalmol.* 2012;49:66-80.
148. Damato BE, Kacperek A, Errington D, Heimann H. Proton beam radiotherapy of uveal melanoma. *Saudi J Ophthalmol.* 2013;27:151-157.
149. Bechrakis NE, Petousis V, Willerding G, Krause L, Wachtlin J, Stroux A, Foerster MH. Ten-year results of transscleral resection of large uveal melanomas: local tumour control and metastatic rate. *Br J Ophthalmol.* 2010;94:460-466.
150. Damato BE. Progress in the management of patients with uveal melanoma. The 2012 Ashton Lecture. *Eye (Lond).* 2012;26:1157-1172.
151. Damato BE, Paul J, Foulds WS. Predictive factors of visual outcome after local resection of choroidal melanoma. *Br J Ophthalmol.* 1993;77:616-623.
152. Diener-West M, Reynolds SM, Agugliaro DJ, Caldwell R, Cumming K, Earle JD, Green DL, Hawkins BS, Hayman J, Jaiyisimi I, Kirkwood JM, Koh WJ, Robertson DM, Shaw JM, Thoma J; Collaborative Ocular Melanoma Study Group Report 23. Screening for metastasis from choroidal melanoma: the Collaborative Ocular Melanoma Study Group Report 23. *J Clin Oncol.* 2004;22:2438-2444.
153. Eskelin S, Pyrhönen S, Summanen P, Prause JU, Kivelä T. Screening for metastatic malignant melanoma of the uvea revisited. *Cancer.* 1999;85:1151-1159.
154. Larsen LP. Role of contrast enhanced ultrasonography in the assessment of hepatic metastases: A review. *World J Hepatol.* 2010;2:8-15.
155. Servois V, Mariani P, Malhaire C, Petras S, Piperno-Neumann S, Plancher C, Levy-Gabriel C, Lumbroso-le Rouic L, Desjardins L, Salmon RJ. Preoperative staging of liver metastases from uveal melanoma by magnetic resonance imaging (MRI) and fluorodeoxyglucose-positron emission tomography (FDG-PET). *Eur J Surg Oncol.* 2010;36:189-194.
156. Feinstein EG, Marr BP, Winston CB, Abramson DH. Hepatic abnormalities identified on abdominal computed tomography at diagnosis of uveal melanoma. *Arch Ophthalmol.* 2010;128:319-323.
157. Onken MD, Worley LA, Char DH, Augsburger JJ, Correa ZM, Nudleman E, Aaberg TM Jr, Altaweel MM, Bardenstein DS, Finger PT, Gallie BL, Harocopos GJ, Hovland PG, McGowan HD, Milman T, Mruthyunjaya P, Simpson ER, Smith ME, Wilson DJ, Wirosko WJ, Harbour JW. Collaborative Ocular Oncology Group report number 1: prospective validation of a multi-gene prognostic assay in uveal melanoma. *Ophthalmology.* 2012;119:1596-1603.
158. Field MG, Harbour JW. Recent developments in prognostic and predictive testing in uveal melanoma. *Curr Opin Ophthalmol.* 2014;25:234-239.
159. Damato BE, Coupland SE. Translating uveal melanoma cytogenetics into clinical care. *Arch Ophthalmol.* 2009;127:423-429.
160. Torres V, Triozzi P, Eng C, Tubbs R, Schoenfeld L, Crabb JW, Sauntharajah Y, Singh AD. Circulating tumor cells in uveal melanoma. *Future Oncol.* 2011;7:101-109.

161. Schuster R, Bechrakis NE, Stroux A, Busse A, Schmittl A, Thiel E, Foerster MH, Keilholz U. Prognostic relevance of circulating tumor cells in metastatic uveal melanoma. *Oncology*. 2011;80:57-62.
162. Bidard FC, Madic J, Mariani P, Piperno-Neumann S, Rampanou A, Servois V, Cassoux N, Desjardins L, Milder M, Vaucher I, Pierga JY, Lebofsky R, Stern MH, Lantz O. Detection rate and prognostic value of circulating tumor cells and circulating tumor DNA in metastatic uveal melanoma. *Int J Cancer*. 2014;134:1207-1213.
163. Lane AM, Egan KM, Harmon D, Holbrook A, Munzenrider JE, Gragoudas ES. Adjuvant interferon therapy for patients with uveal melanoma at high risk of metastasis. *Ophthalmology*. 2009;116:2206-2212.
164. O'Neill PA, Butt M, Eswar CV, Gillis P, Marshall E. A prospective single arm phase II study of dacarbazine and treosulfan as first-line therapy in metastatic uveal melanoma. *Melanoma Res*. 2006;16:245-248.
165. McLean IW, Berd D, Mastrangelo MJ, Shields JA, Davidoff FH, Grever M, Makley TA, Gamel JW. A randomized study of methanol-extraction residue of bacille Calmette-Guerin as postsurgical adjuvant therapy of uveal melanoma. *Am J Ophthalmol*. 1990;110:522-526.
166. Triozzi PL, Singh AD. Adjuvant Therapy of Uveal Melanoma: Current Status. *Ocul Oncol Pathol*. 2015;1:54-62.
167. Leyvraz S, Piperno-Neumann S, Suci S, Baurain JE, Zdzienicki M, Testori A, Marshall E, Scheulen M, Jouary T, Negrier S, Vermorken JB, Kaempgen E, Durando X, Schadendorf D, Gurunath RK, Keilholz U. Hepatic intra-arterial versus intravenous fotemustine in patients with liver metastases from uveal melanoma (EORTC 18021): a multicentric randomized trial. *Ann Oncol*. 2014;25:742-746.
168. Carvajal RD, Sosman JA, Quevedo JF, Milhem MM, Joshua AM, Kudchadkar RR, Linette GP, Gajewski TF, Lutzky J, Lawson DH1, Lao CD, Flynn PJ, Albertini MR, Sato T, Lewis K, Doyle A, Ancell K, Panageas KS, Bluth M, Hedvat C, Erinjeri J, Ambrosini G, Marr B, Abramson DH, Dickson MA, Wolchok JD, Chapman PB, Schwartz GK. Effect of selumetinib vs chemotherapy on progression-free survival in uveal melanoma: a randomized clinical trial. *JAMA*. 2014;311:2397-2405.
169. Kim DW, Patel SP. Profile of selumetinib and its potential in the treatment of melanoma. *Onco Targets Ther*. 2014;7:1631-1639.
170. ClinicalTrials.gov Identifier: NCI-2012-00665, NCT01585194. <http://clinicaltrials.gov/show/NCI-2012-00665>.
171. ClinicalTrials.gov Identifier: NCT01100528. <http://clinicaltrials.gov/show/NCT01100528>.
172. ClinicalTrials.gov Identifier: NCT02223819. <http://clinicaltrials.gov/show/NCT02223819>.
173. ClinicalTrials.gov Identifier: NCT02068586. <http://clinicaltrials.gov/show/NCT02068586>.
174. Luke JJ, Triozzi PL, McKenna KC, Van Meir EG, Gershenwald JE, Bastian BC, Gutkind JS, Bowcock AM, Streicher HZ, Patel PM, Sato T, Sosman JA, Sznol M, Welch J, Thurin M, Selig S, Flaherty KT, Carvajal RD. Biology of advanced uveal melanoma and next steps for clinical therapeutics. *Pigment Cell Melanoma Res*. 2014;28:135-147.
175. Abildgaard SK, Vorum H. Proteomics of uveal melanoma: a minireview. *J Oncol*. 2013;2013:820953.



## Macular Burns from Nonmedical Lasers

Işıl Sayman Muslubaş, Mümin Hocaoğlu, Serra Arf, Hakan Özdemir, Murat Karaçorlu  
İstanbul Retina Institute, İstanbul, Turkey

### Summary

Laser devices are widely used for medical, military, industrial and entertainment purposes. This extensive and unregulated use of lasers can cause a variety of maculopathies that can result in permanent vision loss. Uncontrolled and inappropriate use of laser instruments should be prevented with strict rules. We strongly emphasize the importance of changing the general misperception that lasers are safe to use for entertainment purposes. In this study we aim to report the clinical features of three patients with a history of maculopathy caused by exposure to laser light in an entertainment venue.

**Keywords:** Nonmedical laser, macular burn, vitreoretinal surgery

### Introduction

The laser, whose name originated as an acronym for 'Light Amplification by Stimulated Emission of Radiation', was first developed in 1960.<sup>1</sup> Following animal studies, laser devices became widely used in a range of fields for medical, industrial, research and entertainment purposes. As the usage of lasers became more common, the incidence of laser-related injuries also increased.<sup>2</sup> Because visible and near-infrared light are focused and concentrated on the retina, this tissue is most susceptible to laser-related injury.<sup>3</sup> Reports of retinal laser injuries include subretinal hemorrhage, retinal edema, damage to the retinal pigment epithelium, vitreous or chorioretinal hemorrhage, perifoveal pigment changes or deposits, foveal ring-shaped hypopigmented lesions and rarely, choroidal neovascularization.<sup>4</sup> We aimed to present two cases of foveal subhyaloid hemorrhage and one case of subfoveal intraretinal hemorrhage associated with laser burns.

### Case Reports

#### Case 1

A 28-year-old male presented to our clinic complaining of loss of central vision in the right eye. He had attended a wedding three days earlier where his right eye was exposed to

laser light. On ophthalmologic examination, his best corrected visual acuity (BCVA) was 3/10 in the right eye and 10/10 in the left eye. Anterior segment examination was normal and intraocular pressure (IOP) was 15 mmHg in both eyes. On fundus examination, foveal hemorrhage was observed in the right eye, while the left eye was normal (Figure 1A). On optical coherence tomography (OCT) performed on the same day, the foveal cross-section of the right eye revealed a hyperreflective dome-shaped protrusion extending into the vitreous cavity due to hemorrhage under the internal limiting membrane (ILM). This protrusion caused optical shadowing of the underlying tissue layers (Figure 2A). The right eye appeared normal. On microperimetry-1 (MP1) analysis, fixation was predominantly eccentric and stable and retinal sensitivity in the central 20 degrees was measured as 16.7 decibels (dB) in the right eye. Absolute and relative scotoma was present centrally in the area of hemorrhage (Figure 3A). Fixation was central and stable in the left eye, and retinal sensitivity in the central 20 degree field was normal.

Surgery was planned for the right eye after informing the patient about his current condition, natural disease course, and the risks and success rates associated with the procedure. Two days later, 23-gauge (G) pars plana vitrectomy (PPV), posterior hyaloid dissection and ILM peeling were performed. The



patient developed no complications in the early postoperative period and was discharged with 0.1% dexamethasone eye drops 4 times a day for 1 month, 0.3% tobramycin drops 4 times a day for 1 month and ciprofloxacin 750 mg tablet twice a day for 1 week.

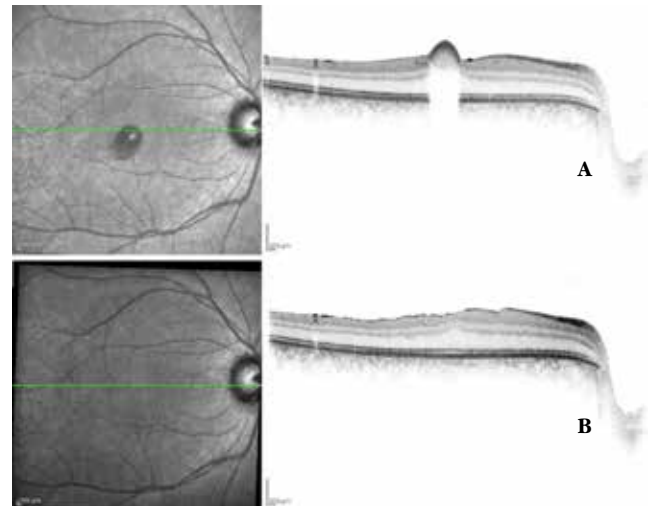
Postoperative follow-up examinations were done at 1 day, 1 week, 1 month, 6 months and 1 year after the procedure. At 1-year follow-up, BCVA was 10/10 in both eyes. Anterior segment examination was normal and IOP was 18 mmHg in both eyes. Retinal attachment was observed in the right eye on fundus examination. Hemorrhage or serous elevation were not detected (Figure 1B). The left eye appeared normal. On OCT performed on the same day, foveal sections from the right eye revealed that foveal cupping and the thickness was 339 microns. In the foveal region, the photoreceptor inner segment/outer segment (IS/OS) junction and external limiting membrane (ELM) were intact (Figure 2B). OCT findings in the left eye were normal. On MP1, fixation was central and stable and retinal sensitivity was measured as 17.0 dB (Figure 3B).

**Case 2**

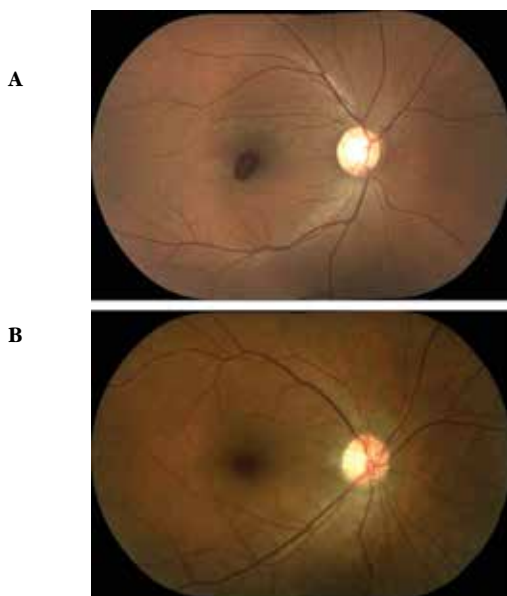
A 9-year-old girl was examined for complaints of blurred vision in her right eye for 15 days. According to her history, her vision problem began after looking into a laser at a hotel 15 days earlier. On ophthalmologic examination, her BCVA was counting fingers from 3 meters in the right eye and 10/10 in the left eye. Anterior segment examination was normal and IOP was 14 mmHg in both eyes. On fundus examination, foveal hemorrhage was observed in the right eye, while the left eye was normal (Figure 4A). On OCT performed on the same day, the foveal cross-section of the right eye revealed a hyperreflective dome-shaped protrusion extending into the

vitreal cavity due to hemorrhage under the ILM. The foveal pit was absent (Figure 5A). The left eye appeared normal. The MP test could not be performed due to patient noncompliance.

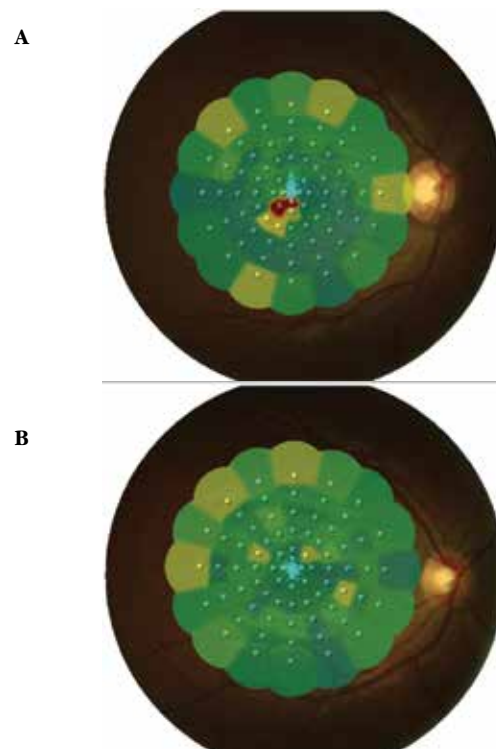
Surgery was planned for the right eye after informing the patient about her current condition, natural disease course, and the risks and success rates associated with the procedure. Two days later, 23-G PPV, posterior hyaloid dissection and ILM peeling were performed. The patient developed no complications in the early postoperative period and was



**Figure 2.** Case 1, preoperative (A) and postoperative (B) optical coherence tomography images



**Figure 1.** Case 1, preoperative (A) and postoperative (B) color fundus photographs



**Figure 3.** Case 1, preoperative (A) and postoperative (B) microperimetry-1 images

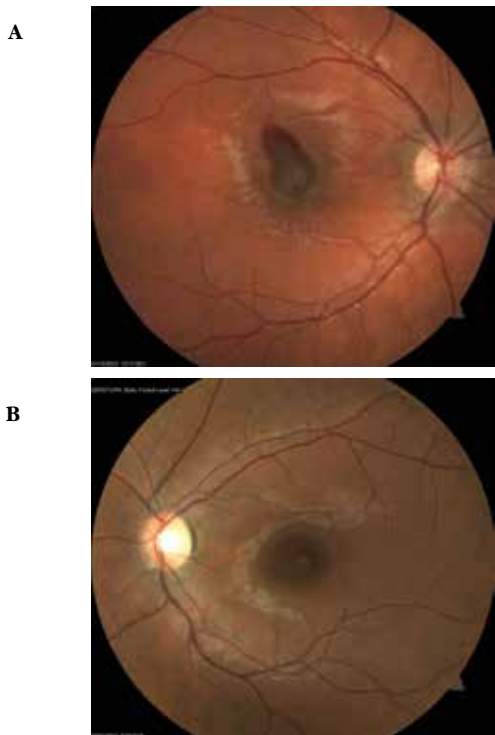
discharged with 0.1% dexamethasone eye drops 4 times a day for 1 month, 0.3% tobramycin drops 4 times a day for 1 month.

Postoperative follow-up examinations were done at 1 day, 1 week, 1 month and 6 months after the procedure. At 6 months her BCVA was 9/10 in the right eye and 10/10 in the left eye. Anterior segment examination was normal and IOP was 15 mmHg in both eyes. Retinal attachment was observed in the right eye on fundus examination. Hemorrhage or serous

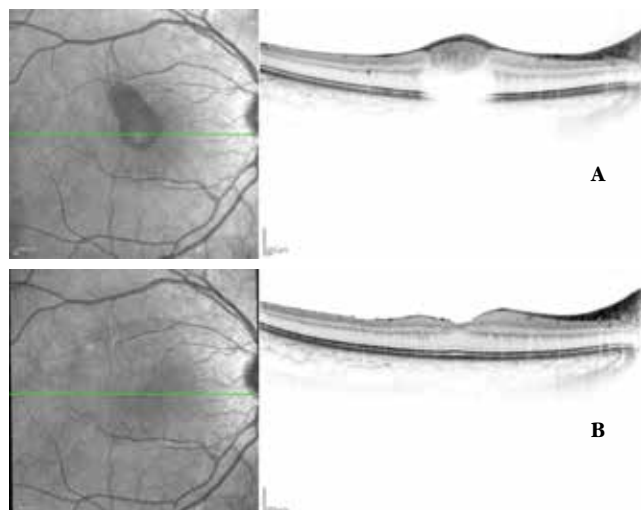
elevation were not detected (Figure 4B). The left eye appeared normal. On OCT performed on the same day, foveal thickness was 272 microns in the right eye. In the foveal region, the photoreceptor IS/OS junction and ELM were intact (Figure 5B). OCT findings in the left eye were normal.

**Case 3**

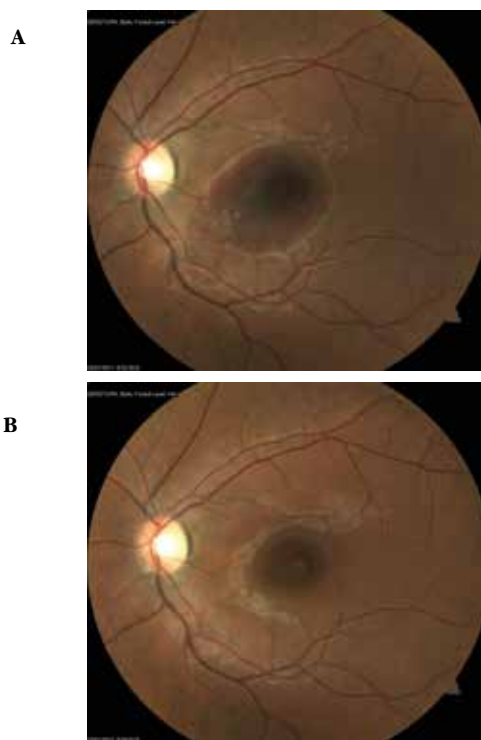A 24-year-old female patient presented to our clinic with complaints of vision loss in her left eye. She reported laser light shining into her left eye at an entertainment venue one week earlier, after which her vision problem started. On ophthalmologic examination, her BCVA was 10/10 in the right eye and 1/10 in the left eye. Anterior segment examination was normal and IOP was 11 mmHg in both eyes. Fundus examination of the right eye revealed subretinal hemorrhage in an area centered around the fovea covering approximately 3 disc diameters; fundus examination of the right eye was normal (Figure 6A). On OCT performed the same day, no pathologic findings were detected in the right eye, while intraretinal hemorrhage at the border of the outer plexiform layer and subretinal fluid were observed in the left eye. Increased reflectivity of the deeper retinal layers were noted (Figure 7A). Fluorescein angiography (FA) of the left eye revealed hypofluorescence due to blockage caused by hemorrhage, although the retinal vessels over the hemorrhage appeared healthy (Figure 8A). On MP1 analysis, fixation was central and stable and retinal sensitivity in the central 20 degrees was 17.0 dB in the right eye. In the left eye, fixation



**Figure 4.** Case 2, preoperative (A) and postoperative (B) color fundus photographs



**Figure 5.** Case 2, preoperative (A) and postoperative (B) optical coherence tomography images



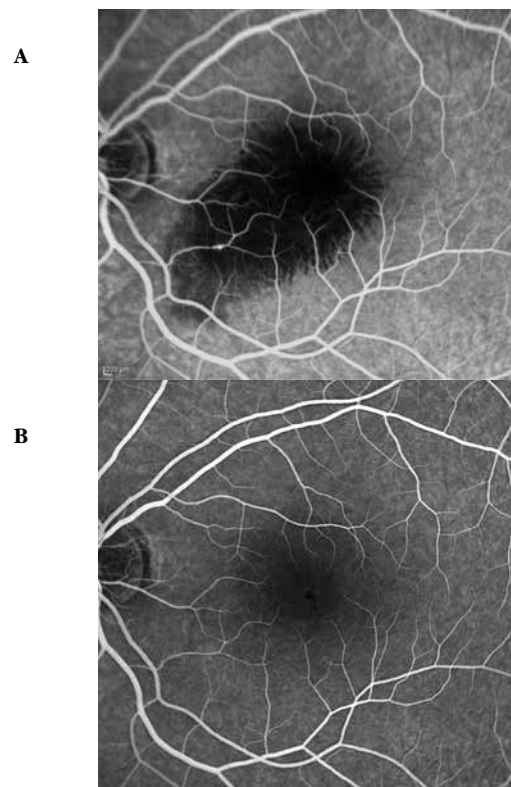
**Figure 6.** Case 3, color fundus photographs before (A) and after (B) intravitreal injection

was extrafoveal and unstable, and retinal sensitivity was 7.8 dB (Figure 9A).

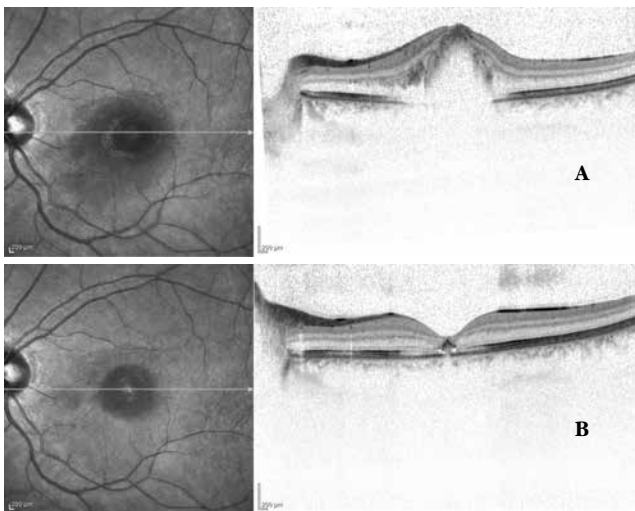
After informing the patient about her current condition, natural disease course, and the risks and success rates associated with the treatment, a total of 3 intravitreal anti-vascular endothelial growth factor (VEGF) injections were applied at 1-month intervals. Follow-up examinations were done at 1 day, 1 week, 3 months and 6 months after the injections. At 6 months her BCVA was 10/10 in the right eye and 3/10 in the left eye. Anterior segment examination was normal and IOP was 14 mmHg in both eyes. On fundus examination, we observed a reduction in the size of the foveal lesion (Figure 6B). The fovea appeared atrophic on OCT. The ELM was intact. A hyperreflective area was observed on the ELM at the foveal pit. IS/OS junction defect was noted (Figure 7B). FA was normal (Figure 8B). MP1 revealed the scotoma had regressed, while fixation was nearer to central and was relatively unstable. Retinal sensitivity was measured as 16.8 dB (Figure 9B).

### Discussion

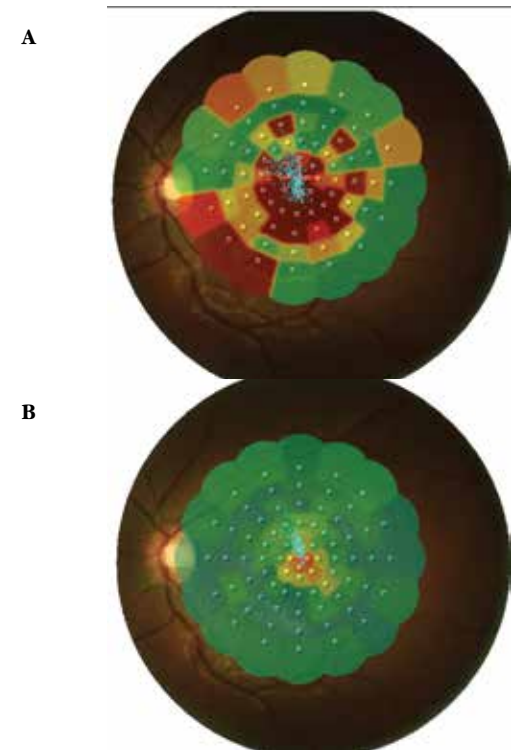
With the widespread use of lasers in various fields and the retina's sensitivity to laser light, laser-induced ocular injuries are commonly encountered in ophthalmology practice. The American National Standards Institute defined four classes of laser device based on their potential risk.<sup>5</sup> In this classification system, red-orange lasers with up to 1 mW of output power and longer wavelengths are in class II; green-blue lasers with up to 5 mW output power and shorter wavelengths are Class III. Exposure to class III and IV lasers can result in injury to the eyes and skin.<sup>2,4,5</sup> Laser-induced ocular injuries may result from ablative, thermal or photochemical mechanisms depending on factors related to both the laser and the eye, including laser power, wavelength, spot size, exposure time, pupil diameter, proximity to the fovea, and amount of



**Figure 8.** Case 3, fluorescein angiography images before (A) and after (B) intravitreal injection



**Figure 7.** Case 3, optical coherence tomography images before (A) and after (B) intravitreal injection



**Figure 9.** Case 3, microperimetry-1 images before (A) and after (B) intravitreal injection

retinal and choroidal pigmentation.<sup>2,4</sup> The main laser-related determining factor in retinal damage is the wavelength of the incident light.<sup>2</sup> Visible and near-infrared incident light with wavelength between 380 and 1400 nm damages the retina. The damage increases in severity with longer exposure times. The blinking reflex and flinching in response to laser light limits laser exposure to between 0.15 and 0.25 seconds; these mechanisms serve as natural protection against laser-induced damage. Other important laser-related factors determining damage severity are pulse duration and energy level. High-energy and short pulses cause more damage to the retina.<sup>2</sup> In our cases, we could not learn specific details regarding the wavelength, power and duration of the lasers our patients were exposed to; therefore, we do not know the laser class and duration of exposure that caused their retinal injuries. However, there are many reports in the literature of macular damage caused by class IIIA and higher lasers.<sup>6,7,8,9,10</sup> The main retinal injuries reported related to class IIIA lasers are retinal pigment epithelium alterations; subretinal, intraretinal, subhyaloid and vitreous hemorrhages; epiretinal membrane; and full-thickness macular holes. The prefoveal hemorrhage observed in two of our cases and subfoveal hemorrhage in the other suggest that the lasers were Class IIIA.

The most important eye-related determining factor in laser-induced ocular damage is its localization on the retina. The resulting functional loss increases proportionately to the proximity of the damage to the fovea. With increasing distance from the fovea, the resulting scotomas are usually asymptomatic. Another factor related to the eye is pupil size. Because pupil dilation in dark environments allows more light to reach the retina, the resulting damage is more severe than that incurred in light environments. Furthermore, in individuals with more retinal and choroidal pigmentation, melanin absorbs more laser light, which leads to more severe injuries.<sup>2,4</sup>

Laser-induced hemorrhage may occur in different layers of the retina, and treatment options vary based on which layer is involved. In a report by Alsulaiman et al.<sup>9</sup> of seven cases of intraocular hemorrhage associated with high-power lasers, five patients developed subhyaloid hemorrhage and two patients sub-ILM hemorrhage. Neodymium: yttrium-aluminum-garnet (Nd:YAG) hyaloidotomy was performed in all patients with subhyaloid hemorrhage; the procedure resulted in a rapid improvement in vision in three patients, but was unsuccessful in the other two. The two patients with sub-ILM hemorrhage were followed; during follow-up their hemorrhages spontaneously regressed and visual acuity improved. Similarly, two of our cases developed subhyaloid foveal hemorrhage, but unlike the other reports we achieved anatomic and functional success in these cases with surgery including 23-G PPV, posterior hyaloid dissection and ILM peeling.

The humanized monoclonal antibody bevacizumab (Avastin; Genentech /Roche, San Francisco, CA, USA) is used in the treatment of many retinal diseases, primarily choroidal neovascularization and age-related macular degeneration. Bevacizumab selectively inhibits VEGF, prevents abnormal vasculature formation and limits vascular permeability.<sup>11,12</sup> Considering these effects of anti-VEGF therapy, we applied a total of three intravitreal anti-VEGF injections at one-month intervals in our patient with subretinal hemorrhage, despite the lack of clear guidance on this topic. An increase in visual acuity was achieved, atrophy at the fovea and damage at the IS/OS border resulted in permanent functional loss.

Another type of laser-related retinal injury is full-thickness macular holes. In a study by Alsulaiman et al.,<sup>9</sup> laser-induced full-thickness macular hole was observed in four cases; anatomic and functional success was achieved in these patients with PPV, ILM peeling and silicone or gas tamponade injection.

## Conclusion

Outside the medical and military fields, the use of lasers ranging from 5 to 1200 mW has become very common in entertainment centers, presentations and meetings or as toys. Our natural protective mechanisms are insufficient for lasers of this power, and extremely severe, permanent functional losses may result. Restraining the uninformed use of high-power lasers by the general public through legislation and educating the public about the harmful effects of laser light are crucial to prevent laser-related permanent retinal injuries.

## Ethics

Informed Consent: In accordance with the principles of the Declaration of Helsinki, patients were informed about their current status and natural course, consent was obtained.

Peer-review: Externally peer-reviewed.

## Authorship Contributions

Surgical and Medical Practices: Işıl Sayman Muslubuş, Mümin Hocoğlu, Serra Arf, Hakan Özdemir, Murat Karaçorlu, Concept: Işıl Sayman Muslubuş, Mümin Hocoğlu, Serra Arf, Hakan Özdemir, Murat Karaçorlu, Design: Işıl Sayman Muslubuş, Mümin Hocoğlu, Serra Arf, Hakan Özdemir, Murat Karaçorlu, Data Collection or Processing: Işıl Sayman Muslubuş, Mümin Hocoğlu, Serra Arf, Hakan Özdemir, Murat Karaçorlu, Analysis or Interpretation: Işıl Sayman Muslubuş, Mümin Hocoğlu, Serra Arf, Hakan Özdemir, Murat Karaçorlu, Literature Search: Işıl Sayman Muslubuş, Mümin Hocoğlu, Serra Arf, Hakan Özdemir, Murat Karaçorlu, Writing: Işıl Sayman Muslubuş, Mümin Hocoğlu, Serra Arf, Hakan Özdemir, Murat Karaçorlu.

Conflict of Interest: No conflict of interest was declared by the authors.

Financial Disclosure: The authors declared that this study received no financial support.

## References

1. Maiman TH. Stimulated optical radiation in ruby. *Nature*. 1960;187:493.
2. Barkan Y, Belkin M. Laser eye injuries. *Surv Ophthalmol*. 2000;44:459-478.
3. Belkin M. Ophthalmic manifestations of laser-induced eye injuries, in Stuck BE, Belkin M, eds. *Laser-inflicted eye injuries: epidemiology, prevention, and treatment*. Bellingham SPIE; 1996;2674:2-6.
4. Turaka K, Bryan JS, Gordon AJ, Reddy R, Kwong HM Jr, Sell CH. Laser pointer induced macular damage: case report and mini review. *Int Ophthalmol*. 2012; 32:293-297.
5. American National Standards Institute (2007) American national standard for safe use of lasers. Orlando: ANSI Z136.1-2007, Revision of ANSI Z136.1-2000.
6. Ueda T, Kurihara I, Koide R. A case of retinal light damage by green laser pointer (Class 3b). *Jpn J Ophthalmol*. 2011;55:428-430.
7. Sell CH, Bryan JS. Maculopathy from handheld diode laser pointer. *Arch Ophthalmol*. 1999;117:1557-1558.
8. Luttrull JK, Hallisey J. Laser pointer-induced macular injury. *Am J Ophthalmol*. 1999;127:95-96.
9. Alsulaiman SM, Alrushood AA, Almasaud J, Alzaaidi S, Alzahrani Y, Arevalo JE, Ghazi NG, Abboud EB, Nowilaty SR, Al-Amry M, Al-Rashaed S; King Khaled Eye Specialist Hospital Collaborative Retina Study Group. High power handheld blue laser-induced maculopathy. *Ophthalmology*. 2014;121:566-572.
10. Kara N, Yazıcı AT, Bozkurt E, Çakır M, Demirok A, Yılmaz ÖF. Lazer aydınlatma ışığına maruz kalan bir olguda retina değişiklikleri. *Ret-Vit*. 2011;19:60-63.
11. Rogers C, Damato B, Kumar I, Heimann H. Intravitreal bevacizumab in the treatment of vasoproliferative retinal tumours. *Eye*. 2014;28:968-973.
12. Finger PT, Chin K. Anti-vascular endothelial growth factor bevacizumab (avastin) for radiation retinopathy. *Arch Ophthalmol*. 2007;125:751-756.





# Objective Determination of Retinal Function in Bietti Crystalline Retinopathy

Dorukcan Akıncıoğlu\*, Ümit Yolcu\*\*, Abdullah İlhan\*\*\*, Fatih Çakır Gündoğan\*

\*Gülhane Military Medical Academy, Department of Ophthalmology, Ankara, Turkey

\*\*Siirt Military Hospital, Ophthalmology Clinic, Siirt, Turkey

\*\*\*Erzurum Military Hospital, Ophthalmology Clinic, Erzurum, Turkey

## Summary

A 44-year-old female patient without any known systemic or ocular disease presented with progressive visual loss and night vision disturbance. Visual acuity was 0.6 in the right eye and 0.2 in the left eye. Tiny, yellow crystalline deposits were seen on fundus examination. In addition, areas of retinal pigment epithelium and choriocapillaris atrophy were detected. Rod and cone responses were depressed in full-field flash electroretinogram. Multifocal electroretinogram testing showed severe foveal function disturbance with less severe but still depressed responses toward the periphery. Multiple hyperreflective lesions were detected in the retina in optical coherence tomography. We aimed to present the role of ocular electrophysiology by comparing the patient's signs and symptoms with her ocular electrophysiological test results.

**Keywords:** Bietti crystalline dystrophy, electroretinography, multifocal electroretinography

## Introduction

Bietti crystalline corneoretinal dystrophy (BCD) is a rare disorder characterized by yellow deposits in the retina and progressive atrophy of the retinal pigment epithelium (RPE) and the choriocapillaris. Bietti first described corneal crystals in 1937 in a report of three cases exhibiting shiny yellow retinal deposits and RPE atrophy. Lipid aggregates resulting from abnormal lipid metabolism form these crystal deposits, which may also be seen in the conjunctiva, fibroblasts and lymphocytes.<sup>1,2</sup> Although some cases have crystals in the paralimbal superficial corneal stroma, corneal depositions are not typical and corneal involvement is not one of the diagnostic criteria.<sup>3</sup> In BCD, symptoms including declining visual acuity and disruptions in night and peripheral vision emerge in the third and fourth decades.<sup>1</sup> Recent studies have demonstrated that the condition is associated with mutations in the *CYP4V2* gene on chromosome 4q35.<sup>4,5,6</sup> *CYP4V2* encodes the cytochrome P450 enzyme group; mutations in this gene result in lipid metabolism dysfunction at the cellular level.<sup>7</sup> Histopathologic studies have revealed complex lipid inclusions and crystals in the choroidal fibroblasts as well as generalized choroidal atrophy.<sup>2</sup>

With this case report, we aimed to discuss multifocal electroretinogram (mfERG) and electroretinogram (ERG) findings in BCD.

## Case Report

A 44-year-old female patient presented complaining of progressive decline in visual acuity over the previous 6 years. Her history indicated no chronic conditions or medication use. Her best corrected visual acuity was 0.6 OD and 0.2 OS; intraocular pressure was 13/11 mmHg OD/OS. Slit-lamp biomicroscopic examination was within normal limits. Small, yellow, shiny punctate intraretinal deposits were observed in the posterior pole and midperipheral retina of both eyes on fundus examination. Bilateral local RPE and choriocapillaris atrophy and pigment clusters were also observed on fundus examination (Figure 1).

Optic coherence tomography (OCT) revealed multiple hyperreflective punctate lesions in the inner and outer retinal layers with multiple cystic alterations in the outer retinal layers (Figure 2). These alterations did not correspond directly to the areas of crystalline deposits, and there were sporadic cystic alterations in the choroidal layer which did not correspond to the

**Address for Correspondence:** Dorukcan Akıncıoğlu MD, Gülhane Military Medical Academy, Department of Ophthalmology, Ankara, Turkey

Phone: +90 533 458 94 55 E-mail: dr.dorukcan@yahoo.com **Received:** 25.01.2014 **Accepted:** 26.09.2014

This article is also published in Turkish under doi:10.4274/tjo.02693 pages 2016;46:144-147.



cystic lesions in the retina. The lesions were not present in areas of fibrosis. In OCT cross-sections the hyperreflective retinal deposits are usually found at the RPE/choriocapillaris junction and in the choroid, and sometimes in the inner retinal layers.<sup>8,9</sup>

According to the normal full-field electroretinography values in our clinic,<sup>10</sup> the patient's b-wave amplitude on dark-adapted 0.01 ERG (rod response) was below the normal limit in the right eye (33.4  $\mu$ V) but was within normal range in the left eye (100  $\mu$ V) (normal range: 47-124  $\mu$ V). On dark-adapted 3.0 ERG, both a- and b-wave implicit times were prolonged in both eyes, a-wave amplitudes were reduced in both eyes but the reduction was more pronounced in the right eye, and b-wave amplitude was reduced in the right eye. Light-adapted 3.0 ERG (cone response) revealed normal a- and b-wave implicit times, but both a- and b-wave amplitudes were below the normal limit. On light-adapted 30 Hz flicker ERG, P1 peak time was prolonged and the 30 Hz amplitudes were attenuated (Figure 3).

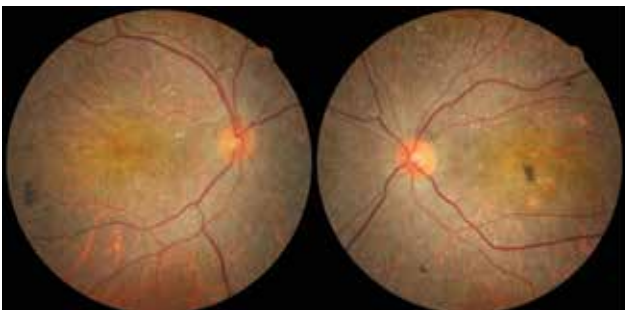

Figure 1. Fundus images from the patient

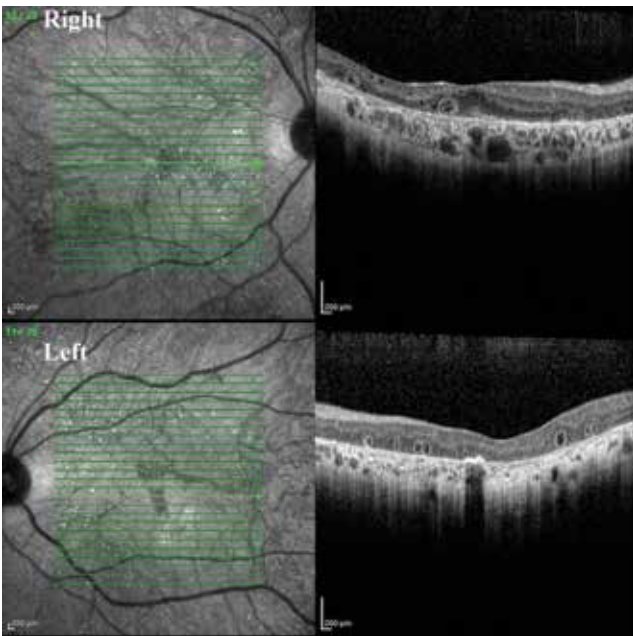


figure 2. Optical coherence tomography images from each eye

Multifocal ERG revealed depressed foveal responses in both eyes; retinal function improved moving from the center toward the periphery, but the amplitudes were still markedly attenuated compared to values from normal individuals (Figure 4).<sup>11</sup>

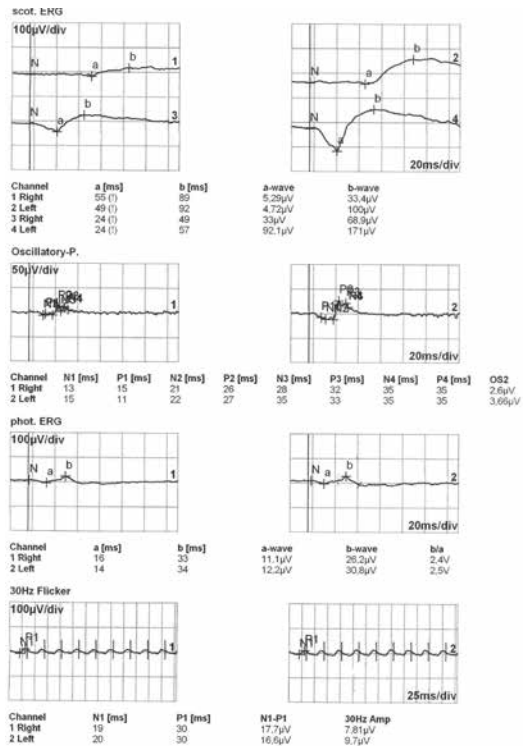


Figure 3. The patient's full-field electroretinogram

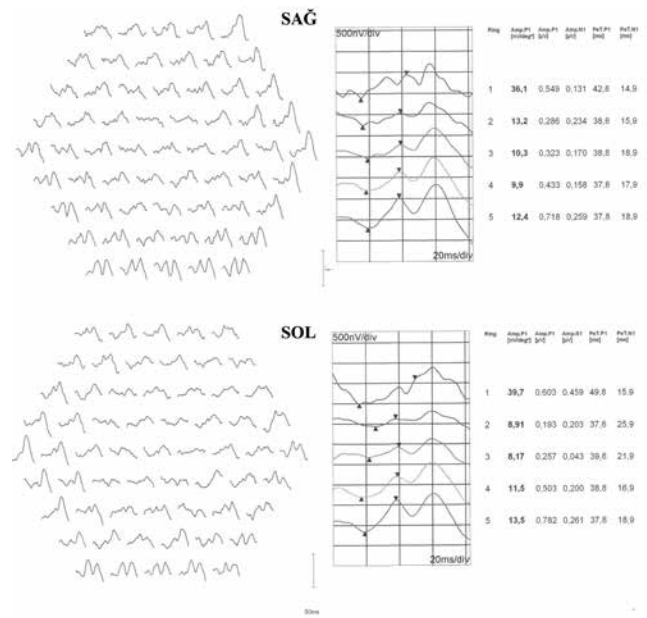


Figure 4. The patient's multifocal electroretinogram in right (top) and left (bottom) eyes

## Discussion

Our patient's symptoms included bilateral progressive vision loss and more recently, difficulty distinguishing figures in the dark. Studies in the literature concerning BCD have reported pathologic ERG responses at non-detectable levels,<sup>1,12,13</sup> a- and b-wave amplitude attenuation on scotopic strong flash ERG,<sup>14</sup> reduced rod b-wave amplitude,<sup>1,15</sup> attenuated a- and b-wave amplitudes on photopic ERG,<sup>15,16</sup> decreased 30-Hz flicker amplitude,<sup>1,16</sup> and abnormal S-cone ERG findings.<sup>15</sup> There are also studies demonstrating retinal dysfunction using focal and mfERG, despite normal ERG findings.<sup>16,17</sup>

Our patient's rod b-wave amplitudes were lower than normal in the right eye and within normal range in the left eye. Attenuated amplitude and prolonged latencies were detected in both a- and b-wave combined rod-cone responses. Photopic response showed reduced amplitudes and extended peak times in both cone and 30 Hz flicker responses in both eyes. These electrophysiological findings indicate widespread outer retinal dysfunction.

MfERG represents the electrical response to cone stimulation, usually from the central 30-40 degree field of the retina, and originating mostly from bipolar cell activity. MfERG provides local retinal function data from 61, 103 or 241 retinal sectors. Our patient showed pathologic cone responses on ERG in both eyes, and mfERG revealed markedly attenuated amplitudes in both eyes, particularly in central sectors. Because BCD is a progressive condition, observing different electrophysiological responses in the the different stages of the disease is understandable. However, in patients showing normal ERG results in the early stages of the disease, retinal function can be assessed using mfERG. We believe the utilization of mfERG is especially advisable in monitoring progression in cases with central involvement as mfERG shows the function of cone cells, which are more concentrated in the central retina. Therefore, a BCD diagnosis should not immediately be ruled out in cases exhibiting normal photopic and scotopic responses on ERG. It must be kept in mind that ERG results may be within normal limits in early BCD and that local retinal dysfunction may be detected with mfERG.

In our patient, the hyperreflective areas detected on OCT did not correspond directly to the retinal crystalline deposits, whereas Ayata et al.<sup>9</sup> showed these hyperreflective areas to be consistent with the crystalline deposits. Although a clear relationship between retinal crystalline deposits and visual prognosis could not be determined, patients with widespread crystalline deposits in the sensorial retina have lower visual acuity.<sup>18</sup> We believe that the cystic alterations, which are more common in the outer layers, are instances of outer retinal tubulation. Zweifel et al.<sup>19</sup> first described this OCT finding as the result of morphological changes occurring after damage to cells in the photoreceptor layer in retinal degenerative

diseases, and determined that this finding can be seen in BCD. Pennesi et al.<sup>20</sup> hypothesized that these lesions are crystalline deposits that have been encapsulated by the retinal pigment epithelium. In terms of the clinical significance of these lesions, on B-scan OCT they can be mistaken for cystic macular edema, and their tubular structure can be more clearly visualized in C-scan sections on en face OCT. We believe the alterations observed in the choroid are an optical illusion created by these tubular alterations in the outer retinal layer.

## Conclusion

Evaluated together with other cases presented in the literature, our mfERG and ERG findings indicate widespread dysfunction of the outer retinal layers in BCD. As mfERG demonstrates central retinal function, this technique can be utilized as an objective assessment method when following macular function in BCD.

## Ethics

Peer-review: Externally peer-reviewed.

## Authorship Contributions

Surgical and Medical Practices: Dorukcan Akıncioğlu, Fatih Çakır Gündoğan, Concept: Dorukcan Akıncioğlu, Fatih Çakır Gündoğan, Ümit Yolcu, Design: Abdullah İlhan, Fatih Çakır Gündoğan, Data Collection or Processing: Dorukcan Akıncioğlu, Fatih Çakır Gündoğan, Analysis or Interpretation: Ümit Yolcu, Abdullah İlhan, Literature Search: Dorukcan Akıncioğlu, Fatih Çakır Gündoğan, Writing: Dorukcan Akıncioğlu, Fatih Çakır Gündoğan, Abdullah İlhan.

Conflict of Interest: No conflict of interest was declared by the authors.

Financial Disclosure: The authors declared that this study received no financial support.

## References

1. Wilson DJ, Weleber RG, Klein ML, Welch RB, Green WR. Bietti's crystalline dystrophy. A clinicopathologic correlative study. *Arch Ophthalmol.* 1989;107: 213-221.
2. Kaiser-Kupfer MI, Chan CC, Markello TC, Crawford MA, Caruso RC, Csaky KG, Guo J, Gahl WA. Clinical biochemical and pathologic correlations in Bietti's crystalline dystrophy. *Am J Ophthalmol.* 1994;118:569-582.
3. Grizzard WS, Deutman AF, Nijhuis F, de Kerk AA. Crystalline retinopathy. *Am J Ophthalmol.* 1978;86:81-88.
4. Wada Y, Itabashi T, Sato H, Kawamura M, Tada A, Tamai M. Screening for mutations in CYP4V2 gene in Japanese patients with Bietti's crystalline corneoretinal dystrophy. *Am J Ophthalmol.* 2005;139:894-899.
5. Lin J, Nishiguchi KM, Nakamura M, Dryja TP, Berson EL, Miyake Y. Recessive mutations in the CYP4V2 gene in East Asian and Middle Eastern patients with Bietti crystalline corneoretinal dystrophy. *J Med Genet.* 2005;42:38.
6. Xiao X, Mai G, Li S, Guo X, Zhang Q. Identification of CYP4V2 mutation in 21 families and overview of mutation spectrum in Bietti crystalline corneoretinal dystrophy. *Biochem Biophys Res Commun.* 2011;409:181-186.

7. Li A, Jiao X, Munier FL, Schorderet DF, Yao W, Iwata F, Hayakawa M, Kanai A, Shy Chen M, Alan Lewis R, Heckenlively J, Weleber RG, Traboulsi EI, Zhang Q, Xiao X, Kaiser-Kupfer M, Sergeev YV, Hejtmancik JF. Bietti crystalline corneoretinal dystrophy is caused by mutations in the novel gene CYP4V2. *Am J Hum Genet.* 2004;74:817-826.
8. Toto L, Carpineto P, Parodi MB, Di Antonio L, Mastropasqua A, Mastropasqua L. Spectral domain optical coherence tomography and in vivo confocal microscopy imaging of a case of Bietti's crystalline dystrophy. *Clin Exp Optom.* 2013;96:39-45.
9. Ayata A, Tatlipinar S, Unal M, Ersanli D, Bilge AH. Autofluorescence and OCT features of Bietti's crystalline dystrophy. *Br J Ophthalmol.* 2008;92:718-720.
10. Gundogan FC, Erdem U, Hamurcu MS, Bayraktar MZ. Our normal values of flash electroretinogram. *Gülhane Medical Journal.* 2006;48:14-18.
11. Gundogan FC, Isilak Z, Erdurman C, Mumcuoglu T, Durukan AH, Bayraktar MZ. Multifocal electroretinogram in mild to moderate essential hypertension. *Clin Exp Hypertens.* 2008;30:375-384.
12. Usui T, Tanimoto N, Takagi M, Hasegawa S, Abe H. Rod and cone a-waves in three cases of Bietti crystalline chorioretinal dystrophy. *Am J Ophthalmol.* 2001;132:395-402.
13. Bernauer W, Daicker B. Bietti's corneal-retinal dystrophy. A 16-year progression. *Retina.* 1992;12:18-20.
14. Weber U, Adler K, Hennekes R. Crystalline chorioretinopathy with marginal corneal involvement. *Klin Monbl Augenheilkd.* 1984;185:268-271.
15. Yamamoto S, Kataoka Y, Kamiyama M, Hayasaka S. Nondetectable S-cone electroretinogram in a patient with crystalline retinopathy. *Doc Ophthalmol.* 1995;90:221-227.
16. Yagasaki K, Miyake Y. Crystalline retinopathy. *Nihon Ganka Gakkai Zasshi.* 1986;90:711-719.
17. Kretschmann U, Usui T, Ruether K, Zrenner E. Electroretinographic campimetry in a patient with crystalline retinopathy. *Ger J Ophthalmol.* 1996;5:399-403.
18. Öztürk B, Bozkurt B, Kaniş Ü, Okka M. Bietti kristalin retinopatisinde optik koherens tomografi bulguları. *Ret-Vit.* 2011;19:198-200.
19. Zweifel SA, Engelbert M, Laud K, Margolis R, Spaide RF, Freund KB. Outer retinal tubulation: a novel optical coherence tomography finding. *Arch Ophthalmol.* 2009;127:1596-1602.
20. Pennesi ME, Weleber RG. High-resolution optical coherence tomography shows new aspects of Bietti crystalline retinopathy. *Retina.* 2010;30:531-532.



## Orbital Metastasis of Multiple Myeloma: Case Report

Mustafa Vatansever\*, Fatma Merve Bozkurt\*, Erdem Dinç\*, Eda Bengi Yılmaz\*\*, Erdinç Nayir\*\*\*, Ayşe Ayça Sarı\*, Özlem Yıldırım\*, Tuba Kara\*\*\*\*

\*Mersin University Faculty of Medicine, Department of Ophthalmology, Mersin, Turkey

\*\*Mersin University Faculty of Medicine, Department of Radiation Oncology, Mersin, Turkey

\*\*\*Mersin University Faculty of Medicine, Department of Oncology, Mersin, Turkey

\*\*\*\*Mersin University Faculty of Medicine, Department of Pathology, Mersin, Turkey

### Summary

A 68-year-old woman with a history of multiple myeloma presented to the clinic with pain and vision loss in her right eye. Proptosis was observed in her right eye and eye movements were restricted in all directions. Best corrected visual acuity was 3/10 in her right eye. On biomicroscopic examination, hyperemia and subconjunctival hemorrhage were present. Fundus examination of the right eye revealed optic disc edema and choroidal folds. In magnetic resonance imaging two orbital masses were detected. Based on the patient's history and ocular examination, we evaluated the masses as orbital metastasis of multiple myeloma. Palliative radiotherapy was recommended.

**Keywords:** Multiple myeloma, orbita, metastasis, plasmacytoma

### Introduction

Multiple myeloma (MM) is a malignancy characterized by abnormal plasma cell proliferation and is generally confined to the bone marrow. However, 3% of cases may develop extramedullary involvement, defined as the formation of solid plasmacytomas outside the bone marrow.<sup>1</sup> Extramedullary involvement usually occurs in the upper skeletal system, but rarely orbital manifestations are observed.<sup>2,3,4</sup> The most common ocular signs and symptoms in orbital involvement are proptosis, redness, pain, diplopia, and impaired vision; proptosis is an indicator of metastasis and recurrence. This report presents a case of orbital involvement observed during follow-up of an MM patient in remission.

### Case Report

A 68-year-old female patient presented to our clinic with bilateral progressive vision loss for the previous 2 years. The patient had been diagnosed with MM 5 years earlier but was in remission at time of presentation and had no other systemic diseases in her medical history. On ophthalmologic examination

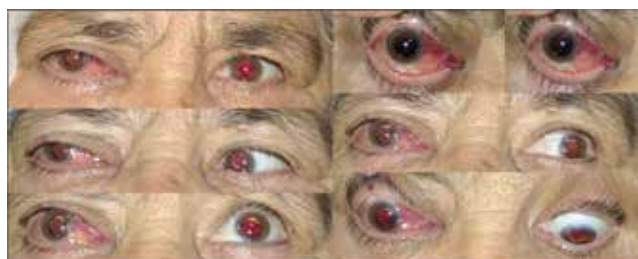her best corrected visual acuity (BCVA) was 3/10 in the right eye and 2/10 in the left eye. Anterior segment examination revealed cataract in both eyes. Posterior segment examination was normal. The patient underwent uncomplicated cataract surgery under local anesthesia on the left eye first, followed by the right eye a month later. She experienced no problems postoperatively and her uncorrected visual acuity was 7/10 in both eyes at the follow-up examination. No pathologies were observed during anterior or posterior examinations. The patient presented to our clinic about 15 days after her final follow-up appointment with complaints of pain, redness and low vision in her right eye. Her BCVA was 3/10 and 8/10 in the right and left eye, respectively. Proptosis was evident and eye movements were restricted in all directions in her right eye. On anterior segment examination of the right eye, subconjunctival hemorrhage and hyperemia were observed (Figure 1). Posterior segment examination of the right eye revealed optic disc edema and widespread choroidal folds (Figure 2). These clinical signs combined with the patient's history of MM suggested orbital metastasis, and urgent radiologic imaging was ordered. Magnetic resonance

**Address for Correspondence:** Mustafa Vatansever MD, Mersin University Faculty of Medicine, Department of Ophthalmology, Mersin, Turkey

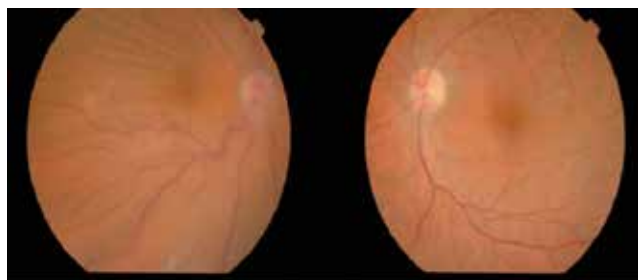
Phone: +90 507 340 89 58 E-mail: vatansevermustafa@hotmail.com **Received:** 16.06.2014 **Accepted:** 19.09.2014

This article is also published in Turkish under doi:10.4274/tjo.73645 pages 2016;46:148-150.

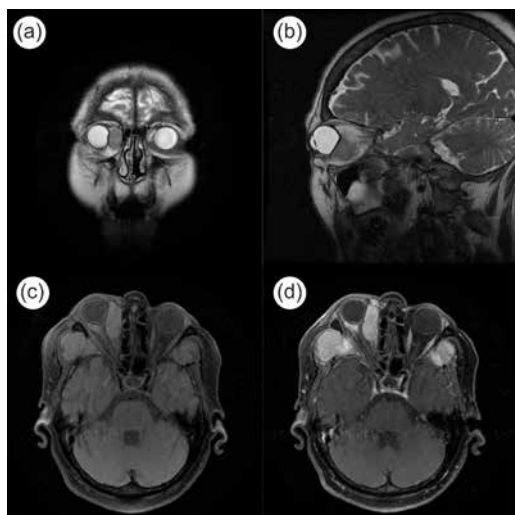
imaging revealed two mass lesions in the right orbital space behind the globe. In contrast-enhanced images the lesions showed homogeneous enhancement, and invasion of the extraocular muscles, disruption of globe shape and optic nerve compression were observed. In addition, mass lesions showing heterogeneous enhancement were present in both temporal fossa (Figure 3). The diagnosis was confirmed using a biopsy obtained from the temporal fossa lesion (Figure 4), and the patient was referred to the radiation oncology department for consultation. Palliative radiotherapy (RT) was recommended.



**Figure 1.** Hyperemia and subconjunctival hemorrhage were observed in the patient's right eye and eye motility was limited in directions



**Figure 2.** Color fundus photography revealed choroidal folds in the right eye, while the fundus appeared normal in the left eye



**Figure 3.** The mass located in the orbit visualized in three different planes by magnetic resonance imaging (a, b and c), and by contrast-enhanced magnetic resonance imaging (d)

## Discussion

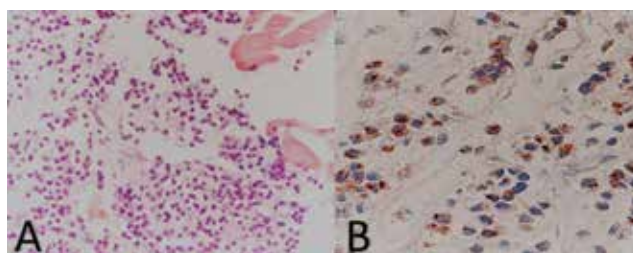
Ocular findings in MM may arise from systemic effects of the disease (increased blood viscosity) or infiltration of plasma cells into ocular tissues.<sup>4</sup> These ocular findings may include crystalline corneal deposits, exudative macular detachment, ciliary body cysts and retinal hemorrhage. Though rare, orbital involvement may be an extramedullary manifestation. The most common clinical sign of orbital involvement in MM is unilateral proptosis, while hyperemia, pain, diplopia and low vision occur less often.<sup>5</sup> There are also reports of bilateral proptosis in some cases.<sup>5</sup> Similarly, our case presented with proptosis, subconjunctival hemorrhage, pain and vision loss. Her ocular motility limitation, optic disc edema and choroidal folds resulted from a metastatic mass located posterior to the globe which was invading the extraocular muscles and applying pressure to both the globe and the optic nerve. All of these findings have been observed in similar cases of orbital involvement.<sup>1,2,6,7,8</sup>

Approximately 9% of orbital tumors in adults are metastases, and orbital metastases usually originate from lung and breast cancers.<sup>9</sup> There have also been reports of kidney, pancreas, prostate and gastric cancers forming orbital metastases.<sup>10,11</sup> The presence of metastasis in MM indicates a poor prognosis. Orbital metastases in particular have worse survival rates compared to other extramedullary plasmacytomas.<sup>6</sup> Mean expected survival for patients with recurrence is 12 months in the absence of systemic involvement, less in cases with systemic involvement. Of all malignancies occurring during remission, approximately one in three is orbital.

RT is an effective palliative therapy for MM patients, especially those with symptomatic local manifestations.<sup>12,13</sup> Palliative RT is indicated for deficits related to pain, bone involvement, spinal cord compression, root compression and cranial nerve involvement. We recommended RT in this case due to the pain that accompanied the orbital involvement.

## Conclusion

Proptosis has an important role in the differential diagnosis of malignancies. In cases like this, imaging should be done immediately and the differential diagnosis should be



**Figure 4.** Biopsy obtained from the patient shows plasma cells in different maturation stages (A) (hematoxylin&eosin, x400) and B) Lambda light chain staining was positive (x400)

considered. It should be kept in mind that proptosis can be the first sign of relapse in a patient previously diagnosed with MM.

#### Ethics

Informed Consent: It was taken.

Peer-review: Externally and internally peer-reviewed.

#### Authorship Contributions

Surgical and Medical Practices: Mustafa Vatansever, Fatma Merve Bozkurt, Erdem Dinç, Eda Bengi Yılmaz, Erdiñç Nayir, Ayşe Ayça Sarı, Özlem Yıldırım, Tuba Kara, Concept: Mustafa Vatansever, Fatma Merve Bozkurt, Erdem Dinç, Eda Bengi Yılmaz, Erdiñç Nayir, Ayşe Ayça Sarı, Özlem Yıldırım, Tuba Kara, Design: Mustafa Vatansever, Fatma Merve Bozkurt, Erdem Dinç, Eda Bengi Yılmaz, Erdiñç Nayir, Ayşe Ayça Sarı, Özlem Yıldırım, Tuba Kara, Data Collection or Processing: Mustafa Vatansever, Fatma Merve Bozkurt, Erdem Dinç, Eda Bengi Yılmaz, Erdiñç Nayir, Ayşe Ayça Sarı, Özlem Yıldırım, Tuba Kara, Analysis or Interpretation: Mustafa Vatansever, Fatma Merve Bozkurt, Erdem Dinç, Eda Bengi Yılmaz, Erdiñç Nayir, Ayşe Ayça Sarı, Özlem Yıldırım, Tuba Kara, Literature Search: Mustafa Vatansever, Fatma Merve Bozkurt, Erdem Dinç, Eda Bengi Yılmaz, Erdiñç Nayir, Ayşe Ayça Sarı, Özlem Yıldırım, Tuba Kara, Writing: Mustafa Vatansever, Fatma Merve Bozkurt, Erdem Dinç, Eda Bengi Yılmaz, Erdiñç Nayir, Ayşe Ayça Sarı, Özlem Yıldırım, Tuba Kara.

Conflict of Interest: No conflict of interest was declared by the authors.

Financial Disclosure: The authors declared that this study received no financial support.

#### References

1. Adkins JW, Shields JA, Shields CL, Eagle RC Jr, Flanagan JC, Campanella PC. Plasmacytoma of the eye and orbit. *Int Ophthalmol.* 1996;20:339-343.
2. Chim CS, Ng I, Trendell-Smith NJ, Liang R. Primary extramedullary plasmacytoma of the lacrimal gland. *Leukemia Lymphoma.* 2003;42:831-834.
3. Rodman HI, Font RL. Orbital involvement in multiple myeloma. Review of the literature and report of three cases. *Arch Ophthalmol.* 1972;87:30-35.
4. Knapp AJ, Gartner S, Henkind P. Multiple myeloma and its ocular manifestations. *Surv Ophthalmol.* 1987;5:343-351.
5. Malik A, Narang S, Handa U, Sood S. Multiple myeloma presenting as bilateral orbital proptosis. *Indian J Ophthalmol.* 2009;57:393-395.
6. Lida N, Saito K, Fukushima K. A case of extramedullary plasmacytoma arising from the lacrimal gland: a case report. *Eur J Plast Surg.* 2005;28:364-367.
7. Lazaridou MN, Micallef-Eyraud P, Hanna IT. Soft tissue plasmacytoma of the orbit as part of the spectrum of multiple myeloma. *Orbit.* 2007;26:315-318.
8. Movsas TZ, Balcer LJ, Eggenberger ER, Hess JL, Galetta SL. Sixth nerve palsy as a presenting sign of intracranial plasmacytoma and multiple myeloma. *J Neuro-Ophthalmol.* 2000;20:242-245.
9. Johansen S, Heegard S, Bogeskov L, Prause JU. Orbital space occupying lesions in Denmark 1974-1997. *Acta Ophthalmol Scand.* 2000;78:547-552.
10. Günalp I, Gündüz K. Metastatic orbital tumors. *Jpn J Ophthalmol.* 1995;39:65-70.
11. Jakobiec FA, Bilyk JR, Font RL. Orbit. In: *Ophthalmic Pathology.* Spencer WH Ed. Vol IV, 4 Ed, USA: WB Saunders. 1196;2438-934.
12. Hu K, Yahalom J. Radiotherapy in the management of plasma cell tumors. *Oncology (Williston Park).* 2000;14:101-108.
13. Yaneva MP, Goranova-Marinova V, Goranov S. Palliative radiotherapy in patients with multiple myeloma. *J Buon.* 2004;124:485-487.