



# Modification of the Temporal Inverted Internal Limiting Membrane Flap in Macular Hole Surgery: Envelope Technique

© Sinan Tatlıpınar

Yeditepe University Faculty of Medicine, Department of Ophthalmology, İstanbul, Türkiye

## Abstract

This case report aims to present a modification of the temporal inverted internal limiting membrane (ILM) flap technique in macular hole surgery. The inverted ILM flap technique was first described in 2010 and was shown to yield superior functional and anatomical outcomes in large macular holes compared to traditional ILM peeling. However, flap displacement can be a major concern with the inverted ILM flap technique. In the first case, a failed large macular hole after temporal inverted ILM flap surgery was reoperated, and flap displacement was observed as the reason for failure. The displaced ILM flap was inverted again and the superior corner of the flap was tucked under the small ILM defect in the upper nasal macular area to stabilize it. Hence, it is called as “envelope modification”. Another patient with rhegmatogenous retinal detachment with coexistent macular hole underwent vitrectomy surgery with silicone oil. The retina was attached postoperatively, and the macular hole was closed with a flat-open pattern. During silicone oil removal, the envelope modification was used and the hole closed. Both patients had visual improvement. Although the inverted ILM flap technique is very effective for large macular holes, the modification described here may further improve the success rate.

**Keywords:** Macular hole, inverted ILM flap, modification

## Introduction

Idiopathic macular hole is one of the main vitreoretinal interface disorders, and removal of the internal limiting membrane (ILM) has become a critical surgical step in most macular hole surgeries. Pars plana vitrectomy with ILM peeling is a safe and effective procedure with a success rate up to 98%. However, macular hole size has been found to be inversely correlated with the surgical success rate.<sup>1,2</sup> Therefore, large macular holes (minimum diameter >400 µm) have less favorable surgical outcomes.

The inverted ILM flap technique was first described in 2010 by Michalewska et al.,<sup>3</sup> who reported the superiority of this technique in large macular holes compared to traditional ILM peeling in terms of both functional and anatomical results. However, the authors pointed out that flap displacement was an important limitation of this technique and concluded that new methods of maintaining the inverted flap on the macular surface should be investigated.

This study presents a novel modification of the inverted ILM flap surgery. To the best of my knowledge, this is the first report of this surgical technique.

## Case Reports

### Case 1

A 64-year-old female patient with a history of decreased vision in her right eye for 3 to 4 months presented to our clinic. Her vision in the right eye was counting fingers. Optical coherence tomography (OCT) revealed a large macular hole with a minimum diameter of 896 µm ([Figure 1a](#)). A 23-gauge pars plana vitrectomy with temporal inverted ILM flap combined with phacoemulsification and intraocular lens implantation was performed. Brilliant Blue

**Cite this article as:** Tatlıpınar A. Modification of the Temporal Inverted Internal Limiting Membrane Flap in Macular Hole Surgery: Envelope Technique. Turk J Ophthalmol. [Ahead of Print]

**Address for Correspondence:** Sinan Tatlıpınar, Yeditepe University Faculty of Medicine, Department of Ophthalmology, İstanbul, Türkiye

**E-mail:** statlipinar@yeditepe.edu.tr

**ORCID-ID:** orcid.org/0000-0002-9959-8895

**Received:** 29.09.2025

**Revision Requested:** 22.12.2025

**Last Revision Received:** 24.12.2025

**Accepted:** 14.02.2026

**Publication Date:**

**DOI:** 10.4274/tjo.galenos.2026.20269

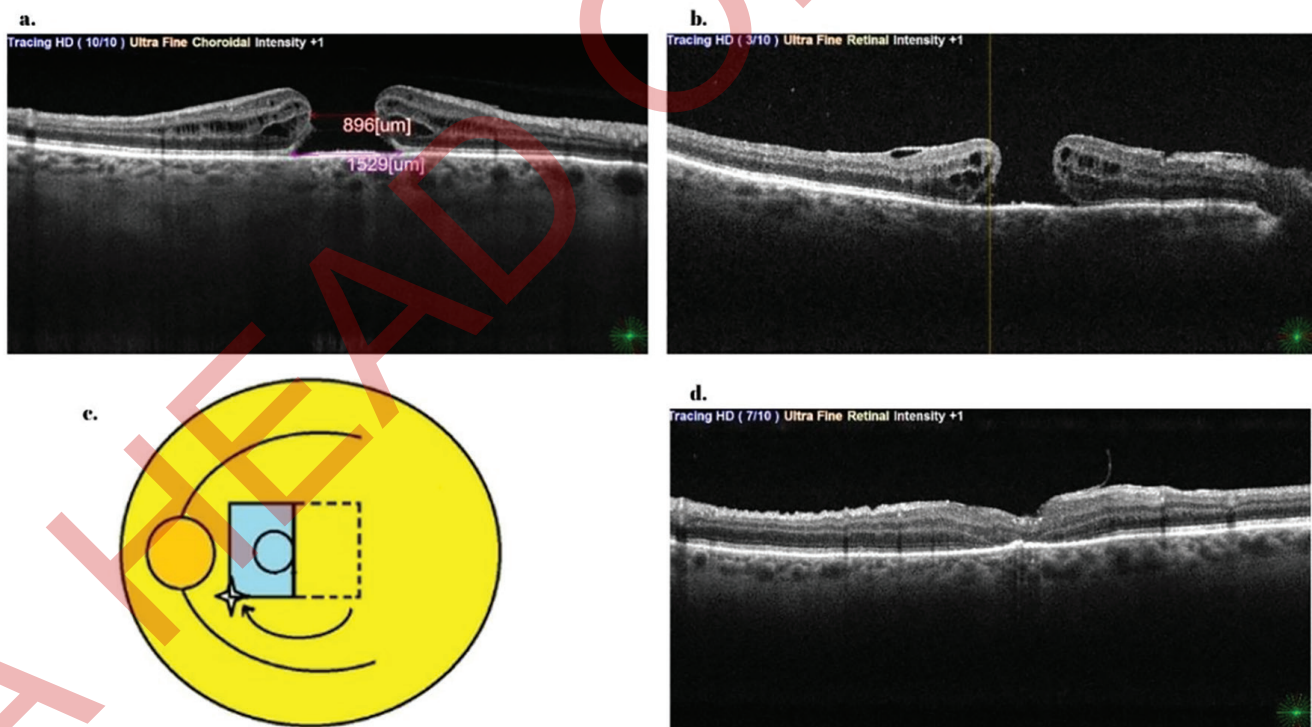


(BB) dye (Brilliant Peel 0.025%, Fluoron, Ulm, Germany) was used to stain the ILM and a temporal half ILM flap was created. The nasal side ILM was not peeled, and the rectangular temporal ILM flap was inverted over the nasal macula using a Tano scraper. A complete fluid-air exchange was performed, making sure that the ILM flap was in place, and 12%  $C_3F_8$  gas was used as tamponade. The patient was advised to maintain a prone position for 5 days. However, the hole remained open after the surgery (Figure 1b), and revision surgery was performed at 6 weeks. During the reoperation, BB dye was used to visualize the original ILM flap, which was observed to be detached and folded over itself in the temporal macular area. To maintain the ILM flap in an inverted position on the macular surface, an “envelope modification” was performed by creating a small ILM window in the superonasal macular area (Figure 1c, Figure 2). A short vertical ILM window was fashioned using ILM forceps. The ILM flap was then inverted over the hole and its superonasal corner was tucked through the window using a Tano scraper. The ILM flap was observed closely during fluid-air exchange and it was seen to be completely immobile at the tucked edge. Gas tamponade (12%  $C_3F_8$ ) was performed with

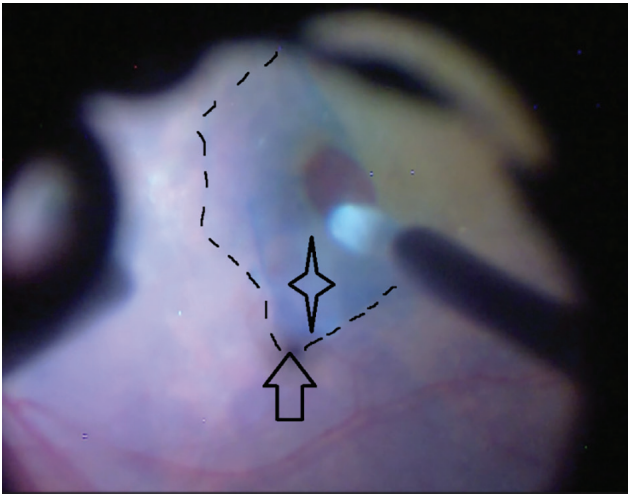
prone positioning for 5 days. Significant inflammation was observed postoperatively and managed with topical steroids (Pred Forte 1%, Allergan, Westport, Ireland). OCT taken 3 weeks after the surgery showed a closed macular hole (Figure 1d). Final visual acuity was 0.2, possibly due to changes in the retinal pigment epithelium (RPE) at the hole base. The hole remained closed during an 18-month follow-up period.

### Case 2

A 65-year-old female patient presented with loss of vision in the right eye for about 10 days. Her vision in the right eye was at the level of counting fingers, and she had a macula-off retinal detachment with a tear at the 10 o'clock position. Macular hole was not evident at the time of examination, possibly obscured by the bullous detachment. The patient underwent phaco-vitrectomy with silicone oil as endotamponade due to the necessity of air travel. A macular hole was clearly observed intraoperatively, and no special attempt was made to peel the ILM due to our previous experience in cases of rhegmatogenous retinal detachment cases with coexistent macular holes.<sup>4</sup> Additionally, ILM peeling may be challenging with a



**Figure 1.** a) Preoperative optical coherence tomography (OCT) section depicting large macular hole. b) Postoperative OCT section showing an open macular hole with internal limiting membrane (ILM) flap returned to its original position on the temporal foveal area. c) Drawing of the modification (the star represents the ILM window in the superonasal macula, the blue rectangle indicates the inverted flap, and the arrow shows the tucked corner, surgeon’s view). d) Postoperative OCT showing a closed macular hole with the inverted flap edge



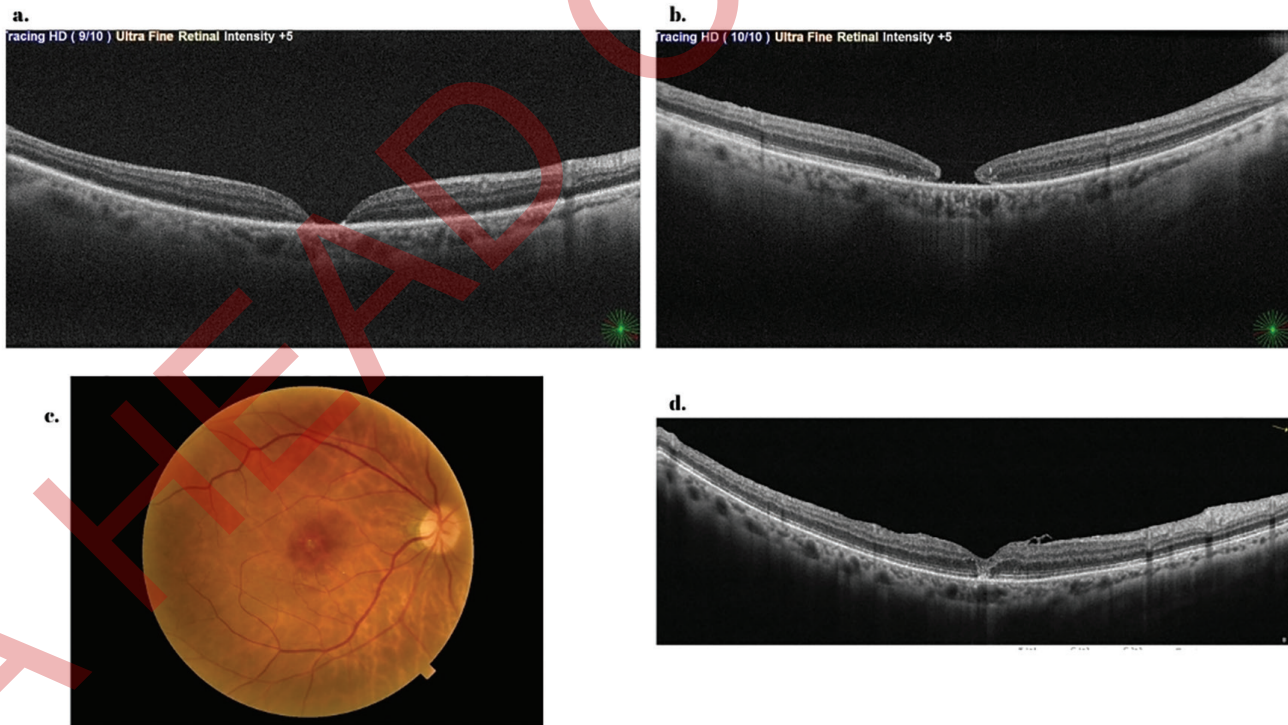
**Figure 2.** Still photo from the surgical video displaying the modification (arrow indicating the tucked corner and the star representing the ILM window in the superonasal macula, surgeon's view)

*ILM: Internal limiting membrane*

detached retina, and dyes can easily pass through the hole into the subretinal space, possibly causing toxicity. On the first postoperative day, the retina was attached and the hole was closed with flat-open pattern (Figure 3a). Visual acuity was 0.05 under silicone oil. After 2 months, OCT showed the hole edges had started to raise and round up (Figure 3b). Silicone oil removal was performed at 3 months, and the inverted ILM flap technique with envelope modification as described above was used to close the hole. Under 12% C<sub>3</sub>F<sub>8</sub> gas with 5 days of prone positioning, the hole closed successfully with a U pattern (Figure 3c, d). Her final visual acuity was 0.2 and the hole remained closed during a 25-month follow-up period.

### Discussion

The surgical management of large macular holes has proven challenging despite ILM peeling. The surgical approach described by Michalewska et al.<sup>3</sup> utilizes an ILM flap as a scaffold to induce retinal gliosis within the macular hole, thereby augmenting hole closure. In 2015, Michalewska et al.<sup>5</sup> introduced the temporal inverted flap technique and compared it to the classic inverted ILM flap technique. The authors reported that the temporal inverted



**Figure 3.** a) Attached retina with flat-open macular hole on postoperative day 1. b) After 2 months, the hole edges started to elevate and round up. c, d) Fundus photo and optical coherence tomography showing closed hole with the ILM flap edge on the nasal foveal area at last follow-up visit

*ILM: Internal limiting membrane*

flap would act as a scaffold for retinal gliosis at the roof of the macular hole without creating an obstacle at the base of the hole, unlike the trimmed ILM flaps in the original technique.

Flap displacement, however, may be a major concern when using the inverted ILM flap technique. In their original report, the authors stated that inverted ILM flaps had displaced spontaneously during fluid-air exchange in 7 of 50 eyes (14%).<sup>3</sup> They concluded that new techniques of maintaining the inverted ILM flap in position should be explored in the future. Although ILM flaps may be stable at the end of surgery, they can detach shortly afterwards due to fluid accumulation at the posterior pole. In a more recent study, the same group reported a 3.8% failure rate in inverted ILM flap procedures, and they repositioned the displaced ILM flap in the second surgery mostly using silicone oil as tamponade.<sup>6</sup>

The first patient in the current report needed the inverted ILM flap technique due to the large size of the macular hole. Although every step of the surgery was performed meticulously, the hole failed to close due to flap displacement. Since the stability of inverted ILM flap is somewhat unpredictable, the current report recommends a modification. The envelope technique involves creating a small vertical ILM window in the nasal macular area away from papillomacular bundle and tucking one of the corners of the inverted ILM flap through the window and under the unpeeled nasal ILM. This tucking ensures that the ILM flap stays in position during the fluid-air exchange and after the surgery. This approach worked very well in both patients, and the holes closed shortly in a U pattern. One may propose to tuck both corners of the flap, but the author believes that this will only add extra work, because tucking one corner is sufficient.

Despite the favorable anatomical outcomes, visual improvement was limited. This can probably be attributed to outer retinal/ellipsoid zone defect and RPE changes at the hole base in the first case. The RPE atrophy was believed to be due to repeat surgery, dye usage, and possibly significant inflammation after the second surgery. The author believes it is not related to the modification because the ILM flap was not in contact with the hole base, unlike in the classic inverted ILM technique. Although improved, visual acuity was also limited in the second case, likely due to underlying macula-off retinal detachment. No epiretinal membrane formation or fibrosis was observed during the follow-up period in both cases.

Different surgical techniques or adjuncts like perfluorocarbon liquids or viscoelastics have been used for flap stabilization.<sup>7</sup> Perfluorocarbon liquids have been utilized to “iron” the inverted ILM flap and prevent flap

displacement during fluid-air exchange and afterwards. However, apart from the additional cost, these heavy liquids may cause toxicity. Additionally, it does not guarantee the stability of ILM flap, unlike the current modification.

This additional modification may be seen as unnecessary by some surgeons, but it may save both surgeon and patient from reoperation. This modified technique may be used in inverted ILM flap cases that failed due to flap displacement or can be used primarily in temporal inverted ILM flap surgeries according to the surgeon's discretion. The author proposes using a superior inverted ILM flap and tucking the temporal corner of the flap under the inferotemporal macular area. This may preserve the inferior visual field by moving the tucking area from the superior to inferior macula.

In conclusion, although the inverted ILM flap is a very effective surgical procedure for large macular holes, modifying the technique as described may augment the success rate. Larger studies are needed to determine whether the modified technique affects anatomical and visual results.

#### Ethics

**Informed Consent:** Due to the retrospective nature of the study, informed consent was not obtained.

#### Declarations

**Conflict of Interest:** No conflict of interest was declared by the author.

**Financial Disclosure:** The author declared that this study received no financial support.

#### References

1. Velez-Montoya R, Ramirez-Estudillo JA, Sjöholm-Gomez de Liano C, Bejar-Cornejo F, Sanchez-Ramos J, Guerrero-Naranjo JL, Morales-Canton V, Hernandez-Da Mota SE. Inverted ILM flap, free ILM flap and conventional ILM peeling for large macular holes. *Int J Retina Vitreous*. 2018;4:8.
2. Shroff D, Gupta P, Atri N, Gupta C, Shroff C. Inverted internal limiting membrane (ILM) flap technique for macular hole closure: patient selection and special considerations. *Clin Ophthalmol*. 2019;13:671-678.
3. Michalewska Z, Michalewski J, Adelman RA, Nawrocki J. Inverted internal limiting membrane flap technique for large macular holes. *Ophthalmology*. 2010;117:2018-2025.
4. Tatlıpınar S, Marangoz D, Altunsoy M, Kohen MC. Surgery on two patients with rhegmatogenous retinal detachment with coexistent macular hole. *Turk J Ophthalmol*. 2013;43:374-376.
5. Michalewska Z, Michalewski J, Dulciewska-Cichecka K, Adelman RA, Nawrocki J. Temporal inverted internal limiting membrane flap technique versus classic inverted internal limiting membrane flap technique: a comparative Study. *Retina*. 2015;35:1844-1850.

6. Michalewska Z, Nawrocki J. Repeat surgery in failed primary vitrectomy for macular holes operated with the inverted ILM flap technique. *Ophthalmic Surg Lasers Imaging Retina*. 2018;49:611-618.
7. Karabas L, Tokuç EÖ, Seyyar SA, Şahin Ö. A new complementary touch for the temporal inverted internal limiting membrane flap technique. *J Ophthalmic Vis Res*. 2025;20:10.18502/jovr.v20.14516.

A HEAD OF PRINT