



## *In Vivo* Confocal Microscopy and Anterior Segment Optical Coherence Tomography Findings of Patients with Iridocorneal Endothelial Syndrome

✉ Gülay Güler Canözer, ✉ Emine Tınkır Kayıtmazbatır, ✉ Esra Öztürk, ✉ Ayşe Bozkurt Oflaz, ✉ Banu Bozkurt

Selçuk University Faculty of Medicine, Department of Ophthalmology, Konya, Türkiye

### Abstract

This case report aims to present the findings of *in vivo* confocal microscopy (IVCM) and anterior segment optical coherence tomography (AS-OCT) in three patients with iridocorneal endothelial (ICE) syndrome. Three female patients 37, 50, and 57 years of age presented with complaints of unilateral visual impairment and elevated intraocular pressure (IOP). Biomicroscopy revealed unilateral pupil irregularities and anterior synechiae, and gonioscopy demonstrated synechiae in the iridocorneal angle. IOP was within normal limits with medical treatment in two patients, while one patient had an IOP of 44 mmHg despite maximal antiglaucomatous treatment. IVCM revealed large, polymorphic, and hyperreflective cells in the corneal endothelial layer of the affected eyes and normal corneal epithelium, stroma, and endothelium in the fellow eyes. AS-OCT findings were normal in healthy eyes, while the affected eye showed synechiae in the iridocorneal angle and a hyperreflective, thickened endothelial layer. The patient with refractory glaucoma underwent trabeculectomy surgery with 5-fluorouracil. In conclusion, IVCM and AS-OCT allow a detailed examination of endothelial cell abnormalities and iridocorneal membranes in ICE syndrome, which is characterized by unilateral pupil and iris irregularities and anterior synechiae mainly in women.

**Keywords:** Iridocorneal endothelial syndrome, *in vivo* confocal microscopy, anterior segment optical coherence tomography

**Cite this article as:** Güler Canözer G, Tınkır Kayıtmazbatır E, Öztürk E, Bozkurt Oflaz A, Bozkurt B. *In Vivo* Confocal Microscopy and Anterior Segment Optical Coherence Tomography Findings of Patients with Iridocorneal Endothelial Syndrome. *Turk J Ophthalmol* 2024;54:170-174

This study was presented as an oral presentation at the 45<sup>th</sup> TOA Winter Symposium (19-21 January 2024, Konya).

**Address for Correspondence:** Emine Tınkır Kayıtmazbatır, Selçuk University Faculty of Medicine, Department of Ophthalmology, Konya, Türkiye  
E-mail: drtinkir@gmail.com ORCID-ID: orcid.org/0000-0002-8553-6992  
Received: 24.01.2024 Accepted: 22.04.2024

DOI: 10.4274/tjo.galenos.2024.78861

### Introduction

Iridocorneal endothelial (ICE) syndrome is a group of diseases in which corneal endothelial cells multiply and migrate to the iridocorneal angle and onto the iris.<sup>1</sup> There are three clinical variants: Chandler syndrome, progressive iris atrophy, and Cogan-Reese syndrome.<sup>2</sup> Yanoff<sup>3</sup> proposed the term ICE for these clinical entities, which have similar clinical findings and a common pathogenic mechanism characterized by abnormal endothelial proliferation.<sup>4</sup> In ICE syndrome, abnormally proliferating endothelial cells form a membrane on the iridocorneal angle and peripheral iris. This membrane can cause pupillary disorder, high intraocular pressure (IOP), corneal decompensation, and corneal edema due to peripheral anterior synechiae and peripheral iris traction. ICE syndrome occurs sporadically, is usually unilateral, and typically affects women 30-40 years of age.<sup>5</sup> Although its etiology is not fully known, it is thought to be of viral origin.<sup>6</sup> In the differential diagnosis, consideration should be given to conditions such as posterior polymorphous corneal dystrophy, Fuchs endothelial dystrophy, and Axenfeld-Rieger syndrome. In addition, findings such as aniridia, pupillary deformities, and corneal edema must also be evaluated alongside potential diagnoses including iris melanoma, inflammatory iris nodules, and glaucoma. This case report presents the clinical examination findings, *in vivo* confocal microscopy (IVCM, Heidelberg Retina Tomograph 3, Rostock Cornea Module, Germany) and anterior segment optical coherence tomography (AS-OCT, DRI Triton Topcon, Tokyo, Japan) findings, and treatment of 3 female patients with ICE syndrome.

### Case Report

#### Case 1

A 50-year-old woman presented with decreased vision and elevated IOP in the left eye. The patient was using topical



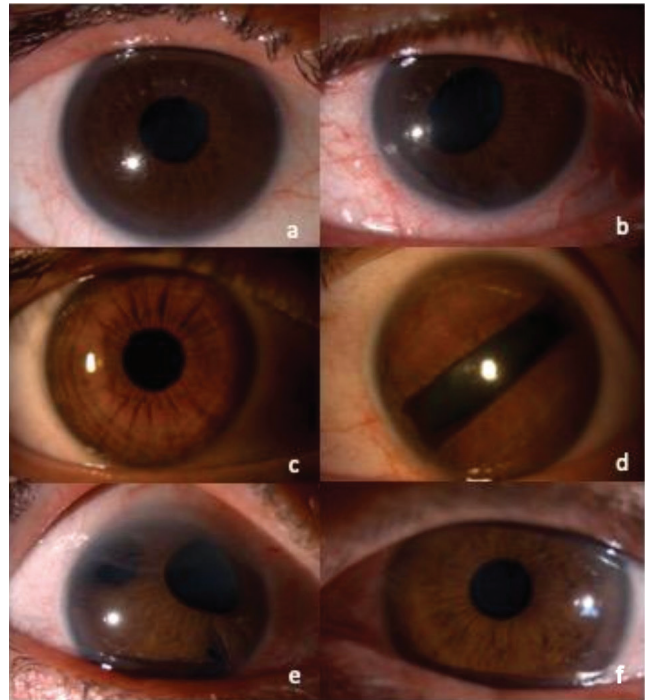
brimonidine (Alphagan P 0.15%, AbbVie Pharmaceuticals, İstanbul, Türkiye), timolol/dorzolamide (Tomec 2% + 0.5% Abdi İbrahim Pharmaceuticals, İstanbul, Türkiye), and latanoprostene bunod (Vyzulta 0.024%, Bausch & Lomb Incorporated, Bridgewater, NJ, USA) drops in the left eye. On examination, her best-corrected visual acuity (BCVA) was 20/20 bilaterally and her IOP was 16 mmHg in the right eye and 44 mmHg in the left eye. Anterior segment findings in the right eye were normal, while the left eye showed inferonasal pupil displacement (Figure 1a, b) and peripheral anterior synechiae at 6-9 o'clock with a "beaten bronze" appearance in the endothelium. On gonioscopic examination of the left eye, extensive synechia at the iridocorneal angle was observed in the region corresponding to the iris irregularity (Figure 2a). On fundus examination, the cup/disc (C/D) ratio was 0.3 in the right eye and 0.7 in the left eye. Peripapillary nerve fiber layer thickness was 98 µm in the right eye and 63 µm in the left eye (Figure 3a, b). Visual field test revealed no visual field defect in the right eye and an altitudinal scotoma in the left eye (Figure 3c, d). The patient underwent trabeculectomy surgery with 5-fluorouracil (5-FU; Koçak Pharmaceuticals, Tekirdağ, Türkiye). IOP was 12 mmHg at postoperative 1 month.

#### Case 2


A 37-year-old woman presented with decreased vision and high IOP in the left eye. She was using topical brimonidine (Brimogut 0.15%, Bilim Pharmaceuticals, İstanbul, Türkiye) and brinzolamide/timolol (Azarga, Novartis International AG, Basel, Switzerland) in her left eye. Her BCVA was 20/20 in both eyes; IOP was 15 mmHg in the right eye and 12 mmHg in the left eye. On anterior segment examination, the right eye was normal, while the pupil of the left eye was rectangular in shape, elongated on a superotemporal-inferonasal axis (Figure 1c, d). There were peripheral anterior synechiae at 2 and 7 o'clock with a "beaten bronze" appearance in the endothelium. Gonioscopy also revealed extensive synechia at the iridocorneal angle in the region of the iris irregularity (Figure 2b). On fundus examination, the optic nerve and macula were normal in both eyes. The C/D ratio was 0.3 bilaterally. The patient was recommended follow-up with her current antiglaucoma therapy.

#### Case 3

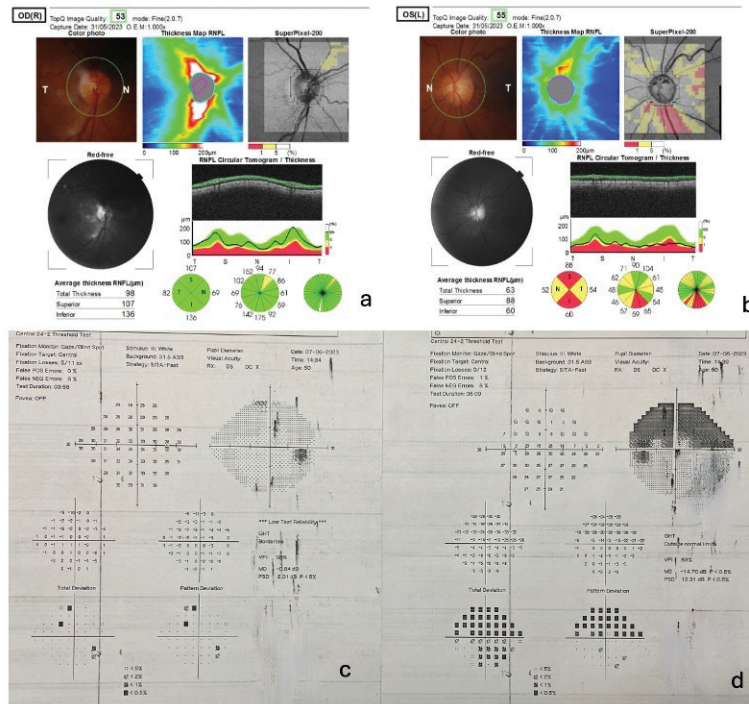
A 57-year-old woman presented with decreased vision and high IOP. The patient was using brimonidine (Brimogut 0.15%, Bilim Pharmaceuticals, İstanbul, Türkiye) and brinzolamide/timolol (Azarga, Novartis International AG, Basel, Switzerland) antiglaucoma drops. On examination, BCVA was 20/40 in the right eye and 20/20 in the left eye. IOP was measured as 18 mmHg in the right eye and 13 mmHg in the left eye. On anterior segment examination, peripheral iridocorneal synechiae at 1-3 o'clock, iris atrophy, and corectopia were observed in the right eye (Figure 1e). Left anterior segment examination was normal



**Figure 1.** Anterior segment photographs of the patients: Patient 1: (a) healthy right eye, (b) affected eye showing inferonasal pupil displacement and anterior synechia in the same quadrant. Patient 2: (c) healthy right eye, (d) affected left eye showing an abnormal rectangular pupil extending along a superotemporal-inferonasal axis. Patient 3: (e) affected right eye showing peripheral iridocorneal synechia at 1-3 o'clock, iris atrophy, and corectopia, (f) healthy left eye



**Figure 2.** (a) Gonioscopy image of patient 1 shows extensive synechia at the iridocorneal angle in the lower nasal quadrant where the iris irregularity is located, and apparent ectropion uvae in the nasal quadrant, consistent with the anterior segment image. (b) Gonioscopy image of patient 2 shows extensive synechia at the iridocorneal angle in the region of the iris irregularity



**Figure 3.** In patient 1, (a) peripapillary nerve fiber layer was 98 µm in the right eye, (b) 63 µm in the left eye, (c) visual field tests demonstrated no defect in the right eye, (d) altitudinal scotoma was detected in the left eye

(Figure 1f). On gonioscopy, there were extensive synechiae at the iridocorneal angle corresponding to the iris irregularity. Fundus examination revealed normal maculae bilaterally with a C/D ratio of 0.5 on the right and 0.3 on the left. The peripapillary nerve layer thickness was measured as 93 µm on the right and 105 µm on the left. The patient was recommended follow-up with her current medical treatment.

#### IVCM Findings

On IVCM, the corneal epithelium, stroma, and endothelial layers were normal in the patients' healthy eyes (Figure 4a, c, f). In the affected eyes, patient 1 exhibited cobblestone-like swollen endothelial cells, which were thought to correspond to the beaten bronze appearance observed on biomicroscopy, and occasional giant cells (Figure 4b). In patient 2, the endothelial cells were hyperreflective, highly polymorphic, and had lost their normal hexagonality, showing irregular borders and cobblestone pattern (Figure 4d), while hyperreflective uni- or binucleate giant endothelial cells were observed in patient 3 (Figure 4e).

#### AS-OCT Findings

AS-OCT parameters were within normal limits in the patients' healthy eyes. Corneal thicknesses were 559, 576, and 480 µm, respectively. In the affected eyes, there was extensive synechia at the iridocorneal angle, increased hyperreflectivity in the endothelial layer, and thickened hyperreflective tissue resembling an epiretinal membrane over the iridocorneal angle and iris. An increase in hyperreflectivity was observed in the endothelial layer of one patient, while another patient had several round hyperreflective formations on the membranous

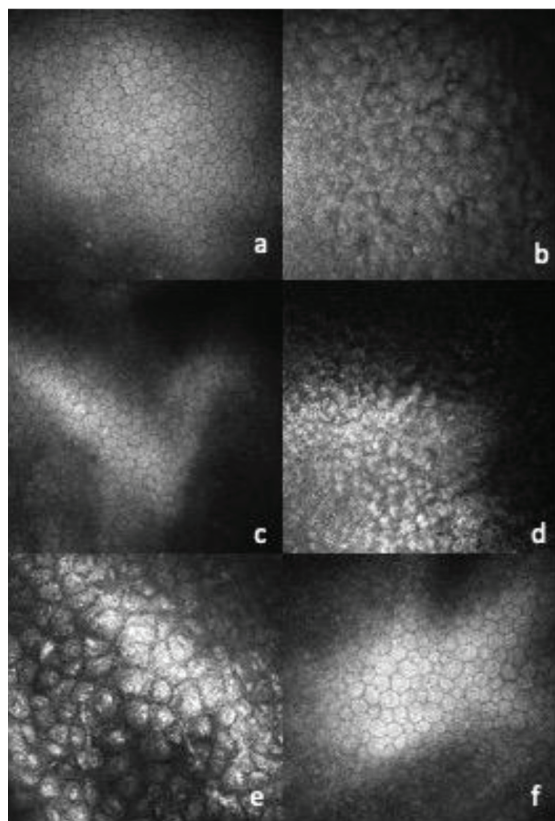
structure overlying the iris and one beneath the endothelial layer (Figure 5a-d). Corneal thicknesses were 552, 604, 561 µm, respectively.

### Discussion

ICE syndrome is a rare condition characterized by proliferative and structural abnormalities in the corneal endothelium, iridocorneal angle obstruction, and iris defects such as atrophy and holes.<sup>4</sup> Patients usually present when they notice a change in the shape and position of the pupil or because of a decrease in visual acuity due to corneal edema and glaucoma. Two of our patients presented to our clinic with reduced vision and all were using antiglaucomatous treatment due to high IOP.

Although the etiology of ICE is still not fully understood, it is thought to be viral in origin. Using polymerase chain reaction (PCR) methods, Alvarado et al.<sup>6</sup> detected herpes simplex virus (HSV) DNA in over 60% of corneal and aqueous humor samples obtained from patients with ICE syndrome, but PCR results were negative in the patients' unaffected eyes. Histopathological studies have shown that corneal endothelial cells have epithelial-like morphological features, and these epithelial-like endothelial cells were called "ICE cells".<sup>7</sup> These abnormal endothelial cells obstruct the iridocorneal angle and advance through the anterior chamber to cover the iris, forming a basement membrane that leads to abnormal pupil shape and iris atrophic damage and adhesions to neighboring structures.<sup>8</sup> Being a rare disease with variable clinical presentations, ICE syndrome may be overlooked and misdiagnosed. Imaging the abnormal corneal endothelium





**Figure 4.** *In vivo* confocal microscopy images of the patients. Patient 1: (a) hexagonal endothelial layer in the healthy eye, (b) endothelial cells showing cobblestone-like swelling and occasional giant cells in the affected eye. Patient 2: (c) endothelial layer in the healthy eye, (d) hyperreflective, irregularly bordered endothelial cells showing cobblestone-like swelling in the affected eye. Patient 3: (e) hyperreflective uni- or binucleate giant endothelial cells in the affected right eye, (f) normal-looking endothelial cells in the healthy eye

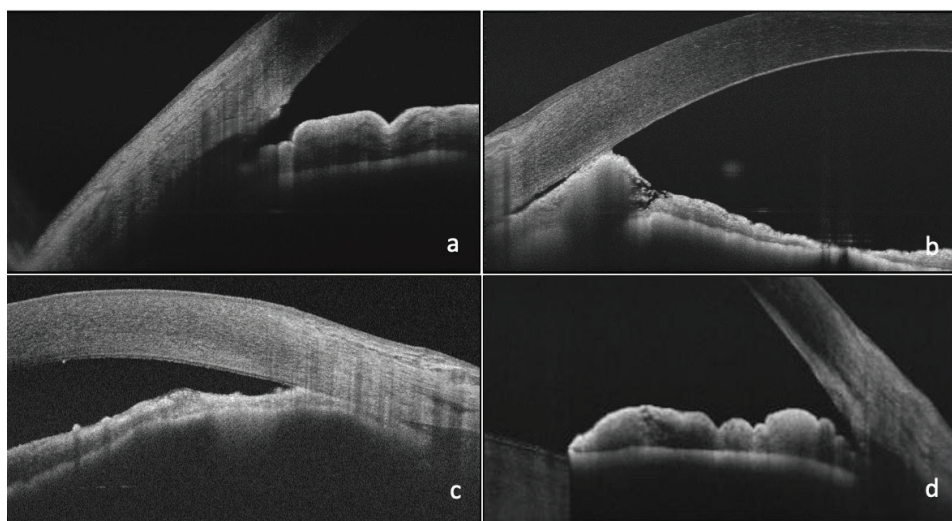
during examination or evaluating the anterior chamber angle in glaucoma suspects is also important in terms of distinguishing it from other endotheliopathies. High-magnification slit-lamp examination may show a “beaten bronze” endothelium appearance. However, evaluating the endothelial layer and visualizing the anterior chamber and iris details might be difficult in patients with severe corneal edema.

IVCM is a non-interventional, high-resolution imaging technique that aids in the evaluation of corneal layers and cells, similar to histopathological sections. In a study of patients with ICE syndrome, two basic “epithelial-like endothelial cell” morphologies were described.<sup>9</sup> While the first type of abnormal endothelium cells were close in shape and size to the normal endothelial cell morphology, they lost normal hexagonality and had a distinct uniform “cobblestone-like” nucleus in their centers, with some having two nuclei or a single divided nucleus. The second type was more irregular in cellular size and shape, with hyperreflective variously shaped nuclei adjacent to the cell borders.<sup>9</sup>

In another IVCN and specular microscopy study conducted in patients with ICE syndrome, three types of cells were identified: smooth, epithelium-sized cells; cells resembling epithelial wing cells with a central hyperreflective nucleus; and highly irregular endothelial cells resembling superficial epithelial cells.<sup>10</sup> In another study conducted in Türkiye, ICE cells were identified on specular microscopy as white-bordered black cells, the reverse image of endothelial cells, and peripheral anterior synechiae and iris atrophy were shown in ultrasonic biomicroscopy in the same eye.<sup>11</sup>

In our cases, IVCN in eyes affected by ICE syndrome revealed highly polymorphic endothelial cells with cobblestone-like swelling, as well as hyperreflective uni- or binucleate giant cells in one patient.

A case report published by Hillard<sup>12</sup> evaluated angle and corneal changes in ICE syndrome with AS-OCT and demonstrated



**Figure 5.** Anterior segment optical coherence tomography images. Patient 1: (a) healthy iridocorneal angle in left eye; (b) synechia at the iridocorneal angle, increased hyperreflectivity in the endothelial layer, thickening of hyperreflective tissue resembling an epiretinal membrane on the iridocorneal angle and iris in the affected right eye. Patient 3: (c) the affected right eye shows synechia at the iridocorneal angle, increased hyperreflectivity in the endothelial layer, irregular tissue thickening of the hyperreflective layer overlying the iris, several round hyperreflective formations on this membranous structure over the iris, and one under the endothelial layer; (d) normal iridocorneal angle appearance in the healthy left eye

in detail iridocorneal membrane formation, adhesions, and subepithelial bullae secondary to corneal edema. In our study, in addition to iridocorneal adhesions on swept-source OCT, we observed increased hyperreflectivity in the endothelial layer and a thickened hyperreflective tissue resembling an epiretinal membrane on the iridocorneal angle and iris.

In patients with high IOP, medical treatment and drugs that reduce aqueous production are preferred as the first-line treatment option. However, as the possible role of HSV in the pathogenesis has not been conclusively ruled out, prostaglandin analogues should be avoided in treatment. Surgical interventions such as goniotomy, trabeculectomy with antifibrotic agents such as mitomycin-C or 5-FU, glaucoma drainage implants, or cyclodestructive procedures should be considered in cases where medical treatment is insufficient.<sup>1,2,13</sup> However, recurrent obstructions resulting from proliferation of the endothelial membrane may cause surgical failure. Among our cases, one patient with high IOP despite medical treatment underwent trabeculectomy surgery combined with 5-FU.

In conclusion, ICE syndrome should be suspected in cases of unilateral IOP elevation accompanied by corectopia and corneal edema, especially in female patients. IVCN and AS-OCT are non-invasive, diagnostically useful imaging methods that can reveal the abnormal structure and anterior segment migration of endothelial cells with epithelial characteristics in ICE syndrome.

#### Ethics

**Informed Consent:** Obtained.

#### Authorship Contributions

Surgical and Medical Practices: G.G.C., E.Ö., B.B., Concept: G.G.C., E.T.K., E.Ö., A.B.O., B.B., Design: G.G.C., E.T.K., E.Ö., A.B.O., B.B., Data Collection or Processing: G.G.C., E.T.K., E.Ö., A.B.O., Analysis or Interpretation: G.G.C., E.T.K., E.Ö., A.B.O., B.B., Literature Search: G.G.C., E.T.K., E.Ö., B.B., Writing: G.G.C., E.T.K., A.B.O., B.B.

**Conflict of Interest:** No conflict of interest was declared by the authors.

**Financial Disclosure:** The authors declared that this study received no financial support.

#### References

1. Silva L, Najafi A, Suwan Y, Teekhasaene C, Ritch R. The iridocorneal endothelial syndrome. *Surv Ophthalmol*. 2018;63:665-676.
2. Sacchetti M, Mantelli F, Marengo M, Macchi I, Ambrosio O, Rama P. Diagnosis and Management of Iridocorneal Endothelial Syndrome. *Biomed Res Int*. 2015;2015:763093.
3. Yanoff M. Iridocorneal endothelial syndrome: unification of a disease spectrum. *Surv Ophthalmol*. 1979;24:1-2.
4. Shields MB. Progressive essential iris atrophy, Chandler's syndrome, and the iris nevus (Cogan-Reese) syndrome: a spectrum of disease. *Surv Ophthalmol*. 1979;24:3-20.
5. Scheie HG, Yanoff M. Iris nevus (Cogan-Reese) syndrome. A cause of unilateral glaucoma. *Arch Ophthalmol*. 1975;93:963-970.
6. Alvarado JA, Underwood JL, Green WR, Wu S, Murphy CG, Hwang DG, Moore TE, O'Day D. Detection of herpes simplex viral DNA in the iridocorneal endothelial syndrome. *Arch Ophthalmol*. 1994;112:1601-1609.
7. Sherrard ES, Frangoulis MA, Muir MG, Buckley RJ. The posterior surface of the cornea in the irido-corneal endothelial syndrome: a specular microscopic study. *Trans Ophthalmol Soc U K* (1962). 1985;104(Pt 7):766-774.
8. Campbell DG, Shields MB, Smith TR. The corneal endothelium and the spectrum of essential iris atrophy. *Am J Ophthalmol*. 1978;86:317-324.
9. Le QH, Sun XH, Xu JJ. In-vivo confocal microscopy of iridocorneal endothelial syndrome. *Int Ophthalmol*. 2009;29:11-18.
10. Chiou AG, Kaufman SC, Beuerman RW, Ohta T, Yaylali V, Kaufman HE. Confocal microscopy in the iridocorneal endothelial syndrome. *Br J Ophthalmol*. 1999;83:697-702.
11. Altındal EU, Türkoğlu EB, Hasanreisöglü M, Gülpınar G. Iridocorneal Endothelial Syndrome: A Case Report and Review of the Literature. *Turkiye Klinikleri J Ophthalmol*. 2016;25:66-70.
12. Hillard JG. Case Report: Iridocorneal Endothelial Syndrome Progression Documented by Anterior Segment Optical Coherence Tomography. *Optom Vis Sci*. 2019;96:309-313.
13. Laganowski HC, Kerr Muir MG, Hitchings RA. Glaucoma and the iridocorneal endothelial syndrome. *Arch Ophthalmol*. 1992;110:346-350.