



Conjunctival Collagen Cross-Linking for the Treatment of Leaking Avascular Cystic Bleb

Ali Mert Koçer, Büşra Turpçuoğlu

University of Health Sciences Türkiye, Ulucanlar Eye Training and Research Hospital, Clinic of Ophthalmology, Ankara, Türkiye

Abstract

Trabeculectomy is a primary surgical procedure used to reduce intraocular pressure (IOP) in patients with glaucoma. Despite its effectiveness, it can lead to significant complications, including hypotony, choroidal effusion, blebitis, and bleb leaks. Bleb leaks require prompt medical or surgical intervention to prevent severe complications such as blebitis and bleb-associated endophthalmitis. In recent years, the indications for collagen cross-linking (CCL) have expanded beyond corneal ectatic diseases to include various ocular conditions such as keratitis and leaking blebs. Here, we present the case of a 70-year-old male patient with a leaking avascular cystic bleb. Following treatment with a combination of conjunctival CCL, topical gentamicin, a dorzolamide/timolol combination, and a therapeutic contact lens, the patient experienced cessation of bleb leakage and an increase in IOP.

Keywords: Bleb leak, collagen cross-linking, trabeculectomy

Introduction

Trabeculectomy is a commonly performed surgical procedure aimed at reducing intraocular pressure (IOP) in patients with glaucoma.¹ Despite its efficacy in lowering IOP and preserving vision, trabeculectomy is associated with several potential complications.² Among these, bleb leaks are particularly concerning due to their potential to cause serious complications such as blebitis and bleb-associated endophthalmitis.³ These complications necessitate timely and effective management, either medically or surgically, to prevent further morbidity.

Collagen cross-linking (CCL) is a minimally invasive procedure designed to strengthen the cornea by using a combination of riboflavin and ultraviolet A (UVA) light to induce cross-links between collagen fibers. This process enhances the cornea's mechanical stability and resistance to deformation. Over recent years, the therapeutic applications of CCL have significantly expanded beyond its initial use in treating corneal ectatic disorders.⁴ CCL is now being investigated for its efficacy in managing a variety of ocular conditions, including infectious keratitis and leaking blebs.^{5,6}

In this case report, we present a 70-year-old male patient who developed a leaking avascular cystic bleb following trabeculectomy. The patient's management included conjunctival CCL combined with a regimen of topical antibiotics, hypotensive eye drops, and the use of a therapeutic contact lens (TCL). By documenting the cessation of bleb leakage and the subsequent increase in IOP following this multimodal treatment approach, this case report underscores the potential utility of CCL in addressing bleb leaks.

Case Report

A 70-year-old male patient was admitted to the glaucoma department for routine evaluation. His medical history was unremarkable for systemic diseases. However, his ocular history included a trabeculectomy performed on the left eye seven years

Cite this article as: Koçer AM, Turpçuoğlu B. Conjunctival Collagen Cross-Linking for the Treatment of Leaking Avascular Cystic Bleb. *Turk J Ophthalmol.* 2024;54:309-312

Address for Correspondence: Ali Mert Koçer, University of Health Sciences Türkiye, Ulucanlar Eye Training and Research Hospital, Clinic of Ophthalmology, Ankara, Türkiye

E-mail: alimertkocer@gmail.com **ORCID-ID:** orcid.org/0000-0001-6847-1560

Received: 29.05.2024 **Accepted:** 22.08.2024

DOI: 10.4274/tjo.galenos.2024.55601

prior. Best corrected visual acuity was 0.7 in the right eye and 0.4 in the left, as measured with Snellen chart. IOP readings were 14 mmHg in the right eye and 7 mmHg in the left.

Anterior segment examination of the right eye revealed a pseudophakic eye with no other significant findings. In the left eye, a notable avascular cystic bleb was present at the 12 o'clock position, along with pseudophakia. The bulbar conjunctiva in the superior region was hyperemic, and prominent scleral vessels were observed nasally to the avascular cystic bleb. The conjunctiva adjacent to the bleb exhibited limited mobility. Anterior chamber depth was normal, and the cornea was clear. Fluorescein staining revealed pinpoint leakage from the avascular cystic bleb (Figure 1A). The bleb leak was located approximately 2 mm from the limbus. Anterior segment optical coherence tomography showed fluid-containing cystic spaces (Figure 2). Fundus examination revealed a total cup-to-disc ratio in both eyes, with no signs of maculopathy related to bleb leakage.

Initially, the circumstances and risks associated with the patient's left eye, as well as all available treatment options, were comprehensively explained to the patient. Following an in-depth discussion, a medical regimen was implemented, which included the application of a TCL with a base curve of 8.6 mm and a diameter of 14.5 mm, topical gentamicin (Gentagut, Bilim Pharmaceuticals, İstanbul, Türkiye), and a combination of dorzolamide/timolol (Tomec, Abdi İbrahim, İstanbul, Türkiye). After applying the TCL, its coverage of the bleb leak was assessed and confirmed. The patient was monitored daily, but no

improvement in the severity of bleb leakage was observed by the end of the third day.

Following a collaborative decision with the patient, conjunctival CCL was performed to address the bleb leakage. A 0.1% hypotonic riboflavin solution containing 1.1% hydroxypropyl methylcellulose without dextran (MedioCROSS M, PeschkeMeditrade GmbH, Germany) was applied to the bleb's anterior surface at 1-minute intervals for 5 minutes. Subsequently, accelerated CCL treatment was conducted with 3 minutes of UVA irradiation at 30 mW/cm² using the CRS-X cross-linker (Yuratek, Türkiye) (Figure 3). A sponge was used to protect the cornea during the procedure. Post-treatment, topical gentamicin drops were continued not only to prevent infection but also to irritate the bleb surface, thereby stimulating epithelial proliferation. Treatment with combination dorzolamide/timolol was also extended to mitigate bleb leakage. A TCL (base curve: 8.6 mm, diameter: 14.5 mm) was applied for additional protection and support.

The patient was closely monitored after treatment, and the signs and symptoms of bleb-related infection were explained in detail to the patient. On the first postoperative day, a decrease in bleb leakage intensity was noted. Two weeks after CCL treatment, there was no observable bleb leakage (Figure 1B), and IOP had increased to 11 mmHg. No ocular complications or bleb leakage were detected during the 2.5-month follow-up.

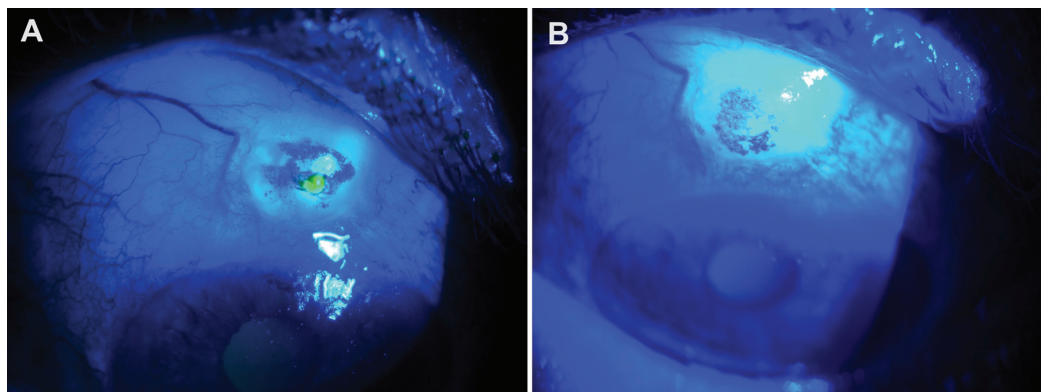


Figure 1. Visualization of pinpoint leakage from avascular cystic bleb upon contact with fluorescein paper (A). Resolution of bleb leakage observed two weeks after conjunctival collagen cross-linking treatment (B)

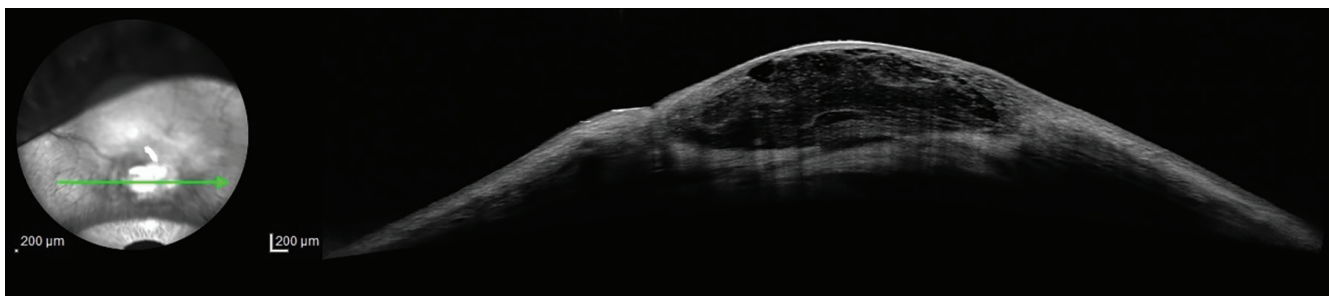


Figure 2. Anterior segment optical coherence tomography showing cystic spaces within the bleb

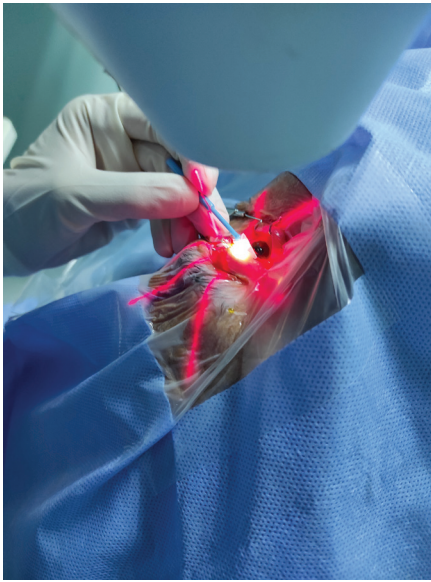

Figure 3. Accelerated conjunctival collagen cross-linking treatment utilizing the CRS-X cross-linker (Yuratek, Türkiye). A sponge was employed to safeguard the cornea during the procedure

Discussion

Despite many complications, trabeculectomy remains one of the most common surgical procedures performed for patients with glaucoma.⁷ One such complication is bleb leakage, which can be detected in both the early and late postoperative periods. Early leakage is generally related to surgical technique and insufficient conjunctival healing. In contrast, late bleb leakage is often caused by the use of antimetabolites, such as mitomycin C.⁷ Early detection and management of bleb leakage are essential to prevent serious complications including bleb-related infection and hypotony.

Bleb leakage can be managed through both medical and surgical treatments. Medical treatment options include aqueous suppressants, prophylactic antibiotics, direct pressure patching, and the use of bandage contact lenses. Surgical interventions to address leaking blebs encompass autologous blood injection, compression sutures, cyanoacrylate glue application, and conjunctival advancement procedures.⁸ Medical management is typically the initial approach in cases where the bleb leak is minor, free of infection, and the patient exhibits stable visual acuity and IOP, with no prior history of bleb-related infection. Surgical intervention is generally considered when a bleb leak fails to respond to medical management, is severe enough to induce complications, or if the patient has a history of recurrent bleb-related infections. A frequently utilized surgical technique is conjunctival advancement, which entails the excision of unhealthy bleb tissue and the subsequent coverage of the filtration site with a flap of healthy conjunctival tissue harvested from the region posterior to the bleb. Additionally, conjunctival CCL has recently emerged as an effective modality for the

treatment of bleb leaks.⁶ One advantage of this technique is the potential enhancement of conjunctival strength and stability through the reinforcement of the collagen structure, which may subsequently reduce the risk of future leakage.

There is a limited body of research investigating the impact of conjunctival CCL on bleb leakage. Choy et al.⁹ conducted a study wherein they treated 5 patients experiencing bleb leakage with conjunctival CCL, employing a protocol involving 30 minutes of UVA application. They reported that all patients demonstrated complete healing within a timeframe ranging from 1 to 4 weeks after treatment. Upon follow-up, this effect persisted for an average duration of 33.5 ± 10.2 weeks following the cessation of bleb leakage.⁹ In another study conducted by Wang and Harasymowycz⁶, a cohort of 7 patients presenting with bleb leakage underwent treatment involving 30 minutes of riboflavin loading followed by 30 minutes of UVA irradiation at 2 mW/cm^2 . While complete resolution was observed in 5 patients, bleb leakage persisted in 2 individuals.⁶ A prior case report documented the cessation of bleb leakage in a 60-year-old male patient after undergoing two consecutive CCL treatments.¹⁰ However, another author reported achieving bleb stabilization for 4 years with a single session of conjunctival CCL treatment.¹¹ As a result, despite the demonstrated effectiveness of conjunctival CCL in treating bleb leakage, clear criteria for patient selection and specific treatment protocols for CCL remain elusive. Therefore, additional studies are essential to delineate the precise role of CCL within the spectrum of therapeutic options for this condition.

In the present case report, accelerated CCL treatment was administered (3 minutes of UVA irradiation at 30 mW/cm^2). The rationale for selecting this treatment option included a stable eye with no complications, a lack of response to initial medical therapy, and restricted conjunctival mobility. Remarkably, cessation of bleb leakage was observed within two weeks after treatment. However, it should be noted that this treatment approach was combined with adjunctive therapies including topical gentamicin, dorzolamide/timolol combination, and TCL application. Although combined treatment was applied, it is believed that conjunctival CCL played a major role in reducing bleb leakage, as a significant decrease in the intensity of bleb leakage was detected on postoperative day 1. In comparison to other studies, we employed an accelerated CCL protocol that was notably shorter in duration. Similarly, Lázaro-Rodríguez et al.¹¹ also adopted this protocol (Avedro accelerated crosslinking) and reported prolonged stabilization of the bleb. Therefore, it can be inferred that accelerated conjunctival CCL treatment, involving 3 minutes of UVA irradiation at 30 mW/cm^2 , represents an effective and safe treatment protocol for managing bleb leakage. However, it should be noted that the short follow-up duration is a limitation of this study. Although the long-term effect of conjunctival CCL has been shown, further studies are necessary to evaluate the use of CCL.

In conclusion, conjunctival CCL appears to be a viable treatment modality for managing leaking blebs. When combined with adjunctive topical treatments and TCL application, bleb

leakage can be effectively managed in a non-invasive, safe, and expeditious manner. Hence, it is prudent to consider conjunctival CCL as an initial therapeutic option before resorting to surgical intervention for managing bleb leakage. Nevertheless, there exists a necessity for further comprehensive studies aimed at discerning the most effective treatment options and identifying suitable candidates for conjunctival CCL in the management of bleb leaks.

Ethics

Informed Consent: Obtained.

Authorship Contributions

Surgical and Medical Practices: A.M.K., B.T., Concept: A.M.K., Design: Data Collection or Processing: A.M.K., Analysis or Interpretation: A.M.K., Literature Search: A.M.K., Writing: A.M.K.

Conflict of Interest: No conflict of interest was declared by the authors.

Financial Disclosure: The authors declared that this study received no financial support.

References

1. Lim R. The surgical management of glaucoma: A review. *Clin Exp Ophthalmol*. 2022;50:213-231.
2. Rao A, Cruz RD. Trabeculectomy: Does It Have a Future? *Cureus*. 2022;14:e27834.
3. Feldman RM, Altaher G. Management of late-onset bleb leaks. *Curr Opin Ophthalmol*. 2004;15:151-154.
4. Sorkin N, Varssano D. Corneal collagen crosslinking: a systematic review. *Ophthalmologica*. 2014;232:10-27.
5. Chan TC, Agarwal T, Vajpayee RB, Jhanji V. Cross-linking for microbial keratitis. *Curr Opin Ophthalmol*. 2016;27:348-352.
6. Wang Q, Harasymowycz P. Collagen Cross-linking for Late-onset Bleb Leakage: 1-Year Results. *J Glaucoma*. 2016;25:273-276.
7. Leung DY, Tham CC. Management of bleb complications after trabeculectomy. *Semin Ophthalmol*. 2013;28:144-156.
8. Bochmann F, Azuara-Blanco A. Interventions for late trabeculectomy bleb leak. *Cochrane Database Syst Rev*. 2012:CD006769.
9. Choy BN, Zhu MM, Shum JW, Ho WL, Chan JC, Ng AL, Lai JS. Collagen crosslinking in the management of leaking cystic blebs: a prospective study. *Graefes Arch Clin Exp Ophthalmol*. 2016;254:529-533.
10. Aktas Z, Aribas YK, Bilgihan K, Tefon AB. Collagen Crosslinking-assisted Treatment of a Bleb Leak: Enhancement of Vascularization around the Bleb. *J Curr Glaucoma Pract*. 2021;15:36-39.
11. Lázaro-Rodríguez V, Casado-López D, Tolosa FR. Conjunctival collagen crosslinking for the management of bleb leak. *Indian J Ophthalmol*. 2023;71:276-279.