



## Endogenous Endophthalmitis Caused by *Aspergillus lentulus* in an Immunocompromised Patient with Lung Cancer

Mustafa Kayabaşı\*, Ziya Ayhan\*\*, Banu Lebe\*\*\*, Ayşe Aydan Özkütük\*\*\*\*, Meltem Söylev Bajin\*\*, Arzu Nazlı\*\*\*\*\*, Eyüp Sabri Uçan\*\*\*\*\*, Aziz Karaoğlu\*\*\*\*\*, Ali Osman Saatci\*\*

\*Muş State Hospital, Clinic of Ophthalmology, Muş, Türkiye

\*\*Dokuz Eylül University Faculty of Medicine, Department of Ophthalmology, İzmir, Türkiye

\*\*\*Dokuz Eylül University Faculty of Medicine, Department of Pathology, İzmir, Türkiye

\*\*\*\*Dokuz Eylül University Faculty of Medicine, Department of Microbiology, İzmir, Türkiye

\*\*\*\*\*Dokuz Eylül University Faculty of Medicine, Department of Infectious Diseases, İzmir, Türkiye

\*\*\*\*\*Dokuz Eylül University Faculty of Medicine, Department of Chest Diseases, İzmir, Türkiye

\*\*\*\*\*Dokuz Eylül University Faculty of Medicine, Department of Oncology, İzmir, Türkiye

### Abstract

A 78-year-old man with a history of lung cancer, chemotherapy, radiotherapy, and coronavirus disease 2019 infection experienced visual deterioration of two-weeks' duration in his right eye. There was multifocal, yellowish-white retinitis foci, vascular engorgement, and scattered intraretinal hemorrhages extending from posterior pole to retinal periphery in the right eye, whereas the left eye was normal. Intravitreal vancomycin, ceftazidime, clindamycin, and dexamethasone were given for endogenous endophthalmitis initially. Vitreous culture confirmed the presence of *Aspergillus lentulus*, and he was treated with intravitreal amphotericin-B and voriconazole injections together with systemic amphotericin-B, voriconazole, posaconazole, and micafungin therapy. During follow-up, vitreoretinal surgery was performed because of rhegmatogenous retinal detachment, and he received one additional cycle of chemotherapy due to recurrence of the cancer. Although the retina was attached, enucleation was eventually required due to painful red eye. Atypical squamous cells beneath the neurosensory retina suggesting metastasis were noted on histopathological examination. Timely ocular examination is crucial for any immunocompromised patient having ocular symptoms. High level of suspicion for a fungal etiology is a must in these patients.

**Keywords:** *Aspergillus lentulus*, COVID-19 infection, endogenous endophthalmitis, immunosuppression, retinitis

**Cite this article as:** Kayabaşı M, Ayhan Z, Lebe B, Özkütük AA, Söylev Bajin M, Nazlı A, Uçan ES, Karaoğlu A, Saatci AO. Endogenous Endophthalmitis Caused by *Aspergillus lentulus* in an Immunocompromised Patient with Lung Cancer. Turk J Ophthalmol 2024;54:175-179

**Address for Correspondence:** Ali Osman Saatci, Dokuz Eylül University Faculty of Medicine, Department of Ophthalmology, İzmir, Türkiye

E-mail: osman.saatci@gmail.com ORCID-ID: orcid.org/0000-0001-6848-7239

Received: 29.03.2024 Accepted: 27.05.2024

DOI: 10.4274/tjo.galenos.2024.44045

### Introduction

Endogenous endophthalmitis (EE) is typically associated with various risk factors such as systemic comorbidities, recent hospitalization, prolonged use of intravenous cannulas and catheters, intravenous drug use, and systemic infections.<sup>1</sup> Additionally, one or more factors contributing to an immunosuppressive state, such as early or advanced age, malignancy, diabetes mellitus, or the use of corticosteroids or non-corticosteroid immunosuppressive agents may also play a role.<sup>2,3</sup> Despite being less common than exogenous endophthalmitis, EE poses a greater danger to patients due to its life-threatening potential.<sup>4,5</sup> Coronavirus disease 2019 (COVID-19) has been shown to affect various organs and systems, including the eye.<sup>6,7</sup> Although both bacterial and fungal EE have been reported following COVID-19 infection, it has been shown that a fungal etiology is more likely than a bacterial etiology in these cases.<sup>8,9</sup>

Here, we present an extremely rare case in which a patient with lung cancer developed unilateral EE caused by *Aspergillus lentulus*.

### Case Report

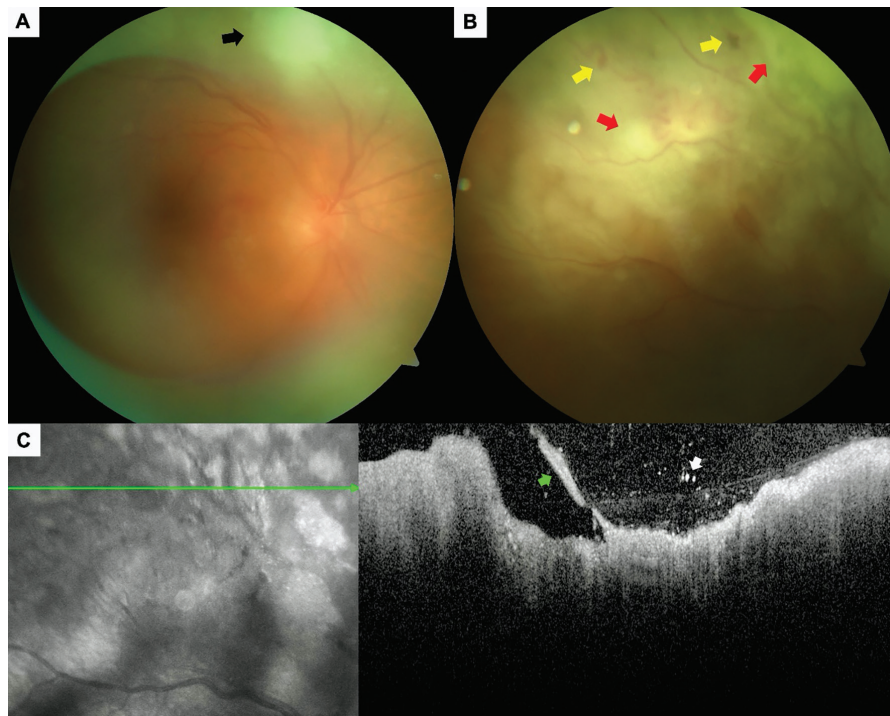
A 78-year-old man was referred to us with a gradual visual deterioration of two weeks' duration in his right eye. He previously received six cycles of chemotherapy based on paclitaxel and carboplatin, followed by four cycles of docetaxel, along with systemic radiation therapy for lung cancer diagnosed elsewhere 10 months earlier. He also had a history of systemic arterial hypertension, a recent hospitalization for COVID-19 infection just after the last chemotherapy session, and

uneventful bilateral cataract surgery with intraocular lens (IOL) implantation performed elsewhere 4 years ago.

On ophthalmological examination, his best-corrected Snellen visual acuity was counting fingers at 1 meter in the right eye and 8/10 in the left eye. Slit-lamp evaluation revealed 2+ anterior chamber cells, a posterior chamber IOL, and moderate vitritis in the right eye, while the left anterior segment was normal. Intraocular pressure was within normal limits bilaterally. Right fundus examination demonstrated a normal-looking optic disc and fovea but with grade 6 vitreous haze (according to the Miami scoring system<sup>10</sup>), white-yellowish presumed retinitis foci extending towards the superior retinal periphery, engorged vessels, and scattered intraretinal hemorrhages (Figure 1A and B). The left fundus was normal. A horizontal spectral-domain optical coherence tomographic section (Heidelberg Spectralis, Heidelberg Engineering, Heidelberg, Germany) passing through the retinitis area showed hyporeflective outer retinal layers related to the shadowing effect from the increased hyperreflectivity of the inner retinal layers, along with vitritis, vitreoretinal traction, and hyperreflective particles in the posterior vitreous (Figure 1C). We felt that the clinical presentation was compatible with right EE. A full systemic work-up was carried out, including complete blood count, routine biochemistry, sedimentation rate, C-reactive protein level, full infectious panel, and QuantiFERON-TB Gold test (Cellestis Inc., Carnegie, Victoria, Australia). A vitreous sample was obtained from the right eye

by vitreous puncture using a 26-gauge needle for bacterial and fungal cultures and polymerase chain reaction (PCR) analysis for the viral etiology. Then, intravitreal injection of 1 mg/0.1 cc vancomycin (Vancotek, Koçak Farma, İstanbul, Türkiye), 2 mg/0.1 cc ceftazidime (Zidim, Tüm Ekip İlaç, İstanbul, Türkiye), 1 mg/0.1 cc clindamycin (Klinoksin, Deva İlaç, İstanbul, Türkiye), and 0.4 mg/0.1 cc dexamethasone (Dekort, Deva İlaç, İstanbul, Türkiye) was administered into the right eye under topical anesthesia. Topical 1% cyclopentolate (Sikloplejin, Abdi İbrahim, İstanbul, Türkiye) 3 times a day, 1% prednisolone (Maxidex, Alcon, Geneva, Switzerland) 8 times a day, and 0.5% moxifloxacin (Vigamox, Novartis, Basel, Switzerland) 6 times a day were commenced.

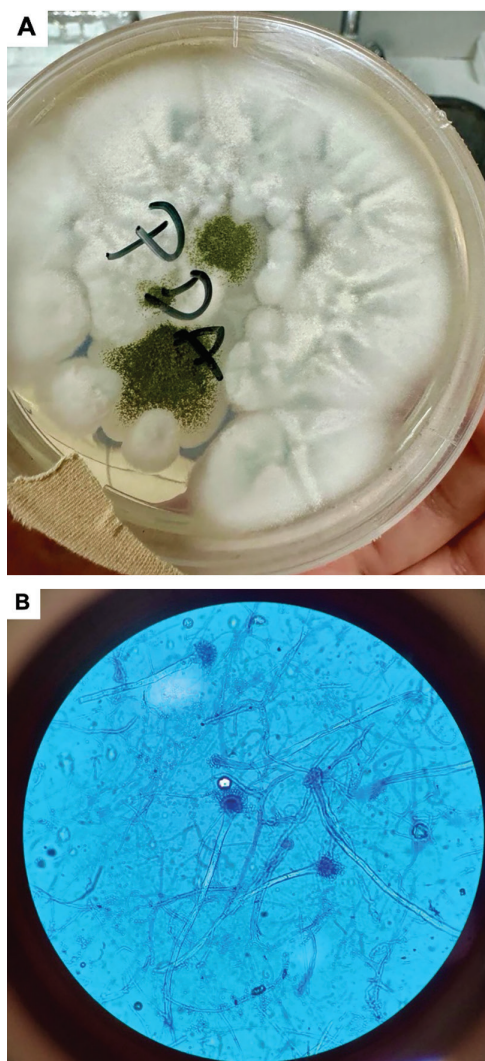
Serological tests for several infectious causes (including *Toxoplasma gondii*, cytomegalovirus, human immunodeficiency virus); QuantiFERON-TB Gold test; viral PCR analysis; and bacterial and fungal culture were negative. The vitreous haze briefly regressed, likely due to concurrent dexamethasone injection. The clinical findings then worsened despite three subsequent intravitreal injections of vancomycin, ceftazidime, and clindamycin administered over a 1-month period. Therefore, another vitreous sample was obtained, this time using a vitreous cutter set at 5000 cuts/min attached to a 2-mL syringe with manual suction under local anesthesia. Direct microscopic examination of the vitreous sample was unremarkable. Repeat viral PCR analysis and bacterial culture once again yielded



**Figure 1.** Right eye. Color fundus image of the posterior pole (A) showing the normal-looking optic disc and fovea, along with grade 6 vitreous haze and an area of retinitis (black arrow). Color fundus image of the superior retinal periphery (B) demonstrating the multifocal, yellowish-white presumed retinitis foci (red arrows), vascular engorgement, and scattered intraretinal hemorrhages (yellow arrows). Spectral-domain optical coherence tomographic section passing through the retinitis foci (C) depicting the hyporeflective outer retinal layers due to shadowing by the increased hyperreflectivity of the inner retinal layers, along with vitritis, vitreoretinal traction (green arrow), and hyperreflective particles in the posterior vitreous (white arrow)

negative results, but this time, fungal culture confirmed the presence of *A. lentulus* (Figure 2). Susceptibility testing for antifungal drugs could not be performed due to the unavailability of the testing kits at our hospital during that time. The patient received seven intravitreal injections of 5 mcg/0.1 cc amphotericin-B (AmBisome, Gilead Pharmaceuticals, Foster City, USA) and three intravitreal injections of 0.1 mg/0.1 cc voriconazole (Vfend, Pfizer, New York, USA) in the right eye and underwent parenteral administration of amphotericin-B (AmBisome, Gilead Pharmaceuticals), voriconazole (Vfend, Pfizer), posaconazole (Posectio, Polifarma, İstanbul, Türkiye), and micafungin (Mikafungus, Polifarma, İstanbul, Türkiye) followed by oral voriconazole (Vfend, Pfizer) therapy over a nearly 2-month period.

Three months after admission, the patient underwent right pars plana vitrectomy, laser photocoagulation, and



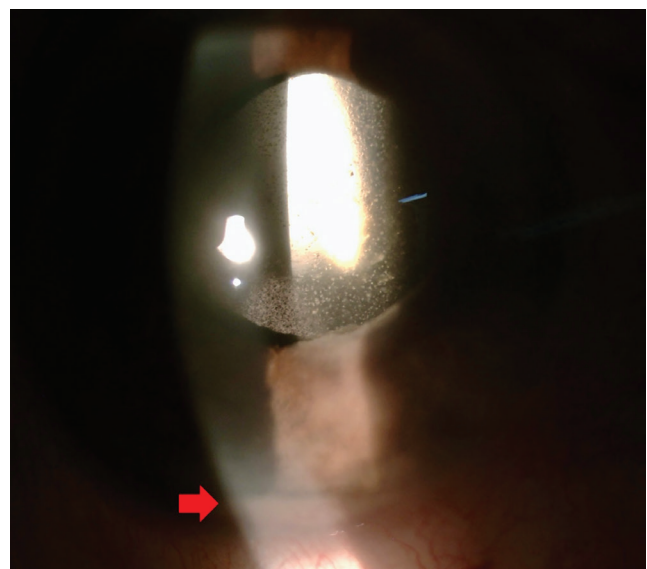
**Figure 2.** Morphologic appearance (A) of *Aspergillus lentulus* on potato dextrose agar showing colonies that are white and pale green-blue with slow sporulation. Microscopic image (B) showing the smaller, conidial heads with more diminutive vesicles compared to *Aspergillus fumigatus* (magnification 40x)

silicone endotamponade surgery due to the development of rhegmatogenous retinal detachment. The oncology department administered one more cycle of chemotherapy based on paclitaxel due to the recurrence of the lung cancer detected by positron emission tomography. Unfortunately, the patient developed a painful red eye with corneal edema, 0.5 mm hypopyon, 3+ anterior chamber cells, and precipitates on the posterior IOL surface together with irideal lumps suggesting metastasis (Figure 3). Right enucleation was performed. Upon microscopic examination of the specimen, we observed atypical squamous cells forming solid islands beneath the sensory retinal epithelium, indicative of metastasis from the lung cancer (Figure 4).

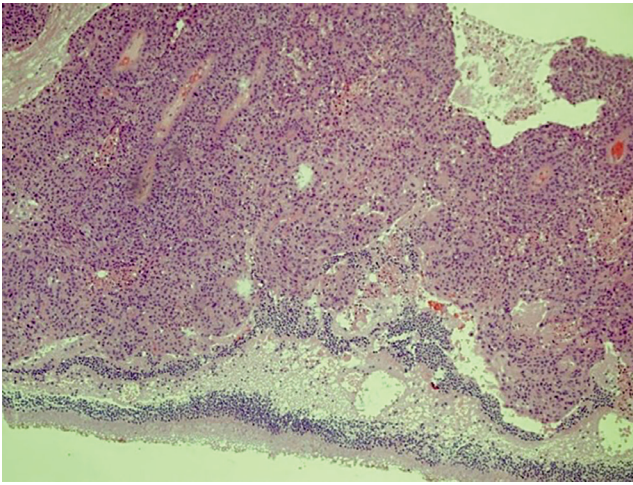
## Discussion

EE constitutes almost 2-8% of all cases of endophthalmitis. Bacterial EE infections are mostly caused by gram-positive bacteria, notably *Staphylococcus* and *Streptococcus* spp., while gram-negative bacteria, especially *Klebsiella* spp., are more commonly encountered in Asian regions.<sup>4,11</sup> On the other hand, *Candida* spp. are the most common fungal cause of EE, followed by *Aspergillus* spp.<sup>12</sup>

*A. lentulus*, which has been phenotypically identified as *A. fumigatus*, is a genetically distinct and highly drug-resistant species of *Aspergillus*.<sup>13,14</sup> To the best of our knowledge, *A. lentulus* endophthalmitis was first described by Shivasabesan et al.<sup>15</sup> in a 72-year-old woman with a history of orthotopic heart transplantation due to idiopathic dilated cardiomyopathy. She developed invasive pulmonary aspergillosis caused by *A. lentulus* despite being under prophylactic itraconazole therapy that was commenced prior to transplantation. Subsequently, the authors switched itraconazole to voriconazole. Several days later, the patient experienced painless floaters in her right eye. Fine



**Figure 3.** Right eye. Anterior segment photo revealing the mild corneal edema, 3+ anterior chamber cells, a 0.5 mm hypopyon (red arrow), and precipitates on the posterior intraocular lens surface



**Figure 4.** Microscopic image of the enucleation specimen depicting atypical squamous cells forming solid islands under the sensorineural retinal epithelium, indicating squamous cell carcinoma (original magnification 10x, stained with hematoxylin & eosin)

keratic precipitates and 2+ anterior chamber cells were observed upon ophthalmological examination, together with a large white mushroom-shaped subretinal mass projecting into the subhyaloid space with overlying mild to moderate vitreous haze in her right eye. 18s rRNA gene sequencing of the intravitreal aspirate confirmed the presence of *A. lentulus*, and twice weekly intravitreal voriconazole injections were commenced concurrent with the systemic voriconazole and anidulafungin therapy. Three weeks later, the patient underwent pars plana vitrectomy with removal of the fungal lesion, perilesional endolaser administration, intravitreal voriconazole injection, and fluid-air exchange due to lesion spread into the vitreous cavity. Intravitreal voriconazole injections were continued for 3 weeks post-vitrectomy.<sup>15</sup> Though systemic fungal infection was not present in our case, similar clinical progress was observed, where only an initial partial response could be obtained with intravitreal and systemic antifungal treatment. Moreover, rhegmatogenous retinal detachment developed, presumably secondary to intraocular inflammation and the burden of repeated intravitreal injections in the right eye, and vitreoretinal surgery was performed. Although the retina was attached, enucleation was eventually performed due to painful red eye.

Recently, Thompson et al.<sup>16</sup> evaluated the clinical course of EE in 37 eyes of 31 patients and reported vision loss, redness, and eye pain as the most common presenting symptoms. Only 7 eyes of 5 patients had fungal EE. They highlighted that all EE cases had at least one significant risk factor related to immunosuppression and concluded that prompt ocular examination was essential in immunocompromised patients experiencing any ocular symptoms to facilitate rapid diagnostic and therapeutic interventions.<sup>16</sup> Similarly, our patient was immunosuppressed because he had malignancy and a history of chemotherapy, and he had also experienced a recent COVID-19 infection prior to EE.

The primary treatment modality for fungal EE is intravenous and concomitant intravitreal administration of antifungal drugs. Polyenes (amphotericin B), azoles (voriconazole, isavuconazole, posaconazole), and echinocandins (micafungin, caspofungin) are among the preferred antifungal drugs. To date, voriconazole has been utilized as the first-line treatment of fungal EE via both the systemic and intravitreal routes as it attains higher concentrations in the intravitreal space. *A. lentulus* has been reported as a more drug-resistant subtype of *Aspergillus*, exhibiting reduced antifungal susceptibility for several antifungal agents.<sup>15,17</sup> We chose a combination of intravitreal amphotericin-B and voriconazole injections along with systemic amphotericin-B, voriconazole, posaconazole, and micafungin as the antifungal treatment in the present case, considering the possible drug resistance of *A. lentulus*.

In conclusion, a prompt ophthalmic examination to detect intraocular inflammation is crucial for any immunocompromised patient exhibiting presumptive ocular symptoms to facilitate early diagnosis and select the appropriate therapeutic regimen to prevent irreversible vision loss. As the differential diagnosis can be challenging, clinicians should have a high index of suspicion for potential fungal etiology and a proactive approach to ensure comprehensive care and optimized outcomes in this group of patients.

#### Ethics

**Informed Consent:** Obtained.

#### Authorship Contributions

Surgical and Medical Practices: Z.A., M.S.B., A.N., E.S.U., A.K., A.O.S., Concept: M.K., A.O.S., Design: M.K., B.L., A.A.Ö., A.O.S., Data Collection or Processing: M.K., B.L., A.A.Ö., Analysis or Interpretation: Z.A., M.S.B., A.O.S., Literature Search: M.K., A.N., E.S.U., A.K., A.O.S., Writing: M.K., A.O.S.

**Conflict of Interest:** No conflict of interest was declared by the authors.

**Financial Disclosure:** The authors declared that this study received no financial support.

#### References

1. Regan KA, Radhakrishnan NS, Hammer JD, Wilson BD, Gadkowski LB, Iyer SSR. Endogenous Endophthalmitis: yield of the diagnostic evaluation. *BMC Ophthalmol.* 2020;20:138.
2. Markan A, Dogra M, Katoch D, Tomar M, Mittal H, Singh R. Endogenous Endophthalmitis in COVID-19 Patients: A Case Series and Literature Review. *Ocul Immunol Inflamm.* 2023;31:1191-1197.
3. Takes O, Kocaoglu G, Saatci AO. Successful Treatment of a Case of Unilateral Endogenous Klebsiella pneumoniae Endophthalmitis. *EEur Ophth.* 2015;9:23-24.
4. Cunningham ET, Flynn HW, Relhan N, Zierhut M. Endogenous Endophthalmitis. *Ocul Immunol Inflamm.* 2018;26:491-495.
5. Ayhan Z, Karataş E, Yaman A, Saatci AO. *Endojen Endoftalminin Klinik Özellikleri* [Clinical Features of Endogenous Endophthalmitis]. *Ret-Vit.* 2019;28:51-56.
6. Cucinotta D, Vanelli M. WHO Declares COVID-19 a Pandemic. *Acta Biomed.* 2020;91:157-160.
7. Sen M, Honavar SG, Sharma N, Sachdev MS. COVID-19 and Eye: A Review of Ophthalmic Manifestations of COVID-19. *Indian J Ophthalmol.* 2021;69:488-509.

8. Agarwal M, Sachdeva M, Pal S, Shah H, Kumar R M, Banker A. Endogenous Endophthalmitis A Complication of COVID-19 Pandemic: A Case Series. *Ocul Immunol Inflamm.* 2021; 29:726-729.
9. Kaderli ST, Karalezli A, Çitil BE, Saatci AO. Endogenous Fungal Endophthalmitis in a Patient Admitted to Intensive Care and Treated with Systemic Steroid for COVID-19. *Turk J Ophthalmol.* 2022; 52:139-141.
10. Davis JL, Madow B, Cornett J, Stratton R, Hess D, Porciatti V, Feuer WJ. Scale for photographic grading of vitreous haze in uveitis. *Am J Ophthalmol.* 2010;150:637-641.e1.
11. Luong PM, Tsui E, Batra NN, Zegans ME. Endogenous endophthalmitis and other ocular manifestations of injection drug use. *Curr Opin Ophthalmol.* 2019;30:506-512.
12. Cunningham ET Jr, Rao NA, Gupta A, Zierhut M. Infections and Inflammation Occurring in the Subretinal Space. *Ocul Immunol Inflamm.* 2018;26:329-332.
13. Balajee SA, Kano R, Baddley JW, Moser SA, Marr KA, Alexander BD, Andes D, Kontoyiannis DP, Perrone G, Peterson S, Brandt ME, Pappas PG, Chiller T. Molecular identification of *Aspergillus* species collected for the Transplant-Associated Infection Surveillance Network. *J Clin Microbiol.* 2009;47:3138-3141.
14. Nematollahi S, Permpalung N, Zhang SX, Morales M, Marr KA. *Aspergillus lentulus*: An Under-recognized Cause of Antifungal Drug-Resistant Aspergillosis. *Open Forum Infect Dis.* 2021;8:ofab392.
15. Shivasabesan G, Logan B, Brennan X, Lau C, Vaze A, Bennett M, Gorrie N, Mirdad F, Deveza R, Koo CM, McCluskey P, Macdonald P, Marriott D, Muthiah K, Dharan NP. Disseminated *Aspergillus lentulus* Infection in a Heart Transplant Recipient: A Case Report. *Clin Infect Dis.* 2022;75:1235-1238.
16. Thompson KN, Alshaikhsalama AM, Wang AL. Evaluation of the Clinical Course of Endogenous Endophthalmitis. *J Vitreoretin Dis.* 2023;7:389-396.
17. Yagi K, Ushikubo M, Maeshima A, Konishi M, Fujimoto K, Tsukamoto M, Araki K, Kamei K, Oyamada Y, Oshima H. Invasive pulmonary aspergillosis due to *Aspergillus lentulus* in an adult patient: A case report and literature review. *J Infect Chemother.* 2019;25:547-551.