



## Tubulointerstitial Nephritis and Uveitis Syndrome During the COVID-19 Pandemic: A Case Series

© Kübra Özdemir Yalçınsoy\*, © Anıl Güngör\*, © Deniz Karakaya\*\*, © Levent Özdal\*\*\*, © Meltem Kılıç\*\*\*\*, © Yasemin Özdamar Erol\*, © Pınar Çakar Özdal\*

\*University of Health Sciences Türkiye, Ulucanlar Eye Training and Research Hospital, Clinic of Ophthalmology, Ankara, Türkiye

\*\*University of Health Sciences Türkiye, Ankara Dr. Sami Ulus Child Health and Diseases Training and Research Hospital, Clinic of Pediatric Nephrology, Ankara, Türkiye

\*\*\*University of Health Sciences Türkiye, Ankara City Hospital, Clinic of Urology, Ankara, Türkiye

\*\*\*\*University of Health Sciences Türkiye, Ankara City Hospital, Clinic of Ophthalmology, Ankara, Türkiye

### Abstract

**Objectives:** To report the ocular findings, laboratory results, and management of patients with tubulointerstitial nephritis and uveitis syndrome (TINU), whose numbers increased during the 2019 coronavirus disease (COVID-19) pandemic.

**Materials and Methods:** Demographic characteristics, ophthalmic examination findings, laboratory results including polymerase chain reaction (PCR) test for severe acute respiratory syndrome coronavirus 2 (SARS-CoV-2), serum SARS-CoV-2 immunoglobulin G (IgG) antibody, and treatment of patients diagnosed with TINU between March 2020 and March 2022 were evaluated retrospectively.

**Results:** The study included 19 eyes of 10 patients (6 female/4 male). The mean age was  $13.5 \pm 2.4$  years (range: 8-16 years). The mean follow-up duration was  $13.5 \pm 6.1$  months (range: 6-24 months). All patients presented with anterior uveitis. Anterior uveitis was bilateral in 9 patients (90%) and unilateral in 1 patient (10%). Posterior segment findings were normal in 8 patients (80%), and bilateral optic disc edema was observed in only 2 patients (20%). None of the patients had a previous SARS-CoV-2 infection and/or vaccination history. The SARS-CoV-2 PCR test was negative in all patients at presentation. The SARS-CoV-2 IgG antibody test was reactive in 7 patients (70%). Recurrent uveitis developed in 8

patients (80%) during follow-up. Systemic immunomodulatory therapy was required for the control of ocular inflammation in 7 patients (70%) with severe uveitis flare-ups.

**Conclusion:** TINU is a multisystemic autoimmune disease, especially in response to environmental triggering factors such as viral infections. Although TINU is a rare disease, the number of cases increased during the COVID-19 pandemic. SARS-CoV-2 antibodies were detected at a significant rate of 70% in these patients, who did not have a history of SARS-CoV-2 infection and vaccination. Previous asymptomatic SARS-CoV-2 infection in children may be a triggering factor in the development of TINU.

**Keywords:** COVID-19, pediatric uveitis, SARS-CoV-2, TINU, tubulointerstitial nephritis, uveitis

### Introduction

Tubulointerstitial nephritis and uveitis syndrome (TINU), which was first reported in 1975 by Dobrin et al.<sup>1</sup>, is a rare autoimmune disease. TINU is characterized by acute kidney inflammation and uveitis without any underlying systemic disease and it appears more frequently in children.<sup>2</sup> Uveitis in TINU is typically bilateral non-granulomatous anterior uveitis, but unilateral involvement, granulomatous uveitis, intermediate uveitis, and various posterior segment presentations may also occur.<sup>3,4</sup> While ocular findings usually follow tubulointerstitial nephritis (TIN), they may also occur concurrently or before TIN.<sup>3</sup> The etiopathogenesis of TINU is still unknown, but it is clear that TINU is an autoimmune inflammatory disease that develops with multifactorial environmental triggers such as viral, bacterial, and parasitic infections or pharmacological agents.<sup>2,3,4</sup>

**Cite this article as:** Özdemir Yalçınsoy K, Güngör A, Karakaya D, Özdal L, Kılıç M, Özdamar Erol Y, Çakar Özdal P. Tubulointerstitial Nephritis and Uveitis Syndrome During the COVID-19 Pandemic: A Case Series. *Turk J Ophthalmol* 2024;54:5-10

Address for Correspondence: Kübra Özdemir Yalçınsoy, University of Health Sciences Türkiye, Ulucanlar Eye Training and Research Hospital, Clinic of Ophthalmology, Ankara, Türkiye

E-mail: kubraozdemir250@gmail.com ORCID-ID: orcid.org/0000-0002-3352-9547

Received: 08.08.2023 Accepted: 05.12.2023

DOI: 10.4274/tjo.galenos.2023.24280

The 2019 coronavirus disease (COVID-19) caused by the severe acute respiratory distress syndrome-coronavirus 2 (SARS-CoV-2) became a pandemic that has affected the whole world.<sup>5</sup> In addition to the severe pulmonary effects of COVID-19, the multisystemic effects of COVID-19 began to emerge over time.<sup>3,6,7,8</sup> Several case reports of acute TIN and TINU that may be associated with SARS-CoV-2 infection have been described in the literature.<sup>9,10,11,12,13,14,15,16,17</sup> Recently, an increase in the incidence of acute TIN and TINU was reported in France in the first wave of the COVID-19 pandemic.<sup>12</sup> Another study reported a significant increase in TINU cases during the COVID-19 pandemic compared to the pre-pandemic period.<sup>13</sup> These studies suggested that SARS-CoV-2 infection may be among the infectious agents responsible for the development of acute TIN and TINU in children.<sup>12,15,16,17</sup>

TINU is known to account for less than 2% of all uveitis patients in ophthalmology clinics.<sup>3,18</sup> Although TINU is a relatively rare disease, an increase in the number of TINU cases has been observed in our clinic during the COVID-19 pandemic. Therefore, we think that the SARS-CoV-2 virus may be a triggering viral infection for TINU. In this study, we aimed to present the ophthalmic examination findings, laboratory results, and treatment approaches of patients diagnosed with TINU during the COVID-19 pandemic.

## Materials and Methods

The records of patients diagnosed with TINU were evaluated retrospectively between March 2020 and March 2022 in the uvea clinic of a tertiary eye hospital. The study was carried out according to the principles of the Helsinki Declaration, and the study was approved by the University of Health Sciences Türkiye, Ankara City Hospital Ethics Committee (number: E1-22-2979).

All patients were diagnosed by the same uveitis specialists and pediatric nephrologists according to the diagnostic criteria of TINU.<sup>19</sup> Typical uveitis findings of TINU were described as bilateral acute anterior uveitis that started within 2 months before or 12 months after acute TIN, while atypical uveitis findings of TINU were described as unilateral anterior uveitis, intermediate uveitis, posterior uveitis, or a combination of these.<sup>19</sup> TINU was categorized as definite (histopathologically or clinically diagnosed acute TIN with all criteria and typical uveitis), probable (histopathologically diagnosed acute TIN and atypical uveitis or clinically diagnosed acute TIN with incomplete criteria and typical uveitis), and possible (clinically diagnosed acute TIN with incomplete criteria and atypical uveitis).<sup>19</sup> Since the clinical findings of acute TIN were considered sufficient, a kidney biopsy was not performed in all patients.

Patients' demographic data, detailed ocular examination findings (Snellen visual acuity, tonometry, anterior and posterior segment slit-lamp examination), follow-up duration, and treatment approaches were evaluated. Best-corrected visual acuities (BCVA) at presentation and last visit, recurrent uveitis flare-up, and development of ocular complications such as

cataracts, glaucoma, and posterior synechia were recorded. Ocular inflammation was defined based on the Standardization of Uveitis Nomenclature Working Group Guidelines.<sup>20</sup>

All patients underwent routine complete blood counts, liver and kidney function tests, acute phase reactants (erythrocyte sedimentation rate [ESR] and C-reactive protein), and urinalysis. Extensive laboratory workup was performed to rule out other diseases. Laboratory tests included serology tests for syphilis; ELISA tests for hepatitis viruses and HIV; serum angiotensin-converting enzyme (ACE) and lysozyme values; antinuclear antibody (ANA), anti-Sjögren's syndrome-related (SS)-A antibody, antiSS-B antibody, proteinase 3-antineutrophil cytoplasmic antibody (ANCA), and myeloperoxidase-ANCA tests; and additional tests if needed. The interferon-gamma release assay test and tuberculin skin test were done to exclude tuberculosis. X-ray and/or chest computed tomography were performed. All patients had polymerase chain reaction (PCR) tests for SARS-CoV-2 from oral and nasal swabs obtained at presentation. To evaluate the relationship between TINU cases and COVID-19, these patients were retrospectively tested for serum SARS-CoV-2 immunoglobulin G (IgG). Patients with at least 6 months of regular follow-up were included.

## Statistical Analysis

The data were analyzed using IBM SPSS Statistics 22.0 (IBM Corp, Armonk, NY, USA). Qualitative data were expressed as number and percentages, and quantitative data as mean  $\pm$  standard deviation and range.

## Results

There were 3 patients with TINU in our clinic between 2010 and 2020, whereas TINU was diagnosed in 10 patients who presented with anterior uveitis in the following two years (2020-2022). This study included 19 eyes of 10 patients diagnosed with TINU between March 2020 and March 2022. Nine patients (90%) had bilateral and 1 patient (10%) had unilateral anterior uveitis. Six patients (60%) were female and 4 (40%) were male. The mean age of the patients at presentation was  $13.5 \pm 2.4$  years (range: 8-16 years). The mean follow-up duration was  $13.5 \pm 6.1$  months (range: 6-24 months). The onset of uveitis followed TIN in 2 patients (20%) and occurred concurrently with TIN in 8 patients (80%). The demographic characteristics, clinical findings, and laboratory results of the patients are summarized in [Table 1](#).

All patients had abnormal kidney function at presentation and the mean serum creatinine level was  $1.4 \pm 1.4$  mg/dL (range: 0.98-3.38 mg/dL). Urine  $\beta_2$  microglobulin level was elevated in 8 patients (80%), and the mean urine  $\beta_2$  microglobulin level was  $3.5 \pm 1.1$  mg/L (range: 1.76-5.42 mg/L). Liver function tests were within normal limits in all patients. ESR was high in 8 patients (80%), and the mean ESR was  $40.6 \pm 26.3$  mm/h (range: 10.0-98.0 mm/h). C-reactive protein was elevated in all patients (100%) and the median C-reactive protein level was 9.2 g/L (range: 3.0-78.7 g/L). ANA autoantibody was positive in 3 patients (30%), but no systemic disease was detected in any

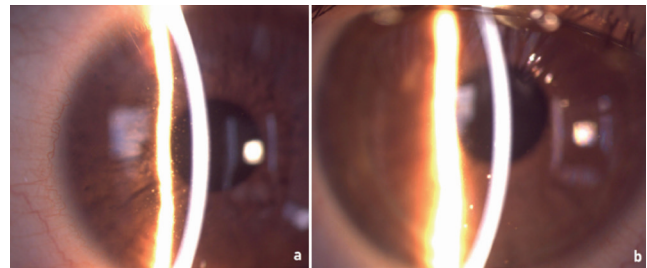
patient. Kidney biopsy was performed in only 3 patients (30%), and the results were consistent with TIN (Table 1).

None of the patients had a previous SARS-CoV-2 infection or vaccination history. Only 2 patients (20%) had family contact with SARS-CoV-2 infection within the last month. The SARS-CoV-2 PCR test was negative in all patients. The SARS-CoV-2 IgG antibody test was reactive in 7 patients (70%), and the mean SARS-CoV-2 IgG antibody level was  $9.3 \pm 7.3$  S/co (range: 1.26-22.79) (Table 1). Furthermore, the patients did not have a history of any medication use.

The ocular findings at presentation and treatment approaches are summarized in Table 2. All patients presented with symptoms of acute anterior uveitis; 8 patients (80%) had redness and 3 patients (30%) had blurred vision. BCVA at presentation was 20/100 in 2 eyes (10.5%), 20/40 in 1 eye (5.3%), and 20/25 or better in the remaining eyes (84.2%). Nine patients (90%) had non-granulomatous anterior uveitis and only 1 patient (10%) had granulomatous anterior uveitis (Figure 1). While fundus examination was normal in 8 patients (80%), bilateral optic disc edema was observed in 2 patients (20%). Fluorescein angiography (FA) was performed only in 2 patients (20%) with optic disc edema and showed bilateral optic disc hyperfluorescence and no vascular leakage. Considering all the above findings, 7 patients (70%) were

categorized as definite TINU and 3 patients (30%) as probable TINU syndrome.

Topical 1% prednisolone acetate (Allergan, Dublin, Ireland) (4 to 8 times daily), 1% cyclopentolate HCl (Abdi İbrahim, İstanbul, Türkiye) (1 to 3 times daily) and oral prednisolone (Gensenta, İstanbul, Türkiye) (0.5-1 mg/kg/day) treatment was given to all patients (100%). Topical and oral corticosteroid treatments were tapered weekly according to the patient's clinical response. Recurrent bilateral anterior uveitis was observed in 8 patients (80%) when topical



**Figure 1.** Anterior segment images of two different patients with TINU. Anterior segment imaging showed diffuse non-granulomatous keratic precipitates (a) and several paracentrally located granulomatous keratic precipitates (b)

TINU: Tubulointerstitial nephritis and uveitis syndrome

Case no	1	2	3	4	5	6	7	8	9	10
Age/gender	13/F	15/F	14/F	14/F	8/F	15/M	12/F	12/M	16/M	16/M
Follow-up duration (months)	10	11	24	9	6	12	12	6	6	6
Clinical findings	AAU, muscle pain and malaise	AAU	AAU	AAU	AAU, muscle pain and malaise	Fever and body rash	AAU, weight loss	AAU	Muscle pain and malaise	AAU
Laboratory work-up										
Serum creatinine (mg/dL)	1.21	1.10	1.05	0.98	0.94	3.38	1.54	1.01	1.98	1.04
Urine $\beta$ 2 microglobulin (mg/L)	3.10	5.42	N/A	2.64	3.72	4.34	4.76	N/A	3.50	3.90
Urine analysis	Proteinuria	Proteinuria, pyuria	Proteinuria	Pyuria	Glucosuria	Proteinuria	Normal	Pyuria	Normal	Normal
CBC	Normal	Anemia	Anemia	Normal	Anemia	Anemia	Anemia	Normal	Normal	Normal
Erythrocyte sedimentation rate (mm/h)	29	40	98	48	12	69	29	39	32	10
C reactive protein (g/L)	20	8.5	39.9	25.2	3.0	78.7	3.0	10.0	6.0	3.0
ANA	Positive	Positive	Negative	Negative	Negative	Negative	Negative	Negative	Negative	Negative
Kidney biopsy	N/A	TIN	TIN	N/A	N/A	TIN	N/A	N/A	N/A	N/A
SARS-CoV-2 PCR	Negative	Negative	Negative	Negative	Negative	Negative	Negative	Negative	Negative	Negative
SARS-CoV-2 IgG antibody (S/co)	Non-reactive	Reactive 22.79	Reactive 1.26	Non-reactive	Reactive 12.97	Non-reactive	Reactive 10.59	Reactive 3.69	Reactive 9.98	Reactive 4.05
F: Female, M: Male, AAU: Acute anterior uveitis, CBC: Complete blood count, ANA: Antinuclear antibodies, TIN: Tubulointerstitial nephritis, SARS-CoV-2: Severe acute respiratory syndrome coronavirus 2, PCR: Polymerase chain reaction, IgG: Immunoglobulin G										

Case no	1	2	3	4	5	6	7	8	9	10
Ocular involvement	Bilateral AU	Bilateral AU	Bilateral AU	Bilateral AU	Bilateral AU	Bilateral AU	Bilateral AU	Bilateral AU	Unilateral AU (left)	Bilateral AU
Anterior segment (right/left)	3+/4+ cells PS	1+/2+ cells	1+/2+ cells	2+/3+ cells	1+/2+ cells	2+/1+ cells	1+/2+ cells, PS	2+/3+ cells granulomatous KP	/4+ cells, PS	2+/2+ cells
Posterior segment	Bilateral OD edema	Normal	Normal	Normal	Bilateral OD edema	Normal	Normal	Normal	Normal	Normal
Recurrence	+	+	+	+	-	+	+	+	-	+
Treatment approach										
Topical and systemic corticosteroid	+	+	+	+	+	+	+	+	+	+
Immunosuppressive	MTX	MTX	MTX	-	-	MTX, MMF	MTX	MTX	-	AZA
Biological agent	ADA	ADA	ADA	-	-	ADA	ADA	-	-	-
Ocular complications	Steroid-induced IOP elevation, persistent PS	Steroid-induced IOP elevation, PSC	PSC			Steroid-induced IOP elevation	Persistent PS			

AU: Anterior uveitis, PS: Posterior synechia, KP: Keratic precipitates, OD: Optic disc, MTX: Methotrexate, MMF: Mycophenolate mofetil, AZA: Azathioprine, ADA: Adalimumab, IOP: Intraocular pressure, PSC: Posterior subcapsular cataract

and systemic corticosteroid therapy was reduced. Systemic immunomodulatory therapy was given to 7 patients (70%). In 2 patients (20%) (case 6, case 10), immunomodulatory therapy was also recommended for renal disease. Six patients (60%) used methotrexate (MTX, Koçak Farma, Ankara, Türkiye) (7.5-15 mg/week) and 1 patient (10%) used azathioprine (Aspen Pharmacare, Durban, South Africa) (100 mg/day). MTX therapy was switched to mycophenolate mofetil (Roche, Basel, Switzerland) in 1 patient (10%) (case 6) due to an elevation of liver function tests. The anti-tumor necrosis factor- $\alpha$  (TNF- $\alpha$ ) agent adalimumab (Abbvie, Chicago, Illinois, USA) (40 mg every 2 weeks), was added to systemic immunosuppressive therapy in 5 patients (50%) to control intraocular inflammation. Triple topical agents (brimonidine [Bilim İlaç, İstanbul, Türkiye] with a combination of non-selective beta-blocker and topical carbonic anhydrase inhibitor) were used for a mean of  $2.3 \pm 0.5$  months (range: 2-3 months) in 3 patients (30%) with steroid-induced intraocular pressure (IOP) elevation. IOP could be controlled, and no patient had glaucoma.

BCVA at the last visit was 20/25 or better in all eyes except 1 eye (5.3%) with 20/100 vision due to cataracts. Intraocular inflammation was controlled, and all patients had normal renal function at the last visit. The patients remain under follow-up, and systemic immunomodulatory treatment has not been discontinued in any patient yet.

## Discussion

This study evaluated the increased cases of TINU in a tertiary uvea clinic during the COVID-19 pandemic and detected reactive

SARS-CoV2 IgG antibodies in 70% of these patients. TINU syndrome, an oculorenal disease, is more commonly diagnosed in children aged 10-15 years, especially in female patients, but may also occur in adults.<sup>2,3,19,21,22</sup> All of our patients were in the pediatric age group and the majority were females. Although the etiopathogenesis of TINU is still unknown, studies have provided evidence for the involvement of cellular and humoral immunity in susceptible individuals.<sup>3,4</sup> Pharmacological and infectious agents have been suggested as two important triggering factors in the etiopathogenesis of TINU, yet active infection at the tissue level has not been demonstrated.<sup>2,3,4,12</sup> It is clear that TINU is an autoimmune inflammatory disease that develops with multifactorial environmental triggers. In our series, none of the patients had a history of drug use or previous infection, and ANA positivity was detected at a rate of 30%.

Avramescu et al.<sup>12</sup> recently evaluated 48 patients aged 9.4-17.6 years who were diagnosed with acute TIN (25 cases) and TINU (23 cases) during the COVID-19 pandemic. In addition to the increase in the incidence of acute TIN and TINU during the pandemic, the authors reported that the obtained positive serological and histopathological findings support a causal association between SARS-CoV-2 infection and the development of acute TIN/TINU in children.<sup>12</sup> SARS-CoV-2 uses ACE2 receptors to infect the cells, and these receptors are commonly in the renal tubules and the eye.<sup>5,8</sup> Studies suggest that SARS-CoV-2 damages kidney cells using this receptor pathway and initiates the inflammatory response.<sup>10,16</sup> García-Fernández et al.<sup>16</sup> reported an adolescent patient diagnosed with TINU in whom SARS-CoV-2 spike protein was detected in kidney tissue. The authors argued that SARS-CoV-2 played a potential role,

both directly and indirectly, in the development of TINU in these patients. There is currently no conclusive evidence in the literature on how acute TINU occurs after COVID-19, but it is hypothesized that the humoral and cellular autoimmune response triggered after SARS-CoV-2 infection may be the cause.<sup>8,10,12</sup> In our study, the increase in the number of pediatric patients with TINU during the COVID-19 pandemic and the detection of SARS-CoV-2 IgG antibodies in most of these patients suggest that previous asymptomatic SARS-CoV-2 infection in children may be a trigger in the development of TINU. Publications and reported cases on this subject are increasing day by day, and future multicenter studies with large sample sizes may help elucidate the pathogenesis.

Ocular involvement of TINU is typically bilateral anterior uveitis, but inflammatory manifestations of the posterior segment, such as optic disc edema, vascular sheathing, and chorioretinal lesions, may also occur.<sup>22,23,24,25</sup> There are currently few reports in the literature reporting uveitis findings in patients diagnosed with TINU during COVID-19.<sup>11,13,14,15,16,17</sup> In some of these, ocular involvement was reported as bilateral anterior uveitis in cases of TINU associated with SARS-CoV2 infection.<sup>14,16,17</sup> Although various posterior segment findings such as disc edema, chorioretinal scar, disc leakage, and peripheral vascular leakage were reported more frequently in TINU patients (87%) during the pandemic period than in pre-pandemic patients (67%), no significant difference was found.<sup>15</sup> Eser-Ozturk et al.<sup>11</sup> reported 4 patients with TINU aged 8-17 years with bilateral granulomatous panuveitis and choroidal inflammation possibly associated with COVID-19. In our series, 90% of the patients presented with bilateral anterior uveitis, and only 1 patient (10%) had granulomatous uveitis. Moreover, optic disc edema (20%) was the only posterior segment finding detected; no clinical signs of choroidal inflammation were observed in any patient. As we did not perform indocyanine green angiography and/or FA in patients without posterior segment findings, we cannot comment on the subclinical choroidal and retinal involvement.

In addition to SARS-CoV-2 infection, cases of uveitis or nephritis developing after COVID-19 vaccination have been reported in the literature.<sup>26,27,28</sup> Chen et al.<sup>26</sup> recently reported a case of TINU with bilateral anterior uveitis after receiving the COVID-19 mRNA vaccine. In a report of TINU cases during the COVID-19 pandemic, 2 out of 18 patients were reported to have received the COVID-19 vaccine before the onset of ocular symptoms.<sup>13</sup> Therefore, not only infection itself but also COVID-19 vaccines may cause autoimmune diseases such as TINU.<sup>26,29</sup> However, none of the cases in our series had a history of COVID-19 vaccination.

Renal involvement of TINU is usually self-limited, but uveitis may be chronic and recurrent, especially in children.<sup>3,4</sup> Topical and systemic corticosteroids are the first-line treatment for uveitis in TINU. However, steroid-sparing systemic immunomodulatory therapy is generally required to control intraocular inflammation.<sup>25,30,31,32</sup> A study evaluating the long-

term treatment results in TINU showed that early systemic immunomodulatory treatment was effective in achieving permanent remission.<sup>31</sup> Tirelli et al.<sup>32</sup> reported that anti-TNF agents are effective in the treatment of TINU cases with uveitis resistant to conventional immunomodulatory therapy. Good outcomes have been recently reported with antimetabolites and adalimumab therapy in patients with TINU associated with SARS-CoV2.<sup>11,13,15</sup> Even though Huang et al.<sup>13</sup> used TNF- $\alpha$  inhibitors only in TINU patients during the COVID-19 pandemic, they found no significant difference in the number of patients requiring biologic therapy before and during the COVID-19 pandemic. Maggio et al.<sup>15</sup> achieved complete uveitis remission after adalimumab treatment in a 7-year-old girl with recurrent uveitis who developed TINU after SARS-CoV-2 infection. Recurrent uveitis occurred in 80% of our patients when corticosteroid therapy was tapered. Therefore, 70% of patients required systemic immunomodulatory therapy, and adalimumab was used in 71% of these patients.

Mandeville et al.<sup>19</sup> reported an ocular complication rate of 21% in TINU, and the most common ocular complications were posterior synechia and optic disc edema. Furthermore, steroid-induced IOP elevation was found in 5% of patients aged 9-74 years.<sup>19</sup> In our series, ocular complications developed in 50% of the patients, and the most common complication was steroid-induced IOP elevation, followed by cataracts and posterior synechia. Steroid-induced IOP elevation is more common in pediatric uveitis patients compared to adults.<sup>33</sup> The high rate of steroid-induced IOP elevation in our series can be explained by the fact that all cases were in the pediatric age group.

#### Study Limitations

The study's main limitations are the retrospective design and the small sample size. Another limitation is that SARS-CoV-2 serological testing was performed only on patients diagnosed with TINU during the pandemic, and a control group of other uveitis could not be established, which may indicate a potential bias in the sample. However, the present study may be useful to draw attention to patients with TINU during the COVID-19 pandemic and to share experiences in the management of intraocular inflammation in TINU.

#### Conclusion

TINU should be considered in the differential diagnosis of bilateral anterior uveitis, especially in pediatric patients. SARS-CoV-2 infection may be among the environmental factors triggering TINU. Steroid-sparing treatments may be needed to control recurrent uveitis and prevent ocular complications in TINU.

#### Ethics

**Ethics Committee Approval:** The study was approved by the University of Health Sciences Türkiye, Ankara City Hospital Ethics Committee (number: E1-22-2979).

**Informed Consent:** Obtained.

### Authorship Contributions

Surgical and Medical Practices: K.Ö.Y., P.Ç.Ö., Y.Ö.E., M.K., D.K., Concept: K.Ö.Y., P.Ç.Ö., Design: K.Ö.Y., P.Ç.Ö., Data Collection or Processing: K.Ö.Y., A.G., P.Ç.Ö., Y.Ö.E., M.K., D.K., L.Ö., Analysis or Interpretation: K.Ö.Y., P.Ç.Ö., Literature Search: K.Ö.Y., A.G., P.Ç.Ö., Writing: K.Ö.Y., P.Ç.Ö.

**Conflict of Interest:** No conflict of interest was declared by the authors.

**Financial Disclosure:** The authors declared that this study received no financial support.

### References

- Dobrin RS, Vernier RL, Fish AL. Acute eosinophilic interstitial nephritis and renal failure with bone marrow-lymph node granulomas and anterior uveitis. A new syndrome. *Am J Med.* 1975;59:325-333.
- Koreishi AF, Zhou M, Goldstein DA. Tubulointerstitial Nephritis and Uveitis Syndrome: Characterization of Clinical Features. *Ocul Immunol Inflamm.* 2021;29:1312-1317.
- Aguilar MC, Longi M, de-la-Torre A. Tubulointerstitial Nephritis and Uveitis Syndrome: Case Report and Review of the Literature. *Ocul Immunol Inflamm.* 2016;24:415-421.
- Clive DM, Vanguri VK. The Syndrome of Tubulointerstitial Nephritis With Uveitis (TINU). *Am J Kidney Dis.* 2018;72:118-128.
- Sen S, Kannan NB, Kumar J, Rajan RP, Kumar K, Baliga G, Reddy H, Upadhyay A, Ramasamy K. Retinal manifestations in patients with SARS-CoV-2 infection and pathogenetic implications: a systematic review. *Int Ophthalmol.* 2022;42:323-336.
- May RM, Cassol C, Hannoudi A, Larsen CP, Lerma EV, Haun RS, Braga JR, Hassen SI, Wilson J, VanBeek S, Vankalakunti M, Barnum L, Walker PD, Bourne TD, Messias NC, Ambruzs JM, Boils CL, Sharma SS, Cossey LN, Baxi PV, Palmer M, Zuckerman JE, Walavalkar V, Urisman A, Gallan AJ, Al-Rabadi LF, Rodby R, Luyckx V, Espino G, Santhana-Krishnan S, Alper B, Lam SG, Hannoudi GN, Matthew D, Belz M, Singer G, Kunaparaju S, Price D, Chawla S, Rondla C, Abdalla MA, Britton ML, Paul S, Ranjit U, Bichu P, Williamson SR, Sharma Y, Gaspert A, Grosse P, Meyer I, Vasudev B, El Kassem M, Velez JCQ, Caza TN. A multi-center retrospective cohort study defines the spectrum of kidney pathology in Coronavirus 2019 Disease (COVID-19). *Kidney Int.* 2021;100:1303-1315.
- Zhou L, Xu Z, Guerra J, Rosenberg AZ, Fenaroli P, Eberhart CG, Duh EJ. Expression of the SARS-CoV-2 Receptor ACE2 in Human Retina and Diabetes-Implications for Retinopathy. *Invest Ophthalmol Vis Sci.* 2021;62:6.
- Su H, Yang M, Wan C, Yi LX, Tang F, Zhu HY, Yi F, Yang HC, Fogo AB, Nie X, Zhang C. Renal histopathological analysis of 26 postmortem findings of patients with COVID-19 in China. *Kidney Int.* 2020;98:219-227.
- León-Román J, Agraz I, Vergara A, Ramos N, Toapanta N, García-Carro C, Gabaldón A, Bury R, Bermejo S, Bestard O, Soler MJ. COVID-19 infection and renal injury: where is the place for acute interstitial nephritis disease? *Clin Kidney J.* 2022;15:1698-1704.
- Serafinelli J, Mastrangelo A, Morello W, Cerioni VF, Salim A, Nebuloni M, Montini G. Kidney involvement and histological findings in two pediatric COVID-19 patients. *Pediatr Nephrol.* 2021;36:3789-3793.
- Eser-Oztruk H, Izci Duran T, Aydog O, Sullu Y. Sarcoid-like Uveitis with or without Tubulointerstitial Nephritis during COVID-19. *Ocul Immunol Inflamm.* 2023;31:483-490.
- Avramescu M, Isnard P, Temmam S, Chevalier A, Bastard P, Attia M, Berthaud R, Fila M, Dossier C, Hogan J, Ulinski T, Leguevaques D, Louillet F, Casado EM, Halimi JM, Cloarec S, Zalozyc A, Faudeux C, Rousset-Rouvière C, Clavé S, Harambat J, Rollor E, Simon T, Nallet-Amate M, Ranchin B, Bacchetta J, Porcheret F, Bernard J, Rycckewaert A, Jamet A, Fourgeaud J, Da Rocha N, Pérot P, Kuperwasser N, Bouazza N, Rabant M, Duong Van Huyen JP, Robert MP, Zuber J, Casanova JL, Eloit M, Sermet-Gaudelus I, Boyer O. Acute tubulointerstitial nephritis with or without uveitis: a novel form of post-acute COVID-19 syndrome in children. *Kidney Int.* 2023;103:1193-1198.
- Huang L, Ta Kim D, Rosenberg CR, Lin P, Suhler E. Diagnosis and Characteristics of Presentation of Tubulointerstitial Nephritis and Uveitis Syndrome During the COVID-2019 Pandemic. *Ocul Immunol Inflamm.* 2023:1-8.
- Bilak VM, Ilko AV, Ignatko YY, Ignatko LV. Rare complication of COVID-19 disease TINU syndrome in a 11-year-old boy, features and management. *Wiad Lek.* 2022;75:2541-2543.
- Maggio MC, Collura F, D'Alessandro MM, Gramaglia B, Corsello G. Tubulointerstitial nephritis and uveitis syndrome post-COVID-19. *Pediatr Investig.* 2023;7:57-59.
- García-Fernández S, Fernández-Morán E, López-Martínez C, Vivanco-Allende B, Costales-Álvarez C, Ordóñez-Álvarez FA. Tubulointerstitial nephritis and uveitis syndrome and SARS-CoV-2 infection in an adolescent: just a coincidence in time? *Pediatr Nephrol.* 2023;38:4203-4207.
- Sakhinia F, Brice V, Ollerenshaw R, Gajendran S, Ashworth J, Shenoy M. Tubulointerstitial nephritis and uveitis in children during the COVID-19 pandemic: report of four cases. *J Nephrol.* 2023;36:1451-1455.
- Yalçındağ FN, Özdal PC, Özyazgan Y, Batioğlu F, Tugal-Tutkun I; BUST Study Group. Demographic and Clinical Characteristics of Uveitis in Turkey: The First National Registry Report. *Ocul Immunol Inflamm.* 2018;26:17-26.
- Mandeville JT, Levinson RD, Holland GN. The tubulointerstitial nephritis and uveitis syndrome. *Surv Ophthalmol.* 2001;46:195-208.
- Jabs DA, Nussenblatt RB, Rosenbaum JT; Standardization of Uveitis Nomenclature (SUN) Working Group. Standardization of uveitis nomenclature for reporting clinical data. Results of the First International Workshop. *Am J Ophthalmol.* 2005;140:509-516.
- Mackensen F, Smith JR, Rosenbaum JT. Enhanced recognition, treatment, and prognosis of tubulointerstitial nephritis and uveitis syndrome. *Ophthalmology.* 2007;114:995-999.
- Lopes BO, Brízido MS, Costa AC, Raimundo M, Miranda MM, Pina SM. Tubulointerstitial Nephritis and Uveitis Syndrome: Case Series and Literature Review. *Case Rep Ophthalmol Med.* 2021;2021:1812271.
- Scifo L, Willermain F, Postelmans L, Pozdzik A, Lolin Sekelj K, Zampieri M, de Jong C, Makhoul D. Subclinical Choroidal Inflammation Revealed by Indocyanine Green Angiography in Tubulointerstitial Nephritis and Uveitis Syndrome. *Ocul Immunol Inflamm.* 2022;30:1190-1198.
- Cao JL, Srivastava SK, Venkat A, Lowder CY, Sharma S. Ultra-widefield Fluorescein Angiography and OCT Findings in Tubulointerstitial Nephritis and Uveitis Syndrome. *Ophthalmol Retina.* 2020;4:189-197.
- Pichi F, Aljeneibi S, Neri P. Tubulointerstitial Nephritis and Uveitis Syndrome in the United Arab Emirates. *Ocul Immunol Inflamm.* 2023:1-5.
- Chen KW, Chang EL, Sheridan AM, Papalioidis GN. Tubulointerstitial nephritis and uveitis syndrome (TINU) following COVID-19 vaccination. *Am J Ophthalmol Case Rep.* 2023;31:101869.
- Sacker A, Kung V, Andeen N. Anti-GBM nephritis with mesangial IgA deposits after SARS-CoV-2 mRNA vaccination. *Kidney Int.* 2021;100:471-472.
- Czerlau C, Bocchi F, Saganas C, Vogt B. Acute interstitial nephritis after messenger RNA-based vaccination. *Clin Kidney J.* 2021;15:174-176.
- Wang Y, Yang L, Xu G. New-Onset Acute Interstitial Nephritis Post-SARS-CoV-2 Infection and COVID-19 Vaccination: A Panoramic Review. *J Epidemiol Glob Health.* 2023;13:615-636.
- Caplash S, Gangaputra S, Kodati S, Tuchman S, Srinivasalu H, Sen HN. Treatment challenges in an atypical presentation of tubulointerstitial nephritis and uveitis (TINU). *Am J Ophthalmol Case Rep.* 2018;10:253-256.
- Sobolewska B, Bayyoud T, Deuter C, Doycheva D, Zierhut M. Long-term follow-up of patients with Tubulointerstitial Nephritis and Uveitis (TINU) Syndrome. *Ocul Immunol Inflamm.* 2016;12:1-7.
- Tirelli F, Shafer BM, Davidson SL, Lerman MA. Immunomodulation and TNF- $\alpha$  inhibition for tubulointerstitial nephritis and uveitis syndrome: a case series. *J AAPOS.* 2021;25:267.
- Lam DS, Fan DS, Ng JS, Yu CB, Wong CY, Cheung AY. Ocular hypertensive and anti-inflammatory responses to different dosages of topical dexamethasone in children: a randomized trial. *Clin Exp Ophthalmol.* 2005;33:252-258.