



Slowly Progressing Retroorbital Hematoma

Yavaş Gelişen Retroorbital Hematom

Esin Tunca Kırıkkaya, Volkan Dayanır*, Mehmet Turgut**, Yelda Özsunar Dayanır***

Aydın Atatürk State Hospital, Department of Ophthalmology, Aydın, Turkey

*Adnan Menderes University School of Medicine, Department of Ophthalmology, Aydın, Turkey

**Adnan Menderes University School of Medicine, Department of Neurosurgery, Aydın, Turkey

*** Adnan Menderes University School of Medicine, Department of Radiology, Aydın, Turkey

Summary

Slowly progressing unilateral proptosis occurred in a male patient with a history of trauma experienced 2 years ago. All the ophthalmological examination, laboratory investigation, and both neurological and hematological evaluations were normal and there was nothing suggestive of coagulopathy. Magnetic resonance (MR) imaging revealed retroorbital hematoma. Exploration and evacuation of hematoma revealed dark yellow-colored liquid collection. Histopathological evaluation suggested hematic cyst. (*Turk J Ophthalmol* 2012; 42: 403-5)

Key Words: Retroorbital hematoma, proptosis

Özet

Travma hikayesi 2 yıl önce olan bir erkek hastada yavaş, tek taraflı propitozis gelişti. Tüm oftalmolojik muayene, labaratuvar inceleme ve nörolojik ve hematolojik değerlendirme normaldi ve koagulopatisi yoktu. Manyetik rezonans (MR) görüntülemesinde retroorbital hematoma saptandı. Hematom eksplore edildiğinde, koyu sarı renkli likid bir koleksiyon boşaltıldı. Histopatolojik değerlendirme hematik kisti destekledi. (*Turk J Ophthalmol* 2012; 42: 403-5)

Anahtar Kelimeler: Retroorbital hematoma, propitozis

Introduction

Due to trauma, orbital plexus bleeds and creates pressure on the globe that can damage the optic nerve and expose the anterior segment of the eye. Patient presents with pain, diplopia, proptosis. Immediate ophthalmology consultation, ice, head elevation and computer tomography (CT) are required.

Acute retrobulbar haemorrhage is a potentially sight-threatening condition that can occur spontaneously or following retrobulbar injections and trauma to the orbit.^{1,2} Visual loss results from central retinal artery occlusion or optic neuropathy from direct compression or from compression of optic nerve venous drainage.³⁻⁶ Prompt therapeutic intervention may restore good visual function. Nontraumatic retrobulbar hemorrhage

occurs rarely and has been associated with arteriovenous malformations,¹ following thrombolysis,² type IV Ehlers-Danlos syndrome,³ seizures,⁴ vomiting,⁵ following attempted strangulation⁵ and in a pregnant woman treated with subcutaneous heparin. We report a patient with retroorbital hematoma with no visual loss but orbital swelling.

Case

A 49-year-old male patient presented to our clinic with left orbital swelling for 3 months. He had a history of trauma of the left eye 2 years ago and following the trauma slowly developing of swelling. His past history was unremarkable for hypertension, hematological disorder, thyroid disease, sarcoidosis, paranasal sinus surgery or pharmacotherapeutics.

Address for Correspondence/Yazışma Adresi: Dr. Esin Tunca Kırıkkaya, Aydın Atatürk State Hospital, Department of Ophthalmology, Aydın, Turkey

Gsm: +90 532 3957240 E-mail: kesintunca@yahoo.com

Received/Geliş Tarihi: 14.05.2012 **Accepted/Kabul Tarihi:** 20.06.2012

Ophthalmological examination identified mild axial proptosis of the left eye, normal eye movements, no pain and no diplopia. Best-corrected visual acuity was 10/10 in both eyes, both biomicroscopic and fundus examinations were normal. Goldmann applanation tonometry revealed 12 mmHg in the right eye and 17 mmHg in the left eye. Visual field was evaluated with central 30-2 threshold test and found to be normal. Orbitometric evaluation revealed 14 mm in the right eye and 21 mm in the left eye. Doppler USG and cranium spiral CT evaluation demonstrated retroorbital collection and cystic benign lesion.

The patient was afebrile and blood examination showed 6.270.000/Ml in addition to no findings suggestive of coagulopathy. He was consulted by a hematologist and thrombosis was thought to be caused by trauma in addition to no hematological pathology causing thrombosis. Neurology consultation was also normal and MR imaging was recommended to be done, which revealed retroorbital hematoma (Figure 1).

Surgery was performed on July 27 2011. Dark yellow-colored liquid collection was gained and sent for histopathological and microbiological evaluation. Histopathological evaluation revealed hematic cyst. After the surgery, repeated MR imaging was performed and it was seen that the lesion was taken out incompletely (Figure 2, 3). After the operation, the lesion was smaller, but did not disappear (before the operation, the lesion

size was 30x20 mm, after the operation, it was found to be 18x20mm) and there were postoperative bone changes.

Discussion

Mechanisms that can increase the risk of postoperative orbital hemorrhage include: 1) traction on orbital fat tearing deep orbital vessels, 2) reflex vasodilatation after use of epinephrine, 3) increased venous pressure from Valsalva maneuvers, and 4) blood dyscrasias or the use of aspirin, coumadin, or nonsteroidal antiinflammatory drugs.

Retrobulbar hemorrhages may occur from facial trauma, orbital surgery, and peribulbar or retrobulbar injections. Retrobulbar anesthetic injections may result in a devastating loss of vision by compression of the circulation from mechanical tamponade, central retinal artery occlusion, or optic atrophy if not detected and treated immediately. The majority of retrobulbar hemorrhages can be managed conservatively with digital ocular massage or intravenous acetazolamide or mannitol. However, further surgical intervention is indicated when vision is at risk.

The mechanism of visual loss after an orbital hematoma is controversial. It is clear that both intraocular and orbital pressures increase when blood accumulates behind the septum. In this context, retinal and optic nerve ischemia is a likely mechanism to reduce vision. As pointed out by Hepler et al.⁷, patients with retinal ischemia should present with marked retinal edema, cotton-wool patches, and retinal vascular changes. In the vast majority of the cases, the ocular fundi were normal, suggesting an optic neuropathy as the only possible cause for the loss of vision. Anderson and Edwards⁸ were the first to describe electrophysiologic data in one case (normal electroretinogram and abolished visual evoked response), indicating that optic nerve damage was the cause of visual loss. The same findings were reported by Goldberg et al.⁹ in two cases. Recently, Good et al.¹¹ obtained magnetic resonance images (axial T2-weighted with fat saturation) for one patient 5 days after surgery, suggesting that an infarction of the posterior portion of the intraorbital optic nerve was the cause of the blindness. Retrobulbar hematoma requires emergency treatment. Taking into account that the source of the

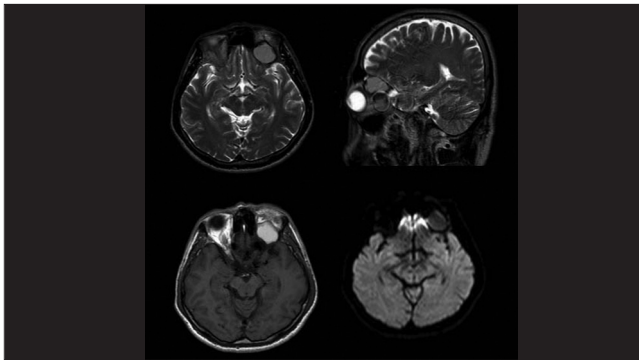


Figure 1. MR imaging of the patient demonstrating retroorbital hematoma

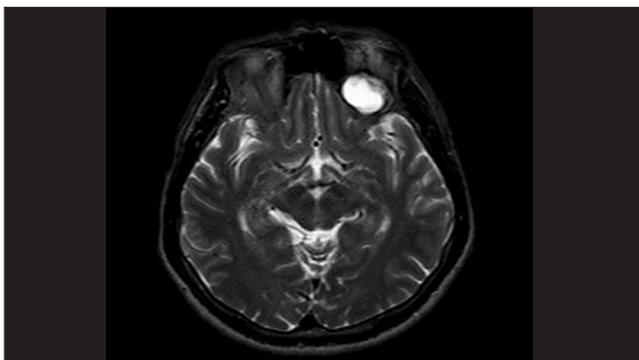


Figure 2. Axial MR imaging demonstrating that the lesion is smaller after the operation

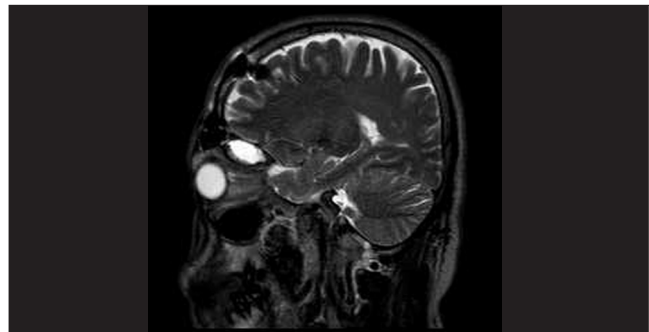


Figure 3. Sagittal MR imaging demonstrating that the lesion is smaller after the operation

loss of vision in most cases is the optic nerve and not the retina, the main focus of treatment is to decompress the orbit. This point has been recently emphasized by Goldberg and Markowitz¹¹ and, in the early literature, by Hepler et al.⁷ Medical treatment, which includes intravenous osmotic agents, acetazolamide, and beta blocker eyedrops, is the first step to be taken. Frequent vision monitoring is essential to establish the necessity of a surgical procedure. If there is any sign of deterioration of vision, surgical exploration of the wound, cantholysis, and orbital decompression should be undertaken.

In our case, there was no loss of vision, no diplopia and no pain. The eye movements were normal in all 9 position of gaze. Ophthalmological examination and laboratory findings were also normal and not suggestive of coagulopathy. The only problem was mild proptosis in his left eye and MR imaging which demonstrated retroorbital hematoma. Maybe the reason why the patient did not present with loss of vision and diplopia is the localization of hematoma being retroorbital and also the progression, which was slowly. Our case is different because there was no visual deterioration and no diplopia, that is why we wanted to share it with our colleagues.

References

1. Krohel GB, Wright JE. Orbital hemorrhage. *Am J Ophthalmol.* 1979;88:254-8.
2. Katz B, Herschler J, Brick DC. Orbital haemorrhage and prolonged blindness: a treatable posterior optic neuropathy. *Br J Ophthalmol.* 1983;67:549-53.
3. Goodall KL, Brahma A, Bates A, Leatherbarrow B. Lateral canthotomy and inferior cantholysis: an effective method of urgent orbital decompression for sight threatening acute retrobulbar haemorrhage. *Injury.* 1999;30:485-90.
4. Vassallo S, Hartstein M, Howard D, Stetz J. Traumatic retrobulbar hemorrhage: emergent decompression by lateral canthotomy and cantholysis. *J Emerg Med.* 2002;22:251-6.
5. Sampath R, Shah S, Leatherbarrow B. The management of an optic nerve compromising acute retrobulbar haemorrhage: report of a case. *Eye.* 1995;9:533-5.
6. Yung CW, Moorthy RS, Lindley D, Ringle M, Nunery WR. Efficacy of lateral canthotomy and cantholysis in orbital hemorrhage. *Ophthalmic Plast Reconstr Surg.* 1994;10:137-41.
7. Hepler RS, Sugimura GI, Straastama BR. On the occurrence of blindness in association with blepharoplasty. *Plast Reconstr Surg.* 1976;57:233-5.
8. Anderson RL, Edwards JJ. Bilateral visual loss after blepharoplasty. *Ann Plast Surg.* 1980;5:288-92.
9. Goldberg RA, Marmor MF, Shorr N, Christenbury JD. Blindness following blepharoplasty: two case reports, and a discussion of management. *Ophthalmic Surg.* 1990;21:85-9.
10. Good CD, Cassidy LM, Moseley IE, Sanders MD. Posterior optic nerve infarction after lower lid blepharoplasty. *J Neuroophthalmol.* 1999;19:176-9.
11. Goldberg RA, Markowitz B. Blindness after blepharoplasty. *Plast Reconstr Surg.* 1992;90:929-30.